



Acute Venous Congestive Myelopathy in a Patient with Neurosarcoidosis

Nicola Hazel Guy¹

¹Department of Neurosurgery, Capital and Coast District Health Board, Wellington Regional Hospital, Newtown, Wellington, New Zealand

Address for correspondence Nicola Hazel Guy, MMedSci, MBChB, Department of Neurosurgery, Capital and Coast District Health Board, Wellington Regional Hospital, Mein Street, Newtown, Wellington 6021, New Zealand (e-mail: nicola.guy@ccdhb.org.nz).

J Neurol Surg Rep 2022;83:e119–e122.

Abstract

There is a range of differential diagnoses for intramedullary lesions of the conus medullaris, both neoplastic and non-neoplastic. There is a limited role for surgery in a large proportion of these diagnoses, and operative risks can outweigh any benefits of surgery. Here a case is presented of a patient referred to a neurosurgical center for a biopsy of a presumed neoplastic conus tumor. However, through the collaboration of a multidisciplinary team, further diagnoses were considered. After thorough investigation, two conditions were diagnosed: venous congestive myelopathy secondary to inferior vena cava agenesis and spinal neurosarcoidosis. This case demonstrates the importance of neurosurgeons retaining a high degree of suspicion for alternative diagnosis to avoid unnecessary surgical risk.

Keywords

- ▶ neurosarcoidosis
- ▶ venous congestive myelopathy
- ▶ cauda equina
- ▶ intramedullary
- ▶ myelopathy

Introduction

The clinical red flags of cauda equina syndrome are bowel and bladder dysfunction, saddle anesthesia, and power or sensation deficits in the lower limbs. In clinical situations where there is suspicion of cauda equina, a magnetic resonance imaging (MRI) of the lumbar spine is generally expedited. Most commonly, a discogenic etiology is uncovered with investigative imaging;¹ however, intramedullary lesions of the conus medullaris can also present with these symptoms if there is compression of the exiting nerve roots. Conus lesions often present with mixed upper and lower neuron compression signs as both the conus medullaris and the cauda equina can be affected.²

There is a wide range of differentials of intramedullary conus lesions, summarized in ▶ **Table 1**. These include neoplastic and non-neoplastic lesions. As not all of these conditions are best managed surgically, or even require an invasive biopsy for diagnosis, it is important that neuro-

surgeons maintain a high degree of suspicion for diagnoses further down the list of differentials.

We present a case that was referred to our unit as a conus tumor for an invasive biopsy; however, the multidisciplinary team of surgeons, neuroradiologists, and oncologists considered alternative diagnoses. The initial diagnosis of neoplasm gave way to a diagnosis of venous congestive myelopathy due to vascular abnormalities found on imaging. However, as the clinical picture evolved, a subsequent additional diagnosis of neurosarcoidosis was delivered.

Case Report

A 45-year-old man presented to his local hospital after a week of lower back pain, 48 hours of ascending numbness in the lower limbs, difficulty mobilizing, and urinary retention. He was previously fit and well, had an active job, and was part of a social rugby team. An MRI of the lower spine revealed abnormal T2 hyperintensity and widening of the distal spinal

received

June 14, 2022

accepted

August 12, 2022

Accepted manuscript online

August 23, 2022

DOI <https://doi.org/>

10.1055/a-1929-5265.

ISSN 2193-6358.

© 2022. The Author(s).

This is an open access article published by Thieme under the terms of the Creative Commons Attribution-NonDerivative-NonCommercial-License, permitting copying and reproduction so long as the original work is given appropriate credit. Contents may not be used for commercial purposes, or adapted, remixed, transformed or built upon. (<https://creativecommons.org/licenses/by-nc-nd/4.0/>)

Georg Thieme Verlag KG, Rüdigerstraße 14, 70469 Stuttgart, Germany

Table 1 Differential diagnosis for intramedullary lesions in the conus medullaris (adapted from Ebner et al¹⁹)

Neoplastic	Ependymoma Astrocytoma Glioblastoma Ganglioma	Hemangioblastoma Lymphoma Melanoma Metastases
Non-neoplastic	Granulomatous— <i>Tuberculosis, sarcoidosis</i> Infection— <i>Abscess, parasitic</i> Vascular— <i>Cavernoma, malformations</i> Demyelinating— <i>Multiple sclerosis</i> Dysembryogenic— <i>Lipoma, epidermoid cyst</i>	

cord. The orthopaedic team in the local hospital made an acute referral to our neurosurgical service for the management of a spinal cord tumor, and on our advice the team administered dexamethasone prior to transfer.

On arrival to our hospital, a full spinal neurological exam was performed and noted normal power with decreased pain and light touch sensation below T12, with diminished but present reflexes. Proprioception was impaired distally below the ankle. On further interrogation of his symptoms, he reported years of exercise-induced, transient numbness in his lower limbs, worse on the right side, which limited his activity.

A whole spine MR scan was performed showing abnormal cord signal (T2 hyperintense, T1 isointense) and expanded cord from T7 to the conus at L2. Additionally, it demonstrated serpiginous prevertebral, paravertebral, and epidural blood vessels (►Fig. 1C, E). At this time an absent infrahepatic inferior vena cava was noted. These images were then discussed at a neurosurgical multidisciplinary meeting,

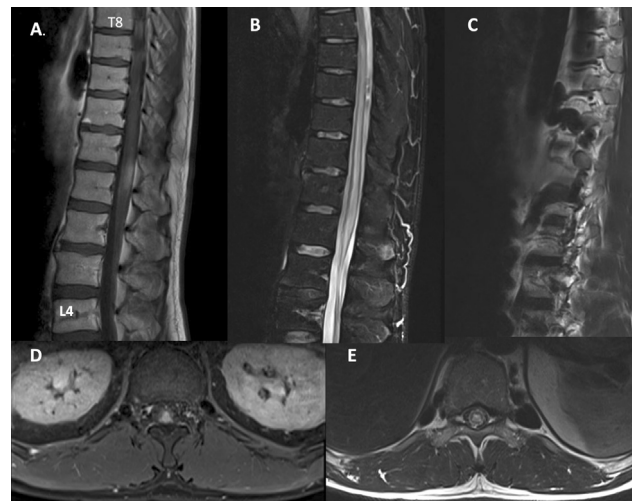


Fig. 1 Magnetic resonance imaging—(A) T1-weighted postcontrast slice showing a contrast enhancing region at the T12-L1 level and (D) representative axial slice through L1 level showing enlarged cord and enhancing region located in dorsal part of cord. (B) T2 fat-saturated sagittal image demonstrating central cord myelopathy from T8 to L2. (C) Sagittal T2 image demonstrating flow voids of the dilated paraspinal varices (E) Axial through T11 demonstrating flow voids of the dilated paraspinal varices, and central cord myelopathy.

where the focus shifted from a diagnosis of spinal cord tumor to venous congestive myelopathy.

Following this, a computed tomography (CT) venogram was performed to investigate possible thrombosis causing the acute presentation given the lifelong underlying vascular abnormality. No thrombosis was seen and thus we proceeded with a spinal angiogram that did not reveal a dural arteriovenous fistula or arteriovenous malformation. Vascular surgery and hematology were consulted, and there was some discussion about anticoagulation in this patient, who had venous congestion and varices without proven thrombosis. Ultimately, it was decided not to initiate anticoagulation.

During the admission to the neurosurgical service, the patient's neurology improved rapidly after administration of steroids and he regained his mobility and bowel and bladder function. Given the significant positive response to steroids, a neurology opinion was sought and the workup started for an inflammatory myelopathy. The patient was transferred back to his local hospital for a lumbar puncture and further investigations. A CT of the chest demonstrated mediastinal lymphadenopathy and shortly following this the cerebrospinal fluid angiotensin-converting enzyme level came back significantly elevated. A diagnosis of neurosarcoidosis was made and the patient was started on immunosuppression therapy.

Two months after his initial presentation, he was fully mobile with a normal neurological exam and some mild urinary hesitancy.

Discussion

This case highlights the importance of the neurosurgeon maintaining a high index of suspicion for alternative diagnosis when referred patients with spinal pathology. Although common things happen commonly, what is first thought to be a spinal tumor is not always a spinal tumor. Non-neoplastic lesions, vascular malformations, and demyelinating disorders can also present as regions of spinal cord enlargement. In our case, there were some red flags in both the clinic history and the imaging that led us away from planning a spinal cord biopsy, toward a diagnosis of venous congestive myelopathy, and further to the discovery of sarcoidosis.

The discovery of inferior vena cava agenesis and significant retroperitoneal and paraspinal varices (►Fig. 1C, E) allowed us to consider vascular myelopathy as a potential diagnosis. The patient presented acutely with cord compression myelopathy symptoms on a background of years of exercise-induced transient lower limb numbness, which is a temporal pattern strongly associated with vascular myelopathy.^{3,4} There have been cases reported previously where patients have presented with cauda equina symptoms due to venous congestion from dilated varices. The underlying etiology of cases with venous congestion is more commonly lower limb deep vein thrombosis⁵ than from inferior vena cava agenesis as in this case.⁶ Although the history of exertion-induced lower limb sensory changes could be attributed

to the venous congestion, the acute presentation did not clinically behave like a vascular myelopathy case as there was clinical improvement after steroid administration. As 50% of patients with venous congestion have worsened neurology after steroid dosing⁷ the team was suspicious of an alternative diagnosis and turned to our neuroradiologists and the MRI for diagnostic help.

On the first lumbar MRI scan, the region of T2 hyperintensity was in the shape of the conus, not displacing the cord that led us away from the diagnosis of spinal tumor. In our institution, we do not have the ability to perform spinal cord diffusion tensor imaging; however, tractography is used in other centers to aid in the differentiation between tumor (spinal cord tract displacing) and inflammatory, nondisplacing, lesions.⁸

In this case, the features of cord myelopathy extended from T7 to L2 (→**Fig. 1B**). However, the imaging findings were out of proportion to what was demonstrated on clinical examination, and given the extent of the myelopathy on imaging we would have expected a greater neurological deficit. This discrepancy between the imaging and the clinical presentation raised the suspicion of neurosarcoidosis with our radiologists. And this suspicion was heightened in the context of the postcontrast MR spine demonstrating a contrast-enhancing region within the area of myelopathy (→**Fig. 1A**).⁹ The pattern of enhancement was not the typical patchy nodule pattern observed in most reported cases of neurosarcoidosis and there was no pachymeningeal enhancement.^{10,11} Although the radiological findings are not specific to sarcoidosis, there was enough suspicion to justify continued investigation into inflammatory etiologies by our neurology colleagues which eventually yielded the diagnosis of sarcoidosis.

This case was interesting to us both as a diagnostic challenge and as a novelty of seeing dual presentations of rare conditions. Spinal sarcoidosis only occurs in 0.43 to 1% of neurosarcoidosis cases,¹² in addition to congestive myelopathy from agenesis of the inferior vena cava, of which there are seven cases in the reported literature.^{6,13–18} However, the probability of having two uncommon diagnoses presenting simultaneously should not detract from the learning point that a surgical intervention is not always required in all referrals of spinal cord lesions. The neurosurgeon should be alert to mimics of spinal neoplasia such as neurosarcoidosis and venous congestive myelopathy.¹⁹ There is no role for surgery in the treatment of venous congestive myelopathy caused by inferior vena cava abnormalities and the majority of cases are medically or conservatively managed.¹⁵ Diagnosis of neurosarcoidosis is often a diagnosis of exclusion and the role for surgery is limited to diagnostic tissue biopsy.²⁰ In some clinical series, spinal cord biopsy carries a 21% complication rate with significant risk of neurological damage²¹ not to mention the bleeding risk would be significant in this patient whose venous drainage of his abdomen and lower limbs passes through the venous plexes surrounding his spine.²² The collaboration of a multidisciplinary team in critically reviewing the imaging and considering alternative diagnoses in this patient avoided the likely significant harm of a surgery.

Conflict of Interest

None declared.

References

- LoRusso S. Disorders of the cauda equina. *Continuum (Minneapolis)* 2021;27(01):205–224
- Hida K, Iwasaki Y, Cho K, Imamura H, Abe H. Gliomas of the conus medullaris. *Paraplegia* 1994;32(01):52–58
- Zalewski NL. Vascular myelopathies. *Continuum (Minneapolis)* 2021;27(01):30–61
- Muralidharan R, Saladino A, Lanzino G, Atkinson JL, Rabinstein AA. The clinical and radiological presentation of spinal dural arteriovenous fistula. *Spine* 2011;36(25):E1641–E1647
- Hallan DR, McNutt S, Reiter GT, Thamburaj K, Specht CS, Knaub M. Dilated epidural venous plexus causing radiculopathy: a report of 2 cases and review of the literature. *World Neurosurg* 2020;144:231–237
- Ghiassi M, Ghiassi M, Kahn E, Tomycz L, Ayad M, Aaronson O. Cauda equina syndrome secondary to an absent inferior vena cava managed with surgical decompression. *J Neurosurg Spine* 2012;16(02):201–205
- Nasr DM, Brinjikji W, Rabinstein AA, Lanzino G. Clinical outcomes following corticosteroid administration in patients with delayed diagnosis of spinal arteriovenous fistulas. *J Neurointerv Surg* 2017;9(06):607–610
- Egger K, Hohenhaus M, Van Velthoven V, Heil S, Urbach H. Spinal diffusion tensor tractography for differentiation of intramedullary tumor-suspected lesions. *Eur J Radiol* 2016;85(12):2275–2280
- Soni N, Bathla G, Pillenahalli Maheshwarappa R. Imaging findings in spinal sarcoidosis: a report of 18 cases and review of the current literature. *Neuroradiol J* 2019;32(01):17–28
- Kaiboriboon K, Olsen TJ, Hayat GR. Cauda equina and conus medullaris syndrome in sarcoidosis. *Neurologist* 2005;11(03):179–183
- Carvalho GBS, Sandim GB, Tibana LAT, Tertulino FF, Idagawa MH, Abdala N. Magnetic resonance imaging in the differential diagnosis of infectious and inflammatory conus medullaris lesions. *Radiol Bras* 2013;46(01):51–55
- Stern BJ, Royal W, Gelfand JM, Clifford DB, Tavee J, Pawate S, Baughman RP. Definition and consensus diagnostic criteria for neurosarcoidosis: from the neurosarcoidosis consortium consensus group. *JAMA Neurology* 2018;75(12):1546–1553
- Yigit H, Yagmurlu B, Yigit N, Fitoz S, Kosar P. Low back pain as the initial symptom of inferior vena cava agenesis. *AJNR Am J Neuroradiol* 2006;27(03):593–595
- Oterdoom DLM, de Jong BM, Hoogland PV, Groen RJM. Transient cauda equina compression syndrome and headache caused by internal vertebral venous plexus engorgement in a teenage female with vena cava inferior agenesis and iliac vein thrombosis. *J Neurol Neurosurg Psychiatry* 2007;78(11):1283–1284
- Kamerath J, Morgan WE. Absent inferior vena cava resulting in exercise-induced epidural venous plexus congestion and lower extremity numbness: a case report and review of the literature. *Spine* 2010;35(18):E921–E924
- Dudeck O, Zeile M, Poellinger A, Kluhs L, Ludwig WD, Hamm B. Epidural venous enlargements presenting with intractable lower back pain and sciatica in a patient with absence of the infrarenal inferior vena cava and bilateral deep venous thrombosis. *Spine* 2007;32(23):E688–E691
- Yugueros X, Alvarez B, Fernández E, Boqué M, Matas M. Compressive symptoms due to thrombosed or hypertrophic collateral circulation in infrarenal inferior vena cava agenesis. *Ann Vasc Surg* 2013;27(02):238.e9–238.e13
- Wnuk E, Maj E, Dziedzic T, Podlecka Piętowska A. Spinal epidural venous plexus enlargement as a cause of neurologic symptoms: vascular anatomy and MRI findings. *Neurol India* 2020;68(05):1238–1241

- 19 Rodriguez FJ, Crum BA, Krauss WE, Scheithauer BW, Giannini C. Venous congestive myelopathy: a mimic of neoplasia. *Mod Pathol* 2005;18(05):710–718
- 20 Ebner FH, Roser F, Acioly MA, Schoeber W, Tatagiba M. Intra-medullary lesions of the conus medullaris: differential diagnosis and surgical management. *Neurosurg Rev* 2009;32(03):287–300, discussion 300–301
- 21 Cohen-Gadol AA, Zikel OM, Miller GM, Aksamit AJ, Scheithauer BW, Krauss WE. Spinal cord biopsy: a review of 38 cases. *Neurosurgery* 2003;52(04):806–815, discussion 815–816
- 22 Yoon JW, Ganaha S, Watridge C. Vertebral venous collaterals with underlying agenesis of the inferior vena cava: implications for spinal surgery. *World Neurosurg* 2018;114:63–67