Article published online: 2022-09-05

Comparison of a High-Pitch Non-ECG-Gated and a Prospective ECG-Gated Protocol for Preprocedural Computed Tomography Imaging Before TAVI/TAVR

Vergleich eines „high-pitch“ nicht EKG-getriggerten und eines prospektiv EKG-getriggerten Protokolls für die präinterventionelle CT vor TAVI

Authors

Seyd Shnayien[1], Nick Lasse Beetz[1, 2], Keno Kyrill Bressem[1], Bernd Hamm[1], Stefan Markus Niehues[1]

Affiliations

1 Department of Radiology, Charite University Hospital Berlin, Germany

2 Berlin Institute of Health at Charité – Universitätsmedizin Berlin, Berlin, Germany

Key words

aortic valve, cardiac, CT-angiography

received 05.01.2022

accepted 19.06.2022

published online 05.09.2022

Bibliography

Fortschr Röntgenstr 2023; 195: 139–147

DOI 10.1055/a-1898-6504

ISSN 1438-9029

© 2022. Thieme. All rights reserved.

Georg Thieme Verlag KG, Rüdigerstraße 14, 70469 Stuttgart, Germany

Correspondence

Dr. Seyd Shnayien

Radiology, Charite University Hospital Berlin, Hindenburgdamm 30, 12203 Berlin, Germany

Tel.: +4 93 04 50 62 78 39

seyd.shnayien@charite.de

ABSTRACT

Purpose Preprocedural computed tomography (CT) imaging before transcatheter aortic valve implantation/replacement (TAVI/TAVR) requires high diagnostic accuracy without motion artifacts. The aim of this retrospective study is to compare the image quality of a high-pitch non-electrocardiography (ECG)-gated CT protocol used in patients with atrial tachyarrhythmias with a prospectively ECG-gated CT protocol used in patients with sinus rhythm.

Materials and Methods We retrospectively included 108 patients who underwent preprocedural CT imaging before TAVI/TAVR. 52 patients with sinus rhythm were imaged using a prospectively ECG-gated protocol (Group A), and 56 patients with atrial tachyarrhythmias were imaged using the high-pitch non-ECG-gated protocol (Group B). Image quality was rated subjectively by two experienced radiologists and assessed by objective parameters including radiation dose, image noise, contrast-to-noise ratio (CNR), and signal-to-noise ratio (SNR) at the levels of the aortic root and abdominal aorta.

Results Subjective image quality was equally good with both CT protocols, and interrater agreement was substantial in both groups but tended to be higher in Group B at the level of the aortic root (Group A: $\kappa w = 0.644$, Group B: $\kappa w = 0.741$). With the high-pitch non-ECG-gated CT protocol, image noise was significantly increased ($p = 0.001$), whereas the SNR, CNR, and radiation dose were significantly decreased ($p = 0.002$, $p = 0.003$, and $p < 0.001$, respectively) at the level of the aortic root compared to the prospectively ECG-gated CT protocol.

Conclusion The high-pitch non-ECG-gated protocol yields images with similar subjective image quality compared with the prospectively ECG-gated CT protocol and allows motion-free assessment of the aortic root for accurate TAVI/TAVR planning. The high-pitch non-ECG-gated protocol may be used as an alternative for preprocedural CT imaging in patients with atrial tachyarrhythmias.

Key Points:

- In patients with atrial tachyarrhythmias, a high-pitch non-ECG-gated CT protocol achieves similar subjective image quality compared to a prospective ECG-gated CT protocol.
- At the level of the aortic root, image noise is significantly increased, whereas SNR and CNR are significantly decreased using the high-pitch non-ECG-gated protocol.
- Radiation dose is reduced by 55 % using the high-pitch non-ECG-gated protocol.

Citation Format

- Shnayien S, Beetz N, Bressem KK et al. Comparison of a High-Pitch Non-ECG-Gated and a Prospective ECG-Gated Protocol for Preprocedural Computed Tomography Imaging Before TAVI/TAVR. Fortschr Röntgenstr 2023; 195: 139–147

This document was downloaded for personal use only. Unauthorized distribution is strictly prohibited.

ZUSAMMENFASSUNG

Ziel Die präinterventionelle Bildgebung mittels Computertomografie (CT) vor geplanter Transkatheter-Aortenklappen-Implantation (TAVI) erfordert eine hohe diagnostische Genauigkeit ohne Bewegungsartefakte. Ziel dieser retrospektiven Studie ist es, die Bildqualitäten eines „high-pitch" nicht Elektrokardiogramm (EKG)-getriggerten CT-Protokolls bei Patienten mit atrialer Tachyarrhythmie und eines prospektiv EKG-getriggerten CT-Protokolls bei Patienten mit Sinusrhythmus zu vergleichen.

Material und Methoden Es wurden 108 Patient*innen mit einer präinterventionellen CT-Bildgebung vor geplanter TAVI retrospektiv eingeschlossen. 52 Patient*innen wurden mit dem prospektiv EKG-getriggerten CT-Protokoll untersucht (Gruppe A), während 56 Patient*innen mit atrialer Tachyarrhythmie mit dem „high pitch" nicht EKG-getriggerten CT-Protokoll untersucht wurden. Die Bildqualität wurde von 2 erfahrenen Radiologen beurteilt. Zudem wurden die objektiven Bildparameter Strahlendosis, Bildrauschen, Kontrast-Rausch-Verhältnis und Signal-Rausch-Verhältnis auf Höhe der Aortenwurzel und der abdominellen Aorta verglichen.

Ergebnisse Unabhängig von dem verwendeten CT-Protokoll war die Bildqualität gleich gut und die Interrater-Reliabilität substantiell, aber tendenziell besser in Gruppe B auf Höhe der Aortenwurzel (Gruppe A: $\kappa w = 0.644$ und Gruppe B: $\kappa w = 0.741$). Bei der Verwendung des „high-pitch" nicht EKG-getriggerten CT-Protokolls war das Bildrauschen auf Höhe der Aortenwurzel signifikant erhöht ($p = 0.001$), wogegen das Kontrast-Rausch-Verhältnis, das Signal-Rausch-Verhältnis sowie die Strahlendosis signifikant reduziert waren ($p = 0.002$, $p = 0.003$, und $p < 0.001$) im Vergleich zum prospektiv EKG-getriggerten CT-Protokoll.

Schlussfolgerung Das „high-pitch" nicht EKG-getriggerte CT-Protokoll bietet eine ähnliche subjektive Bildqualität verglichen mit dem prospektiv EKG-getriggerten CT-Protokoll und erlaubt eine bewegungsfreie Beurteilung der Aortenwurzel für eine akkurate TAVI-Planung. Das „high-pitch" nicht EKG-getriggerte CT-Protokoll könnte eine Alternative für die präinterventionelle CT-Bildgebung bei Patient*innen mit atrialer Tachyarrhythmie darstellen.

Kernaussagen:

- Bei Patient*innen mit atrialer Tachyarrhythmie kann das „high-pitch" nicht EKG-getriggerte CT-Protokoll im Vergleich zu dem EKG-getriggerten CT-Protokoll eine vergleichbare subjektive Bildqualität erzeugen.
- Bei dem „high-pitch" nicht EKG-getriggerten CT-Protokoll ist das Bildrauschen auf Höhe der Aortenwurzel signifikant erhöht, während das Kontrast-Rausch-Verhältnis und Signal-Rausch-Verhältnis signifikant verringert sind.
- Bei dem „high-pitch" nicht EKG-getriggerten CT-Protokoll wird die Strahlendosis um 55 % reduziert.

Introduction

Technological advances and procedural simplification have increased the use of transcatheter aortic valve implantation/replacement (TAVI/TAVR) to treat aortic valve stenosis, such that, in the United States, more patients now undergo TAVI/TAVR than isolated surgical aortic valve replacement (SAVR) [1]. Prior to the procedure, candidates undergo computed tomography (CT) imaging for the assessment of the aortic root including aortic annulus diameter, aortic valve structure, degree of calcification as well as evaluation of the peripheral access route [2–4].

The latest recommendations for preprocedural CT imaging before TAVI/TAVR issued by the Society of Cardiovascular Computed Tomography (SCCT) and European Society of Cardiovascular Radiology (ESCR) suggest that, at least, the aortic root should be imaged with electrocardiogram (ECG)-gated scans to limit motion artifacts [5, 6]. Image quality is best in patients with a slow heart rate (HR) and sinus rhythm [7]. However, many patients suffering from aortic valve stenosis have concomitant atrial tachyarrhythmias such as atrial fibrillation (AF) [8], which is characterized by a high HR and HR variability [9]. This may result in motion artifacts [10] that impair the diagnostic accuracy of CT imaging [11]. While beta-blockers are helpful in regulating HR during a CT examination, they need to be carefully dosed as the additional antihypertensive effect may result in hypotension and hemodynamic collapse in patients with aortic valve stenosis [12]. Therefore, current SCCT guidelines propose ECG editing after retrospective ECG-gated imaging to reduce artifacts [5].

However, besides higher radiation exposure, another disadvantage of retrospective multi-segment reconstruction is that the images may be blurred by respiratory motion or changing R-R intervals [13]. In contrast, non-gated CT can be performed with a higher pitch, thereby reducing artifacts and radiation dose [14]. Therefore, the aim of this study was to investigate whether, in patients with atrial tachyarrhythmias, motion-free imaging of the aortic root can be achieved by using a high-pitch non-ECG-gated CT protocol compared to a prospective ECG-gated CT protocol for preprocedural imaging before TAVI/TAVR [15].

Methods

Study Design

This single-center, retrospective study was designed to evaluate the performance of a high-pitch non-ECG-gated CT protocol in patients with atrial tachyarrhythmias in terms of image quality compared to a prospective ECG-gated CT protocol for preprocedural planning before TAVI/TAVR. The study was approved by the institutional review board and performed in compliance with the Declaration of Helsinki. Patient consent was waived due to the retrospective study design.

This document was downloaded for personal use only. Unauthorized distribution is strictly prohibited.

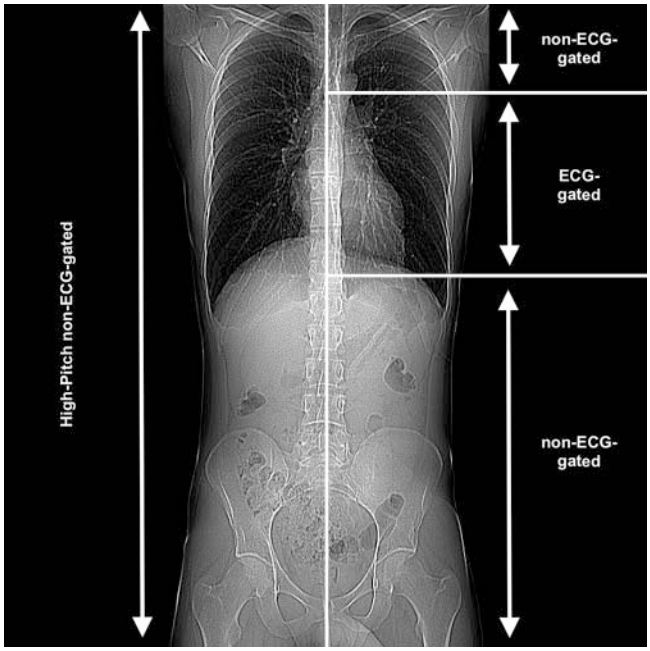

▶ **Fig. 1** Illustration of the two examination protocols for Group A (right) and Group B (left).

▶ **Abb. 1** Darstellung der beiden Untersuchungsprotokolle für Gruppe A (rechts) und Gruppe B (links)

Study Population

A total of 163 patients who were referred to our department for preprocedural CT imaging before TAVI/TAVR over a period of 21 months were considered for inclusion in this study. 55 patients were excluded as they were examined with a retrospective ECG-gated protocol. A total of 108 patients with severe and symptomatic aortic valve stenosis were finally included. Patients who presented with a regular HR (≤ 90 bpm) and sinus rhythm at the time of CT planning were examined using a prospective ECG-gated CT protocol (Group A, n = 52), whereas patients whose ECG signal at the time of CT planning showed atrial tachyarrhythmias were examined using a high-pitch non-ECG-gated protocol (Group B, n = 56) (see ▶ **Fig. 1**).

CT Protocol

All patients were examined on the same 80-detector-row CT scanner (Aquilion PRIME, Canon Medical Systems, Otawara, Japan). In both groups, imaging was performed with a temporal resolution of 175 ms using half-scan reconstruction. The following scan parameters were used for both protocols: automated tube current modulation (max = 600 mA and min = 40 mA), 512 × 512 matrix, 40 × 0.5 collimation, 0.5 mm thickness, 0.35 s rotation time, and automated tube voltage (min/max of 100/120 kV in Group A and 100/135 kV in Group B). Axial images were reconstructed from the raw data using Canon's integrated adaptive iterative dose reduction (AIDR-3 D) reconstruction algorithm at a slice thickness of 0.5 mm for axial images and 3.0 mm for coronal and sagittal images. A full field of view (FOV) was used for annulus assessment.

In Group A, images were acquired with a non-ECG-gated scan of the upper thoracic aperture at a pitch of 0.813, followed by a prospective ECG-gated acquisition of the heart at a pitch of 0.267, and a subsequent non-ECG-gated abdominal/pelvic scan with a pitch of 0.813 reconstructed as one volume [16]. In Group B, a high pitch of 1.388 was set for the entire scan volume, which was acquired with a single non-ECG-gated acquisition.

No premedication to control heart rate was given. All patients received an intravenous contrast agent bolus of iomeprol (400 mg iodine/ml; Imeron-400 MCT, Bracco, Milan, Italy) followed by a 60 ml saline flush. The contrast agent dose and administration rate were adjusted to the estimated glomerular filtration rate (eGFR) as follows: 60 ml at a rate of 3.0 ml/s for eGFR < 35 ml/min/1.73 m^2, 80 ml at 4.0 ml/s for eGFR of 35–45 ml/min/1.73 m^2, 100 ml at 4.0 ml/s for eGFR of 46–60 ml/min/1.73 m^2, and 120 ml at 4.0 ml/s for eGFR > 60 ml/min/1.73 m^2. CT acquisition was started automatically with a delay of 3 s after vessel attenuation in a region of interest (ROI) placed in the ascending thoracic aorta exceeded 200 Hounsfield units (HU).

After acquisition, Vital's Vitrea advanced 6.2 TAVR software (Vital Images Inc., Minnetonka, USA) was used for preprocedural evaluation for TAVI/TAVR including semiautomatic identification and measurement of the area of the aortic annulus.

Objective Image Analysis

In axial images, circular ROIs were placed in the aortic lumen and the closest adjacent muscle at 1) the aortic root and 2) the abdominal aorta just proximal to the aortic bifurcation. HU values of the vessel and muscle as well as image noise of the vessel (defined as the standard deviation (SD) of HU) were measured. Afterwards, the following parameters were calculated: a) signal-to-noise ratio (SNR), defined as vessel HU divided by image noise, and b) contrast-to-noise ratio (CNR), defined as the difference between vessel and muscle HU divided by image noise [17–21]. All aortic ROIs were drawn as large as possible and muscle ROIs were made the same size as vessel ROIs.

Subjective Image Analysis

Two radiologists experienced in cardiovascular imaging rated the image quality of the aortic root and the abdominal aorta with respect to the following features to identify motion artifacts: clear identification of the annulus plane and clear depiction of valve leaflets for the aortic root and arterial wall sharpness as well as conspicuity of arterial wall calcifications for both anatomical regions. Image quality was rated on a 4-point Likert scale (1: excellent, 2: good, 3: sufficient, 4: poor) to avoid a midway option. Image datasets of both groups were blindly evaluated in random order using a hanging protocol on RA1000 PACS (GE Healthcare, Waukesha, USA) with a preset CT Angio window (W: 600 L: 300 HU) and 1 mm slice thickness.

Radiation Dose

Radiation dose exposure was estimated and compared using dose-length product (DLP) in mGy*cm, effective dose (E) in mSv, and size-specific dose estimates (SSDE) in mGy. The DLP was recorded from an automatically generated protocol, based on the

This document was downloaded for personal use only. Unauthorized distribution is strictly prohibited.

▶ **Table 1** Data of the patients included in the two groups.

▶ **Tab. 1** Patientendaten beider Gruppen.

Parameter	Total	Group A	Group B	p-value
Number of patients	108	52	56	
Age (years)	82.0 ± 7.6	80.2 ± 6.9	83.5 ± 7.4	0.009
BMI (kg/m²)	26.6 ± 5.6	27.2 ± 6.0	26.0 ± 5.3	0.508 (n. s.)
Sex (♂/♀)	59/49	31/21	28/28	0.553 (n. s.)
HR **mean** **range** (bpm)	74.8 ± 15.7	68.8 ± 11.0 42–89	80.3 ± 17.1 52–130	≤ 0.001
History of chronic cardiac arrhythmias (yes/no)	52/56	11/41	41/15	≤ 0.001
eGFR (ml/min/1.73 m²)	58.5 ± 18.6	59.7 ± 17.8	57.7 ± 17.4	0.648 (n. s.)
Scan time (s)	8.9 ± 4.8	13.9 ± 1.3	4.5 ± 0.3	≤ 0.001
Median kilovoltage (kV)	100	100	100	≤ 0.001
Contrast agent volume (ml)	101.7 ± 20.3	105.5 ± 17.6	100.7 ± 20.5	0.707 (n. s.)
Contrast agent volume distribution 60/80/100/120 ml	12/18/26/51	5/8/14/25	7/7/19/23	0.785 (n. s.)

CT dose index (CTDI). E was calculated from the DLP using the method proposed by the *European Guidelines on Quality Criteria for Computed Tomography* [17, 22]. SSDE was calculated by multiplying conversion coefficients as a function of the sum of the lateral and anteroposterior dimensions with CTDI [23].

Statistical Analysis

All data were tested for normal distribution using the Shapiro-Wilk test. Differences in body mass index (BMI), HR, and eGFR were tested for significance with an unpaired Student's t-test. To compare the distribution of male and female patients, the distribution of contrast agent volumes, and the distribution of patients with a history of atrial tachyarrhythmias, a chi-squared test (χ^2) was used. Differences in patient age, scan time, contrast agent volume, radiation dose, vessel attenuation, image noise, SNR, CNR, and subjective image quality scores between the two groups were tested for significance using the Mann-Whitney U-test. Differences in median kilovoltage (kV) were tested for significance using the median test. Interrater agreement of subjective image quality scores was compared between the two readers using Cohen's weighted kappa coefficient (κ_w). κ_w was interpreted as follows: < 0.00: poor, 0.00–0.20: slight, 0.21–0.40: fair, 0.41–0.60: moderate, 0.61–0.80: substantial, and 0.81–1.00: almost perfect agreement [24, 25]. A p-value below 0.05 was considered statistically significant. Values are presented as mean ± SD unless specified otherwise. SPSS (SPSS Mac, v. 20.0; IBM Corp., New York, NY) was used for all statistical analyses.

Results

Patient Characteristics

Patient characteristics are summarized in ▶ **Table 1**. There was no significant (n.s.) difference between the two groups with respect to BMI (p = 0.508), sex (p = 0.553), eGFR (p = 0.648), volume of contrast agent administered (p = 0.707), and distribution of contrast agent volumes administered (p = 0.785). HR was significantly faster in Group B with 80.3 ± 17.1 bpm (range 52–130 bpm) compared to 68.3 ± 11.0 bpm (range 42–89 bpm) in Group A (p = ≤ 0.001). Furthermore, significantly more patients in Group B had a history of atrial tachyarrhythmias with 41/56 compared to 11/52 in Group A (p ≤ 0.001). Despite the documented atrial tachyarrhythmias in 11 patients in Group A, these patients presented with sinus rhythm at the time of CT planning, making ECG gating feasible. Persistent AF was by far the most common atrial tachyarrhythmia in both groups with 6/52 in Group A and 19/56 in Group B, followed by paroxysmal AF (4/52 in Group A vs. 14/56 in Group B), atrial flutter (1/52 in Group A vs. 3/56 in Group B),

This document was downloaded for personal use only. Unauthorized distribution is strictly prohibited.

▶ **Table 2** Summary of objective image quality parameters measured in the aortic root and the abdominal aorta. The high-pitch protocol leads to significantly more image noise at the level of the aortic root.

▶ **Tab. 2** Zusammenfassung der objektiven Bildqualitätsparameter gemessen in der Aortenwurzel und der abdominalen Aorta. Das High-Pitch-Protokoll führt zu signifikant mehr Bildrauschen auf Höhe der Aortenwurzel.

Region	Parameter	Group A	Group B	p-value
Aortic root	Vessel (HU)	464.23	471.88	0.934 (n. s.)
	Muscle (HU)	43.53	42.15	0.898 (n. s.)
	Image noise (SD)	34.43	43.20	0.001
	CNR	12.22	9.95	0.003
	SNR	13.48	10.92	0.002
Abdominal aorta	Vessel (HU)	449.05	437.00	0.645 (n. s.)
	Muscle (HU)	49.95	31.49	≤ 0.001
	Image noise (SD)	44.49	44.68	0.620 (n. s.)
	CNR	8.97	9.08	0.895 (n. s.)
	SNR	10.09	9.78	0.540 (n. s.)

atrioventricular block (0/52 in Group A vs. 3/56 in Group B), and right bundle branch block (0/52 in Group A vs. 2/56 in Group B). Patients in Group B were significantly older by a mean of 3.3 years (p = 0.009). The scan time was significantly shorter in Group B with 4.5 ± 0.3 s compared to 13.9 ± 1.3 s (p = ≤ 0.001) in Group A. Even though the median tube voltage (kV) was 100 kV in both groups, the median test showed a statistically significant difference (p = ≤ 0.001) in kV between both groups. This is explained by the difference in distribution (Group A: 100 kV (n = 51) and 120 kV (n = 1) compared to Group B: 100 kV (n = 38), 120 kV (n = 12) and 135 kV (n = 6)).

Objective Image Analysis

At the level of the aortic root, we found statistically significant differences in image noise, SNR, and CNR in the aortic root between Groups A and B (p = 0.001, p = 0.002, and p = 0.003, respectively). There was no significant difference in vessel attenuation between the two groups (p = 0.934). Moreover, the attenuation values for background muscle did not differ significantly (p = 0.898).

At the level of the abdominal aorta, there was no significant difference in image noise, SNR, and CNR between Groups A and B (p = 0.620, p = 0.540, and p = 0.895, respectively). There was no significant difference in vessel attenuation between the two groups (p = 0.645). In contrast, the attenuation value for background muscle was significantly lower in Group B (p ≤ 0.001). All results are compiled in ▶ **Table 2**.

Subjective Image Analysis

Image quality ratings between the two groups were similar without significant differences for both readers. For the first reader, the mean scores were 1.53 ± 0.61 at the aortic root and 1.11 ± 0.46 at the abdominal aorta in Group A compared to 1.40 ± 0.50 and 1.05 ± 0.22 in Group B (p = 0.498 and 0.932). For the second reader, the mean scores were 1.47 ± 0.61 at the aortic root and 1.05 ± 0.23 at the abdominal aorta in Group A compared to 1.50 ± 0.68 and 1.08 ± 0.27 in Group B (p = 0.998 and 0.662). Exemplary images of the aortic root are shown in ▶ **Fig. 2**.

At the level of the aortic root, the interrater agreement was substantial in both groups but tended to be higher in Group B (Group A: κ_w = 0.644 and Group B: κ_w = 0.741). At the level of the abdominal aorta, the interrater agreement was substantial in both groups (Group A: κ_w = 0.787, and Group B: κ_w = 0.787). The results are compiled in ▶ **Table 3**.

Radiation Dose

The mean DLP was 790.90 ± 238.15 mGy*cm in Group A compared to 357.10 ± 200.25 mGy*cm in Group B. Correspondingly, the mean E was 13.44 ± 4.05 mSv in Group A compared to 6.07 ± 3.40 mSv in Group B, and the mean SSDE was 13.84 ± 2.94 mGy in Group A compared to 5.69 ± 2.27 mGy in Group B. Differences were statistically significant (p = ≤ 0.001) (see ▶ **Table 4**).

Discussion

In this single-center, retrospective cohort study, we compared the performance of a high-pitch non-ECG-gated CT protocol in patients with atrial tachyarrhythmia identified by ECG-monitoring immediately before CT with that of a prospective ECG-gated CT protocol in patients with normal sinus rhythm. Our results showed substantial interreader agreement in terms of the image quality of the aortic root between the two CT protocols. However, at the level of the aortic root, image noise was significantly increased, whereas the SNR and CNR were significantly decreased using the high-pitch non-ECG-gated CT protocol.

Atrial tachyarrhythmias are common in patients suffering from aortic valve stenosis and may substantially degrade CT image quality as inconsistent R-R intervals cause motion artifacts [26, 27]. As accurate imaging of the aortic root is essential for preprocedural TAVI/TAVR planning, the probability of nondiagnostic CT scans due to relevant motion artifacts needs to be minimized as much as possible. Some investigators thus advise not examining patients with atrial tachyarrhythmias on 16- or 64-slice CT scanners, reporting that diagnostic image quality is frequently not achieved in these patients [26, 28]. As a result, patients with atrial

This document was downloaded for personal use only. Unauthorized distribution is strictly prohibited.

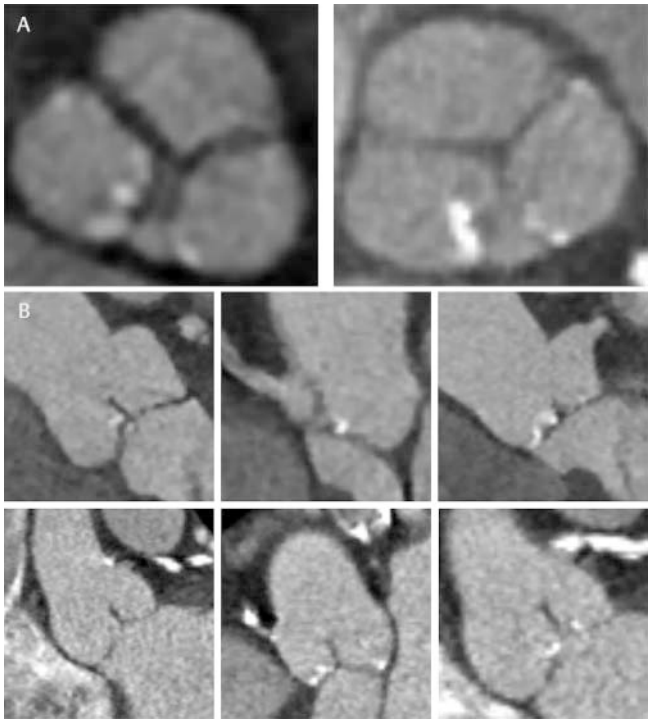

▶ **Fig. 2** **A** Sample images of the aortic valve in the aortic valve plane of representative patients examined with the prospective ECG-gated CT protocol in Group A (left) and the high-pitch non-ECG-gated protocol in Group B (right). **B** Sample images in the plane of sinus vasalva with the origin of the left and right coronary artery for representative patients examined with the prospective ECG-gated CT protocol in Group A (top) and the high-pitch non-ECG-gated protocol in Group B (bottom). Note that the patient in Group B has more coronary sclerosis.

▶ **Abb. 2** **A** Beispielbilder der Aortenklappe in der Aortenklappenebene repräsentativer Patient*innen, die mittels des prospektiv EKG-getriggerten Protokolls in Gruppe A (links) und des „high-pitch" nicht EKG-getriggerten Protokolls in Gruppe B (rechts) untersucht wurden. **B** Beispielbilder der Sinus vasalva-Ebene mit dem Ursprung der linken und rechten Koronararterie repräsentativer Patient*innen, die mittels des prospektiv EKG-getriggerten Protokolls in Gruppe A (oben) und des „high-pitch" nicht EKG-getriggerten Protokolls in Gruppe B (unten) untersucht wurden. Der Patient in Gruppe B hat eine vermehrte Koronarsklerose.

tachyarrhythmias, an HR above 65 bpm, or high HR variability have often been excluded from research trials investigating cardiac CT [10]. While recommendations to reduce artifacts in patients with atrial tachyarrhythmias are available for preprocedural CT imaging before TAVI/TAVR, a standardized protocol remains to be established [29]. Our results demonstrate that the use of a high-pitch non-ECG-gated CT protocol allows accurate imaging of the aortic root. At the level of the aortic root, interrater agreement tended to be higher using the high-pitch non-ECG-gated CT protocol, although the differences were not significant.

Furthermore, the high-pitch non-ECG-gated CT protocol resulted in a significant reduction of radiation exposure of 55 % compared to the ECG-gated protocol (from 13.44 mSv to 6.07 mSv). Dose reduction may appear secondary as TAVI/TAVR is currently generally performed in an elderly patient population [30, 31]. Nevertheless, two recent clinical trials published in *The New England Journal of Medicine* in 2019 have established the noninferiority of TAVI/TAVR compared to SAVR in low-risk patients. In these trials, TAVI/TAVR had a clear early safety benefit over SAVR in low-risk patients and was associated with earlier discharge from the hospital, faster recovery, and fewer rehospitalizations [1, 32]. This has set the stage for a new wave of TAVI/TAVR indications in younger patients.

An unexpected result of our analysis was that the attenuation of background muscle at the level of the abdominal aorta was significantly lower in Group B. While the reason behind this remains unclear, it might be attributable to the statistically significantly older age of the patients.

There are some limitations to our study. First, individuals were only examined with one of the two CT protocols. Therefore, intra-individual evaluation is not possible. Repetitive scanning has not been performed due to the retrospective design of the study and ethical concerns of radiation exposure for research purposes in patients. Furthermore, because our CT protocol was performed without ECG gating, the aortic root was imaged in a random phase of the cardiac cycle. Studies agree that the dimension and shape of the aortic annulus vary during the cardiac cycle and that the aortic diameter is larger in systole [29]. Thus, to avoid the risk of undersizing, annular measurements for TAVI/TAVR are most accurate in mid-systole [33]. In fact, a 2020 study of Capilli et al. comparing a prospectively ECG-gated high-pitch CT protocol with a retrospectively ECG-gated heart CT prior to TAVI/TAVR showed that the high-pitch protocol was associated with significant undersizing of annulus diameter in patients suffering from AF [29]. Moreover, alternative CT protocols are available and should be considered. First, as an alternative to prospective ECG gating, which is generally prone to artifacts in arrhythmic patients at the borders of the acquired slabs, retrospectively ECG-gated CT acquisition allows image reconstruction at numerous points within the R-R cycle using online or offline ECG-editing tools offered by vendors of selected CT scanners [26]. Second, third-generation CT scanners with wide scan coverage along the patient Z-axis and 16 cm detector coverage enable prospectively ECG-gated scanning of the entire heart within a single heartbeat. Therefore, scans that require image acquisition during more than one cardiac cycle are inherently sensitive to atrial tachyarrhythmias regardless of whether prospective or retrospective ECG-gating is used. A volume CT scanner covering the entire heart in an axial snapshot may yield more robust images while at the same time allowing further dose reduction [34]. While the first alternative, namely retrospective ECG gating, comes with an increase in radiation dose [16], the latter requires CT scanners that are not broadly available. Nonetheless, a 2018 study by Annoni et al. showed such state-of-the-art CT hardware to reduce potential artifacts in preprocedural TAVI/TAVR imaging, even in patients with AF (n = 15/115) [35]. However, the authors also acknowledged that their study population had a low incidence of AF, which might have influenced their results [35].

Based on our data, we conclude that the acquisition of a high-pitch non-ECG-gated CT scan allows motion-free assessment of the aortic root for TAVI/TAVR planning in patients suffering from atrial tachyarrhythmias. Therefore, it is a possible and dose-saving

This document was downloaded for personal use only. Unauthorized distribution is strictly prohibited.

▶ **Table 3** Summary of subjective image quality parameters. Subjective image quality is comparable for the two CT protocols.

▶ **Tab. 3** Zusammenfassung der subjektiven Bildqualitätsparameter. Die subjektive Bildqualität ist für die beiden CT-Protokolle vergleichbar.

Region	Rater 1	Rater 2
Aortic root		
Group A vs. Group B	1.53 vs. 1.40 1, n = 28 (53 %) vs. n = 37 (66 %) 2, n = 21 (42 %) vs. n = 15 (27 %) 3, n = 03 (05 %) vs. n = 04 (07 %) 4, n = 00 (00 %) vs. n = 00 (00 %)	1.47 vs. 1.50 1, n = 30 (58 %) vs. n = 35 (63 %) 2, n = 19 (37 %) vs. n = 14 (25 %) 3, n = 03 (05 %) vs. n = 07 (12 %) 4, n = 00 (00 %) vs. n = 00 (00 %)
p-value	0.498 (n.s.)	0.998 (n.s.)
κ_w Group A (p-value) κ_w Group B (p-value)	Substantial: 0.644 (0.002) Substantial: 0.741 (≤ 0.001)	
Abdominal aorta		
Group A vs. Group B	1.11 vs. 1.05 1, n = 46 (88 %) vs. n = 53 (95 %) 2, n = 05 (10 %) vs. n = 03 (05 %) 3, n = 01 (02 %) vs. n = 00 (00 %) 4, n = 00 (00 %) vs. n = 00 (00 %)	1.05 vs. 1.08 1, n = 49 (95 %) vs. n = 52 (92 %) 2, n = 03 (05 %) vs. n = 04 (08 %) 4, n = 00 (00 %) vs. n = 00 (00 %) 4, n = 00 (00 %) vs. n = 00 (00 %)
p-value	0.932 (n.s.)	0.662 (n.s.)
κ_w Group A (p-value) κ_w Group B (p-value)	Substantial: 0.787 (≤ 0.001) Substantial: 0.787 (≤ 0.001)	

▶ **Table 4** Summary of dose parameters. The high-pitch protocol requires significantly less dose compared to the standard protocol.

▶ **Tab. 4** Zusammenfassung der Dosisparameter. Das High-Pitch-Protokoll erfordert im Vergleich zum Standardprotokoll eine deutlich geringere Dosis.

Parameter	Group A	Group B	p-value
DLP (mGy*cm)	790.90 ± 238.15	357.10 ± 200.25	≤ 0.001
E (mSv)	13.44 ± 4.05	6.07 ± 3.40	≤ 0.001
SSDE (mGy)	13.84 ± 2.94	5.69 ± 2.27	≤ 0.001

alternative in patients in whom ECG-gated CT imaging is not feasible. Nonetheless, as the cardiac phase cannot be determined and alternatives are available, we recommend limiting the use of our study protocol to selected cases where ECG-gating is technically not possible. Ultimately, image quality prevails over cardiac phase selection as diastolic images may be of better quality and thus allow more reliable measurement.

Clinical Relevance of the Study

In this study, we show that a high-pitch non-ECG-gated CT scan protocol can yield motion-free images of the aortic root in a patient population presenting with atrial tachyarrhythmias at the time of CT planning. Despite the limitations of this method, this is of clinical relevance as many patients suffering from aortic valve stenosis have concomitant atrial tachyarrhythmias that may impair diagnostic performance of ECG-gated CT imaging and limit the possibility of ECG editing after retrospective ECG gating.

Conflict of Interest

S. Shnayien: nothing to disclose.
N.L. Beetz: nothing to disclose.
K.K. Bressem nothing to disclose.
B. Hamm: grant money from Abbott, AbbVie, Ablative Solutions, Accovion, Achaogen, Actelion Pharmaceuticals, ADIR, Advanced Sleep Research, Aesculap, AGO, Alexion Pharmaceuticals, Amgen, AO Foundation, Arbeitsgemeinschaft Internistische Onkologie, Arena Pharmaceuticals, ARMO BioSciences, art photonics, Astellas, AstraZeneca, B. Braun, BARD, Bayer, Berlin-Brandenburger Centrum für Regenerative Therapien, Berliner Krebsgesellschaft, BIOTRONIK, Bioven, Boehringer Ingelheim, Boston Biomedical, Bracco, BrainsGate, Bristol-Myers Squibb, Bundesministerium für Bildung und Forschung, Canon Medical Systems, Cascadian Therapeutics, Celgene, CellAct Pharma, Celldex Therapeutics, CeloNova Bio-Sciences, Charité Research Organisation, Chiltern, Clovis Oncology, Corvia Medical, Covance, Cubist Pharmaceuticals, Curevac, Curis, Daiichi Sankyō, DC Devices, Delcath Systems, Demira, DFG, Deutsche Krebshilfe, Deutsche Rheuma-Liga, Deutsche Stiftung für Herzforschung, DSM Nutritional Products, Dynavax Technologies, Eli Lilly and Company, Eisai, EORTC, Epizyme, Essex Pharma, EU Funding Programmes, Euroscreen, FIBREX Medical, Focused Ultrasound Surgery Foundation, Fraunhofer-Gesellschaft, Galena Biopharma, Galmed Pharmaceuticals, Ganymed Pharmaceuticals, GETNE, Genentech, Gilead Sciences, GlaxoSmithKline, Glycotope, Goethe-Universität Frankfurt am Main, Guerbet, Guidant Europe, Halozyme, Hewlett Packard, ICON, Idera Pharmaceuticals, Ignyta, Immunocore, Immunomedics, INC Research, Incyte, Innate Pharma, INSIGHTEC, inVentiv Health, iOMEDICO, Ionis Pharmaceuticals, Ipsen Pharma, IQVIA, ISA Pharmaceutical, ITM Solucin, Janssen Pharmaceutical, Kantar Health, Kartos Therapeutics, Karyopharm Therapeutics, Klinische Forschung Berlin-Mitte, Kite Pharma, InspireMD, Land

This document was downloaded for personal use only. Unauthorized distribution is strictly prohibited.

Berlin, Lion Biotechnology, LMU München, Lombard Medical, Loxo Oncology, LSK BioPartners, Lundbeck, Lux Biosciences, LYSARC, MacroGenics, MagForce, MedImmune, Medpace, MedPass International, Medtronic, Merck, Merrimack Pharmaceuticals, MeVis Medical Solutions, Millennium Pharmaceuticals, Mologen, MorphoSys, Monika Kutzner Stiftung Berlin, MSD, Neovacs, NewLink Genetics, Nexus Oncology, NIH, Novartis, Novocure, Nuvaira, Nuvisan, Ockham Oncology, OHIRC, Orion Corporation, Parexel, Perceptive, Pfizer, Pharmacyclics, PharmaCept, Pharmacyclics, PharmaMar, Philips, PIQUR Therapeutics, Pluristem Therapeutics, PPD, PneumRX, Portola Pharmaceuticals, PRA Health Sciences, Premier-Research, Provectus Biopharmaceuticals, PSI CRO, Pulmonx International, Quintiles, Regeneron Pharmaceuticals, Respicardia, Roche, Samsung, Sanofis, Seattle Genetics, Servier, SGS Life Science Services, Shire Human Genetic Therapies, Siemens, Silence Therapeutics, Spectranetics, Spectrum Pharmaceuticals, St. Jude Medical, Symphogen, Taiho Pharmaceutical, TauRx, Terumo Medical Corporation, Tesaro, TETEC, Teva, Theorem Clinical Research, Theradex, Threshold Pharmaceuticals, TNS Healthcare, UCB, Vertex Pharmaceuticals, Winicker Norimed, Wyeth Pharma, Xcovery and Zukunftsfond Berlin. The funding had no role in the study design, data collection and analysis, decision to publish, or preparation of the manuscript. S.M. Niehues: grant money from Bayer, Canon Medical Systems, Guerbet, and Teleflex Medical. The funding had no role in the study design, data collection and analysis, decision to publish, or preparation of the manuscript.

References

[1] Mack MJ, Leon MB, Thourani VH et al. Transcatheter Aortic-Valve Replacement with a Balloon-Expandable Valve in Low-Risk Patients. N Engl J Med 2019; 380: 1695–1705. doi:10.1056/NEJMoa1814052

[2] Leon MB, Smith CR, Mack M et al. Transcatheter aortic-valve implantation for aortic stenosis in patients who cannot undergo surgery. N Engl J Med 2010; 363: 1597–1607. doi:10.1056/NEJMoa1008232

[3] Ismail TF, Cheasty E, King L et al. High-pitch versus conventional cardiovascular CT in patients being assessed for transcatheter aortic valve implantation: a real-world appraisal. Open Heart 2017; 4: e000626. doi:10.1136/openhrt-2017-000626

[4] Achenbach S, Delgado V, Hausleiter J et al. SCCT expert consensus document on computed tomography imaging before transcatheter aortic valve implantation (TAVI)/transcatheter aortic valve replacement (TAVR). J Cardiovasc Comput Tomogr 2012; 6: 366–380. doi:10.1016/j.jcct.2012.11.002

[5] Blanke P, Weir-McCall JR, Achenbach S et al. Computed Tomography Imaging in the Context of Transcatheter Aortic Valve Implantation (TAVI)/Transcatheter Aortic Valve Replacement (TAVR): An Expert Consensus Document of the Society of Cardiovascular Computed Tomography. JACC Cardiovasc Imaging 2019; 12: 1–24. doi:10.1016/j.jcmg.2018.12.003

[6] Francone M, Budde RPJ, Bremerich J et al. CT and MR imaging prior to transcatheter aortic valve implantation: standardisation of scanning protocols, measurements and reporting-a consensus document by the European Society of Cardiovascular Radiology (ESCR). Eur Radiol 2020; 30: 2627–2650. doi:10.1007/s00330-019-06357-8

[7] Salgado RA, Leipsic JA, Shivalkar B et al. Preprocedural CT evaluation of transcatheter aortic valve replacement: what the radiologist needs to know. Radiographics 2014; 34: 1491–1514. doi:10.1148/rg.346125076

[8] Dahl JS, Brandes A, Videbæk L et al. Atrial fibrillation in severe aortic valve stenosis – Association with left ventricular left atrial remodeling. IJC Heart & Vessels 2014; 4: 102–107

[9] Greve AM, Gerdts E, Boman K et al. Prognostic importance of atrial fibrillation in asymptomatic aortic stenosis: the Simvastatin and Ezetimibe in Aortic Stenosis study. Int J Cardiol 2013; 166: 72–76. doi:10.1016/j.ijcard.2011.09.064

[10] Mushtaq S, Conte E, Melotti E et al. Coronary CT Angiography in Challenging Patients: High Heart Rate and Atrial Fibrillation. A Review. Acad Radiol 2019; 26: 1544–1549. doi:10.1016/j.acra.2019.01.022

[11] Andreini D, Pontone G, Mushtaq S et al. Image quality and radiation dose of coronary CT angiography performed with whole-heart coverage CT scanner with intra-cycle motion correction algorithm in patients with atrial fibrillation. Eur Radiol 2018; 28: 1383–1392. doi:10.1007/s00330-017-5131-2

[12] Kang TS, Park S. Antihypertensive Treatment in Severe Aortic Stenosis. J Cardiovasc Imaging 2018; 26: 45–53. doi:10.4250/jcvi.2018.26.e9

[13] Kalisz K, Buethe J, Saboo SS et al. Artifacts at Cardiac CT: Physics and Solutions. Radiographics 2016; 36: 2064–2083. doi:10.1148/rg.2016160079

[14] Horehledova B, Mihl C, Boswijk E et al. Retrospectively ECG-gated helical vs. non-ECG-synchronized high-pitch CTA of the aortic root for TAVI planning. PLoS One 2020; 15: e0232673. doi:10.1371/journal.pone.0232673

[15] Shnayien S, Bressem KK, Beetz NL et al. Feasibility of a High-Pitch Protocol for Transcatheter Aortic Valve Replacement Evaluation in Patients not Suitable for ECG-Gated CT. PREPRINT available at Research Square 2020; 1. doi:10.21203/rs.3.rs-123721/v1

[16] Shnayien S, Bressem KK, Beetz NL et al. Radiation Dose Reduction in Preprocedural CT Imaging for TAVI/TAVR Using a Novel 3-Phase Protocol: A Single Institution's Experience. Fortschr Röntgenstr 2020. doi:10.1055/a-1150-7646

[17] Wielandner A, Beitzke D, Schernthaner R et al. Is ECG triggering for motion artefact reduction in dual-source CT angiography of the ascending aorta still required with high-pitch scanning? The role of ECG-gating in high-pitch dual-source CT of the ascending aorta. Br J Radiol 2016; 89: 20160174. doi:10.1259/bjr.20160174

[18] Beitzke D, Wolf F, Edelhauser G et al. Computed tomography angiography of the carotid arteries at low kV settings: a prospective randomised trial assessing radiation dose and diagnostic confidence. Eur Radiol 2011; 21: 2434–2444. doi:10.1007/s00330-011-2188-1

[19] Apfaltrer P, Hanna EL, Schoepf UJ et al. Radiation dose and image quality at high-pitch CT angiography of the aorta: intraindividual and interindividual comparisons with conventional CT angiography. Am J Roentgenol 2012; 199: 1402–1409. doi:10.2214/ajr.12.8652

[20] Asano Y, Tada A, Shinya T et al. Utility of second-generation single-energy metal artifact reduction in helical lung computed tomography for patients with pulmonary arteriovenous malformation after coil embolization. Jpn J Radiol 2018; 36 (4): 285–294

[21] Wang R, Schoepf UJ, Wu R et al. Diagnostic accuracy of coronary CT angiography: comparison of filtered back projection and iterative reconstruction with different strengths. J Comput Assist Tomogr 2014; 38: 179–184. doi:10.1097/rct.0000000000000005

[22] Christner JA, Kofler JM, McCollough CH. Estimating effective dose for CT using dose-length product compared with using organ doses: consequences of adopting International Commission on Radiological Protection publication 103 or dual-energy scanning. Am J Roentgenol 2010; 194: 881–889. doi:10.2214/ajr.09.3462

[23] Boone JM SK, Cody DD, McCollough CH et al. Size-specific dose estimates (SSDE) in pediatric and adult body CT examinations. Report of AAPM Task Group 2011: 204

[24] Mandrekar JN. Measures of interrater agreement. J Thorac Oncol 2011; 6: 6–7. doi:10.1097/JTO.0b013e318200f983

[25] Landis JR, Koch GG. The measurement of observer agreement for categorical data. Biometrics 1977; 33: 159–174

[26] Min JK, Berman DS, Leipsic J. Multimodality imaging for transcatheter aortic valve replacement. Springer Science & Business Media 2013

[27] Litmanovich DE, Ghersin E, Burke DA et al. Imaging in Transcatheter Aortic Valve Replacement (TAVR): role of the radiologist. Insights Imaging 2014; 5: 123–145. doi:10.1007/s13244-013-0301-5

This document was downloaded for personal use only. Unauthorized distribution is strictly prohibited.

[28] Feuchtner G. Imaging of cardiac valves by computed tomography. Scientifica (Cairo) 2013; 2013: 270579. doi:10.1155/2013/270579

[29] Capilli F, Benndorf M, Soschynski M et al. Assessment of aortic annulus dimensions for transcatheter aortic valve replacement (TAVR) with high-pitch dual-source CT: Comparison of systolic high-pitch vs. multiphasic data acquisition. Eur J Radiol 2020; 133: 109366. doi:10.1016/j.ejrad.2020.109366

[30] Matsumoto S, Yamada Y, Hashimoto M et al. CT imaging before transcatheter aortic valve implantation (TAVI) using variable helical pitch scanning and its diagnostic performance for coronary artery disease. Eur Radiol 2017; 27: 1963–1970. doi:10.1007/s00330-016-4547-4

[31] Salgado R, El Addouli H, Budde RPJ. Transcatheter Aortic Valve Implantation: The Evolving Role of the Radiologist in 2021. Fortschr Röntgenstr 2021; 193: 1411–1425. doi:10.1055/a-1645-1873

[32] Popma JJ, Deeb GM, Yakubov SJ et al. Transcatheter Aortic-Valve Replacement with a Self-Expanding Valve in Low-Risk Patients. N Engl J Med 2019; 380: 1706–1715. doi:10.1056/NEJMoa1816885

[33] Murphy DT, Blanke P, Alaamri S et al. Dynamism of the aortic annulus: Effect of diastolic versus systolic CT annular measurements on device selection in transcatheter aortic valve replacement (TAVR). J Cardiovasc Comput Tomogr 2016; 10: 37–43. doi:10.1016/j.jcct.2015.07.008

[34] Kang EJ. Clinical Applications of Wide-Detector CT Scanners for Cardiothoracic Imaging: An Update. Korean J Radiol 2019; 20: 1583–1596. doi:10.3348/kjr.2019.0327

[35] Annoni AD, Andreini D, Pontone G et al. CT angiography prior to TAVI procedure using third-generation scanner with wide volume coverage: feasibility, renal safety and diagnostic accuracy for coronary tree. Br J Radiol 2018; 91: 20180196. doi:10.1259/bjr.20180196

This document was downloaded for personal use only. Unauthorized distribution is strictly prohibited.