

Case Report: Deficiency of Adenosine Deaminase 2 (DADA2) as a Cause of Brainstem Stroke in a 3-Year-Old Girl and the Importance of Early Fast-Track Genetic Diagnostics to Influence Therapy

Janina Gburek-Augustat¹ Konrad Platzer² Isabell Schumann² Sven Starke³
Michael Steven Hershfield⁴ Ina Sorge⁵ Andreas Merckenschlager¹

¹Division of Neuropaediatrics, Hospital for Children and Adolescents, University Hospital Leipzig, Leipzig, Germany

²Institute of Human Genetics, University of Leipzig Medical Center, Leipzig, Germany

³Department of Paediatric Oncology, Haematology and Haemostaseology, Hospital for Children and Adolescents, University Hospital Leipzig, Leipzig, Germany

⁴Department of Medicine and Biochemistry, Duke University Medical Center, Durham, North Carolina, United States

⁵Department of Pediatric Radiology, Hospital for Children and Adolescents, University Hospital Leipzig, Leipzig, Germany

Address for correspondence Janina Gburek-Augustat, Division of Neuropaediatrics, Hospital for Children and Adolescents, University Hospital Leipzig, Liebigstrasse 20a, D- 04104 Leipzig, Germany (e-mail: Janina.Gburek-Augustat@medizin.uni-leipzig.de).

Neuropediatrics 2022;53:432–435.

Abstract

Deficiency of adenosine deaminase 2 (DADA2) is a rare Mendelian, autoinflammatory multiorgan disease. We report the case of a 3.8-year-old female patient who was admitted with an acute brainstem stroke and was diagnosed with DADA2 by early initiation of exome sequencing. We recommend that DADA2 and a genetic workup should be taken into account, when evaluating strokes in children even if no other than neurological symptoms are evident.

Keywords

- ▶ DADA2
- ▶ fast-track exome sequencing
- ▶ inflammation
- ▶ vasculitis
- ▶ brainstem
- ▶ early stroke

Introduction

Deficiency of adenosine deaminase 2 (DADA2) is a rare Mendelian, autoinflammatory multiorgan disease inherited in an autosomal recessive manner. It was first described in 2014.¹ Loss-of-function mutations in the *ADA2* gene (formerly called *CECR1*) lead to a deficiency of the enzyme adenosine deaminase 2 (ADA2), which has complex immunological

functions and is also a growth factor.^{2,3} The frequency of pathogenic variants is approximately 1:1,000 or lower.^{4,5} Jee et al⁶ revealed an estimated carrier frequency of at least 1 in 236 individuals, corresponding to an expected DADA2 disease prevalence of 1:222,000 individuals. Penetrance is incomplete. There is no clear genotype-phenotype correlation and the phenotype varies widely even within a family.^{3,7} Most patients present clinical symptoms in the first decade

received

March 7, 2022

accepted after revision

July 6, 2022

accepted manuscript online

July 11, 2022

article published online

September 22, 2022

© 2022. Thieme. All rights reserved.

Georg Thieme Verlag KG,

Rüdigerstraße 14,

70469 Stuttgart, Germany

DOI <https://doi.org/>

10.1055/a-1896-5817.

ISSN 0174-304X.

of life and can have a variety of different symptoms with underlying vasculopathy and inflammation, bone marrow failure, or immunodeficiency with overlapping phenotypes. Vasculitis of the small and medium-sized arteries leads to the neurologically predominant symptoms of DADA2. Lacunar ischemic infarcts in the deep-brain nuclei, midbrain, and/or brainstem are very typical.^{8,9} Strokes occur in about one-third of the patients, often in early childhood and may recur and leading to serious residual damage.¹⁰ Since other organs might also be affected by vasculitis and inflammation, the possible clinical symptoms are multifaceted. In addition, hematologic symptoms could occur and immunodeficiency may develop.³

Treatment with tumor necrosis factor (TNF) blockers (etanercept, adalimumab, infliximab) has been well established.^{8,11} Stem cell transplantation is a therapeutic modality in hematologic manifestations and severe combined immunodeficiency.³ Gene therapy may also be a treatment option for young patients in the future.¹²

Case

We presented the case of a 3 years and 8 months old girl child patient with DADA2 (→ **Table 1**). The child's previous medical

history was unremarkable except for thrombocytopenia (28 Tsd/ μ L) in the neonatal period. She received a platelet concentrate on the first day of life. Further on, the platelets were in the low-normal reference range. The parents were not consanguine and both were healthy, as well as the older sister.

Without any prodromal symptoms the girl developed right-sided oculomotor nerve paresis (→ **Fig. 1**), left-sided central facial paresis, and left-sided hemiataxia. She also was somnolent and irritable. Two hours after the onset of symptoms, she was brought to the hospital and an acute brainstem pathology was diagnosed. Emergency magnetic resonance imaging (MRI) of the brain showed a diffusion-weighted imaging lesion on the right side of the midbrain with a decrease in apparent diffusion coefficient (ADC), indicative of cytotoxic edema. In the beginning, this can be seen in inflammatory (infectious and demyelinating), as well as ischemic lesions. Vasogenic edema with increased ADC may then come later (→ **Fig. 2**). It was difficult to differentiate whether this was a local ischemia or an inflammatory process. Given the likelihood in early childhood, we had tended to favor inflammation and treated accordingly. We decided against thrombolysis and in favor of high-dose treatment with intravenous methylprednisolone (20 mg/kg)

Table 1 Tabular listing of the symptoms of our patient

Acute clinical presentation at 3.8 years of age	Oculomotor nerve palsy right, central facial nerve palsy left, hemiataxia left
Medical history	Thrombocytopenia (28 thousand/ μ L) at the first day postpartum, otherwise healthy, no special conditions
Genetic findings	Compound heterozygous variants: paternally inherited Chr22:17690409-17690410; NM_001282225.2:c.158del; p.(Asn53Thrfs*12) probably pathogenic (PVS1, PM2_SUP) and maternally inherited chr22:17690566; NM_001282225.2:c.2T > A, p.0? variant of unclear significance (PVS1_SUP, PM2_SUP, PM3 MOD)
ADA2 enzymatic activity	0,0 mU/g protein in plasma
MRI	Mesencephalic lesion
Vasculitis	Apart from brainstem stroke, no other symptoms
Immunology	IgA deficiency (0.26 g/L), IgM deficiency (0.12 g/L) (normalized 10 months after starting adalimumab: IgA 0.98 g/L, IgM 0.31 g/L)
Pathological inflammation parameters	CRP 10.38 mg/L, IL-2 receptor 1370.0 U/mL, SAA 23.3 mg/L, ferritin 94.8 ng/mL, strong type 1 interferon activation in the blood
Immunophenotyping	Th17-like cells marginally decreased, also in the controls under adalimumab. Otherwise normal number and distribution of lymphocytes, monocytes, and granulocytes, as well as T and NK cells
B cell differentiation	Slightly decreased naive and memory B cells with otherwise normal population distribution
T cell differentiation	Age-appropriate distribution and activation pattern of the measured subpopulations
Vaccination titers	Present for the tested titers (measles, varicella, hepatitis B, tetanus, and diphtheria)
Hematology	Mild hypoplasia of erythropoiesis in bone marrow smear with unremarkable peripheral blood smear
Cerebrospinal fluid	Oligoclonal bands positive

Abbreviations: ADA2, adenosine deaminase 2; CRP, C-reactive protein; Ig, immunoglobulin; IL, interleukin; MRI, magnetic resonance imaging; SAA, serum amyloid A.

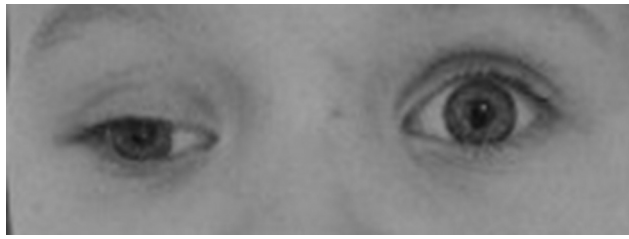

Fig. 1 Patient 1 week after stroke: the picture shows the ipsilateral oculomotor nerve palsy on the right (gaze down and out, dilated pupil).

for 5 days. Due to delayed improvement immunoglobulins (2 g/kg over 2 days) were administered secondly because of the possibility of Bickerstaff encephalitis. When steroids and immunoglobulins failed to produce a therapeutic breakthrough and MRI on day 10 showed demarcation in mid-brain, we considered it to be occlusion of the small arteries. The patient subsequently received acetylsalicylic acid (ASA) for secondary stroke prophylaxis. The initial diagnostic tests did not show any anomalies, apart from detectable oligoclonal bands in the cerebrospinal fluid. Subsequent genetic testing revealed the cause. Single exome sequencing identified two compound heterozygous variants in the *ADA2* gene: the likely pathogenic variant c.158del, p.(Asn53Thrfs*12) based on the American College of Medical Genetics and Genomics criteria¹³ and the variant of unknown significance (VUS) variant c.2T>A, p.(0?). Compound heterozygosity could be determined from single exome sequencing due to the close proximity of the variants (► **Supplementary Fig. S1**, available in the online version only). The extended diagnostic workup revealed a severe deficiency of plasma ADA2 enzyme activity of 0.0 mU/g protein, as measured in extracts of dried plasma spots as described in Ben-Ami et al.¹⁴ The patient also

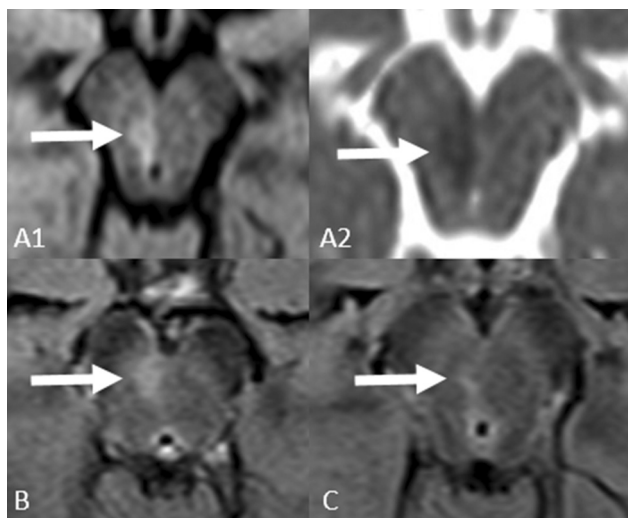


Fig. 2 Magnetic resonance imaging (MRI) of the patient's brain: Circumscribed small diffusion disturbance in the right cerebral peduncle on day 1 is demonstrated in (A1) (diffusion-weighted imaging [DWI]) and (A2) (apparent diffusion coefficient [ADC]). In (B), demarcation of the previously diffusion-disturbed lesion on day 10 in fluid-attenuated inversion recovery (FLAIR) is shown. In (C), there is almost complete regression of the finding on day 72 in FLAIR.

had immunoglobulin (Ig) A (0.26 g/L) and IgM (0.12 g/L) deficiency, slightly decreased low naive and memory B cells (consistent with IgM deficiency) and slightly decreased Th17 lymphocytes, and a strong type 1 interferon activation in the blood. Bone marrow biopsy showed mild hypoplasia of erythropoiesis.

Based on the ADA2 deficiency in plasma, DADA2 from the vasculitis phenotype was confirmed. In light of this new information, the VUS in the *ADA2* gene could be reclassified as pathogenic and the likely pathogenic variant elevated to pathogenic. TNF-blocker treatment with adalimumab was started. Prophylaxis with ASA was stopped, because antiplatelet agents are known to increase the risk of hemorrhagic stroke in DADA2.^{3,16,17} After a 18-month follow-up period, the patient is symptom-free except for the residual oculomotor nerve palsy, which has improved only slightly. Further MRI examinations provided no new abnormalities.

Discussion

Lacunar subcortical stroke in early childhood and brainstem stroke in particular is suspicious of DADA2. It can be diagnosed in the case of compound heterozygosity by genetic testing and, alternatively, by enzymatic confirmation of ADA2 deficiency.

With our case report, we hope to raise awareness of this quite recently described disease.¹ Skin manifestations (e.g., livedo racemosa, erythema nodosum), as reported in the majority of patients with DADA2, were not present in our patient. We report on our patient's neurological symptoms, which initially appeared to be isolated. In the early stage, it was difficult to differentiate between an ischemic and inflammatory process in the brainstem on the basis of the MRI. ADA2 deficiency leads to reduced vascular integrity and perivascular inflammation by proinflammatory cytokines (TNF and interleukin-1 β) and subsequently to lacunar ischemic strokes. It is probably a mixed picture due to the underlying pathophysiology. Detection of oligoclonal bands in cerebral spinal fluid indicated chronic central nervous system inflammation.

Neurological symptoms can precede other organ manifestations in DADA2.¹⁵ We would like to highlight this. In the more detailed workup, immunological abnormalities also were revealed but had to be specifically searched for in an almost uneventful medical history of our patient. We believe that thrombocytopenia in the neonatal period can be retrospectively considered as the first symptom of the disease. However, it did not play any further role in our patient.

The diagnosis of DADA2 has therapeutic implications.^{3,16,17} If DADA2 is diagnosed at an early stage, treatment can be initiated quickly, complications avoided, and outcomes improved. There is wide agreement that treatment with TNF blockers is indicated in the vasculitis phenotype and stem cell transplantation is necessary for patients with severe immunodeficiency in DADA2. However, clinically relevant questions remain open. We believe a patient registry is necessary to find yet unanswered questions, assess long-term outcomes, and optimize patient care.

Early stroke always needs a thorough search for various possible underlying causes. This case is a striking example how today's genetic diagnostics can lead to early diagnosis in rare diseases. If the cause cannot be clearly determined and several genetic and metabolic diseases are considered, fast-track genetic diagnostics with exome sequencing should be part of the workup of childhood stroke to capture a broad spectrum of differential diagnoses. If DADA2 is suspected, targeted measurement of ADA2 activity in plasma may provide a fast result. Should an ADA2 deficiency be detected, in a second step, however, genetic confirmation diagnostics should then follow.

Conclusion

Strokes of unexplained etiology in the first decade of life and especially lacunar and brainstem infarcts should include testing for DADA2.

Funding

None.

Conflict of Interest

None declared.

References

- Zhou Q, Yang D, Ombrello AK, et al. Early-onset stroke and vasculopathy associated with mutations in ADA2. *N Engl J Med* 2014;370(10):911–920
- Ombrello AK, Qin J, Hoffmann PM, et al. Treatment strategies for deficiency of adenosine deaminase 2. *N Engl J Med* 2019;380(16):1582–1584
- Pinto B, Deo P, Sharma S, Syal A, Sharma A. Expanding spectrum of DADA2: a review of phenotypes, genetics, pathogenesis and treatment. *Clin Rheumatol* 2021;40(10):3883–3896
- Schnappauf O, Zhou Q, Moura NS, et al. Deficiency of adenosine deaminase 2 (DADA2): hidden variants, reduced penetrance, and unusual inheritance. *J Clin Immunol* 2020;40(06):917–926
- Karczewski KJ, Francioli LC, Tiao G, et al; Genome Aggregation Database Consortium. The mutational constraint spectrum quantified from variation in 141,456 humans. *Nature* 2020;581(7809):434–443. Erratum in: *Nature*. 2021 Feb;590(7846):E53. Erratum in: *Nature* 2021;597(7874):E3–E4
- Jee H, Huang Z, Baxter S, et al. Comprehensive analysis of ADA2 genetic variants and estimation of carrier frequency driven by a function-based approach. *J Allergy Clin Immunol* 2022;149(01):379–387
- Van Montfrans JM, Hartman EA, Braun KP, et al. Phenotypic variability in patients with ADA2 deficiency due to identical homozygous R169Q mutations. *Rheumatology (Oxford)* 2016;55(05):902–910
- Moens L, Hershfield M, Arts K, Aksentijevich I, Meyts I. Human adenosine deaminase 2 deficiency: a multi-faceted inborn error of immunity. *Immunol Rev* 2019;287(01):62–72
- Bulut E, Erden A, Karadag O, Oguz KK, Ozen S. Deficiency of adenosine deaminase 2; special focus on central nervous system imaging. *J Neuroradiol* 2019;46(03):193–198
- Lee PY. Vasculopathy, immunodeficiency, and bone marrow failure: the intriguing syndrome caused by deficiency of adenosine deaminase 2. *Front Pediatr* 2018;6:282
- Caorsi R, Penco F, Grossi A, et al. ADA2 deficiency (DADA2) as an unrecognised cause of early onset polyarteritis nodosa and stroke: a multicentre national study. *Ann Rheum Dis* 2017;76(10):1648–1656. Erratum in: *Ann Rheum Dis*. 2019;78(7):e73. PMID: 28522451
- Zoccolillo M, Brigida I, Barzaghi F, et al. Lentiviral correction of enzymatic activity restrains macrophage inflammation in adenosine deaminase 2 deficiency. *Blood Adv* 2021;5(16):3174–3187
- Richards S, Aziz N, Bale S, et al; ACMG Laboratory Quality Assurance Committee. Standards and guidelines for the interpretation of sequence variants: a joint consensus recommendation of the American College of Medical Genetics and Genomics and the Association for Molecular Pathology. *Genet Med* 2015;17(05):405–424
- Ben-Ami T, Revel-Vilk S, Brooks R, et al. Extending the clinical phenotype of adenosine deaminase 2 deficiency. *J Pediatr* 2016;177:316–320
- Robinson JT, Thorvaldsdóttir H, Wenger AM, Zehir A, Mesirov JP. Variant review with the Integrative Genomics Viewer. *Cancer Res* 2017;77(21):e31–e34
- Meyts I, Aksentijevich I. Deficiency of adenosine deaminase 2 (DADA2): updates on the phenotype, genetics, pathogenesis, and treatment. *J Clin Immunol* 2018;38(05):569–578
- Elbracht M, Mull M, Wagner N, et al. Stroke as initial manifestation of adenosine deaminase 2 deficiency. *Neuropediatrics* 2017;48(02):111–114