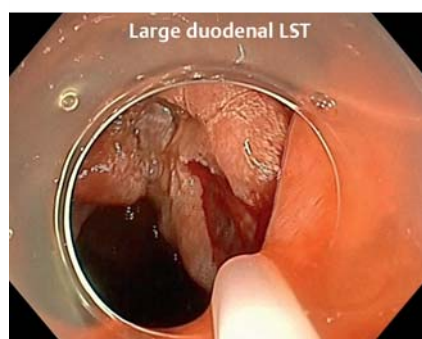
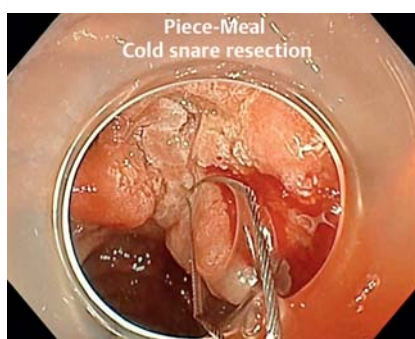
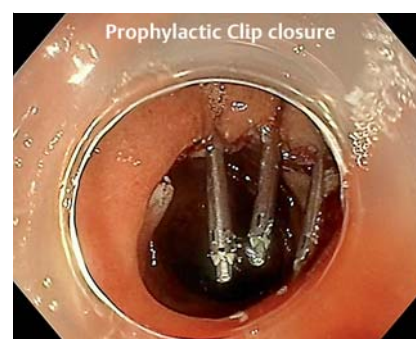Cold-snare endoscopic mucosal resection of large duodenal laterally spreading tumors: is cold the future gold standard?

**OPEN
ACCESS**


► **Fig. 1** Large duodenal laterally spreading tumor.



► **Fig. 2** Piece-meal cold snare resection of the laterally spreading tumor.



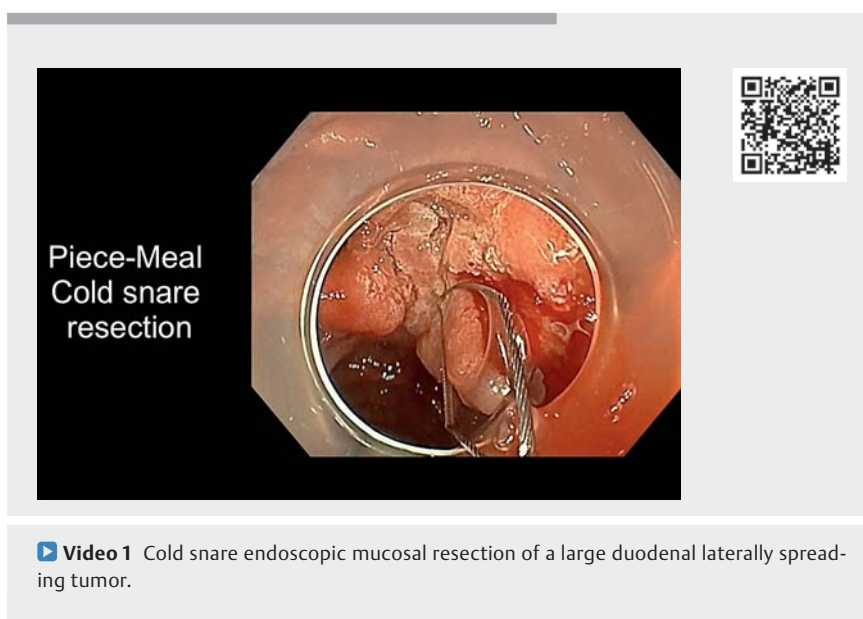
► **Fig. 3** Prophylactic clip closure.

Large laterally spreading tumors (LSTs) of the duodenum are considered by most experts to be very challenging benign lesions requiring endoscopic resection. Piecemeal endoscopic mucosal resection (EMR) is the gold standard but leads to a high recurrence rate and a risk of delayed bleeding.

Piecemeal cold snare EMR [1] has recently been reported as a promising new tool for excising sessile serrated lesions with the same efficiency as classic piecemeal EMR but with a better safety profile, with no perforations and a significantly lower rate of delayed post-EMR bleeding. Here, we report the case of a large 4-cm LST of the duodenum treated with cold snare piecemeal EMR (► **Fig. 1**, ► **Fig. 2**, ► **Fig. 3**, ► **Video 1**).

The tumor was resected with a classic hexagonal pure cold snare in a piecemeal fashion. Minor intraprocedural bleeding was tolerated with a regular waterjet wash. Complete macroscopic removal was possible in 15 minutes, and the scar was closed with large hemostatic clips. No postprocedural complications occurred and no residual adenomas were detected at the 6-month follow-up gastroscopy.

Cold snare piecemeal resection could become a new standard of care for large



► **Video 1** Cold snare endoscopic mucosal resection of a large duodenal laterally spreading tumor.

duodenal adenomas [2], as this technique decreased the high risk of complications in this location (perforation, delayed bleeding, or postpolypectomy syndrome). A prospective observational Italian study is ongoing to evaluate this procedure for large duodenal adenomas (NCT04783961).

Endoscopy_UCTN_Code_CPL_1AH_2AZ

Competing interests

The authors declare that they have no conflict of interest.

The authors

Sophie Geyl¹, Marion Schaefer², Mathieu Pioche³, Martin Dahan¹, Romain Legros¹, Jérémie Albouys¹, Jérémie Jacques^{1,4}

- 1 Service d'Hépatogastro-entérologie, CHU Dupuytren, Limoges, France
- 2 Service d'Hépatogastro-entérologie, CHU de Nancy, Nancy, France
- 3 Service d'Hépatogastro-entérologie, Hôpital Edouard Herriot, CHU Lyon, France
- 4 BioEM, XLim, UMR 7252, CNRS, Limoges, France

Corresponding author

Jérémie Jacques, MD

Service d'Hépatogastro-entérologie, CHU Dupuytren, Limoges University Hospital, 2 Avenue Martin Luther King, 87042 Limoges, France

jeremiejacques@gmail.com

References

- [1] van Hattem WA, Shahidi N, Vosko S et al. Piecemeal cold snare polypectomy versus conventional endoscopic mucosal resection for large sessile serrated lesions: a retrospective comparison across two successive periods. *Gut* 2021; 70: 1691–1697
- [2] Ochiai Y, Kato M, Kiguchi Y et al. Current status and challenges of endoscopic treatments for duodenal tumors. *Digestion* 2019; 99: 21–26

Bibliography

Endoscopy 2022; 54: E894–E895

DOI 10.1055/a-1841-5607

ISSN 0013-726X

published online 1.7.2022

© 2022. The Author(s).

This is an open access article published by Thieme under the terms of the Creative Commons Attribution-NonDerivative-NonCommercial License, permitting copying and reproduction so long as the original work is given appropriate credit. Contents may not be used for commercial purposes, or adapted, remixed, transformed or built upon. (<https://creativecommons.org/licenses/by-nc-nd/4.0/>)

Georg Thieme Verlag KG, Rüdigerstraße 14, 70469 Stuttgart, Germany



ENDOSCOPY E-VIDEOS

<https://eref.thieme.de/e-videos>



Endoscopy E-Videos is an open access online section, reporting on interesting cases and new techniques in gastroenterological endoscopy. All papers include a high quality video and all contributions are freely accessible online. Processing charges apply (currently EUR 375), discounts and waivers acc. to HINARI are available.

This section has its own submission website at

<https://mc.manuscriptcentral.com/e-videos>