

# Metabolic Status Modulates Choroidal Thickness – A Possible Early Indicator for Diabetic Eye Complications?

## Authors

Svenja Meyhöfer<sup>1,2,3</sup>, Britta Wilms<sup>1,2</sup>, Rodrigo Chamorro<sup>1,4</sup>, Armin Knaak<sup>1</sup>, Eleni Pappa<sup>1,2,3</sup>, Agnetha S. Schulz<sup>1,2,3</sup>, Anna-Josephin Pagels<sup>5</sup>, Maria Schröder<sup>5</sup>, Neele Kaluzny<sup>5</sup>, Hans-Jürgen Grein<sup>5</sup>, Sebastian M. Meyhöfer<sup>1,2</sup>

## Affiliations

- 1 Institute for Endocrinology & Diabetes, University of Lübeck, Lübeck, Germany
- 2 German Center for Diabetes Research, Neuherberg, Germany
- 3 Department of Internal Medicine 1, Endocrinology & Diabetes, University of Lübeck, Lübeck, Germany
- 4 Department of Nutrition, School of Medicine, University of Chile, Santiago, Chile
- 5 Section of medical optics, Technische Hochschule Lübeck, Lübeck, Germany

received 15.11.2021

revised 23.03.2022

accepted 19.04.2022

published online 27.06.2022

## Bibliography

Exp Clin Endocrinol Diabetes 2022; 130: 789–792

DOI 10.1055/a-1831-0265

ISSN 0947-7349

© 2022, Thieme. All rights reserved.

Georg Thieme Verlag, Rüdigerstraße 14,  
70469 Stuttgart, Germany

## correspondence

Dr. med. Svenja Meyhöfer  
Institute for Endocrinology & Diabetes  
University of Luebeck  
Ratzeburger Allee 160  
23538 Luebeck  
Germany  
Tel.: 0049-(0)451 3101 7864, Fax: 0049-(0)451 3101 7877  
svenja.meyhoefer@uni-luebeck.de

## ABSTRACT

**Objective** To investigate the impact of metabolic status on choroidal thickness (ChT) in healthy subjects, patients with obesity, and type 2 diabetes.

**Design and Methods** Fasting blood glucose, insulin, insulin-like growth factor-1 (IGF-1), and ChT measured by optical coherence tomography were assessed in healthy normal-weight (n = 17), obese participants (n = 20), and obese participants with T2D (n = 16).

**Results** ChT increased in obese participants and obese participants with T2D as compared to healthy normal-weight participants (P < 0.0001). A negative correlation was observed between IGF1 and ChT (r = -0.268, P = 0.050) for all cohorts. Furthermore, body mass index (BMI; R<sup>2</sup> = 0.209; P = 0.002; beta = 0.388) and model assessment-estimated insulin resistance (HOMA-IR; R<sup>2</sup> = 0.074; P = 0.015; beta = 0.305) were independent variables of ChT, explaining 20.9 and 7.4% of its variance (both p < 0.016), whereas age, sex, and IGF-1 were not significant confounders of ChT (p > 0.975).

**Conclusion** ChT is associated with metabolic characteristics, i. e., BMI and HOMA-IR. Due to the key role of choroidal function in retinal physiology, future studies are needed to evaluate whether metabolic traits, ChT, and potential metabolic eye complications are mechanistically linked.

## Introduction

Diabetic macular edema (DME) is a serious complication of diabetes and is currently one of the leading causes of visual impairment and blindness. Cases of diabetes complications such as DME and diabetic retinopathy (DR) are rising [1], and so far, restoring cell loss of the retina and reverse visual impairment has not been possible [2]. Therefore, new strategies to detect early retinal changes are urgently needed to prevent the development of DME and DR.

Physiologically, retinal substrate supply and oxidative stress protection are dependent on regular choroidal function [3]. The choroid represents the only source of metabolic exchange for the avascular fovea centralis due to a high blood flow. Reduced choroidal blood circulation can result in retinal dysfunction resulting in vision loss [4]. Alterations in choroidal vascularity caused by tight junction disassembly and endothelial cell-mediated leukostasis are considered major mechanisms for retinal edema and ischemia [5]. Fur-

thermore, DME is caused by leakage of fluid from the choroidal vessels. The fluid accumulates within the neurosensory retina resulting in an increased thickness of the central retina [6]. The choroid also maintains the highly metabolically active photoreceptor cells, and hypoperfusion leads to outer retina dysfunction [5]. Precise and three-dimensional retinal and choroidal morphology can be assessed by optical coherence tomography (OCT) with a high resolution of 7  $\mu\text{m}$  optical and 3.5  $\mu\text{m}$  digital axis [7]. To diagnose DME, measuring choroidal thickness (ChT) by OCT represents a well-established method in clinical practice. Measurements by OCT have been evaluated to be more precise than conventional diagnostic methods such as stereoscopic slit lamps fundus examination [8]. However, OCT is only used in clinical practice to assess DME when DR is already diagnosed or to follow up the treatment of DR. It is known that ChT increases in progressive DR and decreases after treatment of DR. In addition, ChT is thicker in patients with DME [9]. While patients with type 1 diabetes are at a higher risk of developing DR, patients with type 2 diabetes (T2D), especially when treated with insulin, tend to develop DME. However, the development of DME is due to changes in the choroid and its blood flow [10]. Thus, we hypothesize ChT as a parameter to detect early metabolic complications in posterior structures of the eye. Therefore, this pilot study aimed to assess fasting state ChT in healthy normal-weight controls and compare it to measures in healthy obese people as well as in patients with T2D.

## Methods

### Subjects

Three respective cohorts of participants (healthy normal-weight, healthy obese with BMI  $\geq 30 \text{ kg/m}^2$ , and obese with T2D) were enrolled in this mono-center study at the Metabolic Core Unit of the Centre of Brain, Behavior and Metabolism, University of Luebeck, Germany. T2D was diagnosed according to the American Diabetes Association criteria [11]. Healthy normal-weight subjects had no history of chronic illness and long-term medication. All patients with T2D were treated with insulin and oral antidiabetics. Exclusion criteria for all groups were substance abuse, any ophthalmological diagnosis or previous treatment, myopia or hyperopia with a spherical

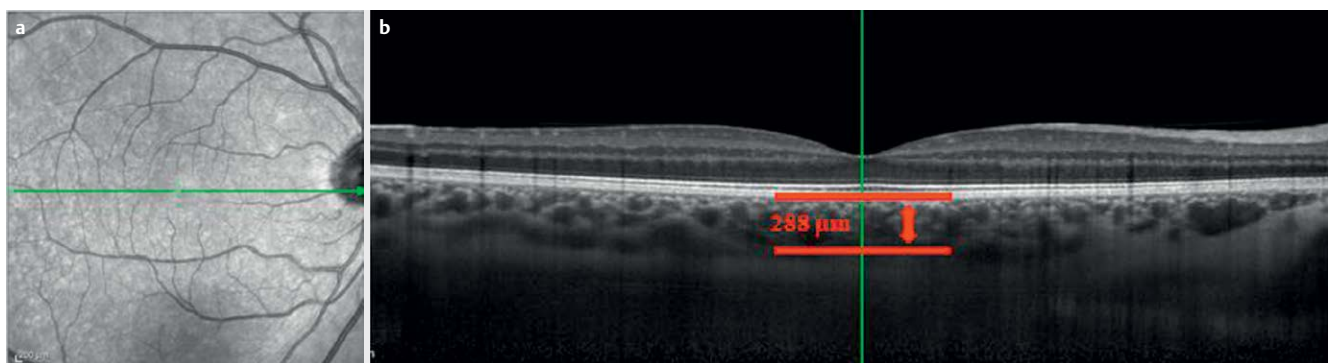
equivalent of  $< -7.0 \text{ dpt.}$  or  $> +7.0 \text{ dpt.}$ , wearing contact lenses in the past 12 h, a glomerular filtration rate  $< 60 \text{ mL/min./1.73}$ , any type of insulin-deficient diabetes, and a blood pressure  $> 140/90 \text{ mmHg}$ . Further exclusion criteria for healthy normal-weight and healthy obese participants were medication and acute or chronic illness of any kind. The study protocol was approved by the ethics committee of the University of Luebeck according to the declaration of Helsinki. All participants gave written informed consent prior to study enrolment.

### Study Design

Measurements were taken at 8 am in a fasting state. Blood pressure was measured right before ChT measurements. ChT was defined as the subfoveal choroid measured by OCT (Heidelberg Engineering GmbH, Heidelberg, Germany) at the center of the foveola according to standard criteria: ChT was measured as the distance between the hyperreflective outer border on the retinal pigment epithelium and the interface line behind the large vessel layers of the choroid. The outer border of the retinal pigment epithelial layer was automatically detected by the instrument, and the interface line behind the vessels was defined manually [12] (► Fig. 1). Simultaneously, blood samples were drawn for duplicate measurement of fasting blood glucose (EKF-Diagnostics Biosen C-line, Barleben, Germany), insulin and insulin-like growth factor-1 (IGF-1) were assessed by immunoassays (Immulite 2000, Siemens Healthcare Diagnostics, UK). The model assessment-estimated insulin resistance (HOMA-IR) was calculated according to standard equation (insulin ( $\mu\text{U/mL}$ )  $\times$  fasting blood glucose (mg/dL)/405) [13].

### Statistical Analyses

One-way ANOVA calculation was performed to compare ChT between cohorts. Pearson's correlation coefficients were calculated to determine bivariate relationships between ChT and BMI, HOMA-IR, and IGF-1, respectively. Stepwise multiple linear regression was performed to test independent confounding variables (BMI, HOMA-IR, age, sex, and IGF-1) of variance of ChT. All data are presented as mean  $\pm$  SEM. Analyses were performed with SPSS 22.0 for Mac (SPSS Inc, Chicago, IL). P-values of  $< 0.05$  were accepted as being statistically significant. ► Fig. 2 was created using GraphPad Prism 7 for Mac (San Diego, CA).



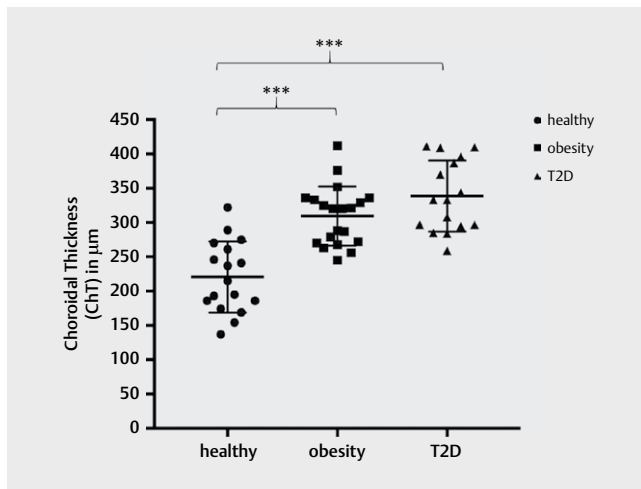
► Fig. 1 a) Image of the retina. The horizontal line shows the area where the measurement was taken by optical coherence tomography (OCT). b) Example image of the choroidal thickness measurements by OCT (Heidelberg Engineering GmbH, Heidelberg, Germany) at the center of the foveola. The green line shows the subfoveal area. Red lines highlight the measured choroidal thickness of 288  $\mu\text{m}$ .

## Results

### Study Group

In total, data of 53 participants were included for the final analysis: 17 healthy (aged  $27.6 \pm 1.7$  years, BMI  $24.4 \pm 0.6 \text{ kg/m}^2$ ), 20 healthy obese (aged  $37.8 \pm 2.5$  years, BMI  $34.9 \pm 1.0 \text{ kg/m}^2$ ), and 16 obese subjects with T2D (aged  $56.4 \pm 3.0$  years, BMI  $34.7 \pm 1.1 \text{ kg/m}^2$ ), (► **Table 1**).

ChT in the obese healthy ( $309.40 \pm 9.66 \mu\text{m}$ ) as well as obese with T2D cohort ( $328.82 \pm 15.65 \mu\text{m}$ ) was significantly thicker as compared to physiological ChT in the healthy normal-weight cohort ( $220.60 \pm 12.60 \mu\text{m}$ ), ( $P < 0.0001$ ; ► **Fig. 2**). However, there was no difference in ChT between healthy obese and obese with T2D subjects ( $P = 0.826$ ). Overall, ChT correlated positively with BMI ( $r = 0.625$ ,  $P < 0.0001$ ), HOMA-IR ( $r = 0.274$ ,  $P < 0.045$ ), and negatively with IGF-1 ( $r = -0.268$ ,  $P = 0.050$ ). The cohort with T2D showed no correlation between ChT and diabetes duration ( $r = -0.058$ ,  $P = 0.851$ ). Stepwise multiple linear regression revealed that BMI ( $R^2 = 0.209$ ;  $P = 0.002$ ;  $\beta = 0.388$ ) and HOMA-IR ( $R^2 = 0.074$ ;  $P = 0.015$ ;  $\beta = 0.305$ ) are independent variables of ChT explaining 20.9 and 7.4% of its variance (both  $p < 0.016$ ), whereas age, sex, and IGF-1 were not significant confounders of ChT ( $p > 0.975$ ).



► **Fig. 2** Choroidal thickness (ChT) is significantly higher in people with obesity compared to healthy participants, but not compared to people with type 2 diabetes (T2D). ChT is also elevated in people with T2D compared to healthy participants (\*\*\*) ( $p < 0.0001$ ).

► **Table 1** Clinical characteristics of healthy participants, people with obesity, and those with T2D.

Participants	Metabolic Healthy	Obesity	T2D
Age (years)	$27.6 (\pm 1.7)$	$37.8 (\pm 2.5)$	$56.4 (\pm 3.0)$
BMI ( $\text{kg/m}^2$ )	$24.4 (\pm 0.6)$	$34.9 (\pm 1.0)$	$34.7 (\pm 1.1)$
Fasting blood glucose (mg/dL)	$77.3 (\pm 1.6)$	$87.7 (\pm 2.0)$	$154.2 (\pm 15.9)$
Insulin ( $\mu\text{U/mL}$ )	$4.8 (\pm 0.8)$	$13.5 (\pm 2.2)$	$37.5 (\pm 13.3)$
HOMA-Index	$1.1 (\pm 0.2)$	$3.0 (\pm 0.5)$	$12.8 (\pm 3.8)$
IGF-1 (ng/mL)	$158.9 (\pm 12.2)$	$122.7 (\pm 10.0)$	$122.7 (\pm 10.0)$
ChT ( $\mu\text{m}$ )	$220.6 (\pm 12.6)$	$309.4 (\pm 9.7)$	$309.4 (\pm 9.7)$

## Discussion

These data reveal the first evidence that increased metabolic burden, i. e., obesity and insulin resistance, is associated with thicker ChT as measured by OCT. Choroid morphology has been previously proposed as possibly an important determinant for diabetes-associated changes in posterior eye structures, and ChT has been found to be thicker in patients with diabetes [3, 14, 15]. Furthermore, data suggest that in patients with DR, both ChT and the sclera are thicker than in healthy eyes [15]. Another study reported increased ChT after a hyperglycemic episode in hospitalized patients with diabetes [16]. In line, Ferreira et al. described that ChT increases with higher glycaemic levels ( $> 160 \text{ mg/dL}$ ) in patients with diabetes [17]. This is of special clinical interest because the choroid is the central structure for supplying the retinal pigment epithelium and the photoreceptors of the retina with nutrient substrates and oxygen [3]. However, T2D is a chronic disease derived from increasing insulin resistance, showing a huge overlap with obesity as another main criterion of the metabolic syndrome. Until now, there was no data on ChT in people with obesity but without manifested T2D. Here we show that higher BMI, as a measure of obesity, is independently associated with thicker ChT. To further account for the continuity in the development of metabolic conditions, such as diabetes and the broad overlap with obesity, we used HOMA-IR as a clinically established measure of insulin resistance [18–20] for our analysis. Apart from obesity, insulin resistance was positively associated with ChT, implying that distinct changes in ChT morphology arise even during early impairment of glucose metabolism and before the manifestation of diabetes.

Since this study reports associations between metabolic characteristics and OCT measures, we can only speculate on underlying mechanistic pathways. Therefore, we included IGF-1 as a proxy of somatotrophic axis activity in an exploratory and hypothesis-generating analysis. IGF-1 represents a well-known modulator of energy metabolism and is key for the regulation of body composition [21]. In people with long-standing insulin resistance or manifested T2D, IGF-1 levels are reported to be lower as compared to healthy controls due to elevated IGF-1 binding proteins (IGF-1BP). Hence, low IGF-1 levels have been debated as a predictive factor for the development and progression of diabetes [22–24]. In addition, elevated levels of IGF-1 binding protein within the vitreous body were found in patients with DR, contributing to the progress of proliferative DR and DME [25]. Fitting into this current state of knowledge, our exploratory analysis of IGF-1 revealed a significant negative correlation between IGF-1 and ChT. However, further research is needed to assess the IGF-1 pathway as a potential link between metabolic traits and changes in eye physiology.

This study had some limitations that need to be addressed. Cohorts differed significantly in age, which might have an impact on ophthalmological measures. In a previous study, age was found not to be associated with ChT in young people [3] and decreased with age in adults [26]. In line, regression analysis revealed that age was not an independent variable of ChT in our study. Furthermore, this pilot study reports only correlations between metabolic state and ChT. Future – and in the best case scenario, interventional – studies are needed to prove a causal link between metabolically modulated dynamics in ChT and the development of DME and DR.

In summary, our findings reveal that increased metabolic burden is associated with thicker ChT as measured by OCT. Currently,

there are no diagnostic methods for detecting the early development of metabolic eye complications, e. g., DR. Our preliminary findings might add clinical implications for early eye screening in patients with metabolic disease. However, further studies are needed to confirm our findings and translate them into clinical routine.

## Author Contributions

S.M.M., H.J.G., B.W., and S.M. designed the study. A.J.P., M.S., N.K., and S.M. collected the data, and R.C., B.W., A.K., S.M.M., and S.M. analyzed and interpreted the data. S.M. researched literature and wrote the manuscript. B.W., R.C., A.K., A.J.P., M.S., N.K., A.S.S., E.P., H.J.G., and S.M.M. reviewed the manuscript. S.M.M. takes responsibility for the integrity of the data and the accuracy of the data analysis.

## Funding

This study did not receive funding from any source.

## Conflict of Interest

S.M., B.W., R.C., A.K., A.J.P., M.S., N.K., A.S.S., E.P., H.J.G., and S.M.M. have nothing to disclose.

## References

- [1] Yau JWY, Rogers SL, Kawasaki R et al. Global prevalence and major risk factors of diabetic retinopathy. *Diabetes Care* 2012; 35: 556–564. doi:10.2337/dc11-1909
- [2] Fong DS, Aiello L, Gardner TW et al. Retinopathy in diabetes. *Diabetes Care* 2004; 27: S84–S87. doi:10.2337/diacare.27.2007.S84
- [3] Wu W-C, Shih C-P, Wang N-K et al. Choroidal thickness in patients with a history of retinopathy of prematurity. *JAMA Ophthalmol* 2013; 131: 1451–1458. doi:10.1001/jamaophthalmol.2013.5052
- [4] Tan K-A, Gupta P, Agarwal A et al. State of science: Choroidal thickness and systemic health. *Surv Ophthalmol* 2016; 61: 566–581. doi:10.1016/j.survophthal.2016.02.007
- [5] Vujosevic S, Martini F, Cavarzeran F et al. Macular and peripapillary choroidal thickness in diabetic patients. *Retina* 2012; 32: 1781–1790. doi:10.1097/IAE.0b013e31825db73d
- [6] Soubrane G. Macular Edema of Choroidal Origin. In: Coscas G, Loewenstein A, Cunha-Vaz J, et al., Hrsg. *Developments in Ophthalmology*. S. Karger AG. 2017; 202–219
- [7] Park K-A, Oh SY. Analysis of spectral-domain optical coherence tomography in preterm children: Retinal layer thickness and choroidal thickness profiles. *Invest Ophthalmol Vis Sci* 2012; 53: 7201–7207. doi:10.1167/iovs.12-10599
- [8] Browning DJ, McOwen MD, Bowen RM et al. Comparison of the clinical diagnosis of diabetic macular edema with diagnosis by optical coherence tomography. *Ophthalmology* 2004; 111: 712–715. doi:10.1016/j.ophtha.2003.06.028
- [9] Kim JT, Lee DH, Joe SG et al. Changes in choroidal thickness in relation to the severity of retinopathy and macular edema in type 2 diabetic patients. *Invest Ophthalmol Vis Sci* 2013; 54: 3378. doi:10.1167/iovs.12-11503
- [10] Unsal E, Eltutar K, Zirtiloglu S et al. Choroidal thickness in patients with diabetic retinopathy. *Clin Ophthalmol* 2014; 637. doi:10.2147/OPHT.S59395
- [11] American Diabetes Association 2. Classification and Diagnosis of Diabetes: *Standards of Medical Care in Diabetes – 2019*. *Diabetes Care* 2019; 42: S13–S28. doi:10.2337/dc19-S002
- [12] Wang N-K, Lai C-C, Chu H-Y et al. Classification of early dry-type myopic maculopathy with macular choroidal thickness. *Am J Ophthalmol* 2012; 153: 669–677. doi:10.1016/j.ajo.2011.08.039
- [13] Matthews DR, Hosker JP, Rudenski AS et al. Homeostasis model assessment: Insulin resistance and beta-cell function from fasting plasma glucose and insulin concentrations in man. *Diabetologia* 1985; 28: 412–419. doi:10.1007/BF00280883
- [14] Xu J, Xu L, Du KF et al. Subfoveal choroidal thickness in diabetes and diabetic retinopathy. *Ophthalmology* 2013; 120: 2023–2028. doi:10.1016/j.ophtha.2013.03.009
- [15] Lee YJ, Lee YJ, Lee JY et al. A pilot study of scleral thickness in central serous chorioretinopathy using anterior segment optical coherence tomography. *Sci Rep* 2021; 11: 5872. doi:10.1038/s41598-021-85229-y
- [16] Jo Y, Ikuno Y, Iwamoto R et al. Choroidal thickness changes after diabetes type 2 and blood pressure control in a hospitalized situation. *Retina* 2014; 34: 1190–1198. doi:10.1097/IAE.000000000000051
- [17] Tavares Ferreira J, Vicente A, Proença R et al. Choroidal thickness in diabetic patients without diabetic retinopathy. *Retina* 2018; 38: 795–804. doi:10.1097/IAE.0000000000001582
- [18] Hřebíček J, Janout V, Malinčíková J et al. Detection of insulin resistance by simple Quantitative Insulin Sensitivity Check Index QUICKI for epidemiological assessment and prevention. *J Clin Endocrinol Metab* 2002; 87: 144–144. doi:10.1210/jcem.87.1.8292
- [19] Singh B, Saxena A. Surrogate markers of insulin resistance: A review. *World J Diabetes* 2010; 1: 36–47. doi:10.4239/wjdv1.i2.36
- [20] Motamed N, Miresmail SJH, Rabiee B et al. Optimal cutoff points for HOMA-IR and QUICKI in the diagnosis of metabolic syndrome and non-alcoholic fatty liver disease: A population based study. *J Diabetes Complications* 2016; 30: 269–274. doi:10.1016/j.jdiacomp.2015.11.019
- [21] Berryman DE, Glad CAM, List EO et al. The GH/IGF-1 axis in obesity: Pathophysiology and therapeutic considerations. *Nat Rev Endocrinol* 2013; 9: 346–356. doi:10.1038/nrendo.2013.64
- [22] Sandhu MS, Heald AH, Gibson JM et al. Circulating concentrations of insulin-like growth factor-I and development of glucose intolerance: A prospective observational study. *Lancet* 2002; 359: 1740–1745. doi:10.1016/S0140-6736(02)08655-5
- [23] Haywood NJ, Slater TA, Matthews CJ et al. The insulin like growth factor and binding protein family: Novel therapeutic targets in obesity & diabetes. *Mol Metab* 2019; 19: 86–96. doi:10.1016/j.molmet.2018.10.008
- [24] Teppala S, Shankar A. Association between serum IGF-1 and diabetes among U.S. adults. *Diabetes Care* 2010; 33: 2257–2259. doi:10.2337/dc10-0770
- [25] Burgos R, Mateo C, Cantón A et al. Vitreous levels of IGF-I, IGF binding protein 1, and IGF binding protein 3 in proliferative diabetic retinopathy: A case-control study. *Diabetes Care* 2000; 23: 80–83. doi:10.2337/diacare.23.1.80
- [26] Wei WB, Xu L, Jonas JB et al. Subfoveal choroidal thickness: The Beijing Eye Study. *Ophthalmology* 2013; 120: 175–180. doi:10.1016/j.ophtha.2012.07.048