

Epidemiological, clinical and endoscopic characteristics of colorectal neuroendocrine neoplasms: a population-based study in the Netherlands



Authors

Ankie Reumkens^{1,2,3}, Prapto Sastrowijoto⁴, Heike I. Grabsch^{5,6}, Danny Goudkade⁴, Chantal le Clercq^{1,3}, Minke Bakker¹, Eric Keulen³, Rogier de Ridder¹, Wouter W. de Herder⁷, Bjorn Winkens^{8,9}, Silvia Sanduleanu^{1,6}, Judith de Vos-Geelen^{6,10}, Ad Masclee^{1,2}

Institutions

- 1 Division of Gastroenterology and Hepatology, Department of Internal Medicine, Maastricht University Medical Center, Maastricht, the Netherlands
- 2 NUTRIM, School for Nutrition, Toxicology and Metabolism, Maastricht University Medical Center, Maastricht, the Netherlands
- 3 Department of Internal Medicine and Gastroenterology, Zuyderland Medical Center, Sittard-Heerlen, the Netherlands
- 4 Department of Pathology, Zuyderland Medical Center, Sittard-Geleen-Heerlen, the Netherlands
- 5 Division of Pathology and Data Analytics, Leeds Institute of Medical Research at St James's, University of Leeds, Leeds, the United Kingdom
- 6 Department of Pathology, GROW, School for Oncology and Developmental Biology, Maastricht University Medical Center, Maastricht, the Netherlands
- 7 Department of Endocrine Oncology, Erasmus MC and Erasmus MC Cancer Institute, ENETS Center of Excellence Rotterdam, the Netherlands
- 8 Department of Methodology and Statistics, Maastricht University Medical Center, Maastricht, the Netherlands
- 9 CAPHRI, Care and Public Health Research Institute, Maastricht University Medical Center, Maastricht, the Netherlands
- 10 Department of Internal Medicine, Division of Medical Oncology, Maastricht, the Netherlands

submitted 9.7.2021

accepted after revision 8.3.2022

published online 10.3.2022

Bibliography

Endosc Int Open 2022; 10: E940–E951

DOI 10.1055/a-1793-9057

ISSN 2364-3722

© 2022. The Author(s).

This is an open access article published by Thieme under the terms of the Creative Commons Attribution-NonDerivative-NonCommercial License, permitting copying and reproduction so long as the original work is given appropriate credit. Contents may not be used for commercial purposes, or adapted, remixed, transformed or built upon. (<https://creativecommons.org/licenses/by-nc-nd/4.0/>)

Georg Thieme Verlag KG, Rüdigerstraße 14, 70469 Stuttgart, Germany

Corresponding author

Ankie Reumkens, MD, Division of Gastroenterology and Hepatology, Maastricht University Medical Center, Postbox 5800, 6202 AZ, Maastricht, The Netherlands
 Fax: +31-43-3875006
ankie.reumkens@gmail.com

ABSTRACT

Background and study aims Neuroendocrine neoplasms (NEN) account for a small number of colorectal neoplasms. Endoscopic detection is essential for diagnosis, treatment and follow-up. Little is known about incidence of NENs in colonoscopy populations or the relationship between clinical, endoscopic and histopathologic features. We evaluated epidemiology, endoscopic and clinical characteristics of colorectal NENs in a population-based cohort.

Patients and methods Medical records of NEN cases were cross-linked with the national pathology database from January 2001 to December 2015, in South Limburg County, the Netherlands, covering four endoscopy units. Senior pathologists reviewed and classified NENs using World Health Organization 5th edition (2019) guidelines.

Results The number of colorectal NEN diagnoses was stable over time with 0.6 NEN per 1,000 patients. A total of NENs were detected in 85 patients: 65 neuroendocrine tumors (NETs) and 20 poorly differentiated neuroendocrine carcinomas (NECs). Rectal NETs were usually small sessile/submucosal lesions with yellowish (lipoma-like) color. Colonic NETs were larger sessile/submucosal lesions with darker color compared to background. Colorectal NECs presented as large, dark-colored lesions with ulcerated/necrotizing areas.

Conclusions Our population-based data point to a stable and low incidence of 0.6 NEN per 1,000 patients in the Netherlands. Rectal NETs mainly present as small sessile yellowish lesions. Colonic NETs present as larger and darker lesions than background mucosa and NECs as darker lesions

than background with ulceration/necrosis. Standardized endoscopic characterization of colorectal NENs is necessary to improve recognition of these lesions and provide a basis for evidence-based treatment and surveillance recommendations.

Introduction

Neuroendocrine neoplasms (NENs) comprise a rare group of morphologically and biologically heterogeneous malignant tumors [1]. The 2010 and 2019 5th edition World Health Organization (WHO) classification of gastrointestinal tumors subdivides neuroendocrine neoplasms (NENs) into well-differentiated neuroendocrine tumors (NETs), which are subclassified as grades (G) 1 to 3 NETs based on their Ki67 index (► **Fig. 1**), and poorly differentiated neuroendocrine carcinomas (NECs), which are subclassified as small cell neuroendocrine carcinoma (SCNEC) or large cell neuroendocrine carcinoma (LCNEC) [2].

Colorectal NENs are classified according to primary site, e.g. colon or rectum, in relation to their different natural history [3]. Rectal NENs are mostly small and generally G1 and G2 NETs, while colonic NENs are often larger and poorly differentiated (NECs) showing more aggressive behavior [4].

Previous population-based studies indicate that NENs account for less than 1% of all colorectal tumors [5, 6]. The incidence of NENs in the general population is rising [7]. The vast majority of colorectal NENs are asymptomatic and found incidentally at colonoscopy [8]. With the implementation of population-based colorectal cancer (CRC) screening programs, the incidence of colorectal NENs has increased from 0.4 per 1,000 patients to 0.6 per 1,000 patients [9–11]. Rectal NETs diagnosed through CRC screening programs or diagnosed at surveillance colonoscopy were detected at an earlier stage and were smaller in size compared to rectal NETs detected on non-screening colonoscopies [9, 12]. Early detection of colorectal NENs is important, because up to 20% of all NEN patients present with metastases at the time of diagnosis, depending on tumor site (colon > rectum) and tumor size [13, 14]. For early detection, it is essential to describe and become familiar with the endoscopic appearance of colorectal NENs and to use the most appropriate resection technique: endoscopic mucosal resection, endoscopic submucosal dissection or surgery [3, 15]. Because of overall low prevalence, studies on endoscopic characteristics of NENs are limited [16, 17], and data based on the 5th edition WHO classification are lacking [18].

An accurate diagnosis is the critical first step to optimize clinical outcomes in patients with NENs. Endoscopic appearance has only been described in case reports [19] and has not been examined in population-based studies or related to grade of differentiation (i.e. G1, G2, G3, based on Ki67) [20]. In this population-based cohort study, our aim was to describe the incidence of colorectal NENs, clinical characteristics (including survival), and their endoscopic appearance.

Patients and methods

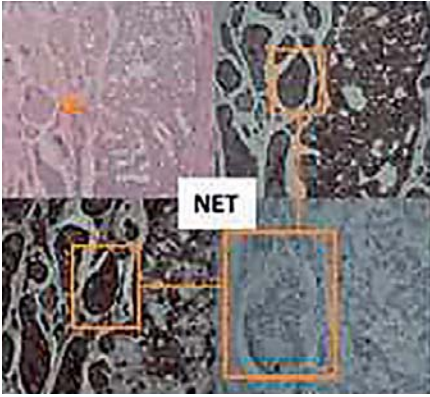

Study population and design

This was a multicenter study involving three large-volume hospitals and one diagnostic center in the Netherlands. The three hospitals included one academic center (Maastricht University Medical Center+) and two regional hospitals (Zuyderland Medical Center Heerlen, previously Atrium Medical Center, and Zuyderland Medical Center Sittard-Geleen, previously Orbis Medical Center). The diagnostic center is located in Maastricht (Diagnostic Center Maastricht, Maastricht). All hospitals are located in the county of South Limburg in the Netherlands. The total county population consists of approximately 605,000 inhabitants and has a low net migration rate of six to 13 per 1000 inhabitants per year (according to the Central Office of Statistics, the Netherlands). The study was approved by the Institutional Review Board of the participating hospitals and was registered in The Netherlands Trial Registry NTR4844 and NTR3093.

Data from the national population-based pathology database (PALGA, IZV 2016–47) were obtained for all patients diagnosed with a colorectal neuroendocrine neoplasm (i.e. carcinoids, neuroendocrine tumors, and neuroendocrine carcinomas originating from the colon or rectum) from January 1, 2001 to December 31, 2015. We cross-linked the national population-based pathology database (PALGA) and hospital records, including colonoscopy reports performed in single patients, to retrieve all unique cases of colorectal NENs diagnosed in the county between 2001 and 2015. Inclusion criteria were: (1) diagnosis of colorectal NEN based on histology of material obtained during colonoscopy; and (2) availability of follow-up data. Patients who directly underwent surgery due to colonic obstruction and in whom a colonoscopy had not been performed were excluded (n = 3) (► **Fig. 2**). Patients with colorectal metastases of other origin, or NEN other than colon or rectum (i.e. appendix, ileum, n = 63), and external referrals (index colonoscopy performed in another hospital and incomplete survival data, n = 6) were excluded.

We collected clinical data from medical charts, endoscopy and histology reports, regarding macroscopic appearance of the NENs, tumor location, size, stage, treatment, surveillance, and patient characteristics (gender, age, medication use, medical history, smoking status, family history, comorbidities, survival).

PGEP-NEN nomenclature, 5th ed. WHO classification (2019)

	Pathologic assessment	Grade	Mitotic count (per 10 HPF)	Ki 67
Well-differentiated NETs		NET G1	<2	<3 %
		NET G2	2–20	3–20 %
		NET G3	>20	>20 %
Poorly differentiated NECs		LCNEC	>20	>20 %
		SCNEC	>20	>20 %

* NET G1 (based on Ki-67 and mitotic count). The HE-staining shows abnormal tumor cells, surrounded by normal cells. Both synaptophysin and chromogranin A staining visualize neuroendocrine tumor cells positive.

** NEC. The HE-staining shows no normal cells anymore. Synaptophysin and chromogranin A staining are both positive. The Ki-67 is in nearly all cells positive in this case.

► **Fig. 1** GEP-NEN nomenclature, 5th ed. WHO classification (2019).

Definitions and pathologic assessment

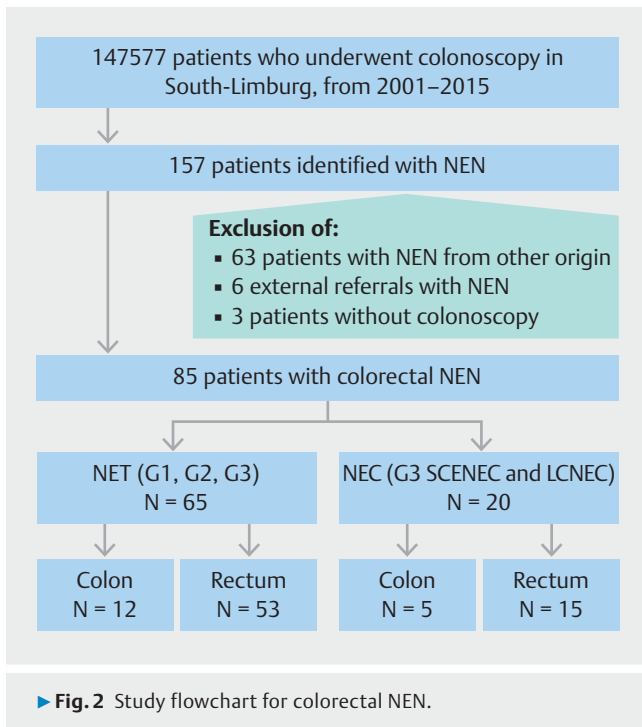
We defined colorectal NENs according to the 5th edition WHO classification (2019) (► **Fig. 1**) [18]. Second, the poorly differentiated group is designated as NEC and subdivided based on morphologic types as small cell carcinoma (SCNEC) or large cell carcinoma (LCNEC) (both Ki67>20% or mitotic index>20/10 HPF) [1].

Hematoxylin and eosin-stained slides were evaluated and scored by a consultant pathologist with a special interest in gastrointestinal pathology and a random set was reviewed by a second consultant pathologist. In addition, synaptophysin staining was available to confirm neuroendocrine differentia-

tion and Ki67 staining to calculate the Ki-67 proliferation index. Colorectal neuroendocrine neoplasm grading after pathology review was used to generate the results.

Endoscopic appearance

Because there was no endoscopic classification of NENs available, items from the Paris Classification [21], the BLI (Blue Light Imaging) Adenoma Serrated International Classification (BASIC) [22], and the narrow band imaging International Colorectal Endoscopic (NICE) classification were used [23] to retrospectively describe NENs based on colonoscopy reports and the saved photo documentation of the endoscopic procedure.



Lipoma-like lesions were defined as yellowish, submucosal lesions.

Study endpoints and statistical analysis

Primary endpoints of this study were: (1) epidemiological characteristics; and (2) clinical and endoscopic characteristics of NENs. For survival analysis, time to event was calculated from the date of diagnosis to the time of death from any cause, based on of the Municipal Personal Records Database or censored at

20 April 2020. Numerical data are presented as mean ± standard deviation (SD) and range or median with interquartile range (IQR). Differences in numerical variables between groups were assessed using independent-samples t-test or Mann-Whitney U tests as appropriate, while chi square (χ^2) or Fisher's exact tests were used for categorical variables. The Fisher-Freeman-Halton Exact test was used for categorical variables with more than two categories.

Kaplan-Meier survival analysis was used to estimate overall survival (OS) of patients with G1 and G2 or G3 NENs. Survival distributions were compared using the log rank test and Cox regression analyses. Hazard ratios with 95% confidence interval and corresponding P values were presented. $P \leq 0.05$ were considered statistically significant. Analyses were conducted using IBM SPSS Statistics for Windows version 26.0 (SPSS, IBM Corp., Armonk, New York, United States).

Results

Epidemiology

Of the 147,577 single per-patient colonoscopies performed from January 2001 to December 2015 in South Limburg County, we identified a total of 85 patients who had been diagnosed with a NEN (► Fig. 2). The total number of colonoscopies per year increased gradually over the 15-year study period (► Fig. 3). The number of diagnosed NENs remained relatively stable with an average incidence of 0.6 NENs per 1,000 patients per year.

Clinical features of NEN patients

The 85 patients (65 with NETs and 20 with NECs) had a mean age of 61.8 ± 11.6 years (range: 33–86 years) and 51.8% were male. In 17 patients (20%) the NEN was localized in the colon, and 68 patients (80%) had a rectal NEN. Of the 68 rectal NENs,

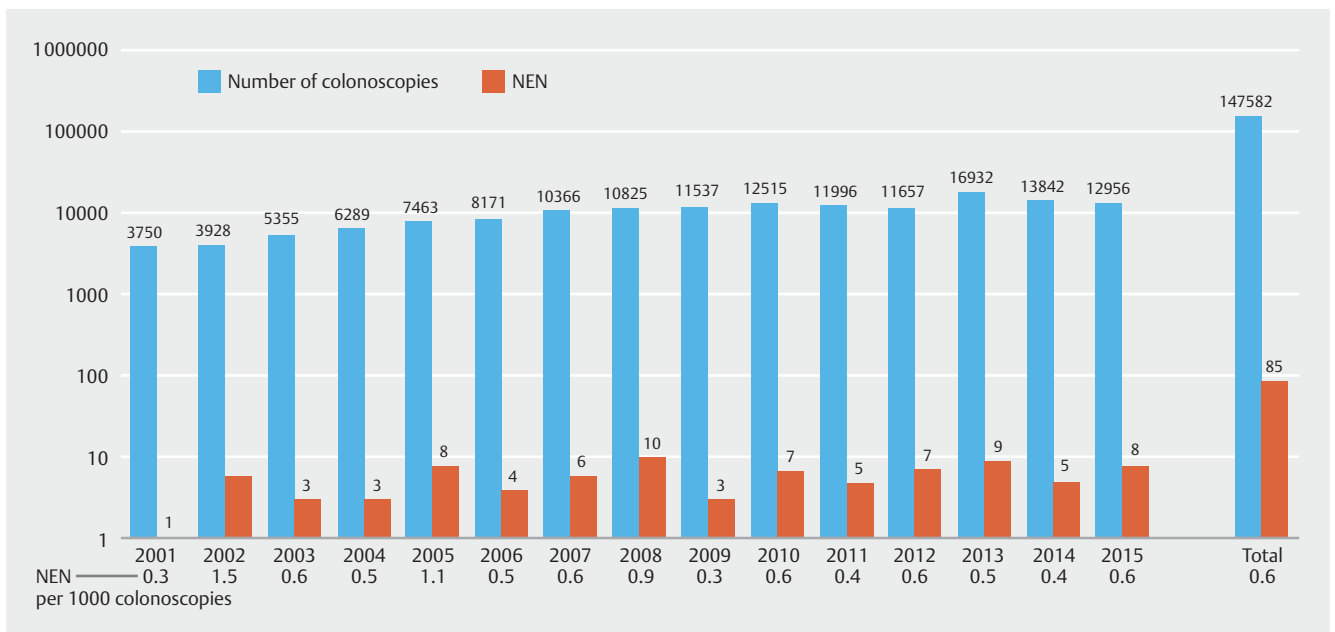


Fig. 3 Time trends in diagnosis of colorectal NENs.

► **Table 1** Characteristics of neuroendocrine tumors.

	Tumor site				P value
	Colon		Rectum		
	N = 12	%	N = 53	%	
Age, mean (years) ±SD (range)	62 ± 12 (39–79)		58 ± 10 (33–80)		0.34
Gender, male	7	58.3	25	47.2	0.54
NET grade					0.089
▪ Grade 1	11	91.7	45	84.9	
▪ Grade 2	0	0	8	15.1	
▪ Grade 3	1	8.3	0	0	
Indication for colonoscopy					0.55
▪ Symptoms	9	75.0	41	77.4	
▪ Screening	1	8.3	1	1.9	
▪ Surveillance	2	16.7	11	20.8	
Tumor size					
Median, IQR, mm	33 (5–40)		6 (3–9)		0.006 ¹
Category					0.001 ¹
▪ <1 cm	4	33.3	41	77.4	
▪ 1–2 cm	0	0	9	17.0	
▪ >2 cm	8	66	3	5.7	
Tumor site colon					
▪ Cecum	10	83.3	–	–	–
▪ Ascending	0	0	–	–	–
▪ Transverse	0	0	–	–	–
▪ Sigmoid	2	16.7	–	–	–
Endoscopic features					
Morphology					
▪ Submucosal/sessile lesion	11	91.7	53	100	0.19
▪ (Pseudo)depression or donut-shaped	3	25.0	15	28.3	1.00
▪ Regular surface	9	75.0	51	96.2	0.040 ¹
▪ Vessels: prominent, yes	4/6	80.0	23	23/24 = 95.8	0.32
▪ Lipoma-like	2	16.7	45	84.9	<0.001 ¹
Color					0.001 ¹
▪ Yellowish color	4	33.3	45	84.9	
▪ Darker than background	8	66.7	8	15.1	
Stage					
▪ Lymph node metastasis	4	33.3	3	5.7	0.018 ¹
▪ Distant metastasis	2	16.7	4	7.5	0.31
▪ Total	4	33.3	4	7.5	0.033 ¹
Treatment					
▪ Endoscopy	2	16.7	46	86.8	<0.001 ¹
▪ Surgery	7	58.3	3	5.7	<0.001 ¹

► **Table 1** (Continuation)

	Tumor site				P value
	Colon		Rectum		
	N = 12	%	N = 53	%	
▪ Surgery + (neo)adjuvant therapy	1	8.3	1	1.9	0.29
▪ Palliative therapy	0	0	1	1.9	1.00
▪ No treatment	2	16.7	2	3.8	0.51
Resection					
▪ Complete endoscopically	2	16.7	46	86.8	<0.001 ¹
▪ Complete surgically ²	8	66.7	4	7.5	<0.001 ¹
After complete resection					
▪ Recurrence	0	³	2	³	
▪ Metastasis	1	³	3	³	

NET, neuroendocrine tumor; IQR, interquartile range.

¹ P < 0.05.

² With or without (neo)adjuvant therapy.

³ No percentages were calculated because follow-up endoscopy or radiology was not completed in all patients.

► **Table 2** Characteristics of neuroendocrine carcinomas.

	Tumor site				P value
	Colon (n = 5)	%	Rectum (n = 15)	%	
Age, mean (years) ±SD (range)	69 ± 4 (63–75)		72 ± 10 (53–86)		0.54
Gender, male	4	80.0	8	53.3	0.60
NEC					
▪ LCNEC	3	60.0	9	60.0	1.00
▪ SCNEC	2	40.0	6	40.0	1.00
Indication for colonoscopy					
▪ Symptoms	4	80.0	15	100	1.00
▪ Screening	0	0	0	0	1.00
▪ Surveillance	1	20.0	0	0	1.00
Tumor size					
▪ Median, IQR, mm	48 (33–59)		50 (30–80)		0.44
Category					
▪ <1 cm	0	0	0	0	1.00
▪ 1–2 cm	0	0	1	6.7	1.00
▪ >2 cm	5	100	14	93.3	1.00
Tumor site colon					
▪ Caecum	2	40.0	–	–	–
▪ Ascending	1	20.0	–	–	–
▪ Transverse	1	20.0	–	–	–
▪ Sigmoid	1	20.0	–	–	–

► **Table 2** (Continuation)

	Tumor site				P value
	Colon (n=5)	%	Rectum (n=15)	%	
Endoscopic features					
Morphology					
▪ Submucosal lesion	0 ¹	0	0 ¹	0	
▪ (Pseudo)depression	4	80.0	13	86.7	1.00
▪ Irregular surface	4	80.0	13	86.7	1.00
▪ Regular surface	1	20.0	2	13.3	
▪ Ulceration/necrosis	4	80.0	13	86.7	1.00
▪ Semi-circular	3	60.0	5	33.3	0.35
▪ Stenosis	0	0	5	33.3	0.27
Color					
▪ Yellowish color	0	0	0	0	
▪ Darker than background	5	100.0	15	100.0	
Stage					
▪ Lymph node metastasis	1	20.0	3	20.0	1.00
▪ Distant metastasis	2	40.0	8	53.3	0.61
▪ Total	3	60.0	9	60.0	1.00
Treatment					
▪ Endoscopy	0	0	1	6.7	1.00
▪ Surgery	2	40.0	4	26.7	0.58
▪ Surgery + (neo)adjuvant therapy	1	20.0	1	6.7	0.41
▪ Palliative therapy	0	0	6	40.0	1.00
▪ No treatment	2	40.0	3	20.0	0.38
After complete resection					
▪ Recurrence	1	²	1	²	
▪ Metastasis	2	²	4	²	

SD, standard deviation; NEC, neuroendocrine carcinoma; LCNEC, large cell neuroendocrine carcinoma; SCNEC, small cell neuroendocrine carcinoma; IQR, interquartile range.

¹ With or without (neo)adjuvant therapy.

² No percentages were calculated because follow-up endoscopy or radiology was not completed in all patients.

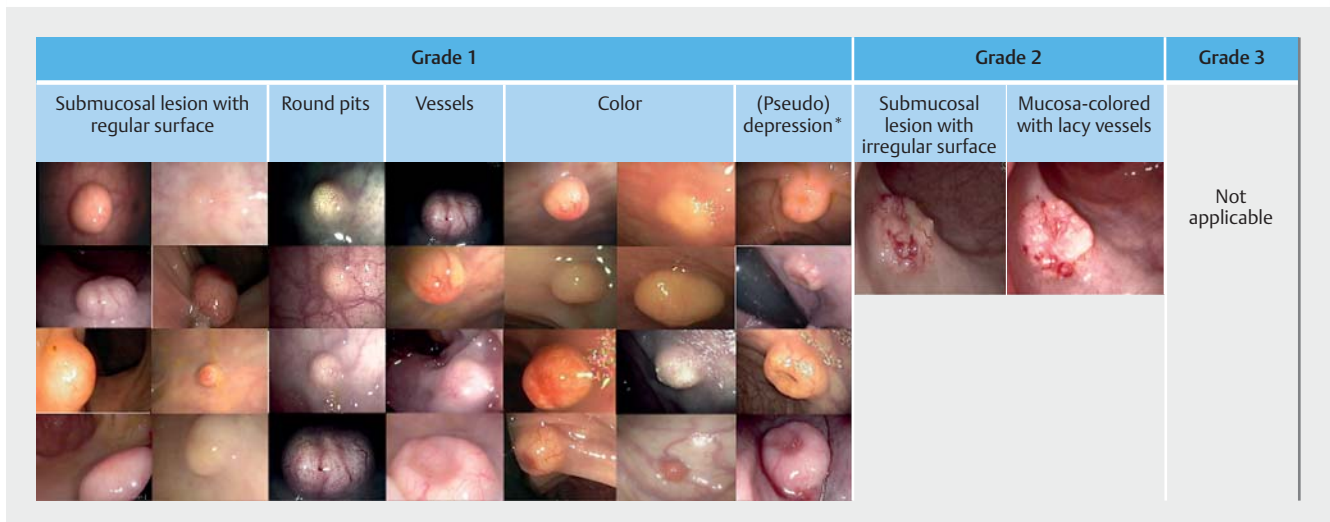
66% (n=45) were G1, 12% (n=8) G2, 0% (n=0) G3 NET, and 22% (n=15) NEC G3 after pathology review (► **Table 1** and ► **Table 2**). Of the 17 colonic NENs, 65% (n=11) were G1, 0% (n=0) G2, 6% (n=1) G3 NET, and 29% (n=5) G3 NEC (► **Table 1** and ► **Table 2**). Of the patients with colonic NEC, 80% had gastrointestinal symptoms (i.e. hematochezia or changed stool habits) vs 100% of the rectal NEC patients (► **Table 2**).

Rectal versus colonic NETs G1, G2 and G3

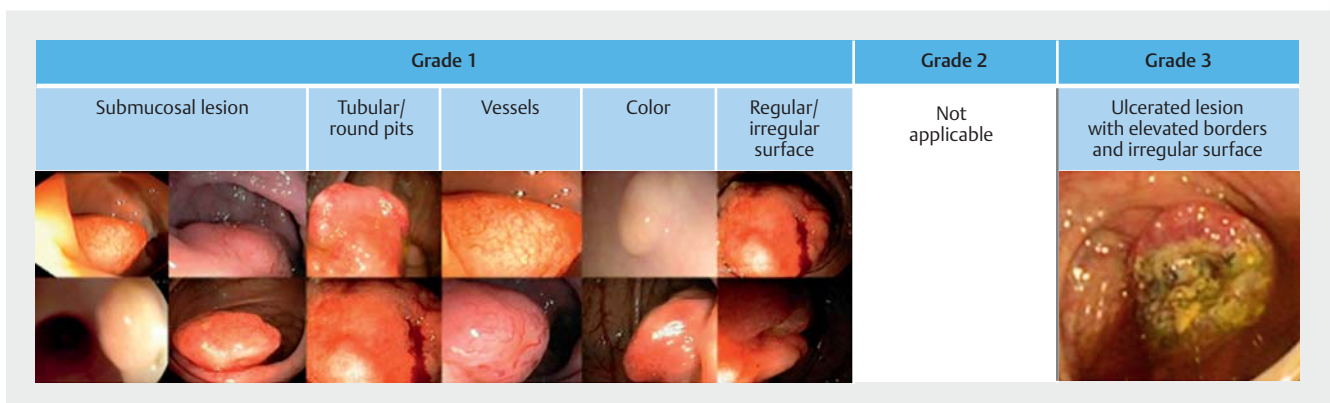
Macroscopically, NETs and NECs were different tumors (► **Fig. 4**, ► **Fig. 5**, ► **Fig. 6** and ► **Table 1** and ► **Table 2**). The most common NET in the colon and rectum was G1 (colon 91.7% and rec-

tum 84.9%), while G2 and G3 NENs were rare (► **Table 1**). Colonic NETs were larger compared to rectal NETs (33 mm IQR 5–40, vs. 6 mm IQR 3–9) ($P=0.006$). Rectal NETs were mostly sessile/submucosal tumors and (► **Fig. 4**) more often had a regular surface compared to colonic NETs (96.2 vs. 75.0%, $P=0.040$) (► **Table 1**), and a yellowish color (84.9 vs. 33.3%, $P=0.001$) and, therefore, were more frequently described as lipoma-like (84.9% vs. 16.7%, $P<0.001$).

Colonic NETs (► **Fig. 5**) were most frequently located in the cecum (83.3%), 66% were relatively large (>2 cm) sessile/submucosal lesions and they were more frequently darker than background mucosa compared to rectal NETs (66.7 vs. 15.1%,



► Fig. 4 Macroscopy of rectal NETs.



► Fig. 5 Macroscopy of colonic NETs.

$P=0.001$) (► Table 1). There were no significant differences in the presence of prominent vessels, (pseudo)depression, and pit pattern between rectal and colonic NEN (► Table 1, ► Fig. 4 and ► Fig. 5).

The percentage of locoregional lymph node metastases (N1) at diagnosis was higher in colonic NETs (33.3%) vs. rectal NETs (5.7%) ($P=0.018$). The majority of the rectal NETs were removed endoscopically (86.8%) (► Table 1), while the majority of the colonic NETs required surgery (58.3%).

Rectal versus colonic NECs

NECs were endoscopically darker than background mucosa in 80% of the colonic and 60% of the rectal NECs (► Table 2, ► Fig. 6). The majority of the NECs were associated with ulceration or necrosis (80% in both the colon and rectum group). There was no statistically significant difference in tumor size for colonic and rectal NECs (48 mm IQR 33–59 vs 50 mm IQR 30–80 mm, $P=0.44$). Three (60%) of the colonic NECs and nine (60%) of the rectal NECs were LCNECs (► Table 2). Colorectal LCNECs and SNECs did not differ with respect to irregular surface, (pseudo) depression, ulceration, necrosis or color (► Fig. 6).

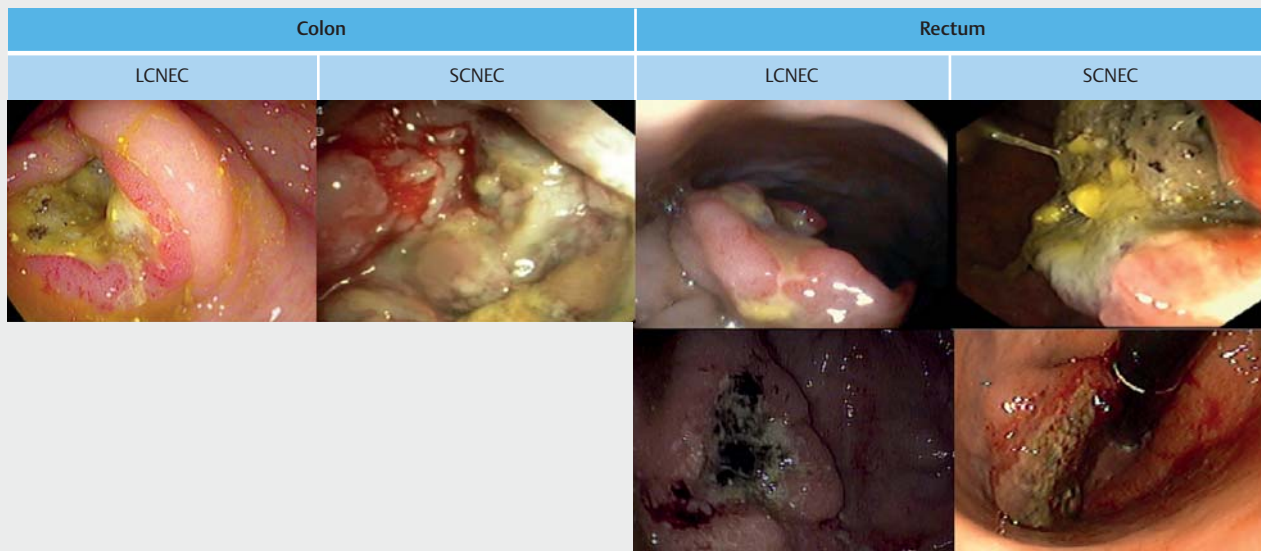
Survival

Median follow-up time was 7.0 years (IQR 2.0–11.0). The median follow-up time for patient with G1, G2, or G3 NETs was 8.8 years (IQR 5.9–11.5) and for NEC patients 0.5 years (IQR 0.3–1.4).

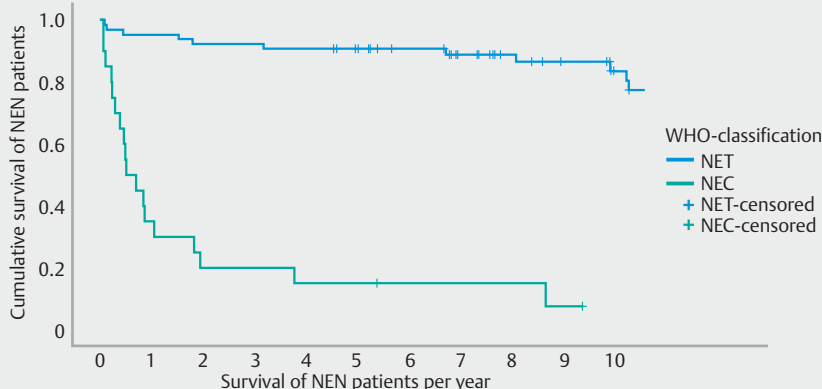
Of all patients with G1, G2 and G3 NETs, 1-, 3-, and 5-year OS rates were 95%, 91%, and 91%, and for those with NECs, 1-, 3-, and 5-year OS rates were 35%, 20%, and 15%, respectively (► Fig. 7). With respect to location, of all patients with colonic G1, G2 and G3 NET, 1-, 3- and 5-year OS rates were 83%, 83% and 83% respectively, and for those with rectal NETs, 98%, 94%, and 92%, respectively ($P=0.47$). OS rates for poorly differentiated NECs were similar with respect to tumor site (colon vs. rectum).

Discussion

Highly relevant findings in our population-based study are that: 1) the incidence of NENs is low and relatively stable; and 2) an endoscopic signature is provided for colorectal NETs and NECs.



► Fig. 6 Macroscopy of colorectal NEC (LCNEC vs SCNEC).



No at risk	Years															
	0	1	2	3	4	5	6	7	8	9	10	11	12	13	14	15
NET	65	62	60	59	59	59	58	58	57	56	54	53	52	52	52	52
NEC	20	7	4	4	3	3	2	2	2	1	-	-	-	-	-	-

► Fig. 7 Survival of patients with colorectal NET vs NEC, corrected for age and gender.

In a comprehensive data collection based on our clinical practice over the past 15 years, we characterized the endoscopic and histologic features of NETs and NECs according to the 5th edition WHO classification [18]. Rectal NETs present mostly as small sessile/submucosal yellowish (lipoma-like) lesions with regular surface. Colonic NETs present mostly as larger sessile lesions, with irregular surface in 25%, prominent vessels, and more often darker (than background) than yellowish or lipoma-like color. NECs present as darker (than background mucosa), larger lesions with ulcerative-necrotizing features, both for rectal and colonic NECs.

Based on reports from Asia and the United States, the number of colorectal NENs detected is rising, which is due to an

increase in the number of colonoscopies [19, 24]. With an average of 0.6 NEN per 1,000 patients, the incidence of NENs is slightly higher compared to the study of Korse et al, which reported an incidence of 0.43 colorectal NENs per 1,000 patients (0.33/1000 for NETs and 0.10/1000 for NECs), in the Netherlands in the period 2001 to 2010 [25]. The slightly higher incidence in our study may be related to implementation of the CRC program in the Netherlands that occurred after 2010. This is confirmed by data from the UK showing that implementation of the CRC screening program has led to a higher ratio of identified NETs (0.6 per 1,000 patients) compared to data from the general UK population [11]. The 5-year survival of patients with NETs appeared to be 91%. However the 5-year survival of pa-

tients with NECs is worse (15%) compared to the 5-year survival rate for colorectal cancer, which has reached almost 65% in the Western World [26].

Diagnosis and management of colorectal neuroendocrine neoplasms is challenging because of the low incidence, and limited data on endoscopic appearance and combined endoscopy and histopathology-based diagnosis and optimal therapeutic approach [3, 16, 27]. Missing a NEN can potentially result in worse outcome and should be prevented. The first step is to create awareness by endoscopists about the need to recognize colorectal NENs during endoscopy. The second step is to adequately resect suspicious NEN lesions in the colon and rectum, thereby limiting the risk of metastasis [20, 28]. Metastasis risk has been associated with tumor grade (Ki-67) and presence of lymphovascular invasion and of a central depression in the lesion [13, 29]. Furthermore, metastasis risk seems to be related to tumor location; colon NETs more often are metastatic than rectal NETs [30]. This is probably related to tumor size [31]. Awareness by the endoscopist with recognition of these endoscopic lesions can result in early detection of well-differentiated NENs and radical endoscopic resections in a first or second attempt [32]. Previous studies have not fully characterized the macroscopic appearances of NEN subtypes [17, 32]. Highly relevant is that rectal NETs are distinguishable from other polyps and tumors, based on their yellowish (lipoma-like) color, sessile or submucosal appearance, usually with a depressed central area when larger than 1 cm [17]. Relevant also is that colorectal NETs should be distinguished from lipomas. With reported prevalence of 0.2% to 4.4% [33], colonic lipomas are characterized by an intact mucosa and the diagnosis is suggested based on the “pillow sign” (tumor indents when depressed using the biopsy forceps) or the “naked fat sign” with extrusion of yellowish fat after repeated biopsy [34, 35]. Vessel distribution appears to be similar to the surrounding mucosa [35]. In contrast to lipomas, NETs have a more pronounced vessel pattern compared to the surrounding mucosa and the “pillow sign” and “naked fat sign” are lacking. Data on how often lipoma-like lesions eventually appear to be NENs are still lacking. All yellowish lesions in the rectum visualized during colonoscopy, (without the pillow and/or naked fat sign) should potentially be considered NETs and resection planned. In contrast to smaller rectal NETs, colonic NETs are often larger than 2 cm and show less lipoma-like characteristics, as confirmed by our data [36].

Colorectal NECs have macroscopic features that are quite different from NETs. NECs appear as large, darker than background-colored mucosa, ulcerated or necrotic lesions and, therefore, are difficult to distinguish from colorectal cancers. Historically, tumor size has always been a main predictor for survival and metastatic patterns of NENs [4].

Colonic NETs are more aggressive and have worse prognosis compared with rectal NETs, as was confirmed in our study. Survival of patients with NETs is generally more favorable than with NECs, because of the lesions' more slowly growing character compared to fast and aggressive tumor growth of NECs [37]. Our population-based data confirm these findings and those of the previously reported survival data in the SEER Program [6].

Even with early detection of NENs, metastatic disease can be present. In metastatic disease, treatment (surgical or systemic) may prolong survival. Therefore, it is highly relevant to detect these NENs at an early stage. Because treatment, and thereby prognosis, for patients with colonic and rectal NENs is different and depends on tumor size, local extent, grade, and stage [32], optimal endoscopic and histologic diagnosis is required [18]. Surveillance recommendations after complete resection of neuroendocrine neoplasms vary across international guidelines [3, 27], probably due to inconsistencies in definitions and diagnosis and limitations in the available data.

For those reasons, European Neuroendocrine Tumor Society (ENET) members have started to develop a training program in NET recognition for endoscopists [38]. In future studies, NENs have to be defined using WHO terms, diagnosed using WHO-recommended stains (i.e. synaptophysin), and their mitotic count and Ki-67 index should be determined [39, 40].

The strengths of our study are the regional population-based character with analysis of all colorectal NENs identified in our practices over a period of 15 years. We reviewed clinical and endoscopic features of NENs and graded them on histopathology according to the newest WHO classification.

The current study has several limitations. First, despite this large colonoscopy database, the number of NETs examined in our study was small, and is in line with previous studies. NETs could have been missed or underreported during endoscopy, because of insufficient awareness on the part of the endoscopist. Second, the CRC screening program in the Netherlands began in 2014, and only 2 years of screening were included in the 15-year study period. The period after 2015 was used to obtain adequate data for follow-up. Third, during the second half of our study period, high-definition (HD) endoscopy was gradually implemented, so only a subset of photos were collected and stored at HD quality. Optimal HD photo and video documentation will help lead to more detailed description of endoscopic characteristics and can be used for training purposes. Fourth, we need more photo/video documentation to describe colonic NETs in more detail. Although not statistically significant, their vascular pattern is most likely macroscopically different in comparison to other colonic neoplasia.

Colorectal NENs should be described according to the most recent WHO classification to assume uniform definitions and diagnosis. This will lead to further standardization and help to improve management and uniform surveillance recommendations in the guidelines on colorectal NENs.

Conclusions

In conclusion, our population-based data point to relatively stable and low incidence of 0.6 NENs per 1,000 patients in the Netherlands. Rectal NETs mainly present as small, sessile yellowish lesions. Colonic NETs present as larger and darker lesions than the background mucosa and NECs as darker lesions than the background with ulceration/necrosis. Adequate management of NENs requires training of endoscopists in recognition of specific features, followed by en-bloc resection and histological diagnosis. Training of endoscopists to recognize NENs

using videos and e-learning will provide the basis for appropriate endoscopic diagnosis and resection and for evidence-based surveillance recommendations.

Acknowledgments

The authors thank Drs. C.V. Hoge, gastroenterologist, Maastricht University Medical Center, the Netherlands; Dr. Z. Mujagic, gastroenterologist, Maastricht University Medical Center, the Netherlands; Drs. K. Soufidi, MD, Gastroenterologist, Zuyderland MC, Sittard-Geleen, the Netherlands; and Dr. J.W.A. Straathof, gastroenterologist, Maastricht University Medical Center, Maastricht and Maxima Medical Center, Veldhoven, the Netherlands, for their help in analyzing the colorectal NENS endoscopy reports and pictures. They also thank PALGA Corporation, the Netherlands, for their comprehensive search (IZV 2016–47).

Competing interests

The authors declare that they have no conflict of interest.

Clinical trial

Netherlands National Trial Register
NTR4844

Netherlands National Trial Register
NTR3093

TRIAL REGISTRATION: Multi-Center study NTR4844 and NTR3093 at <http://www.trialregister.nl>

References

- [1] Rindi G, Klimstra DS, Abedi-Ardekani B et al. A common classification framework for neuroendocrine neoplasms: an International Agency for Research on Cancer (IARC) and World Health Organization (WHO) expert consensus proposal. *Mod Pathol* 2018; 31: 1770–1786
- [2] Bosman FT, Carneiro F, Hruban RH et al. WHO classification of tumours of the digestive system. 4th ed. Lyon: IARC Press; 2010
- [3] Caplin M, Sundin A, Nillson O et al. ENETS Consensus Guidelines for the management of patients with digestive neuroendocrine neoplasms: colorectal neuroendocrine neoplasms. *Neuroendocrinology* 2012; 95: 88–97
- [4] Ramage JK, De Herder WW, Delle Fave G et al. ENETS Consensus Guidelines Update for Colorectal Neuroendocrine Neoplasms. *Neuroendocrinology* 2016; 103: 139–143
- [5] Leoncini E, Boffetta P, Shafir M et al. Increased incidence trend of low-grade and high-grade neuroendocrine neoplasms. *Endocrine* 2017; 58: 368–379
- [6] Yao JC, Hassan M, Phan A et al. One hundred years after “carcinoid”: epidemiology of and prognostic factors for neuroendocrine tumors in 35,825 cases in the United States. *J Clin Oncol* 2008; 26: 3063–3072
- [7] Fraenkel M, Kim M, Faggiano A et al. Incidence of gastroenteropancreatic neuroendocrine tumours: a systematic review of the literature. *Endocr Relat Cancer* 2014; 21: R153–R163
- [8] Chung TP, Hunt SR. Carcinoid and neuroendocrine tumors of the colon and rectum. *Clin Colon Rectal Surg* 2006; 19: 45–48
- [9] Scherübl H. Rectal carcinoids are on the rise: early detection by screening endoscopy. *Endoscopy* 2009; 41: 162–165
- [10] Scherübl H, Kloppel G. Rectal carcinoids on the rise – update. *Zeitschrift für Gastroenterologie* 2009; 47: 365–371
- [11] Basuroy R, O'Donnell CM, Srirajaskanthan R et al. Ileocolonic neuroendocrine tumours identified in the English bowel cancer screening programme. *Colorectal Dis* 2018; 20: O85–O91
- [12] Derix LA, Vierdag WM, Kievit W et al. Is the prevalence of colonic neuroendocrine tumors increased in patients with inflammatory bowel disease? *J Int Cancer* 2016; 139: 535–542
- [13] Hofland J, Kaltsas G, de Herder WW. Advances in the Diagnosis and management of well-differentiated neuroendocrine neoplasms. *Endocr Rev* 2020; 41: 371–403
- [14] Concors SJ, Sinnamon AJ, Folkert IW et al. Predictors of metastases in rectal neuroendocrine tumors: results of a national cohort study. *Dis Colon Rectum* 2018; 61: 1372–1379
- [15] Shimizu T, Tanaka S, Haruma K et al. Growth characteristics of rectal carcinoid tumors. *Oncology* 2000; 59: 229–237
- [16] Shim KN, Yang SK, Myung SJ et al. Atypical endoscopic features of rectal carcinoids. *Endoscopy* 2004; 36: 313–316
- [17] Eggenberger JC. Carcinoid and other neuroendocrine tumors of the colon and rectum. *Clin Colon Rectal Surg* 2011; 24: 129–134
- [18] Nagtegaal ID, Odze RD, Klimstra D et al. The 2019 WHO classification of tumours of the digestive system. *Histopathology* 2020; 76: 182–188
- [19] Jung YS, Yun KE, Chang Y et al. Risk factors associated with rectal neuroendocrine tumors: a cross-sectional study. *Cancer Epidemiol Biomarkers Prev* 2014; 23: 1406–1413
- [20] O'Toole D, Kianmanesh R, Caplin M. ENETS 2016 Consensus Guidelines for the Management of Patients with Digestive Neuroendocrine Tumors: An Update. *Neuroendocrinology* 2016; 103: 117–118
- [21] Update on the Paris classification of superficial neoplastic lesions in the digestive tract. *Endoscopy* 2005; 37: 570–578
- [22] Bisschops R, Hassan C, Bhandari P et al. BASIC (BLI Adenoma Serrated International Classification) classification for colorectal polyp characterization with blue light imaging. *Endoscopy* 2018; 50: 211–220
- [23] Patrun J, Okreša L, Iveković H et al. Diagnostic accuracy of NICE classification system for optical recognition of predictive morphology of colorectal polyps. *Gastroenterol Res Pract* 2018; 2018: 7531368
- [24] Taghavi S, Jayarajan SN, Powers BD et al. Examining rectal carcinoids in the era of screening colonoscopy: a surveillance, epidemiology, and end results analysis. *Dis Colon Rectum* 2013; 56: 952–959
- [25] Korse CM, Taal BG, van Velthuysen ML et al. Incidence and survival of neuroendocrine tumours in the Netherlands according to histological grade: experience of two decades of cancer registry. *Europ J Cancer* 2013; 49: 1975–1983
- [26] Brenner H, Kloor M, Pox CP. Colorectal cancer. *Lancet* 2014; 383: 1490–1502
- [27] Anthony LB, Strosberg JR, Klimstra DS et al. The NANETS consensus guidelines for the diagnosis and management of gastrointestinal neuroendocrine tumors (nets): well-differentiated nets of the distal colon and rectum. *Pancreas* 2010; 39: 767–774
- [28] Kuiper T, van Oijen MGH, van Velthuysen MF et al. Endoscopically removed rectal NETs: a nationwide cohort study. *International journal of colorectal disease* 2021; 36: 535–541
- [29] Konishi T, Watanabe T, Kishimoto J et al. Prognosis and risk factors of metastasis in colorectal carcinoids: results of a nationwide registry over 15 years. *Gut* 2007; 56: 863–868
- [30] Madani A, Thomassen I, van Gestel Y et al. Peritoneal metastases from gastroenteropancreatic neuroendocrine tumors: incidence, risk factors and prognosis. *Ann Surg Oncol* 2017; 24: 2199–2205
- [31] Hotz HG, Bojarski C, Buhr HJ. Neuroendocrine colorectal tumors. Surgical and endoscopic treatment. *Chirurg* 2011; 82: 607–611

- [32] Hrabe J. Neuroendocrine tumors of the appendix, colon, and rectum. *Surg Oncol Clin N Am* 2020; 29: 267–279
- [33] Vecchio R, Ferrara M, Mosca F et al. Lipomas of the large bowel. *Eur J Surg* 1996; 162: 915–919
- [34] Law YY, Patel R, Cusick M et al. A case of colonic intussusception and obstruction secondary to giant colonic lipoma. *J Surg Case Rep* 2020; 2020: rjaa429
- [35] Hsu-Heng Y. Colonic lipoma. *Video J Encyclop GI Endosc* 2014; 1: 661–662
- [36] Ford MM. Neuroendocrine tumors of the colon and rectum. *Dis Colon Rectum* 2017; 60: 1018–1020
- [37] Arnold R. Endocrine tumours of the gastrointestinal tract. Introduction: definition, historical aspects, classification, staging, prognosis and therapeutic options. *Best Pract Res Clin Gastroenterol* 2005; 19: 491–505
- [38] Ramage JK, Valle JW, Nieveen van Dijkum EJM et al. Colorectal Neuroendocrine neoplasms: areas of unmet need. *Neuroendocrinology* 2019; 108: 45–53
- [39] Gao W, Liu SM, Lu HZ et al. Analysis of clinicopathological features of intestinal neuroendocrine neoplasms. *Zhonghua zhong liu za zhi [Chinese J Oncol]* 2012; 34: 450–456
- [40] Wang AY, Ahmad NA. Rectal carcinoids. *Curr Opin Gastroenterol* 2006; 22: 529–535