Article published online: 2022-02-15

Partially covered self-expandable metal stent with antimigratory single flange plays important role during EUS-guided hepaticogastrostomy

Authors
Masahiro Yamamura, Takeshi Ogura, Saori Ueno, Atsushi Okuda, Nobu Nishioka, Masanori Yamada, Kazuya Ueshima, Jun Matsuno, Yoshitaro Yamamoto, Kazuhide Higuchi

Institution
2nd Department of Internal Medicine, Osaka Medical College, Osaka, Japan

submitted 10.9.2021
accepted after revision 19.10.2021

Bibliography
Endosc Int Open 2022; 10: E209–E214
DOI 10.1055/a-1729-0048
ISSN 2364-3722
© 2022. The Author(s).
This is an open access article published by Thieme under the terms of the Creative Commons Attribution-NonDerivative-NonCommercial License, permitting copying and reproduction so long as the original work is given appropriate credit. Contents may not be used for commercial purposes, or adapted, remixed, transformed or built upon. (https://creativecommons.org/licenses/by-nc-nd/4.0/)
Georg Thieme Verlag KG, Rüdigerstraße 14, 70469 Stuttgart, Germany

Corresponding author
Takeshi Ogura, 2nd Department of Internal Medicine, Osaka Medical College, 2-7 Daigakuchou, Takatsukishi, Osaka 569-8686, Japan
Fax: +81-726846532
oguratakeshi0411@yahoo.co.jp

ABSTRACT

Background and study aims Stent migration into the abdominal cavity, which can occur due to stent shortening or stomach mobility, is a critical adverse event (AE) in EUS-HGS. To prevent this AE due to stent shortening, a novel, partially covered self-expandable metal stent with an antimigratory single flange has recently become available in Japan. The present study evaluated the clinical feasibility and safety of EUS-HGS using this novel stent.

Patients and methods We measured stent length in the abdominal cavity and the luminal portion after EUS-HGS using computed tomography (CT) performed 1 day after EUS-HGS (early phase). To evaluate stent shortening and the influence of stomach mobility, we also measured stent length at the same sites on CT performed at least 7 days after EUS-HGS (late phase).

Results Thirty-one patients successfully underwent EUS-HGS using this stent. According to CT in the early phase, stent length in the abdominal cavity was 7.13 ± 2.11 mm and the length of the luminal portion was 53.3 ± 6.27 mm. Conversely, according to CT in the late phase, stent length in the abdominal cavity was 8.55 ± 2.36 mm and the length of the luminal portion was 50.0 ± 8.36 mm. Stent shortening in the luminal portion was significantly greater in the late phase than in the early phase ($P = 0.04$).

Conclusions CT showed that stent migration can occur even with successful stent deployment, due to various factors such as stent shortening. The antimigratory single flange may be helpful to prevent stent migration, but further prospective comparative studies are needed to confirm our results.

Introduction

Endoscopic biliary drainage for malignant biliary obstruction is usually achieved under endoscopic retrograde cholangiopancreatography (ERCP) guidance [1]. ERCP is widely accepted as an effective drainage technique, but might be challenging in patients with duodenal obstruction caused by malignant tumors such as cancer of the pancreatic head, or with surgically altered anatomy. In such situations, percutaneous transhepatic biliary drainage (PTBD) represents an alternative biliary drainage technique. However, several disadvantages of PTBD have been described, such as the external drainage or the risk of self-tube removal [2]. Endoscopic ultrasound-guided biliary drainage (EUS-BD), therefore, has been developed as an alternative biliary drainage technique [3–9]. Among EUS-BD techniques, EUS-guided hepaticogastrostomy (HGS) can be per-

formed for patients with duodenal obstruction or surgically altered anatomy. The indications for this technique are highly variable and opportunities to perform it may thus be comparatively high. However, although the technical success rate for EUS-HGS has been reported as favorable, severe adverse events (AEs) such as stent migration into the abdominal cavity can occur [10–13]. Recently, a novel, partially covered self-expandable metal stent (PCSEMS) with an antimigratory single flange has become available in Japan. The present study evaluated the clinical feasibility and safety of EUS-HGS using this novel stent.

Patients and methods

This preliminary study included consecutive patients in whom EUS-HGS was attempted between October 2020 and April 2021. All study protocols were approved by the institutional review board of our hospital. The study protocol conformed to the ethical guidelines of the 1975 Declaration of Helsinki as reflected in the a priori approval given by the human research committee at Osaka Medical College.

Partially covered self-expandable metal stent with antimigratory single flange (▶ Video 1)

▶ **Fig. 1a** shows the PCSEMS with antimigratory single flange (PCSEMS-AF) (Spring Stopper; Taewoong Medical, Seoul, Korea). This stent is made of braided nitinol wire, partially covered by a silicone membrane. The distal end has a 1.5-cm uncovered portion (▶ **Fig. 1a**) and the proximal end has a lumen-apposing system (▶ **Fig. 1b**). This lumen-apposing system can prevent stent migration into the abdominal cavity because the proximal end is expanded up to 16 mm and acts to oppose movement of the stent toward the abdominal cavity (▶ **Fig. 1c**, ▶ **Fig. 1d**). In addition, this stent is available in lengths of 10 cm or 12 cm. Stent migration is thus difficult. This study used stents 8 mm in diameter, and 10 cm or 12 cm in length. The stent delivery system was 8.5 Fr.

VIDEO



▶ **Video 1** Experimental study of the partially covered self-expandable metal stent with antimigratory single flange. If the stent is pulled, the anchoring function is seen to be strong.



▶ **Fig. 1** Partially covered self-expandable metal stent with antimigratory single flange (PCSEMS-AF) (Spring Stopper; Taewoong Medical, Seoul, Korea). **a** The distal portion is uncovered to prevent stent dislocation. **b** The proximal site has a lumen-apposing system. **c** Image of stent deployment in the stomach. **d** If the stent is pulled into the abdominal cavity, stent migration is impeded by the lumen-apposing system.

Technical tips for EUS-HGS

A GF-UGT260 echoendoscope (Olympus Optical, Tokyo, Japan) was advanced into the stomach, and the intrahepatic bile duct (IHBD) was identified. First, the IHBD duct of segment three was detected as the puncture site. Bile duct puncture was carefully and gently performed using a 19-G needle (EZ Shot; Olympus, Tokyo, Japan). After aspirating bile juice, the contrast medium was injected (▶ **Fig. 2a**). A 0.025-inch guidewire (VisiGlide 1; Olympus Medical Systems, Tokyo, Japan) then was inserted into the IHBD through the needle. If the guidewire was advanced into the periphery of the bile duct, the liver impaction technique was attempted to manipulate the guidewire [14]. Briefly, the guidewire was adequately pushed into the peripheral bile duct, then the needle itself was pulled back into the hepatic parenchyma. Because the tip of the needle was within the hepatic parenchyma, guidewire sharing may be prevented. After successful deployment of the guidewire into the hepatic hilar or common bile duct (▶ **Fig. 2b**), the IHBD and stomach wall were dilated using a 4-mm balloon catheter (REN biliary balloon catheter; KANEKA, Osaka, Japan) or ultra-tapered mechanical dilator (EZ dilator; Zeon Medical Inc., Tokyo, Japan) (▶ **Fig. 2c**). The stent delivery system of the PCSEMS-AF was inserted into the IHBD (▶ **Fig. 2d, e**). To prevent stent migration, stent deployment from the IHBD to the stomach was performed using an intra-scope channel release technique, as previously described [15].

Definitions and statistical analysis

The main outcome of this preliminary study was the technical success rate for EUS-HGS using PCSEMS-AF. Secondary outcomes were the kinds of AEs. Technical success was defined as successful stent deployment from the IHBD to the stomach.

▶ **Fig. 2** **a** The intrahepatic bile duct is punctured, and the contrast medium is injected. **b** The 0.025-inch guidewire is inserted into the biliary tract. **c** The intrahepatic bile duct and stomach wall are dilated using an ultra-tapered mechanical dilator. **d** Endoscopic ultrasound-guided hepaticogastrostomy using the novel metal stent is successfully performed. **e** Endoscopic image of the novel metal stent.

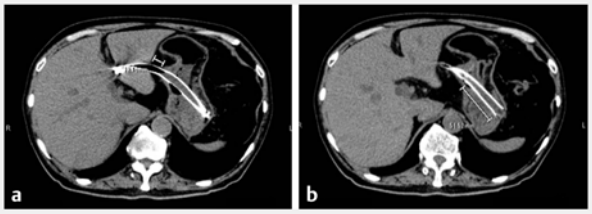

▶ **Fig. 3** Measurement of stent length in the **a** abdominal cavity and **b** luminal portion.

Clinical success was defined as a reduction in serum total bilirubin level by 50 % and resolution of symptoms related to biliary tract obstruction within 2 weeks. All patients underwent computed tomography (CT) 1 day after EUS-HGS. We also measured stent length in the abdominal cavity and the luminal portion after EUS-HGS using CT performed 1 day after EUS-HGS (early phase) (▶ **Fig. 3a**, ▶ **Fig. 3b**). Fistula creation may take at least 7 days, according to our previous study [16]. Therefore, we also measured stent length at the same sites on CT performed at least 7 days after EUS-HGS (late phase). Procedure time was measured from scope insertion to successful stent deployment. Peritonitis was diagnosed if clinical symptoms of peritoneal inflammation and/or corresponding fluid collection on CT were observed. These data were corrected as average values after five measurements by three doctors. Stent dysfunction was considered present if jaundice recurred with clinical imaging findings such as biliary tract dilation or cholangitis. Stent patency was measured from EUS-HGS to stent dysfunction or death of the patient. These data were also statistically compared using T-tests. When fluid collection was absent on CT despite the presence of abdominal pain, the abdominal pain was not defined as peritonitis [17]. Descriptive statistics are presented as mean (± standard deviation), median (interquartile range [IQR]) and frequency for continuous and categorical variables. Survival curves for stent patency were estimated using the Kaplan-Meier method. AEs associated with EUS-HGS procedures were evaluated according to the severity grading system of the American Society for Gastrointestinal Endoscopy lexicon [18].

▶ **Table 1** Patient characteristics.

Total no. patients (n)	31
Age (year, median [range])	74 [55–87]
Sex (male:female)	23:8
Underlying pathology (n)	
▪ Pancreatic cancer	20
▪ Bile duct cancer	9
▪ Gastric cancer	2
Reasons for EUS-HGS (n)	
▪ Duodenal obstruction	16
▪ Surgically altered anatomy	15
Puncture site (n)	
▪ Segment 2	0
▪ Segment 3	31
Diameter of IHBD (mm, mean ± SD)	4.19 ± 0.97
Procedure time (min, mean ± SD)	17.7 ± 3.76
Kind of device for tract dilation (n)	
▪ Ultra-tapered mechanical dilator	9
▪ Balloon catheter	22
T-Bil (mg/dL, mean ± SD)	9.20 ± 3.76
AST (U/L, mean ± SD)	131.1 ± 104.7
ALT (U/L, mean ± SD)	159.7 ± 148.3
Presence of ascites, n	2

EUS-HGS, endoscopic ultrasound-guided hepaticogastrostomy; IHBD, intrahepatic bile duct; SD, standard deviation; T-Bil, total bilirubin; AST, aspartate transaminase; ALT, alanine aminotransferase.

Results

A total of 31 patients (median age, 74 years; IQR, 55.00–87.00 years; 23 males) were enrolled in this study. ▶ **Table 1** shows the background characteristics of patients. The primary cancer in these patients was pancreatic in 20 patients, bile duct in

▶ **Table 2** Clinical outcomes

Technical success, % (n)	100 (31/31)
Clinical success, % (n)	93.5 (29/31)
Adverse events, n	
▪ Peritonitis	0
▪ Abdominal pain	1
▪ Stent migration	0
▪ Cholangitis	1
Stent length in early phase (mm, mean ± SD)	
▪ Abdominal cavity	7.13 ± 2.11
▪ Luminal portion	53.3 ± 6.27
Stent length after late phase (mm, mean ± SD)	
▪ Abdominal cavity	8.55 ± 2.36
▪ Luminal portion	50.0 ± 8.36
Median duration of CT scan in late phase (days [IQR])	14 [7.00, 25.00]

SD, standard deviation; CT, computed tomography; IQR, interquartile range.

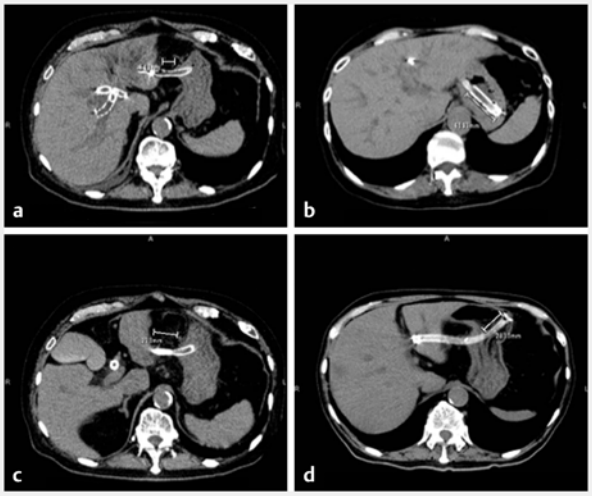

▶ **Fig. 4** **a** The length of stent in the abdominal cavity is 16.4 mm according to CT at 1 day after EUS-HGS. **b** The length of stent in the luminal portion is 40.9 mm according to CT at 1 day after EUS-HGS. **c** The length of stent in the abdominal cavity is 29.3 mm according to CT at 10 days after EUS-HGS. **d** The length of stent in the luminal portion is 28.1 mm according to CT at 10 days after EUS-HGS.

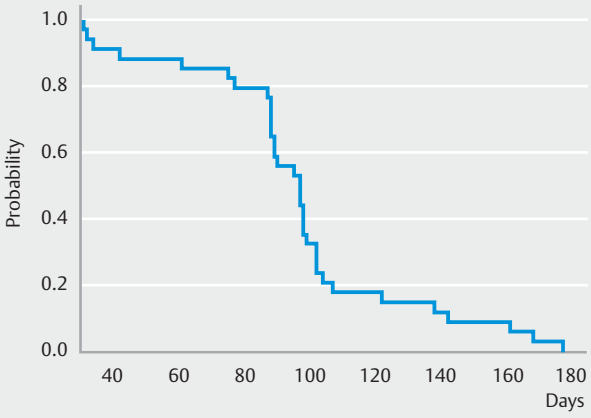

▶ **Fig. 5** Median duration of stent patency is 97 days (95 %CI, 88–99 days) according to survival curves.

nine, and gastric cancer in two. EUS-HGS was performed based on duodenal obstruction (n = 16) or surgically altered anatomy (n = 15). As a puncture site, the IHBD in segment three was selected in all patients. Mean diameter of the puncture site was 4.19 ± 0.97 mm. Mean procedure time was 17.7 ± 3.76 minutes. During the IHBD and stomach wall dilation, an ultra-tapered mechanical dilator was used in nine patients and a balloon dilation catheter was used in 22 patients. Laboratory data (mean ± SD) before EUS-HGS were as follows: 9.20 ± 3.76 mg/dL; aspartate aminotransferase, 131.1 ± 104.7 IU/L; and alanine aminotransferase, 159.7 ± 148.3 IU/L. A small volume of ascites was observed around the liver before EUS-HGS in two patients.

▶ **Table 2** shows clinical outcomes. Technical success was achieved in all patients (100 %, 31/31). Clinical success was also obtained in 29 patients (93.5 %). AEs were observed in two patients (6.5 %, 2/31; abdominal pain, n = 1; cholangitis, n = 1), and were successfully treated with conservative therapy. According to early-phase CT, length in the abdominal cavity was 7.13 ± 2.1 mm [95 % confidence interval (CI) 6.32–7.93 mm], and length of the luminal portion was 53.3 ± 6.27 mm (95 %CI 48.8–54.9). On the other hand, according to late-phase CT imaging, length in the abdominal cavity was 8.55 ± 2.4 mm (95 %CI 7.74–9.35 mm) and length of the luminal portion was 5.00 ± 8.4 mm (95 %CI 46.76–52.08 mm). Extensive stent shortening was observed in two patients (12 mm and 17 mm). Stent length in the luminal portion was shortened before the early phase (▶ **Fig. 4**). ▶ **Fig. 5** shows survival curves for stent patency. Stent dysfunction was observed in two patients due to recurrent obstructive jaundice during clinical follow-up (median, 102 days; range, 31–211 days). Stent obstruction was observed at the partially covered site caused by hyperplasia, so we successfully performed stent deployment. Median stent patency was 97 days (95 %CI, 88–99 days). Finally, although stent migration into the abdominal cavity was not seen in any patients, stent shortening in the luminal portion was significantly greater in the late phase than in the early phase (P = 0.042).

Discussion

Although EUS-HGS has clinical benefits for selected patients excepted for absence of viable liver, such as atrophic segments or occupation by a huge tumor, EUS-HGS also results in critical AEs, such as stent migration into the abdominal cavity follow-

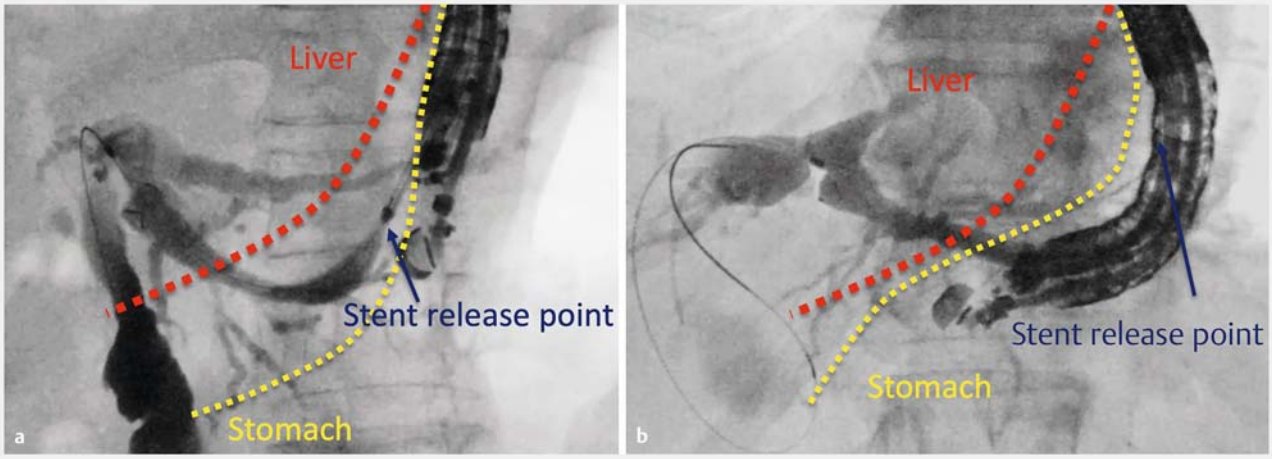

▶ **Fig. 6** **a** If the up angle of the echoendoscope is not used during stent release, stent release was performed within the abdominal cavity. **b** If the angle of the echoendoscope is usually the full up angle during stent release, the hepatic parenchyma and stomach wall may be closely attached during EUS-HGS.

ing EUS-BD procedures [10–13]. Various efforts to prevent stent migration into the abdominal cavity have been reported from the perspective of technical tips for stent deployment and kinds of metal stent. In our study, EUS-HGS using PCSEMS-AF was performed in 21 patients, with no migration or dislocation observed in any patients. In addition, to the best of our knowledge, our study may be the first to evaluate stent lengths in the abdominal and luminal portions, not only in the early phase, but also in the late phase.

Stent migration occurs as a complication in two situations. First, it can occur during EUS-HGS. Naturally, no adhesion exists between the hepatic parenchyma and stomach wall. The distance between these organs differs between individuals. If this distance is longer, the risk of stent migration may be increased. In addition, the stomach itself shows mobility. If the up angle of the echoendoscope is not used during stent release (▶ **Fig. 6a**), no adhesion will occur between these organs. For these reasons, stent migration can occur during stent deployment because stent release is performed within the abdominal cavity. On the other hand, if the angle of the echoendoscope is usually the full up angle during stent release (▶ **Fig. 6b**), the hepatic parenchyma and stomach wall may be closely attached during EUS-HGS. Indeed, according to our previous study [15], the distance between the hepatic parenchyma and stomach wall after EUS-HGS was significantly shorter in the intra-scope channel stent release group (0.66 ± 1.25 mm) than in the extra-scope channel release group (2.52 ± 0.97 mm, $P < 0.05$). Therefore, if the intra-scope technique is performed, adhesion between these organs may occur, so stent migration into the abdominal cavity may be prevented, at least during EUS-HGS stent deployment.

However, the present study revealed some useful findings. Compared with the early phase, the length of the luminal portion was significantly shorter in the late phase according to CT. This suggests that stent migration would occur if an intra-scope channel release technique were to be applied. This phenomenon may be based on shortening of the stent itself and stomach mobility. According to our previous study [16], creation of a fistula between the hepatic parenchyma and stomach wall takes at least 7 days. Until fistula creation, fatal events can occur if stent migration arises as a complication. Careful attention, therefore, should be paid, not only to the technique of stent deployment, but also to the antimigratory function of the EUS-HGS stent because stent shortening will occur according to our findings from CT.

As a study into kinds of EUS-HGS stent, Cho et al. reported long-term outcomes for a newly developed hybrid metal stent for EUS-BD [19]. In that study, 21 patients underwent EUS-HGS using a hybrid metal stent. The stent was a PCSEMS, and the length of the uncovered site was 1.5 cm to 6.5 cm. The covered portion had proximal and distal anchoring flaps to prevent stent migration. EUS-HGS using a hybrid metal stent was successfully performed in all 21 patients, with clinical success in 18 patients (85.7 %). As early AEs, pneumoperitoneum (n = 2), bleeding (n = 1), and abdominal pain (n = 1) were observed, but no stent migration was seen. In addition, stent migration was not observed in any patients during follow-up (median 148.5 days; IQR, 79.7–244 days). They therefore concluded that EUS-BD with the hybrid metal stent can reduce stent-related AEs, especially stent migration. However, stent migration into the abdominal cavity has still been reported even using that hybrid stent [13]. To prevent stent migration into the abdominal cavity, improvements to anti-migration systems are needed. The lumen-apposing metal stent is a well-known design for anti-migration systems in pancreatic fluid collection drainage and EUS-guided gallbladder drainage [20, 21]. A similar stent design was used in the lumen-apposing system of the present study, and the anchoring function might thus have been stronger than with other systems, although a comparative study is warranted to verify our results.

Stent dislocation should be considered as a significant AE. If the fistula has also not yet been completed, this AE is critical. To prevent stent dislocation, we believe the uncovered site may play an important role. Indeed, several reports have examined dislocation of a fully covered self-expandable metal stent (FCSEMS). Okuno et al conducted a prospective study of 20 patients with EUS-HGS using a 6-mm FCSEMS [22]. Although technical and clinical success was obtained in all patients, stent dislocation was observed in four patients. In a similar study, Maehara et al reported a case series of EUS-HGS using FCSEMS [12]. Stent dislocation was observed in 20 % of cases during follow-up (median, 76.5 days; range, 8–212 days). Although a strict prospective randomized controlled study comparing PCSEMS and FCSEMS is needed, we considered that EUS-HGS using PCSEMS may be suitable.

The present study had several limitations, including the small size of the cohort and the retrospective, single-arm design. Although these limitations might be critical, our preliminary results including stent lengths in the abdominal cavity and luminal portions in the early and late phases may provide landmarks for further investigations.

Conclusions

In conclusion, EUS-HGS using PCSEMS-AF appears clinically feasible and safe. Although stent migration may be prevented by this anti-migration system, further prospective comparative studies are needed to confirm our results.

Competing interests

The authors declare that they have no conflict of interest.

References

[1] Fogel EL, Sherman S, Devereaux BM et al. Therapeutic biliary endoscopy. Endoscopy 2001; 33: 31–38

[2] Carrasco CH, Zornoza J, Bechtel WJ. Malignant biliary obstruction: complications of percutaneous biliary drainage. Radiology 1984; 152: 343–346

[3] Dhindsa BS, Mashiana HS, Dhaliwal A et al. EUS-guided biliary drainage: A systematic review and meta-analysis. Endosc Ultrasound 2020; 9: 101–109

[4] Kakked G, Salameh H, Cheesman AR et al. Primary EUS-guided biliary drainage versus ERCP drainage for the management of malignant biliary obstruction: A systematic review and meta-analysis. Endosc Ultrasound 2020; 9: 298–307

[5] Miller CS, Barkun AN, Martel M et al. Endoscopic ultrasound-guided biliary drainage for distal malignant obstruction: a systematic review and meta-analysis of randomized trials. Endosc Int Open 2019; 7: E1563–E1573

[6] Itoi T, Isayama H, Sofuni A et al. Stent selection and tips on placement technique of EUS-guided biliary drainage: transduodenal and transgastric stenting. J Hepatobiliary Pancreat Sci 2011; 18: 664–672

[7] Sun B, Moon JH, Cai Q et al. Review article: Asia-Pacific consensus recommendations on endoscopic tissue acquisition for biliary strictures. Aliment Pharmacol Ther 2018; 48: 138–151

[8] Ogura T, Higuchi K. Endoscopic ultrasound-guided gallbladder drainage: Current status and future prospects. Dig Endosc 2019; 31: (Suppl. 01): 55–64

[9] El Chafic AH, Shah JN. Advances in biliary access. Curr Gastroenterol Rep 2020; 22: 62

[10] Martins FP, Rossini LG, Ferrari AP. Migration of a covered metallic stent following endoscopic ultrasound-guided hepaticogastrostomy: fatal complication. Endoscopy 2010; 42: E126–E127

[11] Kamata K, Takenaka M, Minaga K et al. Stent migration during EUS-guided hepaticogastrostomy in a patient with massive ascites: Troubleshooting using additional EUS-guided antegrade stenting. Arab J Gastroenterol 2017; 18: 120–121

[12] Okuno N, Hara K, Mizuno N et al. Stent migration into the peritoneal cavity following endoscopic ultrasound-guided hepaticogastrostomy. Endoscopy 2015; 47: E311

[13] Yang MJ, Kim JH, Kim DJ et al. Hepatobiliary and pancreatic: EUS-guided reintervention for extraluminal stent migration after EUS-guided hepaticogastrostomy. J Gastroenterol Hepatol 2018; 33: 772

[14] Ogura T, Masuda D, Takeuchi T et al. Liver impaction technique to prevent shearing of the guidewire during endoscopic ultrasound-guided hepaticogastrostomy. Endoscopy 2015; 47: E583–E584

[15] Miyano A, Ogura T, Yamamoto K et al. Clinical impact of the intrascope channel stent release technique in preventing stent migration during EUS-guided hepaticogastrostomy. J Gastrointest Surg 2018; 22: 1312–1318

[16] Ogura T, Nishioka N, Yamada MY et al. Novel transluminal treatment protocol for hepaticojejunostomy stricture using covered self-expandable metal stent. Surg Endosc 2021; 35: 209–215

[17] Nakai Y, Sato T, Hakuta R et al. Long-term outcomes of a long, partially covered metal stent for EUS-guided hepaticogastrostomy in patients with malignant biliary obstruction (with video). Gastrointest Endosc 2020; 92: 623–631.e1

[18] Cotton PB, Eisen GM, Aabakken L et al. A lexicon for endoscopic adverse events: report of an ASGE workshop. Gastrointest Endosc 2010; 71: 446–454

[19] Cho DH, Lee SS, Oh D et al. Long-term outcomes of a newly developed hybrid metal stent for EUS-guided biliary drainage (with videos). Gastrointest Endosc 2017; 85: 1067–1075

[20] Chandrasekhara V, Barthet M, Devière J et al. Safety and efficacy of lumen-apposing metal stents versus plastic stents to treat walled-off pancreatic necrosis: systematic review and meta-analysis. Endosc Int Open 2020; 8: E1639–E1653

[21] Teoh AYB, Kitano M, Itoi T et al. Endosonography-guided gallbladder drainage versus percutaneous cholecystostomy in very high-risk surgical patients with acute cholecystitis: an international randomised multicentre controlled superiority trial (DRAC 1). Gut 2020; 69: 1085–1091

[22] Okuno N, Hara K, Mizuno N et al. Efficacy of the 6-mm fully covered self-expandable metal stent during endoscopic ultrasound-guided hepaticogastrostomy as a primary biliary drainage for the cases estimated difficult endoscopic retrograde cholangiopancreatography: A prospective clinical study. J Gastroenterol Hepatol 2018; 33: 1413–1421