Artikel online veröffentlicht: 24.05.2022

On the Current Care Situation and Treatment of Ocular Mucous Membrane Pemphigoid in Germany

Zur Versorgungssituation und konservativen Therapie des okulären vernarbenden Schleimhautpemphigoids in Deutschland

Authors

Rémi Yaïci[1], Mathias Roth[1], Lukas Juergens[1], Sami Al Nawaiseh[2], Dick Burkhard[3], Volker Besgen[4], Matthias Fuest[5], Christian Girbardt[6], Ulrike Hampel[7], Jens Heichel[8], Arnd Heiligenhaus[9], Martina C. Herwig-Carl[10], Vinodh Kakkassery[11], Kalliopi Kontopoulou[12], Karin U. Löffler[10], Philip Christian Maier[13], Bernhard Nölle[14], Johanna Pach[15], Sebastian Paul[16], Uwe Pleyer[17], Michael Pöllmann[18], Mark Saeger[14], Enno Schmidt[19], Sebastian Siebelmann[20], Ekatarina Sokolenko[21], Lisa Strudel[22], Nicole Stübiger[23], Melih Tarhan[24], Johanna Theuersbacher[25], Christian van Oterendorp[26], Marten Walker[27], Carolin Wiecha[28], Agata Anna Wykrota[29], Gerd Geerling[1]

Affiliations

1 Klinik für Augenheilkunde, Universitätsklinikum Düsseldorf, Deutschland
2 Klinik für Augenheilkunde, Universitätsklinikum Münster, Deutschland
3 Klinik für Augenheilkunde, Universitätsklinikum der Ruhr-Universität Bochum, Deutschland
4 Klinik für Augenheilkunde, Universitätsklinikum Gießen und Marburg – Standort Marburg, Deutschland
5 Augenheilkunde, Universitätsklinikum Aachen, Deutschland
6 Klinik für Augenheilkunde, Universitätsklinikum Leipzig, Deutschland
7 Klinik für Augenheilkunde, Universitätsmedizin der Johannes Gutenberg-Universität Mainz, Deutschland
8 Klinik für Augenheilkunde, Universitätsklinikum Halle, Deutschland
9 Uveitis Zentrum, Augenzentrum am St Franziskus-Hospital Münster, Deutschland
10 Universitäts-Augenklinik, Universitätsklinikum Bonn, Deutschland
11 Klinik für Augenheilkunde, Universitätsklinikum Schleswig-Holstein, Campus Lübeck, Deutschland
12 Klinik für Augenheilkunde, Sankt-Johannes-Hospital Dortmund, Deutschland
13 Klinik für Augenheilkunde, Universitätsklinikum Freiburg, Deutschland
14 Klinik für Ophthalmologie, Universitätsklinikum Schleswig-Holstein, Kiel, Deutschland
15 Augenklinik, Klinikum Stuttgart, Deutschland
16 Klinik für Augenheilkunde, Universitätsklinikum Greifswald, Deutschland
17 Universitäts-Augenklinik, Charité – Universitätsmedizin Berlin, Deutschland
18 Klinik für Augenheilkunde, Universitätsklinikum Regensburg, Deutschland
19 Klinik für Dermatologie, Universitätsklinikum Schleswig-Holstein, Campus Lübeck, Deutschland
20 Zentrum für Augenheilkunde, Klinikum der Universität zu Köln, Deutschland
21 Klinik für Augenheilkunde, Universitätsklinikum Essen, Deutschland
22 Klinik für Augenheilkunde, Universitätsklinikum Tübingen, Deutschland
23 Klinik und Poliklinik für Augenheilkunde, Universitätsklinikum Hamburg-Eppendorf, Deutschland
24 Klinik für Augenheilkunde, Universitätsklinikum Jena, Deutschland
25 Klinik für Augenheilkunde, Universitätsklinikum Würzburg, Deutschland
26 Klinik für Augenheilkunde, Universitätsklinikum Göttingen, Deutschland
27 Universitätsklinik für Augenheilkunde, Klinikum Oldenburg AöR, Deutschland
28 Klinik für Augenheilkunde, Klinikum der Universität München, Deutschland
29 Klinik für Augenheilkunde, Universitätsklinikum des Saarlandes, Homburg/Saar, Deutschland

Key words

survey, mucous membrane pemphigoid, immunosuppression, register, Germany, therapy

Schlüsselwörter

Umfrage, Schleimhautpemphigoid, Therapie, Immunsuppression, Register, Deutschland

received	30.9.2021
accepted	10.12.2021
published online	24.5.2022

Dieses Dokument wurde zum persönlichen Gebrauch heruntergeladen. Vervielfältigung nur mit Zustimmung des Verlages.

Bibliography
Klin Monatsbl Augenheilkd 2023; 240: 1077–1083
DOI 10.1055/a-1720-1819
ISSN 0023-2165
© 2022. Thieme. All rights reserved.
Georg Thieme Verlag KG, Rüdigerstraße 14,
70469 Stuttgart, Germany

Correspondence
Rémi Yaïci
Klinik für Augenheilkunde, Universitätsklinikum Düsseldorf
Moorenstraße 5, 40225 Düsseldorf, Deutschland
Phone: + 49 (0) 21 18 11 73 20, Fax: + 49 (0) 21 18 11 62 41
yaici.remi@orange.fr

ABSTRACT

Background Ocular involvement in mucous membrane pemphigoid (MMP) is relatively rare, with a prevalence of 25 cases per million population, equating to approx. 2,100 patients throughout Germany. Diagnosis can be difficult – especially in cases of isolated ocular involvement – and treatment can be complex and lengthy. Immunosuppressants or immunomodulatory drugs are often used. Due to the complexity of diagnosis and treatment, MMP patients are usually referred to specialized centers. The aim of this project was to evaluate the current care situation of patients with ocular MMP in Germany.

Methods A paper-based survey was designed and sent to all university eye clinics and other specialized centers in Germany in April 2020. The survey asked about the existence of a specialized outpatient service, the total annual number of patients with MMP, the annual number of newly diagnosed patients, any interdisciplinary collaboration for diagnostic or therapeutic purposes, as well as the local and systemic therapy used.

Results Of a total of 44 clinics, 28 (64%) responded, reporting a total average of 27 ± 42 (0–200) patients and 3.6 ± 2.2 (0–10) new cases per year. This corresponds to a total of 741 patients. Only nine (32%) of the responding clinics offer specialized MMP clinics. 93% of the centers collaborate with the local dermatology department. 79% perform serological and histological diagnostics in-house. About half of the centers (n = 16) apply a standardized treatment regime. Systemic glucocorticoids (66.7%) are most commonly used, followed by mycophenolate mofetil and dapsone (57.1%), rituximab (33.3%), azathioprine and cyclophosphamide (28.6%), as well as methotrexate (19.0%). The least frequently used treatment is intravenous immunoglobulin (14.3%).

Conclusion This survey of German ophthalmology departments obtained data from about one third of the estimated total cohort of all patients with MMP in Germany. These are presumed to be exclusively patients with at least one ocular involvement. The complex care of these patients is usually provided in collaboration with a dermatologist and with the use of systemic anti-inflammatory medication. Currently, an ophthalmological MMP register is being established to better record the epidemiology and care situation of this rare disease in Germany and to improve it in the long term.

ZUSAMMENFASSUNG

Hintergrund Die okuläre Beteiligung bei vernarbendem Schleimhautpemphigoid (SHP) ist mit einer Prävalenz von 25 Fällen je 1 Mio. Einwohner und damit ca. 2100 Patienten in ganz Deutschland selten. Die Diagnosestellung kann – besonders in Abwesenheit anderer Beteiligungen – schwierig und die Therapie komplex und langwierig sein. Nicht selten kommen Immunsuppressiva zum Einsatz. Aufgrund der Komplexität von Diagnose und Therapie sind SHP-Patienten meist an entsprechend spezialisierte Zentren angebunden. Ziel dieses Projektes war die Erfassung der aktuellen augenärztlichen Versorgungssituation von Patienten mit SHP in Deutschland.

Methoden Eine papierbasierte Umfrage wurde konzipiert und im April 2020 an alle Universitätsaugenkliniken und weitere potenzielle Zentren versandt. Gefragt wurde nach dem Bestehen einer spezialisierten Sprechstunde, der jährlichen Gesamtzahl der betreuten Patienten, der jährlichen Anzahl von neu diagnostizierten Patienten, den klinischen Kooperationspartnern in Diagnostik und Therapie sowie nach der angewendeten lokalen und systemischen Therapie.

Ergebnisse Von insgesamt 44 angeschrieben Kliniken erfolgten 28 (64%) vollständige Rückmeldungen. Im Mittel werden in den Kliniken 27 ± 42 (0–200) Patienten betreut und jährlich pro Zentrum 3,6 ± 2,2 (0–10) neue Fälle diagnostiziert. Dies entspricht einer Gesamtpatientenzahl von 741 Patienten. Lediglich 9 (32%) der antwortenden Kliniken bieten eine spezialisierte SHP-Sprechstunde an. 93% der Zentren kooperieren mit der lokalen Klinik für Dermatologie. 79% führen die serologische und histologische Diagnostik intern durch. Etwa die Hälfte der Zentren (n = 16) wendet ein standardisiertes Therapieschema an. Systemisch werden Glukokortikoide (66,7%) am häufigsten verwendet, gefolgt von Mycophenolatmofetil und Dapson (57,1%), Rituximab (33,3%), Azathioprin und Cyclophosphamid (28,6%) sowie Methotrexat (19,0%). Am seltensten werden i. v. Immunoglobuline eingesetzt (14,3%).

Schlussfolgerung Mit dieser Umfrage unter deutschen augenärztlichen Zentren wurden Daten von etwa einem Drittel der geschätzten Gesamtzahl aller in Deutschland an einem SHP erkrankten Menschen erhoben. Dabei handelt es sich vermutlich ausschließlich um Patienten mit mindestens einer okulären Beteiligung. Aktuell wird eine augenärztliche SHP-Registerstudie etabliert, um die Epidemiologie und Versorgungssituation besser zu erfassen und langfristig zu verbessern.

Dieses Dokument wurde zum persönlichen Gebrauch heruntergeladen. Vervielfältigung nur mit Zustimmung des Verlages.

Introduction

Mucous membrane pemphigoid (MMP) is one of a group of disorders known as the pemphigoid diseases. MMP is the third most common autoimmune blistering skin disease in Europe, after bullous pemphigoid and pemphigus vulgaris. It is defined by the appearance of autoantibodies targeting the epithelial basement membrane, predominantly attacking the mucous membranes. This can affect all of the mucous membranes in the body. In the course of this disease, approx. 70% of patients develop ocular involvement with scarring of the conjunctiva [1–3]. According to a recent international consensus, if the conjunctiva are the sole targets of the attack, the condition is referred to as ocular mucous membrane pemphigoid; if other mucous membranes are also affected at the same time, it is referred to as mucous membrane pemphigoid with ocular involvement [2].

With an annual incidence of approx. 1 to 2 cases per million and a prevalence of 25 per million population recorded in 2014, MMP is a rare disease [4, 5]. In Germany, with a total population of 83 million, approximately 2,100 patients are affected overall, with 80 to 170 new cases diagnosed each year. Nevertheless, this attack on the conjunctiva represents one of the greatest challenges in the field of ocular surface diseases. Because the symptoms are initially nonspecific, for example conjunctival hyperemia, a burning sensation or a foreign body sensation, MMP is often not diagnosed until it has reached an advanced stage. In the case of glaucoma patients receiving long-term topical treatment, pseudopemphigoid should always be considered as a differential diagnosis [6].

Without adequate treatment, MMP can lead to increasing scar tissue adhesion between the bulbar conjunctiva and the eyelid (symblepharon or ankyloblepharon), as well as conjunctival keratinization. (▶ **Fig. 1**). Subsequently, eyelid malposition and trichiasis can lead to serious complications such as limbal stem cell deficiency, neovascularization, and corneal scarring or erosion. It can even lead to corneal perforation (▶ **Fig. 1**) [7]. The progression of MMP therefore poses a potential threat to visual function; this means that ocular involvement can have an especially severe impact on the patient's quality of life [7, 8]. Treatment is often lengthy and complicated [7]. As a rule, systemic immunosuppressants or immunomodulatory drugs are required. In the most severe cases, it is often necessary to resort to surgical interventions such as entropion repair or corneal transplant in order to restore the patient's vision [7]. In Germany to date, there has been no nationwide collection of epidemiological and clinical data for this disease.

In light of this, we conducted a brief survey on the care situation for MMP patients and on the approaches used to diagnose and treat ocular MMP and MMP with ocular involvement.

Methods

We designed a survey to investigate the care situation for patients with ocular MMP and MMP with ocular involvement (▶ **Fig. 2**). In this survey, clinics were asked whether they provided a specialized outpatient service for this disease, how many MMP patients they had in total, how many new MMP patients they acquired each

▶ **Fig. 1** Slit lamp images showing typical clinical findings for ocular MMP. **a** Conjunctival keratinization with symblepharon and ankyloblepharon at the lateral canthus. **b** Distinct symblepharon of the lower eyelid with clear shortening of the fornix. **c** Corneal neovascularization and keratinization with central scarring. **d** Extensive corneal ulcer with pronounced scarring of the underlying stroma.

Umfrage zur Versorgung von Patienten mit okulärem Schleimhautpemphigoid in Deutschland.

Herzlichen Dank für Ihre Mitarbeit!

Name der einsenden Klinik: _____

1. Haben Sie eine **spezialisierte Sprechstunde** für okulares Pemphigoid?
   - o ja
   - o nein
2. Wie viele **Patienten insgesamt** betreuen Sie ungefähr zurzeit?
   _____

   Wie viele **neue Fälle** werden ca. pro Jahr bei Ihnen diagnostiziert?
   _____
3. Welche **klinischen** Kooperationspartner nutzen Sie?
   _____
4. Welche **Diagnostikpartner** nutzen Sie für die **Histologie**?
   _____

   Welche **Diagnostikpartner** nutzen Sie für die **Serologie**?
   _____
5. Haben Sie eine **Standardtherapie**?
   - o ja
   - o nein

   Unabhängig davon, womit behandeln Sie:
   - leichte bis moderate Fälle. _____
   - schwere bis schwerste Fälle _____

▶ **Fig. 2** Questionnaire.

Dieses Dokument wurde zum persönlichen Gebrauch heruntergeladen. Vervielfältigung nur mit Zustimmung des Verlages.

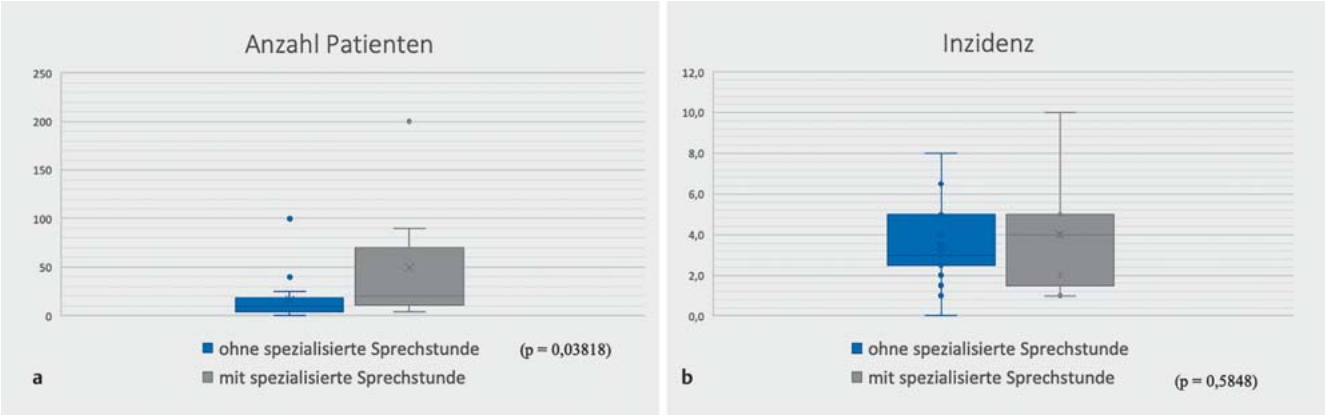

▶ **Fig. 3** **a** Box and whisker plots showing the total number of MMP patients per center, according to whether or not a specialized service was available. **b** Box and whisker plots showing the incidence of MMP patients per ophthalmology center, according to whether or not a specialized service was available. The median value is indicated as a continuous line inside the box. Values greater than 1.5 times the interquartile range were treated as outliers.

year, what interdisciplinary clinical collaborations they had established, and which local and/or systemic therapies they usually used. In April 2020, the survey was sent in paper form to a total of 44 clinics, including all of the university eye departments, and other potential treatment centers with patients recruited from different regions.

We used "R", version 4.0.5 ([7950 Catalina build], R Foundation for Statistical Computing, 2021), to perform a statistical analysis of the results. The descriptive presentation of the numerical data includes the mean and standard deviation values as well as the range; nominal data are presented as percentages, and for ordinal data, the median value and range are reported. In order to investigate the degree of correlation in the case of dichotomous variables, we performed correlation analysis using the phi coefficient, and for variables with non-normal distribution we performed correlation analysis using the Spearman correlation coefficient. Group comparisons for variables with non-normal distribution were performed using the Wilcoxon-Mann-Whitney test. P-values ≤ 0.05 were considered statistically significant.

Results

From April 2020 to April 2021, 28 out of 44 response forms were returned (64%) and analyzed. These 28 clinics reported treating a combined annual average of 27 ± 42 MMP patients (range: 0–200), with an average of 3.6 ± 2.2 new patients (range: 0–10) each year. This results in a total cohort of 741 patients, with 101 new patients diagnosed each year.

Of the clinics that took part in the survey, 32% (n = 9) reported that they provide a specialized outpatient consultation service for MMP. The total number of MMP patients in the care of these clinics (49 ± 67) was significantly higher (p = 0.038) than in clinics that did not provide a specialized outpatient service for MMP (16 ± 23) (▶ **Fig. 3**). In contrast, the annual number of new MMP patients for the clinics with a specialized service (4.0 ± 2.7) was not significantly higher than for clinics without a specialized service (3.4 ± 1.9) (p = 0.58).

Of all the participating centers, 93% (n = 26) reported collaborating with established partners from other departments to provide clinical diagnosis. Two clinics reported that they did not have any established form of clinical collaboration with other departments. All of the respondents who collaborated with other departments reported the department in question to be the dermatology service available at their location. A further five centers also collaborated with the rheumatology clinic (17.9%), and two reported collaborating with the department for internal medicine (7.1%). 79% of the clinics (n = 22) performed serology and histology diagnostics in-house. Five clinics (18%) reported sending these to a specialized external autoimmune laboratory. Two clinics (7%) did not respond to this question.

A little over half of the centers (57%; n = 16) reported using a standardized treatment regimen. Clinics providing a specialized outpatient service were not significantly more likely than other clinics to use standardized therapy (p = 0.2232). Eight clinics reported that they did not use a standardized treatment regimen, and four clinics did not provide information regarding the therapy they used.

Topical treatment consisted uniformly of artificial tears and anti-inflammatory eyedrops and ointments. In the group using a standardized treatment regimen, 81.3% (13 of 16) used topical glucocorticoids, and seven of these clinics also used topical cyclosporine A. One clinic treated patients only with topical cyclosporine A as standard, while another clinic combined cyclosporine A with tacrolimus. In the group with no standardized treatment regimen (n = 8), topical glucocorticoids were uniformly the treatment of choice, with six of these clinics also using topical cyclosporine A.

Seven clinics gave no response to the question about systemic therapy; of these, three clinics reported leaving it entirely to the dermatologists to determine this indication. Among the other clinics (n = 21), systemic glucocorticoids (66.7%) were most often used, followed by mycophenolate mofetil and dapsone (57.1%), rituximab (33.3%), azathioprine and cyclophosphamide (28.6%), and methotrexate (19.0%). Immunoglobulin was used less fre-

Dieses Dokument wurde zum persönlichen Gebrauch heruntergeladen. Vervielfältigung nur mit Zustimmung des Verlages.

▶ **Table 1** Reported treatment data.

Drug	n	%
Topical administration		
Prednisolone + cyclosporine A	13	54.2
Prednisolone as monotherapy	8	33.3
Cyclosporine A as monotherapy	1	4.2
Pimecrolimus	1	4.2
Systemic administration		
Methylprednisolone	14	66.7
Mycophenolate mofetil	12	57.1
Dapsone	12	57.1
Rituximab	7	33.3
Azathioprine	6	28.6
Cyclophosphamide	6	28.6
Methotrexate	4	19.0
Immunoglobulin	3	14.3
Sulfapyridine and sulfamethoxypyrazine	1	4.8
Tetracycline	1	4.8

quently (14.3%), followed by tetracycline, sulfapyridine, and sulfamethoxypyrazine (4.8%) (▶ **Table 1**). There was a strong correlation (phi coefficient 0.46, p = 0.02 347) between the use of mycophenolate mofetil and having a standard treatment regimen in place.

Discussion

In accordance with the international literature, our survey confirms the prevalence and incidence data reported in other countries [9–12] which characterize MMP as a rare disease. The results from our survey indicate a low prevalence and annual incidence for MMP, with considerable differences sometimes occurring between clinics. We attribute this disparity to the fact that some clinics recruit patients with ocular MMP or MMP with ocular involvement from other regions. Even though MMP is a rare disease, as many as nine of the German clinics that responded to the survey provide a specialized consultation service for patients with ocular involvement. Accordingly, these "centers" accommodate a significantly higher number of MMP patients.

A diagnosis of MMP can be difficult to confirm. In the case of ocular MMP, a clinical diagnosis can only be made if the relevant diagnostic tests (biopsy, serology) give negative results, and any possible differential diagnoses have been ruled out. However, it is extremely important both to patients and physicians to be certain about this diagnosis, because it often leads to long-term immunosuppressive therapy. In addition, once the diagnosis has been made, specialists from other disciplines such as dermatology, ENT, or oral surgeons should be consulted for a joint assessment in order to reliably rule out other possible causes of lesions.

Interdisciplinary support for treatment planning can be provided by Rheumatology, and by Dermatology provided that the appropriate expertise is available. Nearly all of the clinics that took part in the survey reported collaborating with Dermatology as their primary interdisciplinary partner, while collaboration with Rheumatology or Internal Medicine was much less common, even though skin lesions represent only 25–30% of all lesions occurring in affected MMP patients [7, 13]. Although lesions occur most frequently (> 85%) in the mucous membranes of the mouth, nose, and larynx [1, 14], no clinics reported working with dental, oral and maxillofacial, or ENT services; this may be attributable to the fact that symptoms involving extraocular lesions are minor and tend to have a benign spontaneous course. Nevertheless, it is advisable to consult these specialists, because their findings can be of definitive importance in confirming the diagnosis.

Based on the recently published European guideline, the following measures are recommended in all cases of ocular MMP or MMP with ocular involvement: biopsy of non-inflamed conjunctiva and/or healthy oral mucous membrane with direct immunofluorescence, conventional histopathology on tissue from conjunctival lesions, and detection of serum autoantibodies. It is not always possible to rule out differential diagnoses, such as lichen planus, with certainty [15]. In addition, in the case of a unilateral lesion, performing a biopsy of the conjunctiva makes it possible to differentiate between MMP and conjunctival intraepithelial neoplasia. The clinics that participated in the survey were all maximum care providers, and as such, they mostly performed diagnostic testing in-house, even though there are autoimmune laboratories specialized in this field which offer specific diagnostic options based on their own scientific focus.

Only half of the clinics surveyed reported using a standardized treatment regimen. This may be due to the absence of a relevant international consensus. An interdisciplinary guideline on this topic has just been published [16]. In principle, it seems useful to take a graduated approach based on whether the patient's inflammatory condition is progressing or regressing [7, 17]. In the case of persistent inflammation, progression to conjunctival fibrosis and corneal complications can be expected. In such cases, it is important to differentiate between immune-mediated inflammation and other concurrent ocular surface diseases, such as chronic blepharitis or meibomian gland dysfunction.

Only 25% of ocular MMP patients do not require systemic immunosuppression. In these cases, progression of the disease can be minimized by treatment with artificial tears, topical steroids, and cyclosporine A (CsA) [7]. However, in such cases it is important to bear in mind the complications that typically arise with long-term use of steroids (glaucoma and cataracts). Although available case reports on the use of cyclosporine A show only variable results [7, 18], half of all clinics surveyed use it as an adjuvant together with topical steroid treatment; one clinic even reported using it as the sole topical anti-inflammatory medication. However, the use of purely topical anti-inflammatory medication (e.g., tacrolimus) is generally limited to individual mild cases [19].

Since azathioprine and cyclophosphamide were first used by Foster in 1980, systemic immunosuppressants have come to be universally considered indispensable for improving the long-term prognosis of progressive forms of MMP or in cases of moderate to

Dieses Dokument wurde zum persönlichen Gebrauch heruntergeladen. Vervielfältigung nur mit Zustimmung des Verlages.

severe inflammation [1, 7, 20]. Other options for systemic therapy include oral dapsone, sulfasalazine, and sulfapyridine [17]. In all cases, over the course of treatment that can often last for many years, it is necessary to regularly monitor the patient's blood count as well as liver and kidney function so as to detect any adverse drug effects at an early stage. The treatment monitoring forms published by the German Society for Rheumatology can be very useful for this purpose [21]. However, there is little evidence from clinical studies on this topic, and the studies that have been published are limited to dapsone and cyclophosphamide.

The same applies in particular for stronger drugs such as mycophenolate mofetil (MMF), which according to our survey was the most commonly used steroid-sparing immunosuppressant; this may be due to the fact that this drug is well tolerated. It was used particularly frequently in clinics that had an established treatment regimen. In all cases, it is essential that the patient is fully informed before starting treatment, not least because of the potentially lethal complications [17]. Oral or intravenous cyclophosphamide, at times in combination with intravenous prednisolone, and biologics such as rituximab, or the significantly more expensive intravenous administration of immunoglobulin [22 – 24], tend to be treatments of last resort [21, 25].

Given the generally quite advanced age of this patient cohort, in addition to corneal complications, cataracts represent another cause of vision loss. Before surgery can be performed to restore the patient's vision, the inflammatory process first needs to be brought under control with medication. Corneal neovascularization and a severe tear film deficiency can significantly compromise the success of a corneal transplant or a Boston keratoprosthesis. In such cases, keratoprostheses with biological haptics represent an alternative [26, 27]. Provided that the inflammation is adequately controlled, it is also possible to successfully restore the patient's vision through cataract surgery; however, reactivation of ocular MMP may lead to renewed loss of vision in the long term [28].

Despite the low prevalence of MMP, with just over 2,000 cases in Germany, this survey captured around a third of all MMP cases in the country. According to the literature, around 70 % of patients with MMP have ocular involvement. The literature also indicates that 20 % of all MMP patients have an exclusively ocular form of the disease [1, 14]. We may assume that there are other patients with ocular involvement in the clinics that did not respond to the survey, or under the care of other specialist departments such as dermatology, who so far remain undiagnosed and therefore undertreated. However, in view of the irreversible and potentially disastrous nature of this disease, ophthalmologists in Germany ought to be familiar with it as a differential diagnosis, and should refer patients to a treatment center that has the necessary expertise. In the future, patients treated at these centers can be registered in a "German Ocular Pemphigoid Register"; this is intended to contribute to the prospective collection of clinical, diagnostic, and therapeutic data relating to this rare disease, so as to identify possible progression parameters and thus improve long-term care for these patients.

Conflict of Interest

Martina Herwig-Carl: Research grant: EPIC-XS (project no. 823839, funded by the Horizon 2020 programme of the EU), German Research Foundation (HE5775/5-1); lectures and consultancy work: GlaxoSmithKline. I declare that the other authors have not declared any economic or personal connections as defined above in the past 3 years.

References

[1] Chan LS, Ahmed AR, Anhalt GJ et al. The first international consensus on mucous membrane pemphigoid: Definition, diagnostic criteria, pathogenic factors, medical treatment and prognostic indicators. Arch Dermatol 2002; 138: 370–379. doi:10.1001/archderm.138.3.370

[2] Rashid H, Lamberts A, Borradori L et al. European guidelines (S3) on diagnosis and management of mucous membrane pemphigoid, initiated by the European Academy of Dermatology and Venereology – Part I. J Eur Acad Dermatol Venereol 2021; 35: 1750–1764. doi:10.1111/JDV.17397

[3] Schmidt E, Rashid H, Marzano AV et al. European Guidelines (S3) on diagnosis and management of mucous membrane pemphigoid, initiated by the European Academy of Dermatology and Venereology – Part II. J Eur Acad Dermatol Venereol 2021; 35: 1926–1948. doi:10.1111/JDV.17395

[4] Hübner F, Recke A, Zillikens D et al. Prevalence and Age Distribution of Pemphigus and Pemphigoid Diseases in Germany. J Invest Dermatol 2016; 136: 2495–2498. doi:10.1016/j.jid.2016.07.013

[5] Bertram F, Bröcker EB, Zillikens D et al. Prospective analysis of the incidence of autoimmune bullous disorders in Lower Franconia, Germany. J Dtsch Dermatol Ges 2009; 7: 434–440. doi:10.1111/j.1610-0387.2008.06976.x

[6] Geerling G, Roth M. [Pseudopemphigoid Induced by Topical Glaucoma Medications]. Klin Monbl Augenheilkd 2019; 236: 762–766. doi:10.1055/a-0842-7566

[7] Dart JK. The 2016 Bowman Lecture Conjunctival curses: scarring conjunctivitis 30 years on. Eye (Lond) 2017; 31: 301–332. doi:10.1038/eye.2016.284

[8] Radford CF, Rauz S, Williams GP et al. Incidence, presenting features, and diagnosis of cicatrising conjunctivitis in the United Kingdom. Eye (Lond) 2012; 26: 1199–1208. doi:10.1038/eye.2012.119

[9] Bobba S, Devlin C, di Girolamo N et al. Incidence, clinical features and diagnosis of cicatrising conjunctivitis in Australia and New Zealand. Eye (Lond) 2018; 32: 1636–1643. doi:10.1038/s41433-018-0155-7

[10] Radford CF, Rauz S, Williams GP et al. Incidence, presenting features, and diagnosis of cicatrising conjunctivitis in the United Kingdom. Eye (Lond) 2012; 26: 1199–1208. doi:10.1038/eye.2012.119

[11] Langan SM, Smeeth L, Hubbard R et al. Bullous pemphigoid and pemphigus vulgaris – Incidence and mortality in the UK: Population based cohort study. BMJ 2008; 337: 160–163. doi:10.1136/bmj.a180

[12] Joo JS, Yun SJ, Lee SC et al. Incidence of bullous pemphigoid and pemphigus in Korea. Ann Dermatol 2021; 33: 193–195. doi:10.5021/ad.2021.33.2.193

[13] Greenberg M, Glick M, Ship JA. Burket's Oral Medicine. Eleventh Edition. Hamilton: BC Decker Inc.; 2008

[14] Thorne JE, Anhalt GJ, Jabs DA. Mucous Membrane Pemphigoid and Pseudopemphigoid. Ophthalmology 2004; 111: 45–52. doi:10.1016/j.ophtha.2003.03.001

[15] Holtsche MM, Zillikens D, Schmidt E. [Mucous membrane pemphigoid]. Hautarzt 2018; 69: 67–83. doi:10.1007/s00105-017-4089-y

[16] Rashid H, Lamberts A, Borradori L et al. European guidelines (S3) on diagnosis and management of mucous membrane pemphigoid, initiated by the European Academy of Dermatology and Venereology (EADV) –

Dieses Dokument wurde zum persönlichen Gebrauch heruntergeladen. Vervielfältigung nur mit Zustimmung des Verlages.

Part I. J Eur Acad Dermatol Venereol 2021; 35: 1750–1764. doi:10.1111/jdv.17397

[17] Saw VPJ, Dart JKG, Sitaru C et al. Cicatrising conjunctivitis with anti-basement membrane autoantibodies in ectodermal dysplasia. Br J Ophthalmol 2008; 92: 1403–1410. doi:10.1136/bjo.2007.130583

[18] Holland EJ, Olsen TW, Ketcham JM et al. Topical cyclosporin A in the treatment of anterior segment inflammatory disease. Cornea 1993; 12: 413–419. doi:10.1097/00003226-199309000-00008

[19] Suresh L, Calixto LEM, Radfar L. Successful treatment of mucous membrane pemphigoid with tacrolimus. Spec Care Dentist 2006; 26: 66–70. doi:10.1111/j.1754-4505.2006.tb01512.x

[20] Foster CS. Immunosuppressive Therapy for External Ocular Inflammatory Disease. Ophthalmology 1980; 87: 140–150. doi:10.1016/S0161-6420(80)35272-X

[21] Deutsche Gesellschaft für Rheumatologie e.V. Informationen zur Therapie. Merkblätter für Ärztinnen und Ärzte sowie Patientinnen und Patienten. Accessed August 6, 2021 at: https://dgrh.de/Start/Versorgung/Therapieinformationen/Therapieinformationsb%C3%B6gen.html

[22] Le Roux-Villet C, Prost-Squarcioni C, Alexandre M et al. Rituximab for patients with refractory mucous membrane pemphigoid. Arch Dermatol 2011; 147: 843–849. doi:10.1001/archdermatol.2011.54

[23] Rübsam A, Stefaniak R, Worm M et al. Rituximab preserves vision in ocular mucous membrane pemphigoid. Expert Opin Biol Ther 2015; 15: 927–933. doi:10.1517/14712598.2015.1046833

[24] Maley A, Warren M, Haberman I et al. Rituximab combined with conventional therapy versus conventional therapy alone for the treatment of mucous membrane pemphigoid (MMP). J Am Acad Dermatol 2016; 74: 835–840. doi:10.1016/j.jaad.2016.01.020

[25] Hügel R, Lang A, Lhotta K et al. Anti-laminin 332 mucous membrane pemphigoid with laryngeal involvement-adjuvant treatment with immunoadsorption and rituximab. J Dtsch Dermatol Ges 2018; 16: 897–900. doi:10.1111/ddg.13569

[26] Geerling G, Hille K. Zum Stand der Keratoprothesen mit biologischer Haptik – Die Düsseldorf-Offenburger-Erfahrungen mit Osteo-Odonto- und Tibia-Keratoprothese. Klin Monbl Augenheilkd 2017; 234: 763–769. doi:10.1055/S-0043-111086

[27] Schmidt E, Benoit S, Kampik D et al. Tibial bone keratoprosthesis: reversing blindness in mucous membrane pemphigoid. J Dtsch Dermatol Ges 2017; 15: 1024–1026. doi:10.1111/ddg.13317

[28] Geerling G, Dart JKG. Management and outcome of cataract surgery in ocular cicatricial pemphigoid. Graefes Arch Clin Exp Ophthalmol 2000; 238: 112–118. doi:10.1007/PL00007877

Dieses Dokument wurde zum persönlichen Gebrauch heruntergeladen. Vervielfältigung nur mit Zustimmung des Verlages.