

Effectiveness of High-intensity Focused Ultrasound (HIFU) Therapy of Solid and Complex Benign Thyroid Nodules – A Long-term Follow up Two-center Study

Authors

Anne Fischer¹, Hüdayi Korkusuz², Christian Vorländer³

Affiliation

- 1 DZTA - Deutsches Zentrum für Thermoablation e.V. Bürgerhospital Frankfurt Nibelungenallee Frankfurt
- 2 Afyonkarahisar Sağlık Bilimleri Üniversitesi, Turkey
- 3 Bürgerhospital Frankfurt, Frankfurt am Main

Key words

thermoablation, nodal morphology, volume reduction, therapeutic effect

received 01.06.2021

revised 18.11.2021

accepted 06.12.2021

published online 10.01.2022

Bibliography

Exp Clin Endocrinol Diabetes 2022; 130: 374–380

DOI 10.1055/a-1719-4441

ISSN 0947-7349

© 2022. Thieme. All rights reserved.

Georg Thieme Verlag KG, Rüdigerstraße 14, 70469 Stuttgart, Germany

Correspondence

Anne Fischer

DZTA – Deutsches Zentrum für Thermoablation e.V.

Nibelungenallee 37–41

60318 Frankfurt am Main

Tel.: + 0049 69 1500 1880

anne@ffm-fischer.de

ABSTRACT

Purpose To investigate the effectiveness of high-intensity focused ultrasound (HIFU) of solid and complex benign thyroid nodules.

Methods Fifty-eight patients with benign thyroid nodules were treated with HIFU at two centers from 2014–2019. The device, EchoPulse (Teraclion, Malakoff, France), heats the nodes to 80–90 °C. Nodal volumes were measured by ultrasound at regular intervals before and up to 12 months after therapy. In a retrospective long-term two-center study, average volume reductions in relation to baseline volume were statistically analyzed by the Wilcoxon signed-rank test. Side effects were documented.

Results In solid nodules, the average percent volume reductions at the 3, 6, 9, and 12-months follow-up were 49.98%, 46.40%, 65.77%, and 63.88%, respectively. The results were significant with $p < 0.05$ in the Wilcoxon signed-rank test at the 3, 6, and 9-months follow-up. In complex nodules, the average percent volume reduction was 35.2% at 3 months, 36.89% at 6 months, and 63.64% at twelve months follow up. The results were significant with $p < 0.05$ in the Wilcoxon signed-rank test at the 3- and 6-months follow-up. The complication rate was 5.2%. All complications occurred in patients with solid nodules.

Conclusion The study showed that HIFU is an effective treatment method for both solid and complex nodules. The complication rate is relatively high at 5.2%. No long-term complications occurred. The solid nodules responded better to HIFU than complex nodules.

Introduction

Thyroid nodules are very common in our population and are therefore of great scientific interest. About 50% of women and 30% of men have thyroid nodules [1]. Benign nodules (80–95% of the thyroid nodules) are classified as cystic, complex, and solid nodules according to their nodule morphology [2–4]. Most benign nodules do not cause any symptoms, although, they are nowadays easily diagnosed by ultrasound.

The nodules only need to be treated if they cause symptoms (feeling of pressure, difficulty swallowing, dyspnea) or cosmetic impairments [5, 6]. The treatments include radioiodine therapy or surgical removal; despite their advantages, these therapy options

have several side effects and are therefore not accepted by patients. For example, bleeding, laryngeal recurrent nerve paralysis, hypothyroidism, or infections may occur. Pregnant women or women who wish to have children in the next few months cannot undergo radioiodine therapy [7–9]. Therefore, minimally invasive thermoablative procedures such as HIFU, radiofrequency ablation (RFA), microwave ablation (MWA), and laser are other alternatives and have been assessed intensively over the past years [5, 10–14]. Among the alternative thermoablative procedures, HIFU is the least invasive and most precise [15]. In HIFU, ultrasound rays are focused by a concave ultrasound probe to heat the tissue to 85 °C. This irreversibly causes coagulation necrosis and nodule atrophy

[5, 11, 13, 14]. HIFU is not skin penetrating and therefore much more comfortable for the patient. There is no risk of infection. HIFU is used not only for the treatment of thyroid nodules, but also for prostate cancer, uterine myomas, and liver or bone metastases [16–18]. To make the structures react even more sensitively to ultrasound, research is underway on so-called sonosensitizers, for instance, for the liver and kidney [19, 20].

HIFU is found to be a safe and effective method to treat benign thyroid nodules [10–14, 21]. It is currently mentioned as an alternative treatment option for solid and complex nodules, but with the caveat that further studies are needed [1]. This study investigated whether the morphology of the nodule influences the therapeutic effect. Nodule volume is the crucial assessment parameter of both treatment success and patient comfort, therefore, the primary criteria of judgment was volume evaluation.

This study aimed to investigate volume reduction of solid nodules and complex nodules in the treatment of benign thyroid nodules with HIFU and to determine the complication rate in a long-term follow-up two-center study.

Material and methods

Study design

The study was a retrospective analysis of data in an open-label, baseline controlled, two-center study. The study complied with the institutional review board, ethic committees, informed consent regulation, the Declaration of Helsinki, and local regulations.

Patients

Fifty-eight patients (50 female, 8 male) from two-centers were enrolled in the study from 2014 to 2019. Twenty-three patients were recruited from Centrum 1 (University Hospital Frankfurt) and 35 patients were from Centrum 2 (Buergerhospital Frankfurt). The median solid nodules volume was 4.7 mL (range 0.2–23.1 mL, $n = 35$) and the median complex nodule volume was 4.3 mL (range 0.13–17 mL, $n = 23$). Twenty-four nodules were located in the left thyroid lobe, 32 nodules in the right thyroid lobe, and two nodules in the isthmus.

All patients were over 18 years of age. Patients were included in the study if they had proven nonmalignant nodules, symptomatic thyroid nodules (thyrotoxicosis, swallowing problems, pain, or hoarseness), cosmetic concerns, and refused surgery or had proven contraindications to it. No patient was known to have had previous therapy or thermoablative procedures. None of the patients received RIT or surgery. The indication for HIFU was thyroid autonomy in 26 patients and pressure symptoms in 32 patients.

Treatment procedure and equipment

The HIFU therapy was performed at both centers using the EchoPulse (Teraclion, Malakoff, France) system. The device uses a concave ultrasound head (3 MHz) to heat a 2×9 mm focus to 80–90 °C. The therapeutic head generates 87.6–320.3 J per sonication at the focus, in which heat is generated by absorbing the acoustic energy and converting it to thermal energy. To heat 1 mL of the nodule, the device needs 10 seconds.

The system automatically selects the following safety margins: 0.5 cm to the skin, 0.3 cm to the trachea, and 0.2 cm to the carotid. Furthermore, endangered structures are protected by a physical process – the “heat sink”. The vessels surrounding the major nerve and vascular tracts (from 4 mm) transpose the heat generated and thus protect the nerves and vessels from heat-induced necrosis [11].

The exact point of the nodule treatment was defined by the doctor on the device using a so-called voxel map. The tissue was divided into voxels by 10–20 sagittal and transverse layers.

A cooling kit was installed before any therapy. The nodule volume was measured by the Echopulse system. This was followed by either local anesthesia with Mecain 1 % or general anesthesia. Then the ultrasound probe was positioned on the hyperextended neck, with the patient in a supine position. The sonication was performed by the device in a screw pattern and the energy level was adjusted after each sonication.

The device uses a laser to detect deviations between the planned focus and the actual position of the probe. If the pattern shifted, the device automatically stopped the current sonication and the adjustment was made. At the same time, the doctor observed the therapy process with the diagnostic ultrasound probe. The presence of deviations or heat bubbles indicated too high a temperature, and the doctor had to intervene manually at any time and correct the process [5, 10–14, 22, 23].

Baseline assessment

In all patients, a pre-ablative assessment was done. Malignancy was excluded by cytological examination based on fine-needle aspiration biopsy (FNAB) [24]. In addition, laboratory blood tests, 99Tc MIBI scan, and calcitonin measurement were performed. Two pathologists were involved in the study. The 2017 Bethesda-System was used as the pathological classification system [25]. There were no biopsies due to insufficient material.

All nodules were also examined for the position, volume, and echogenicity by B-mode ultrasound (Sonix Touch Ultrasound System, Ultrasonix Medical Corporation, Richmond Canada) before and at regular intervals after therapy. Ultrasound measurements were performed by three examiners as three-dimensional measurements [26]. Nodules with a liquid portion $> 50\%$ but $\leq 90\%$ of the nodule volume were defined as a complex nodule [27, 28].

The volume reduction is the crucial parameter for the patient's symptom improvement and thus for the success of the therapy. Studies have shown significant volume reduction of the nodules up to 12 months after therapy [12]. Therefore, volume reduction of the nodules at three, six, nine, and 12 months after therapy was observed. There were few examinations of the complex nodules at nine months follow-up. Therefore, the nine-month follow-up was only performed for the solid nodules and the overall study population.

Statistical analysis

The statistical analysis was done with MedCalc. Normal distribution could not be assumed thus, statistical testing was nonparametric. Differences between the pre-ablation volume and the time points three, six, nine, and 12 months were compared by the Wilcoxon signed-rank test. The results were significant with $p < 0.05$.

Results

As shown in ► **Fig 1**, at three months-follow up the overall study population had an average volume reduction of 38.86 % (range: 4.03 %–91.16 %, $p < 0.0001$ in the Wilcoxon test, $n = 25$), at six months-follow-up of 42.7 % (range: 7.36 %–93.2 %, $p < 0.0001$, $n = 18$), at nine months-follow-up of 62.21 % (range: 12.88 %–93.2 %, $p = 0.0078$, $n = 8$), and at 12 months-follow-up of 61.42 % (range of 39.39 %–93.2 %, $p > 0.05$, $n = 4$) Thus, significant differences between pre-ablative volume reduction and volume reduction with $p < 0.05$ in the Wilcoxon-signed-rank-test were found at the three, six, and nine month follow-up. The percentage volume reduction of the nodules showed large ranges.

As shown in ► **Fig 2** and ► **3**, at the study population with solid nodules had an average volume reduction of 49.98 % at three months (range: 4.03–91.16 %, $p = 0.0001$ in the Wilcoxon test, $n = 15$), 46.40 % at six months (range: 7.36–93.2 %, $p = 0.001$, $n = 11$), 65.77 % at nine months (range of 39.39–93.2 %, $p = 0.0156$, $n = 7$) and 63.88 % at 12 months (range of 39.39–93.2 %, $p > 0.05$, $n = 2$) follow up. Thus, significant differences between pre-ablative volume reduction and volume reduction with $p < 0.05$ in the Wilcoxon-signed-rank-test were found at three-, six-, and nine-month follow-ups.

As shown in ► **Fig 3** and ► **4**, the study population with complex nodules had an average volume reduction of 35.2 % at three months (range: 5.85–68.63 %, $p = 0.002$ in the Wilcoxon test, $n = 10$), 36.89 % at six months (range of 12.23–68.63 %, $p = 0.0156$, $n = 7$) and 63.64 % at 12 months (range of 52.38–73.91 %, $p > 0.05$, $n = 2$) of follow up. Thus, significant differences between pre-ablative volume reduction and volume reduction with $p < 0.05$ in the Wilcoxon-signed-rank-test were found at the three- and six-month follow-up.

In solid nodules, the average applied energy duration was 2340 s i. e. 39 min. In complex nodules it was 3690 s i. e. 61.5 min.

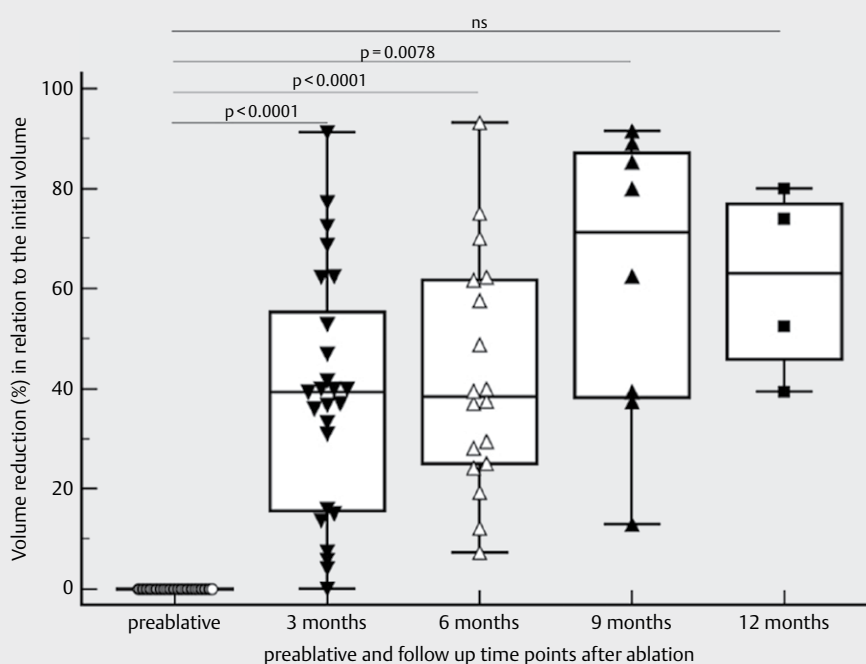
Postinterventional nodal re-growth occurred in three patients. All three patients showed initial volume reduction in the first three months and renewed volume growth after three months. In none of the patients did the nodules increase to the pre-interventional size with the renewed volume increase.

The complication rate was 5.2 %. No complications occurred in patients with complex nodules. In the group of patients with solid nodules, three patients had short-term complications. Two patients had laryngeal recurrent nerve paralysis, which was reversible after speech therapy. One patient complained of a vocal cord weakness three months after therapy. No long-term complications occurred.

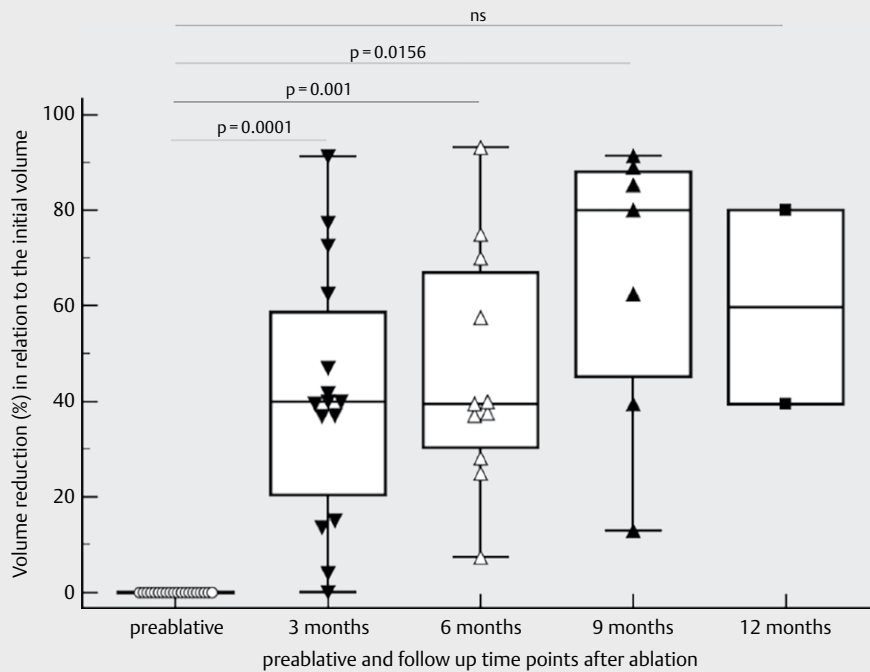
Discussion

In our study, the overall population showed a significant volume reduction and therefore a response to HIFU therapy. Both solid and complex nodules responded with a significant volume reduction to the therapy. The solid nodule group had a higher percent volume reduction in relation to baseline volume at three months and six months. These are further important data to strengthen the evidence for HIFU therapy of benign thyroid nodules in clinical routine.

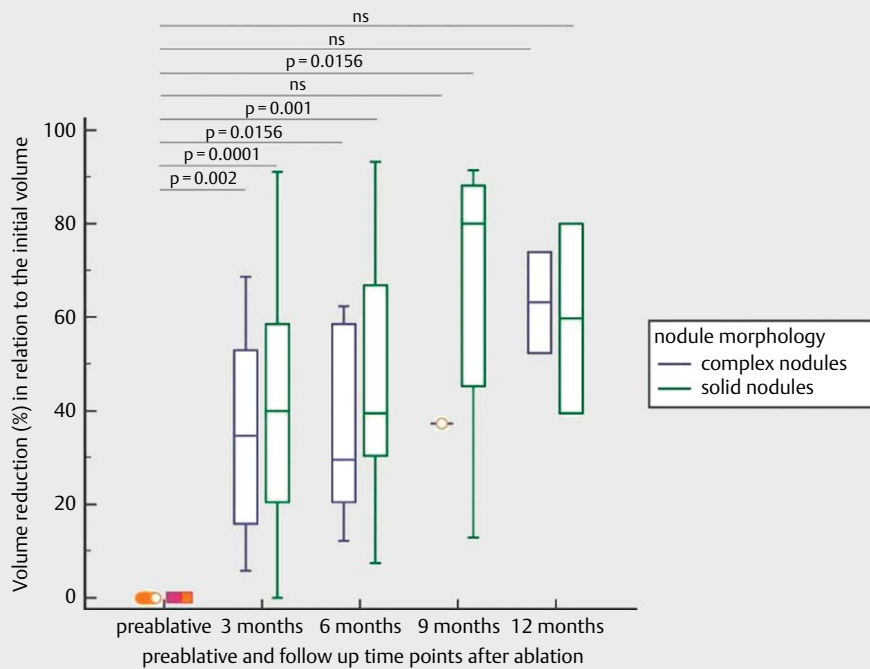
The volume reduction of 62.21 % percent achieved after nine months in the total study population, could effectively improve the patient's symptoms such as the feeling of pressure and problems with swallowing. It confirms the statistically significant results of other studies on HIFU therapy of benign thyroid nodules, which often defined a volume reduction of 50 % as a therapeutic success



► **Fig. 1** Percentage volume reduction in benign thyroid nodules after HIFU therapy in relation to the baseline volume at the follow-up of three, six, nine, and twelve months.



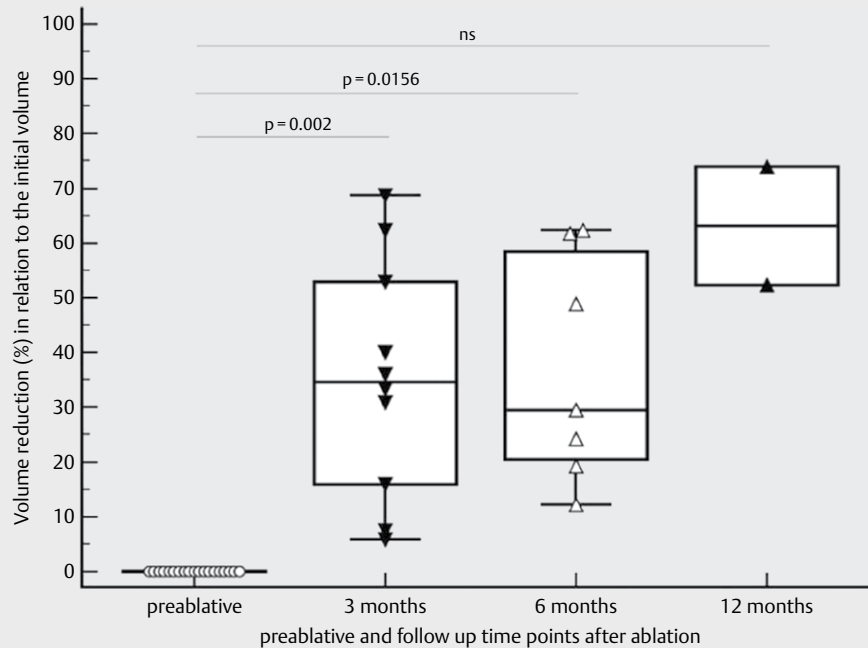
► **Fig. 2** Percentage volume reduction in solid thyroid nodules after HIFU therapy in relation to the baseline volume at the follow-up of three, six, nine, and twelve months.



► **Fig 3** The boxplots show the average percent volume reduction of benign thyroid nodules after HIFU therapy at the time points of three, six, nine, and twelve months follow-up divided into groups of complex and solid nodules.

[15]. Since residual tissue remains after HIFU, it was necessary to exclude malignancy in all nodules with FNAB before treatment [24].

In solid nodules, 49.98 % volume reduction was observed after three months and a 65.77 % volume reduction after nine months. Thus, solid nodules achieved a volume reduction of 50%, which was



► **Fig. 4** Percentage volume reduction of complex thyroid nodules after HIFU therapy in relation to the baseline volume at the follow-up of three, six, nine, and twelve months.

usually defined as therapeutic success [15]. Complex nodules in our study achieved a volume reduction of only 35.2% after three months and 36.89% after six months. They exhibited less than 50% volume reduction. In the present study, the therapy was overall more effective in solid nodules. In the group comparison, no statistically significant difference could be detected due to insufficient sample size. More studies are needed to perform a group comparison.

Since complex nodules are more inhomogeneous and have more interfaces, they would respond better to therapy if absorption is the decisive factor for the response to therapy [29–31]. Therefore, it seems that not absorption, but possibly another factor, such as the removal of heat is crucial for the success of therapy. The therapeutic effect, i. e. the heating of the tissue, depends not only on the initial process of heating but also on the removal of heat. If the heat is removed quickly, the therapeutic effect is less. The distribution or conduction of temperature in tissues is described by Pennes heat transfer. According to this, the greater the temperature distribution, the less dense tissue is, the less specific heat capacity a tissue has, the greater are thermal conductivity and the more the blood perfusion [29, 32, 33]. Transferring these aspects to cystic, complex, and solid nodules, it becomes clear that solid nodules have the least heat distribution. The heat exerted on them has a very local effect. This means that more targeted therapy can be performed and endangered structures can be avoided. Cystic nodules are the other extreme. These have a very high-temperature distribution so that the energy applied is quickly distributed or evaporates and is not so easy to control. With HIFU, only areas the size of a grain of rice are heated. If only such a small area is heated in several mL of the cyst, the temperature is quickly distributed and the overall temperature of the cyst rises only slightly. A

complex nodule has cystic and solid areas so that in some areas the effect of temperature is significant and local and in other areas, the temperature is distributed quickly and the target area is heated less. Therefore solid nodules should respond better to HIFU than complex ones.

A limitation of this study was that the data at the 12-months follow-up were not significant. This was due to insufficient sample size at 12 months. Further data would be needed to significantly assess different trends in volume reduction of solid and complex nodules beyond six months. Another weakness of the study was the retrospective data analysis and the small number of patients in the nine- and twelve-month groups.

In some patients, we observed a renewed volume increase after the initial volume reduction after therapy. What causes recurrences after therapy? It is known that 15% of benign thyroid nodules have a size progression without therapy [6]. After therapy, however, these usually do not grow any more despite the remaining tissue. The larger the nodule is, the more nodules a patient has; the younger a patient is and the higher the BMI of a patient is, the higher is the probability that the nodule will grow without therapy [6]. In the patients in our study with the grown nodule, none of the above-listed criteria applied. It would be necessary to clarify which factors correlate with a renewed increase in nodule volume after therapy.

In this study, the duration of therapy of complex nodules was significantly longer, although the patients initially had a similar median volume as the solid nodules. Despite the longer therapy duration, they had a relatively small volume reduction. This may be because the heat is removed too quickly in complex nodules as described above. This could only be compensated by even higher

temperatures. However, this is not possible, because otherwise heat bubbles are created by cavitation, which would cause complications [22, 31]. Therefore, the same energy is used for a longer time, but this cannot compensate for the larger heat distribution, besides, the therapeutic effect is smaller. One solution would be to heat not only a small area but several areas simultaneously next to each other so that relatively less heat is dissipated.

The fact that in our study side effects only occurred in solid nodules and none in complex nodules underlines the hypothesis that complex nodules did not develop such high temperatures as solid ones. Less tissue was damaged.

In other thermo-ablative procedures such as MWA and RFA, a dependence of the therapeutic outcome on the nodule morphology has already been observed.

In MWA and RFA, cystic or complex nodules respond better to therapy than solid nodules. In one report, MWA, volume reduction of complex nodules was 72 % and of solid nodules was 27 % [34]. In RFA, cystic nodules showed 87–93 % volume reduction while that in solid nodules was 49 % [34–37]. Therefore, in complex nodules, RFA or MWA should be considered more likely, since HIFU, with 36.89 % volume reduction, was significantly worse than MWA and RFA. Nonetheless, for small solid nodules, the HIFU would be preferable to MWA and RFA, because it is more effective with a 46.40 % volume reduction after six months in solid nodules.

Conclusion

To conclude, HIFU is an effective method to treat benign solid and complex thyroid nodules. Overall, solid nodules had more volume reduction than complex nodules through this method. The complication rate was relatively high at 5.2 % and no long-term complications occurred. All complications occurred in patients with solid nodules.

Based on these results, the treatment alternatives of solid and complex nodules can be evaluated better and strategies for the optimization of HIFU therapy of complex nodules can be discussed.

Conflicts of Interest

The authors declare that they had no conflict of interest.

References

- [1] Papini E, Monpeyssen H, Frasoldati A et al. 2020 European Thyroid Association Clinical Practice Guideline for the use of image-guided ablation in benign thyroid nodules. *Eur Thyroid J* 2020; 9: 172–185
- [2] Haugen BR, Alexander EK, Bible KC et al. 2015 American Thyroid Association Management Guidelines for adult patients with thyroid nodules and differentiated thyroid cancer: The American Thyroid Association Guidelines Task Force on thyroid nodules and differentiated thyroid cancer. *Thyroid* 2016; 26: 1–133
- [3] Ha EJ, Lim HK, Yoon JH et al. Primary imaging test and appropriate biopsy methods for thyroid nodules: Guidelines by Korean Society of Radiology and National Evidence-Based Healthcare Collaborating Agency. *Korean J Radiol* 2018; 19: 623–631
- [4] Dobnig H. (2015): Schilddrüsenknoten und Schilddrüse. *Österreichische Ärztezeitung* 2015; 19: 26–34
- [5] Lang BHH, Wu ALH. High intensity focused ultrasound (HIFU) ablation of benign thyroid nodules – A systematic review. *J Ther Ultrasound* 2017; 5: 11
- [6] Durante C, Costante G, Lucisano G et al. The natural history of benign thyroid nodules. *JAMA* 2015; 313: 926
- [7] Federführende Fachgesellschaft: Deutsche Gesellschaft für Allgemein- und Viszeralchirurgie (DGAV), Operative Therapie benigner Schilddrüsenerkrankungen. AWMF online 2015;
- [8] Dietlein M, Grünwald F, Schmidt M et al. Radioiodtherapie bei benignen Schilddrüsenerkrankungen (Version 5). *Nuklearmedizin* 2016; 55: 213–220
- [9] Korkusuz H, Gröner D, Racynski N et al. Thermal ablation of thyroid nodules: Are radiofrequency ablation, microwave ablation and high intensity focused ultrasound equally safe and effective methods? *Eur Radiol* 2018; 28: 929–935
- [10] Chung SR, Baek JH, Suh CH et al. Efficacy and safety of high-intensity focused ultrasound (HIFU) for treating benign thyroid nodules: A systematic review and meta-analysis. *SAGE Journals* 2020; 61: 1636–1643
- [11] Korkusuz H. Thermoablation von schilddrüsenknoten. *Nuklearmediziner* 2016; 39: 227–231
- [12] Trimboli P, Pelloni F, Bini F et al. High-intensity focused ultrasound (HIFU) for benign thyroid nodules: 2-year follow-up results. *Endocrine* 2019; 65: 312–317
- [13] Korkusuz H, Fehre N, Sennert M et al. Volume reduction of benign thyroid nodules 3 months after a single treatment with high-intensity focused ultrasound (HIFU). *J Ther Ultrasound* 2015; 3: 4
- [14] Korkusuz H, Sennert M, Fehre N et al. Localized thyroid tissue ablation by high intensity focused ultrasound: Volume reduction, effects on thyroid function and immune response. *Fortschr Röntgenstr* 2015; 187: 1011–1015
- [15] Sennert M, Happel C, Korkusuz Y et al. Further investigation on high-intensity focused ultrasound (HIFU) treatment for thyroid nodules. *Acad Radiol* 2018; 25: 88–94
- [16] Hill CR, Haar GR. Review article: High intensity focused ultrasound–potential for cancer treatment. *Br J Radiol* 1995; 68: 1296–1303
- [17] Yang R, Sanghvi NT, Rescorla FJ et al. Liver cancer ablation with extracorporeal high-intensity focused ultrasound. *Eur Urol* 1993; 23: 17–22
- [18] Wu F, Wang ZB, Cao YD et al. A randomised clinical trial of high-intensity focused ultrasound ablation for the treatment of patients with localised breast cancer. *Br J Cancer* 2003; 89: 2227–2233
- [19] Lorton O, Guillemin P, Holman R et al. Enhancement of HIFU thermal therapy in perfused tissue models using micron-sized FTAC-stabilized PFOB-core endovascular sonosensitizers. *Int J Hyprth* 2020; 37: 1116–1130
- [20] Zhong X, Mei Z, Tian Z et al. The study of enhanced high-intensity focused ultrasound therapy by sonodynamic N2O microbubbles. *Nanoscale Res Lett* 2019; 14: 381
- [21] Spartalis E, Karagiannis SP, Plakopitis N et al. Single-session high-intensity focused ultrasound (HIFU) ablation for benign thyroid nodules: A systematic review. *Expert Rev Med Devices* 2020; 17: 1–13
- [22] Izadifar Z, Izadifar Z, Chapman D et al. An introduction to high intensity focused ultrasound: Systematic review on principles, devices, and clinical applications. *J Clin Med* 2020; 9: 460
- [23] Trimboli P, Bini F, Marinozzi F et al. High-intensity focused ultrasound (HIFU) therapy for benign thyroid nodules without anesthesia or sedation. *Endocrine* 2018; 61: 210–215

- [24] Bryan R et al. American Thyroid Association Management Guidelines for Adult Patients with Thyroid Nodules and Differentiated Thyroid Cancer: The American Thyroid Association Guidelines Task Force on thyroid nodules and differentiated thyroid cancer, *Thyroid* 2016; 26: 1–133
- [25] Cibas ES, Ali SZ. The 2017 Bethesda System for reporting thyroid cytopathology. *Thyroid* 2017; 27: 1341–1346
- [26] Wen-Bo L et al. Comparison between thin-slice 3-D volumetric ultrasound and conventional ultrasound in the differentiation of benign and malignant thyroid esions. *Ultrasound Med Biol* 2015; 41: 3096–3101
- [27] Andrioli M, Carzaniga C, Persani L et al. Standardized ultrasound report for thyroid nodules: The endocrinologist's viewpoint. *Eur Thyroid J* 2013; 2: 37–48
- [28] Mi-Jung Lee.et. al. Partially cystic thyroid nodules on ultrasound: Probability of malignancy and sonographic differentiation. *Thyroid* 2009; 19: 341–346
- [29] Liu X, Li J, Gong X, Zhang D. Nonlinear absorption in biological tissue for high intensity focused ultrasound. *Ultrasonics* 2006; 44: 27–30
- [30] Bailey MR, Khokhlova VA, Sapozhnikov OA et al. Physical mechanisms of the therapeutic effect of ultrasound (a review). *Acoust Phys* 2003; 49: 369–388
- [31] Haar G, Coussios C. High intensity focused ultrasound: Physical principles and devices. *Int J Hypertherm* 2007; 23: 89–104
- [32] Namakshenas P, Mojra A. Microstructure-based non-Fourier heat transfer modeling of HIFU treatment for thyroid cancer. *Comput Methods Programs Biomed* 2020; 197: 105698
- [33] Jin C, He ZZ, Yang Y, Liu J. MRI-based three-dimensional thermal physiological characterization of thyroid gland of human body. *Med Eng Phys* 2014; 36: 16–25
- [34] Yue W, Wang S, Wang B et al. Ultrasound guided percutaneous microwave ablation of benign thyroid nodules: Safety and imaging follow-up in 222 patients. *Eur J Radiol* 2013; 82: e11–e16
- [35] Lim HK, Lee JH, Ha EJ et al. Radiofrequency ablation of benign non-functioning thyroid nodules: 4-year follow-up results for 111 patients. *European Radiol* 2013; 23: 1044–1049
- [36] Baek JH, Ha EJ, Choi YJ et al. Radiofrequency versus ethanol ablation for treating predominantly cystic thyroid nodules: A randomized clinical trial. *Korean J Radiol* 2015; 16: 1332–1340
- [37] Jung HB, Yoon SK, Ducky L et al. Benign predominantly solid thyroid nodules: Prospective study of efficacy of sonographically guided radiofrequency ablation versus control condition. *AJR AM J Roentgenol* 2010; 194: 1137–1142

Notice

This article was changed according to the following Erratum on January 28th 2022.

Erratum

In the above-mentioned article, the order of the authors' names was corrected and Affiliations 2 and 3 were added.