Article published online: 2022-02-15

Stepwise endoscopic submucosal dissection for circumferential Barrett's esophageal dysplasia and carcinoma: a case series

Authors
Ippei Tanaka[1], Dai Hirasawa[1], Hiroaki Saito[1], Junichi Akahira[2], Fumiyoshi Fujishima[3], Tomoki Matsuda[1]

Institutions
1 Department of Gastroenterology, Sendai Kousei Hospital, Sendai-city, Miyagi, Japan
2 Department of Pathology, Sendai Kousei Hospital, Sendai-city, Miyagi, Japan
3 Department of Anatomic Pathology, Tohoku University School of Medicine, Sendai-city, Japan

submitted 19.6.2021
accepted after revision 17.9.2021

Bibliography
Endosc Int Open 2022; 10: E215–E221
DOI 10.1055/a-1672-4122
ISSN 2364-3722

© 2022. The Author(s).
This is an open access article published by Thieme under the terms of the Creative Commons Attribution-NonDerivative-NonCommercial License, permitting copying and reproduction so long as the original work is given appropriate credit. Contents may not be used for commercial purposes, or adapted, remixed, transformed or built upon. (https://creativecommons.org/licenses/by-nc-nd/4.0/)
Georg Thieme Verlag KG, Rüdigerstraße 14, 70469 Stuttgart, Germany

Corresponding author
Ippei Tanaka, Department of Gastroenterology, Sendai Kousei Hospital, 4-15, Hirose-machi, Aoba-ku, Sendai-city, Miyagi 980-0873, Japan
Fax: +81222226189
ippeitanaka777@gmail.com

The incidence of neoplasia developing in long-segment Barrett's esophagus (LSBE) has recently been gradually increasing in Japan. These neoplastic lesions are sometimes detected as circumferential lesions. However, if such lesions are removed with circumferential en bloc resection by endoscopic submucosal dissection (ESD), severe postoperative stenosis is inevitable. Therefore, we performed stepwise ESD in three patients with circumferential LSBE dysplasia or intramucosal carcinoma. The entire Barrett's neoplasia was successfully resected in all three patients. No adverse events such as posterior bleeding or perforation were observed. Only one patient experienced mild postoperative stenosis, which was resolved with a single balloon dilation. The pathological diagnosis of the lesions was high-grade dysplasia or intramucosal carcinoma. No recurrence was observed in any patient during an average follow-up of 20 months. In conclusion, stepwise ESD may be an effective and safe treatment for circumferential Barrett's neoplasia.

Introduction

The incidence of Barrett's esophageal carcinoma has rapidly increased in Western countries. It is now gradually increasing in Japan due to the decreasing rate of *Helicobacter pylori* infections and the increased prevalence of gastroesophageal reflux disease [1]. Although most lesions develop in short-segment Barrett's esophagus [2], long-segment Barrett's esophagus (LSBE) cancers have also been detected in clinical practice. LSBE cancers or dysplasia sometimes present as circumferential lesions, and treatment strategies for them remain controversial.

Endoscopic submucosal dissection (ESD) is a preferred therapeutic approach for Barrett's neoplasia, especially in Japan, due to its unique advantages of allowing an en bloc resection and a detailed pathological evaluation of the lesions [3, 4]. However, if patients with such circumferential lesions are treated with circumferential en bloc resection by ESD, most of them will experience severe postoperative stenosis despite the use of local steroid therapy [5]. Since sub-total or two-thirds circumferential resection has a significantly lower stricture rate than circumferential en bloc resection, we hypothesized that stepwise total resection would prevent stricture. Therefore, we performed a stepwise ESD in patients with circumferential Barrett's dysplasia or carcinoma.

Patients and methods

Patients and diagnosis

We performed stepwise ESD for circumferential Barrett's neoplasia between March 2018 and April 2020. Before endoscopic treatment, the lesions were precisely assessed with white light endoscopy using a high-definition magnification endoscope

▶ **Table 1** Characteristics of patients with circumferential Barrett's neoplasia treated with stepwise endoscopic submucosal dissection

Patient	Age years	Sex	Prague criteria	Major axis diameter, mm		Histology	Lymphovascular invasion	Depth of invasion
				Resected Specimen of 1st ESD (2nd, 3rd and 4th)	Lesion Size of 1st ESD (2nd, 3rd and 4th)			
1	78	Female	C10M14	125×70 (110×35)	105×70 (100×35)	High-grade dysplasia	–	–
2	67	Male	C7M7	110×77 (88×40, 60×20, 20×18)	100×77 (80×40, 55×18, 20×18)	High-grade dysplasia and intramural carcinoma	v0, ly0	Tis
3	68	Male	C7M9	140×80 (30×28)	130×80 (28×28)	High-grade dysplasia and intramural carcinoma	–	Tis

ESD – endoscopic submucosal dissection.

(GIF-H260Z, Olympus Corp., Tokyo, Japan) and a light source system (EVIS LUCERA CLV-260SL, Olympus Corp.). After the observation of white light imaging, narrow-band imaging-magnifying endoscopy (NBI-ME) was performed to determine the lateral tumor margin, observing mucosal structure and vascular pattern irregularity. If the demarcation of the lesion was difficult to determine, negative biopsies were taken from outside the estimated demarcation line. The negative biopsy specimen was confirmed to be adenocarcinoma or high-grade dysplasia, and an irregular mucosal pattern on NBI-ME was seen in the entire Barrett's mucosa. Thus, the lesion was diagnosed as circumferential Barrett's neoplasia.

ESD procedure and technique

All of the ESD procedures were performed under intravenous anesthesia using propofol. A single-channel upper gastrointestinal endoscope (GIF-Q260J; Olympus Medical Systems, Tokyo, Japan) was used with a transparent hood (D-201–11804; Olympus Medical Systems, Tokyo, Japan) attached to the tip of the scope. We used a VIO300 D (Erbe Elektromedizin GmbH, Tubingen, Germany) as electrosurgical generators. Sodium hyaluronate (MucoUp; Boston Scientific, Marlborough, Massachusetts, United States) was injected into the submucosa to lift the mucosa, followed by mucosal incision and dissection using a hook knife (KD-625LR; Olympus Medical Systems, Tokyo, Japan).

The stepwise ESD technique has been described as follows: In the first resection, approximately two-thirds of the Barrett's segment was removed, including the abnormal area where the deepest tumor invasion was suspected. However, if the area of suspicion was deep muscularis muscle or deeper invasion was seen at more than two-thirds of the circumferential lumen, the stepwise ESD strategy was not indicated. Either circumferential en bloc resection by ESD or esophagectomy should be considered. The squamous epithelium on the oral side and the gastric mucosa on the anal side were contained within the cutting area. After entire mucosal incision, a clip with a thread was attached to the oral edge of the lesion [6]. The shallow submucosa should be dissected during the first ESD procedure; if the deep submucosa had been resected, the scar of the resected area would adhere to the muscularis propria and make the second resection significantly challenging. To keep the dissection to the shallow submucosal layer, it was important to carefully make the incision just behind the mucosa under sufficient submucosal injection, and to confirm that the submucosa remained in the area after the incision without exposing the muscle layer. After the resection, 100 mg of triamcinolone acetonide (Kenacort-A, Bristol-Myers Squibb, Anagni, Italy) was injected at the base of the artificial ulcer to prevent an esophageal stricture.

The second ESD was performed once the ulcer after the first ESD had scarred and no postoperative stenosis was observed. Before the second ESD, we considered the possibility that the Barrett's neoplasia was covered with a regenerating squamous epithelium. Therefore, 1.5 % acetic acid was sprayed on the regenerating epithelium to check for openings of the cancerous gland [7]. If a certain area showed a slight white change (indicating a region of squamous epithelium with underlying glandular epithelium), preoperative marking was performed to include this area.

The second resection technique was almost similar to the usual ESD technique, except for the necessity of careful incision of the regenerated squamous epithelium due to scar-induced changes. Triamcinolone acetonide 100 mg was injected after the second ESD. Local steroid injection was performed only twice throughout the entire procedure, and no oral steroids were used. One month after the final endoscopic treatment, a follow-up endoscopy was performed to check the complete eradication of Barrett's neoplasia and preoperative stenosis.

Two pathologists with expertise in Barrett's neoplasia pathologically diagnosed the resected specimen based on the Vienna classification [8]. Dysplasia was defined as the presence of a noninvasive neoplastic epithelial proliferation with the potential to become invasive. In contrast, invasion was mandatory for a diagnosis of carcinoma. The distinction between high-grade dysplasia and intramucosal carcinoma was based on features such as whether the neoplastic epithelium invaded into the lamina propria. The characteristics of the patients and the lesions are provided in ▶ **Table 1**. Treatment outcomes and adverse events (AEs) are shown in ▶ **Table 2**.

▶ **Table 2** Treatment outcomes and adverse events.

Patient number	Number of ESD sessions	Time between 1st and 2nd ESD, months (2nd and 3rd, and 3rd and 4th)	Procedure time of first ESD, minutes	Procedure time of second ESD, minutes (3rd and 4th ESD)	Follow-up period (months)	Recurrence
1	2	2	175	120	36	None
2	4	9 (3, 4)	225	160 (40, 30)	12	None
3	2	5	300	52	12	None

ESD – endoscopic submucosal dissection.

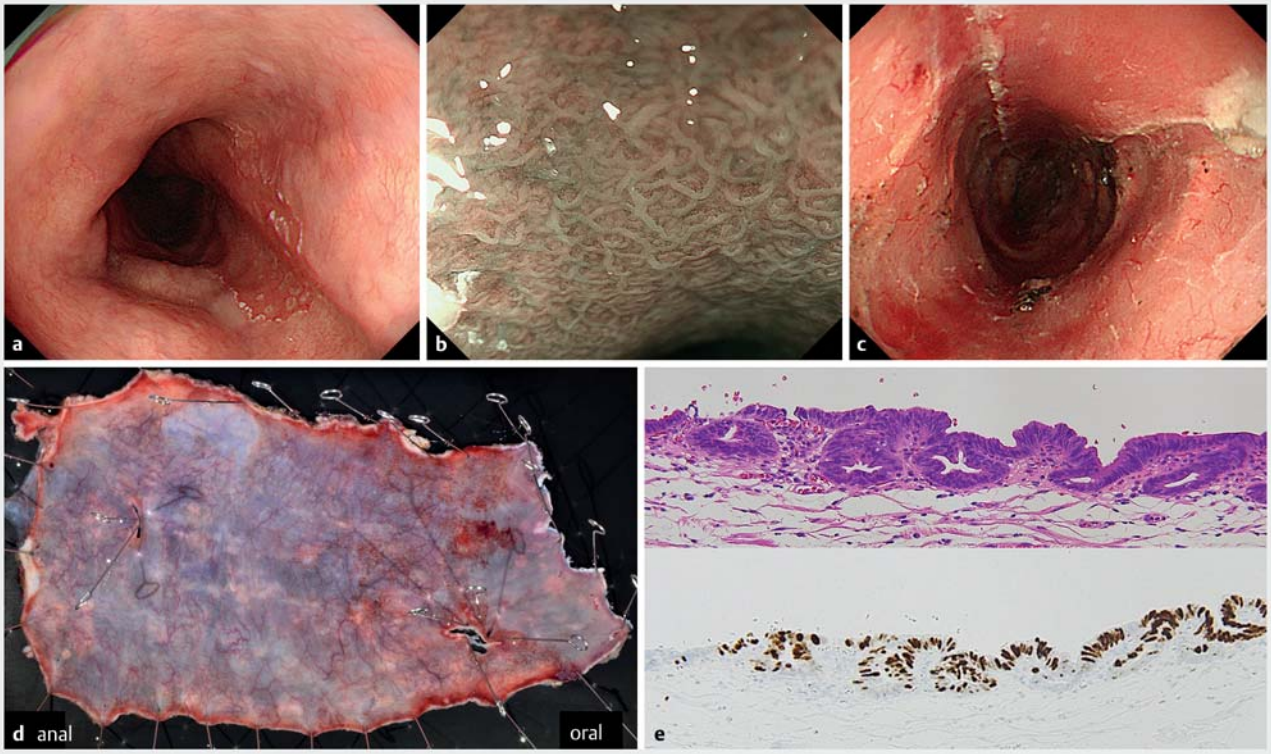

▶ **Fig. 1** **a** Esophagogastroduodenoscopy reveals a long-segment Barrett's esophagus (Prague classification: C10M14). **b** Magnifying endoscopy with narrow-band imaging reveals an irregular pattern throughout the Barrett's mucosa with unclear demarcation. **c** In the first endoscopic submucosal dissection, two-thirds of the Barrett's esophageal circumference is excised to avoid postoperative stenosis. **d** The resected specimen from the first endoscopic submucosal dissection session. **e** Findings of hematoxylin-eosin and Ki-67 staining. Adenocarcinoma is seen in the superficial mucosal layer. Immunohistochemically, the tumor cells were positive for Ki-67.

Case 1

A 78-year-old woman was referred to our hospital for endoscopic treatment of Barrett's dysplasia. Esophagogastroduodenoscopy revealed an LSBE (Prague classification: C10M14) without any nodular or depressed lesion. ME-NBI revealed an irregular mucosal pattern throughout the Barrett's mucosa with unclear demarcation (▶ **Fig. 1a**, ▶ **Fig. 1b**). Preoperative biopsy revealed high-grade dysplasia, and she was diagnosed with Barrett's dysplasia presenting in the entire LSBE area. We dissected two-thirds of the esophageal circumference during the first ESD to avoid stenosis (▶ **Fig. 1c**), and injected 100 mg of triamcinolone acetonide at the resected site. Histopathological examination revealed high-grade dysplasia throughout the entire resected Barrett's mucosa (tumor size: 105 × 70 mm) (▶ **Fig. 1d**, ▶ **Fig. 1e**). Immunohistochemically, the tumor cells were positive for Ki-67 (▶ **Fig. 1e**). No esophageal stricture was observed, and the ulcer was found to be covered with a squamous epithelium.

The second ESD was performed 69 days after the first ESD to treat the residual lesion (▶ **Fig. 2a**, ▶ **Fig. 2b**). There were no AEs such as perforation or bleeding. Furthermore, no esophageal stricture was observed. The entire Barrett's mucosa was completely resected and found to be covered with squamous epithelium (▶ **Fig. 2c**). The histopathological findings were the same as those noted for the first resected specimen (tumor size: 100 × 35 mm). Therefore, this lesion was diagnosed as cir-

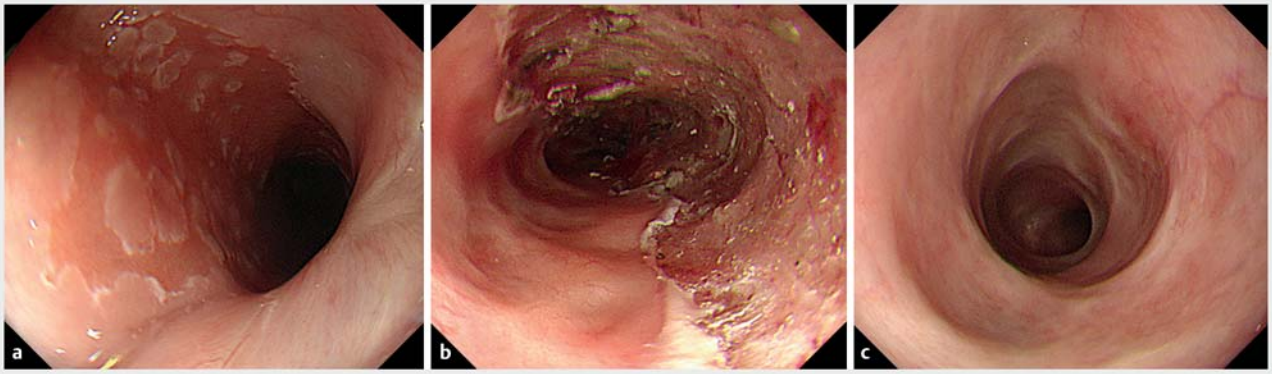

▶ **Fig. 2** **a** Sixty-nine days after the first endoscopic submucosal dissection, the ulcer healed and is noted to be covered with squamous epithelium. **b** The second endoscopic submucosal dissection is performed successfully without any perforation and massive bleeding. **c** The entire Barrett's esophagus is removed and noted to be covered with squamous epithelium.

cumferential Barrett's high-grade dysplasia. No recurrence was observed at 3-year follow-up.

Case 2

A 67-year-old man with LSBE (Prague classification: C7M7) was found to have a 1.0-cm nodule that was identified as adenocarcinoma on biopsy (▶ **Fig. 3a**, ▶ **Fig. 3b**). ME-NBI revealed a highly irregular mucosal pattern on the nodule and mildly irregular mucosal patterns throughout the rest of the flat Barrett's mucosa. Preoperative biopsy of the flat mucosa specimen revealed high-grade dysplasia. Therefore, the entire Barrett's mucosa was considered to be high-grade dysplasia and intramucosal carcinoma, and the nodule was suspected to be the area of deepest tumor invasion. ESD procedure with local steroid injection was performed four times over a 1.5-year period (▶ **Fig. 3c**, ▶ **Fig. 3d**); there were no AEs in each treatment. Histopathological examination of the nodular part revealed a moderately differentiated adenocarcinoma with mucosal invasion, whereas that of the remaining Barrett's mucosa in each procedure showed high-grade dysplasia (tumor size of each ESD: 100 × 77 mm, 80 × 40 mm, 55 × 18 mm, 20 × 18 mm). Therefore, this lesion was diagnosed as circumferential Barrett's neoplasia. Mild stenosis was observed, and a single balloon dilation was performed after the third ESD. No recurrence has been observed 1 year after the fourth ESD.

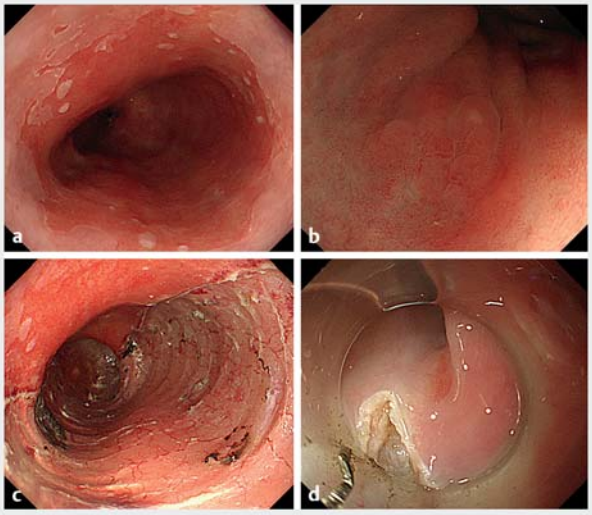

▶ **Fig. 3** **a** Esophagogastroduodenoscopy reveals a long-segment Barrett's esophagus (Prague classification: C7M7). **b** A 10-mm reddish, elevated lesion is seen within the Barrett's mucosa, and is confirmed to be adenocarcinoma on biopsy. **c** Two-thirds of Barrett's esophageal circumference is excised without any complications. **d** An incision is carefully made during the second endoscopic submucosal dissection.

Case 3

A 68-year-old man was referred to our hospital for treatment of an esophageal ulcer. Esophagogastroduodenoscopy revealed an LSBE (Prague classification: C7M9) with an ulcer, confirmed to be adenocarcinoma on biopsy. A month later, another esophagogastroduodenoscopy examination revealed healed ulcer and a mildly irregular mucosal pattern throughout the Barrett's mucosa; additional biopsy confirmed adenocarcinoma. Thus, we diagnosed the lesion as circumferential Barrett's carcinoma. The patient underwent ESD twice in 6 months (▶ **Fig. 4a**). Before the second ESD, acetic acid was sprayed around the regenerating epithelium to check for the opening of cancerous glands. A particular area showing a slight white change indicating a region with glandular epithelium under the squamous epithelium (▶ **Fig. 4b**), and preoperative marking was performed to include this area.

The second ESD was performed and histopathological examination of the resected specimen revealed carcinoma under the squamous epithelium in the white-change region (▶ **Fig. 4c**, ▶ **Fig. 4d**); the other area showed intramucosal carcinoma (tumor size of each ESD: 130 × 80 mm, 28 × 28 mm). Therefore, based on the findings from these two resected specimens, this lesion was diagnosed as circumferential Barrett's carcinoma.

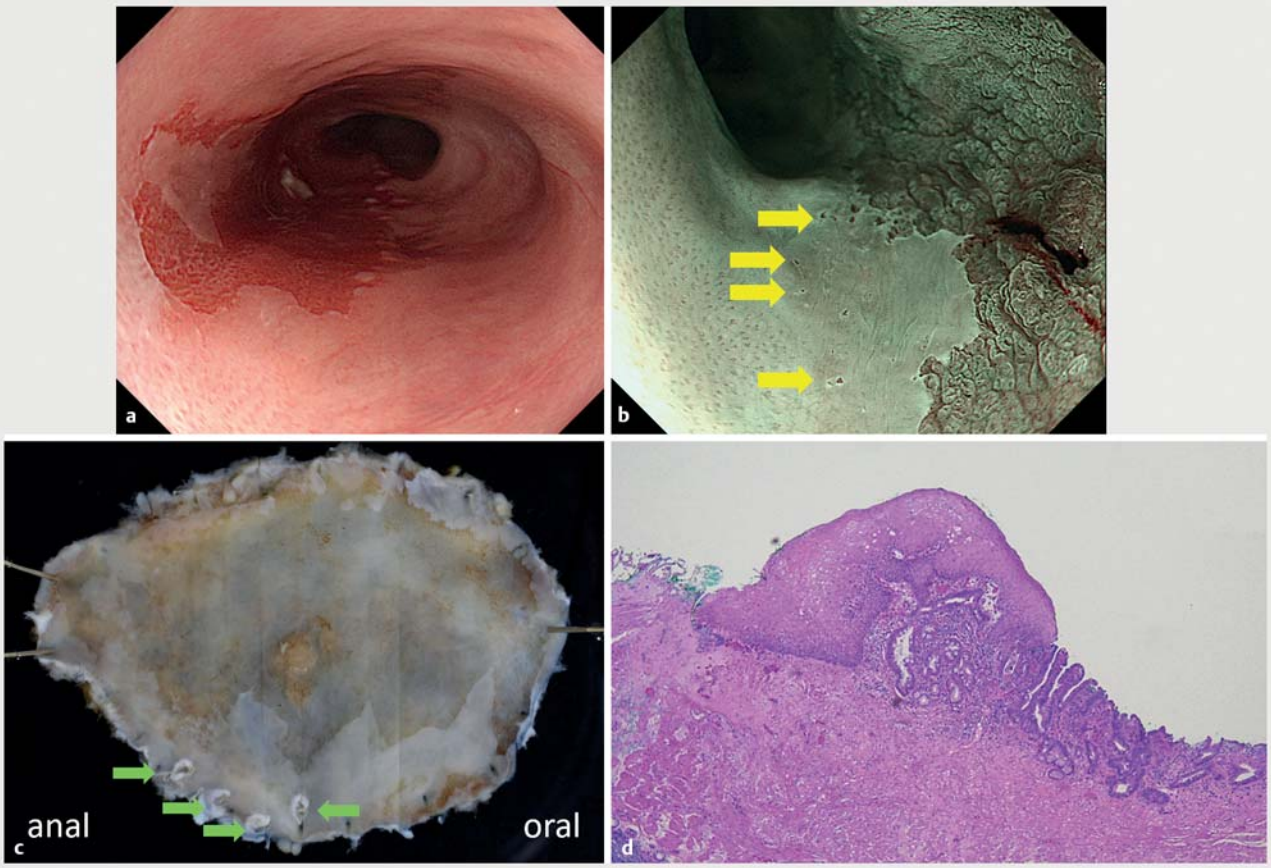

▶ **Fig. 4** **a** White light image taken before the second endoscopic submucosal dissection. **b** Before the second endoscopic submucosal dissection, acetic acid is sprayed on the regenerating epithelium to check for the opening of the cancerous glands. One area shows a slight white change suspicious of glandular epithelium underlying the squamous epithelium (yellow arrows). **c** The resected specimen from the second endoscopic submucosal dissection. Preoperative marking, including the area that showed a slight white change, can be seen (green arrows). **d** Histopathologically, the area is confirmed to have adenocarcinoma underlying the squamous epithelium.

There was no postoperative stenosis. Subsequently, the Barrett's mucosa was found to be completely covered with squamous epithelium. No recurrence has been observed in the past 2 years.

Discussion

ESD is increasingly being recognized as a superior resection technique for superficial gastrointestinal neoplastic lesions because of its high en bloc and curative resection rates. Moreover, its usefulness and safety in Barrett's esophagus neoplasia have also been confirmed. It is one of the standard treatments for early Barrett's esophageal carcinoma and high-grade dysplasia [3, 4]. However, if circumferential Barrett's lesions, such as in the present cases, are removed with circumferential en bloc resection by ESD, severe postoperative stenosis is inevitable. Even with preventive measures (such as oral steroids and/or local injections), postoperative stenosis occurs in 36 % to 100 % of patients [5]. Therefore, we performed stepwise ESD with local steroid injections in three cases: only one experienced mild stenosis (which was resolved with single balloon dilation), and no severe stenosis was observed in any case. In addition, oral steroids were not used in these patients, which may be an advantage of stepwise ESD because corticosteroid treatment may raise concerns about severe AEs, including immunosuppression, psychiatric disturbances, diabetes, peptic ulceration, and osteoporosis. These findings show that stepwise ESD is an effective treatment for early circumferential Barrett's lesions with respect to postoperative stenosis prevention and no necessity of oral steroids. However, the indications for stepwise ESD must be carefully considered; this strategy is not recommended for all lesions with whole circumferential Barrett's dysplasia. Basically, en bloc resection by ESD is preferred because it provides a detailed pathologic diagnosis and reduces the risk of recurrence. According to Miwata et al, a circumferential resection of the esophagus longer than 5 cm is associated with a high risk of severe postoperative stenosis [9]. Therefore, it would be better if the indication criteria of a lesion that fitted stepwise ESD included a resection diameter that exceeds 5 cm in length.

In Western countries, the efficacy of stepwise radical endoscopic resection (SR-ER) involving the cap or multiband mucosectomy techniques has proven effective in Barrett's lesions

[10]. The American Gastroenterological Association and European guidelines have referred to this method as an effective treatment option for early Barrett's lesions [11, 12]. However, SR-ER is associated with a high postoperative stenosis rate of 49.7 % [13]. In the current case series, stepwise ESD led to only mild stenosis in one case. The key reason behind this difference could be that the stepwise ESD allowed selection of the incision layer, and we intentionally resected the shallow submucosal layer. This approach may have helped prevent stenosis because sufficient submucosal layer was left behind at the ulcer site following resection, enabling successful local steroid injections. Furthermore, unlike SR-ER, stepwise ESD also enabled detailed pathological evaluation of the resected lesion, which is also a major advantage of stepwise ESD.

ER with radiofrequency ablation (RFA) is another treatment option used in Western countries. When mucosal irregularities, including nodularity, ulceration, or flat but irregular mucosal contour, are detected as suspected neoplasia, endoscopic mucosal resection is recommended for such visible lesions. Furthermore, if the mucosa surrounding the visible lesion is pathologically confirmed to be dysplastic, endoscopic ablative therapy of the residual dysplastic epithelium is recommended [11]. Although this strategy has shown promising outcomes in recent studies, it carries a risk of subsquamous adenocarcinoma recurrence [14]. Subsquamous recurrence may occur following ablation therapy due to an inadequate number of RFA sessions, which leads to the residual neoplastic epithelium. Stepwise ESD, which can achieve uniform dissection of the submucosal layer underlying the lesion, can help overcome this risk of subsquamous adenocarcinoma recurrence.

In addition, before each ESD session, a detailed diagnosis of the lateral extension was performed using NBI-ME and acetic acid spray. As shown in the representative case, spraying acetic acid before the second ESD revealed a white color change in a small area of the regenerative squamous epithelium. This area was also resected and histopathologically confirmed to have carcinoma underlying the squamous epithelium. Given that stepwise ESD treatment is performed with a detailed diagnosis of the lateral extension of the lesion, we believe that it can help minimize residual neoplastic epithelium. Therefore, stepwise ESD is expected to achieve a lower postoperative recurrence rate.

At present, in Japan, when ESD treatment is performed for non-circumferential Barrett's carcinoma developing in LSBE, only the neoplastic lesion is resected, and the remaining Barrett's mucosa is observed. However, the risk of metachronous carcinoma from the remaining Barrett's mucosa is relatively high, and there is a possibility that micro lesions that are difficult to detect endoscopically may exist in the remaining Barrett's mucosa. Therefore, it would be better to resect the residual Barrett's mucosa, and we believe that this stepwise ESD procedure is recommended. The usefulness of stepwise ESD for the treatment of non-circumferential carcinoma in LSBE will need to be investigated at multiple institutions in the future.

The present study had some limitations. First, it included a small sample size. In Japan, the incidence of LSBE cancer is low due to the low incidence of LSBE itself. Even in a high-volume endoscopic center like ours, we encountered only three cases of early circumferential Barrett's dysplasia and carcinoma. However, we believe that this treatment method can be applied not only to Barrett's esophageal cancer but also to squamous cell carcinoma (SCC) of the esophagus. In fact, in our clinical practice, a few cases of circumferential SCCs were successfully treated with stepwise ESD. Therefore, this treatment strategy may help reduce the risk of severe stenosis after endoscopic resection of esophageal lesions. Second, this study had the short follow-up period. Long-term follow-up is necessary to clarify the tumor recurrence rate after the stepwise ESD.

Conclusions

In conclusion, stepwise ESD may be an advantageous and safe technique for early circumferential Barrett's adenocarcinoma. Future studies with large sample sizes and longer follow-up are required.

Competing interests

The authors declare that they have no conflict of interest.

References

[1] Hongo M, Nagasaki Y, Shoji T. Epidemiology of esophageal cancer: Orient to Occident. Effects of chronology, geography and ethnicity. J Gastroenterol Hepatol 2009; 24: 729–735

[2] Koike T, Nakagawa K, Iijima K et al. Endoscopic resection (endoscopic submucosal dissection/endoscopic mucosal resection) for superficial Barrett's esophageal cancer. Dig Endosc 2013; 25: (Suppl. 01): 20–28

[3] Martelli MG, Duckworth LV, Draganov PV. Endoscopic submucosal dissection is superior to endoscopic mucosal resection for histologic evaluation of Barrett's esophagus and Barrett's-related neoplasia. Am J Gastroenterol 2016; 111: 902–903

[4] Shimizu T, Fujisaki J, Omae M et al. Treatment outcomes of endoscopic submucosal dissection for adenocarcinoma originating from long-segment Barrett's esophagus versus short-segment Barrett's esophagus. Digestion 2018; 97: 316–323

[5] Iizuka T, Kikuchi D, Hoteya S et al. Effectiveness of modified oral steroid administration for preventing esophageal stricture after entire circumferential endoscopic submucosal dissection. Dis Esophagus 2018; 31: doi:10.1093/dote/dox140

[6] Koike Y, Hirasawa D, Fujita N et al. Usefulness of the thread-traction method in esophageal endoscopic submucosal dissection: randomized controlled trial. Dig Endosc 2015; 27: 303–309

[7] Yamagata T, Hirasawa D, Fujita N et al. Efficacy of acetic acid-spraying method in diagnosing extension of Barrett's cancer under the squamous epithelium. Dig Endosc 2012; 24: 309–314

[8] Schlemper RJ, Riddell RH, Kato Y et al. The Vienna classification of gastrointestinal epithelial neoplasia. Gut 2000; 47: 251–255

[9] Miwata T, Oka S, Tanaka S et al. Risk factors for esophageal stenosis after entire circumferential endoscopic submucosal dissection for superficial esophageal squamous cell carcinoma. Surg Endosc 2016; 30: 4049–4056

[10] Peters FP, Kara MA, Rosmolen WD et al. Stepwise radical endoscopic resection is effective for complete removal of Barrett's esophagus

with early neoplasia: a prospective study. Am J Gastroenterol 2006; 101: 1449–1457

[11] Shaheen NJ, Falk GW, Iyer PG et al. ACG clinical guideline: diagnosis and management of Barrett's esophagus. Am J Gastroenterol 2016; 111: 30–50

[12] Pimentel-Nunes P, Dinis-Ribeiro M, Ponchon T et al. Endoscopic submucosal dissection: European Society of Gastrointestinal Endoscopy (ESGE) Guideline. Endoscopy 2015; 47: 829–854

[13] Pouw RE, Seewald S, Gondrie JJ et al. Stepwise radical endoscopic resection for eradication of Barrett's oesophagus with early neoplasia in a cohort of 169 patients. Gut 2010; 59: 1169–1177

[14] Titi M, Overhiser A, Ulusarac O et al. Development of subsquamous high-grade dysplasia and adenocarcinoma after successful radiofrequency ablation of Barrett's esophagus. Gastroenterology 2012; 143: 564–566 e561