

Fetal Profile Markers for the Detection of Robin Sequence in Fetuses with Retrognathia

Fetale Profilmarker für die Erkennung der Robin-Sequenz bei Feten mit Retrognathie

Authors

Cornelia Wiechers^{1, 2}, Christian Poets^{1, 2}, Markus Hoopmann³, Karl Oliver Kagan³

Affiliations

- 1 Department of Neonatology, University Hospital, Eberhard Karls University Tübingen, Tübingen, Germany
- 2 Interdisciplinary Center for Craniofacial Malformations, University Hospital, Eberhard Karls University Tübingen, Tübingen, Germany
- 3 Department of Obstetrics and Gynaecology, University of Tübingen, Tübingen, Germany

Key words

Robin sequence, infant, upper airway obstruction, prenatal screening, retrognathia

received 19.03.2021

accepted 23.09.2021

published online 01.12.2021

Bibliography

Ultraschall in Med 2023; 44: 299–306

DOI 10.1055/a-1659-2499

ISSN 0172-4614

© 2021, Thieme. All rights reserved.

Georg Thieme Verlag KG, Rüdigerstraße 14, 70469 Stuttgart, Germany

Correspondence

Markus Hoopmann

University of Tübingen

Department of Obstetrics and Gynaecology, Calwer Str. 7, 72076 Tübingen, Germany

mhoopmann@gmx.de

ABSTRACT

Objective To determine whether the prefrontal space ratio (PSFR), inferior facial (IFA) and maxilla-nasion-mandible angle (MNM), and the fetal profile line (FPL) are helpful in identifying fetuses with Robin sequence (RS) in cases with isolated retrognathia, and thus better predict the likelihood of immediate need for postnatal respiratory support.

Methods This was a retrospective matched case-control study of fetuses/infants with isolated retrognathia with or without RS receiving pre- and postnatal treatment at the University Hospital of Tübingen, Germany between 2008 and 2020. The PSFR, IFA, MNM, and FPL were measured in affected

and normal fetuses according to standardized protocols. Cases were stratified into isolated retrognathia and RS.

Results 21 (n = 7 isolated retrognathia, n = 14 RS) affected fetuses and 252 normal fetuses were included. Their median gestational age at ultrasound examination was 23.6 and 24.1 weeks, respectively. In fetuses with isolated retrognathia and RS, the PSFR, IFA, and FPL were significantly different from the normal population. At a false-positive rate of 5%, the detection rate was 76.2% for the PSFR, 85.7% for the IFA, and 90.5% for both parameters combined. However, all parameters failed to distinguish between isolated retrognathia and RS.

Conclusion PSFR and IFA are simple markers for identifying retrognathia prenatally. However, they are not helpful for the detection of RS in fetuses with isolated retrognathia. Therefore, delivery should take place in a center experienced with RS and potentially life-threatening airway obstruction immediately after birth.

ZUSAMMENFASSUNG

Zielsetzung Es sollte bestimmt werden, ob das präfrontale Raumverhältnis (PSFR), der inferiore faziale Winkel (IFA) und der Maxilla-Nasion-Mandibula-Winkel (MNM) oder die fetale Profillinie (FPL) bei der Identifizierung von Föten mit Robin-Sequenz (RS) in Fällen mit isolierter Retrognathie hilfreich sind, um so die Wahrscheinlichkeit eines unmittelbaren Bedarfs an postnataler Atmungsunterstützung besser vorherzusagen zu können.

Methoden Dies war eine retrospektive, gematchte Fall-Kontroll-Studie von Föten/Kindern mit isolierter Retrognathie mit oder ohne RS, die zwischen 2008 und 2020 im Universitätsklinikum Tübingen, Deutschland prä- und postnatal behandelt wurden. Die PSFR, IFA, MNM und FPL wurden bei betroffenen und normalen Föten nach standardisierten Protokollen gemessen. Die Patienten wurden in isolierte Retrognathie und RS unterteilt.

Ergebnisse 21 (n = 7 isolierte Retrognathie, n = 14 RS) betroffene und 252 normale Föten wurden eingeschlossen. Das mediane Gestationsalter bei der Ultraschalluntersuchung betrug 23,6 bzw. 24,1 Wochen. Bei Föten mit isolierter Retrognathie und RS unterschieden sich die PSFR, IFA und FPL signifikant von der normalen Population. Bei einer Falsch-Positiv-Rate von 5% betrug die Erkennungsrate 76,2% für die PSFR,

85,7% für die IFA und 90,5% für beide Parameter zusammen. Alle Parameter konnten jedoch nicht zwischen isolierter Retrognathie und RS unterscheiden.

Schlussfolgerung PSFR und IFA sind einfache Marker zur pränatalen Identifizierung von Retrognathien. Sie sind jedoch

nicht hilfreich für die Erkennung von RS bei Föten mit isolierter Retrognathie. Daher sollte die Entbindung in einem Zentrum erfolgen, das Erfahrung mit RS und einer potenziell lebensbedrohlichen Atemwegsobstruktion unmittelbar nach der Geburt hat.

Introduction

Retrognathia, characterized by an abnormally posterior lower jaw position relative to the maxilla, is a common finding in prenatal medicine. Its strong association with chromosomal defects and genetic syndromes is well known. However, in the absence of other morphological or chromosomal aberrations, antenatal differentiation between isolated retrognathia and Robin Sequence (RS) remains challenging [1, 2].

After birth, the diagnosis of RS is based on the clinical triad of retrognathia, glossoptosis, upper airway obstruction and optionally cleft palate. In contrast, in isolated retrognathia, none of these additional findings are present. In RS, antenatal diagnosis is desirable to improve postnatal management, as these newborns may have life-threatening airway obstruction [3].

Unfortunately, the prenatal detection rate of RS is low, ranging from 7–20% [4, 5, 6]. In a prospective epidemiologic study from Germany, only 16% of affected infants were detected before birth [4].

Besides subjective assessment of the facial profile [7], several quantitative approaches have been used to identify retrognathia and RS and to distinguish both entities [1, 2, 8, 9, 10, 11, 12, 13]. In a large prospective study of about 8,000 pregnancies, Bronshtein et al. investigated if glossoptosis can be predicted by assessing the movement of the tongue over a period of 20–30 min [8]. They found two fetuses with glossoptosis and micrognathia and no false-positive cases. However, the assessment was time-consuming and not practical for routine care. Others examined the soft palate, but also with limited success in a screen-

ing setup [5, 14]. Therefore, micro- and retrognathia remain the key prenatal feature for the detection of both isolated retrognathia and RS. In addition to the subjective assessment of the fetal facial profile, some groups have tried to standardize diagnosis by assessing the inferior facial angle (IFA) [1, 9, 10], the maxilla-nasion-mandible angle (MNM) [12], and the fetal profile line (FPL; ► Fig. 1, ► Fig. 2) [11]. However, none have examined whether these markers can be used to distinguish between retrognathia and RS [1, 9, 11, 12, 15].

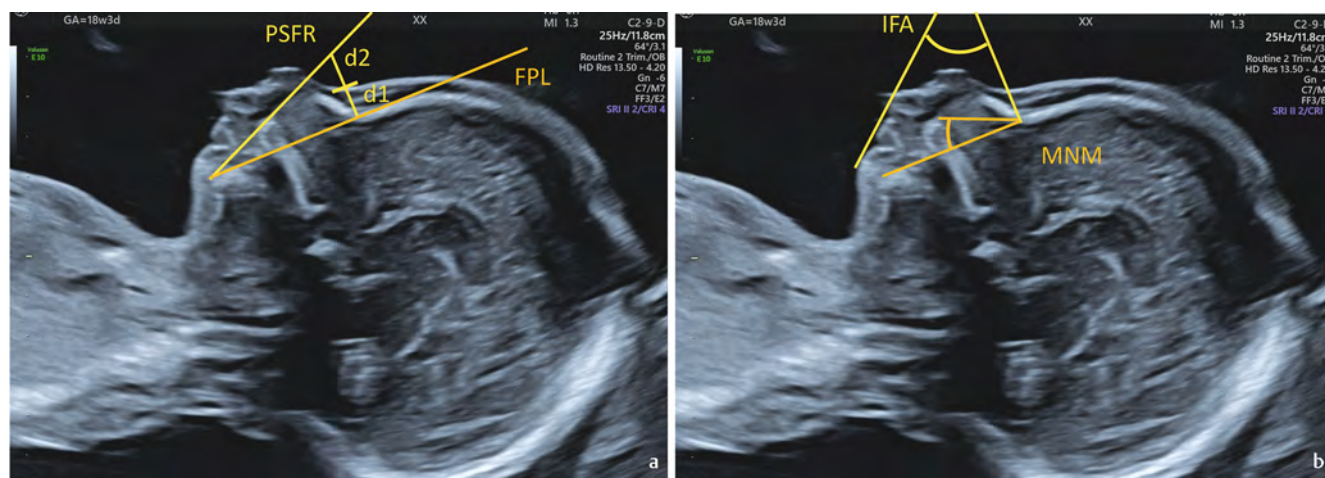
In this study, we set out to examine whether prenatal ultrasound markers for the standardized assessment of the fetal profile can be used to distinguish between isolated retrognathia and RS, and thus better predict the likelihood of immediate need for postnatal respiratory support.

Methods

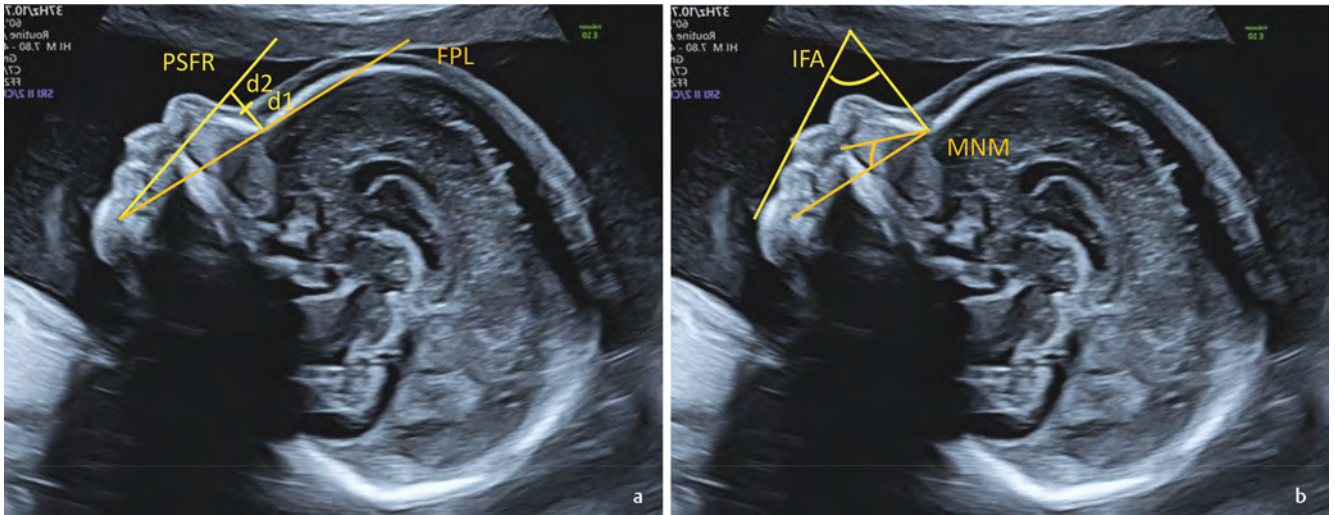
This is a retrospective case – match study utilizing stored 2D images of second and third trimester fetal profiles. The prenatal ultrasound examinations used in this study were performed at the Department of Prenatal Medicine at the University of Tübingen, Germany.

Data acquisition

We searched our digital database for pregnancies in which a postnatal diagnosis of isolated retrognathia or RS had been made and that had an ultrasound examination after 14 weeks of gestation. In pregnancies in which more than one examination was per-



► Fig. 1a: Measurement of the prefrontal space ratio (PSFR) and the fetal profile line (FPL) in a fetus with RS; b: Measurement of the inferior facial angle (IFA) and maxilla-nasion-mandible angle (MNM) in a fetus with RS.



► **Fig. 2a:** Measurement of the prefrontal space ratio (PFSR) and the fetal profile line (FPL) in a normal fetus; **b:** Measurement of the inferior facial angle (IFA) and maxilla-nasion-mandible angle (MNM) in a normal fetus.

formed, only the earliest suitable examination was used for analysis. Cases with complex defects or chromosomal abnormalities were excluded.

For each affected pregnancy, we identified 12 normal cases without fetal defects or chromosomal anomalies and an uneventful outcome. The normal cases were matched for the gestational age of the affected fetuses.

For an image to be acceptable for assessment, it had to meet the following criteria: true mid-sagittal section of the fetal profile (preferably with the corpus callosum visible) and clearly identifiable anterior edges of the mandible and maxilla as well as the leading edge of the bony forehead and the skin over the forehead. The magnification was such that the profile filled most of the image.

Prenatal examination

In each case, the PFSR, MNN, IFA, and the fetal profile line were assessed according to established protocols (► **Fig. 1, 2**) [13]. In short, the MNM angle was defined as the angle between the lines maxilla–nasion and mandible–nasion in the exact median plane. The IFA angle was measured by the crossing of two lines: a line orthogonal to the vertical part of the forehead, drawn at the level of the synostosis of the nasal bones and a second line joining the tip of the mentum and the anterior border of the more protrusive lip. The FP line was defined as the line that passes through the midpoint of the anterior border of the mandible and the nasion. When the FP line passed lengthwise through the frontal bone, this was denoted ‘zero’, when it passed the frontal bone posteriorly, its position was denoted ‘positive’, and when it passed the frontal bone anteriorly, its position was denoted ‘negative’. The PFSR was obtained by dividing the distance between the leading edge of skull and the prenasal skin (D1) by the distance from the prenasal skin to the point where the mandibulo-maxillary line is intercepted (D2) (► **Fig. 2**). The mandibulo-maxillary line was drawn between the anterior edge of the mental protuberance to the anterior edge of the maxilla and extended towards the forehead. The PFSR was determined by dividing D2 by D1. In a training data-

set containing 50 cases, all measurements were taken by two operators (C.W. and K.O.K) and repeated until measurements were within a 5% margin. These measurements were not included in the study results. After finishing with the training dataset, Operator 1 (C.W.) did the measurements in the study population, blinded to her own results and the fetal outcome.

Neonatal follow-up

Infants were born between 01/2008 and 09/2020 in our hospital and treated in the department of neonatology, which is a national referral center for RS and other craniofacial malformations. The affected infants were subdivided into a group of isolated retrognathia, and RS based on the postnatal examination. In neonates diagnosed with RS, postnatal treatment included an individual fitting of an orthodontic appliance (Tübingen palatal plate, TPP), nutritional training, and orofacial stimulation therapy. The treatment protocol has been described in detail elsewhere [16, 17, 18]. If necessary, upper airway obstruction was bridged by prone positioning, use of a nasopharyngeal tube, and/or continuous positive airway pressure (CPAP) prior to the onset of TPP treatment.

Cardiorespiratory sleep studies were performed in the first postnatal week in all infants with retrognathia and RS using a computerized polysomnographic system (Embla N 7000, Med-Care, Reykjavik, Iceland). Study design and evaluation criteria have been described elsewhere [16, 18]. In addition, a second sleep study was performed before discharge in infants treated with a TPP. Central, mixed, and obstructive apneas were identified, and a mixed-obstructive apnea index (MOAI) was calculated as the sum of mixed and obstructive apneas per hour of total sleep time based on standard criteria [19, 20]. If no sleep study could be performed due to very severe upper airway obstruction requiring a nasopharyngeal tube or CPAP, recordings were arbitrarily (and conservatively) assigned an MOAI of 30 for statistical analysis of the sleep study results.

Clinical data were collected from the department’s electronic database and medical records.

► **Table 1** Infant characteristics.

Variables	Isolated retrognathia n = 7	Robin sequence n = 14
Gestational age at birth (weeks)	40.4 (38.8 – 41.2)	38.3 (37.8 – 39.6)
Birth weight (g)	3420 (3280 – 3675)	3330 (2760 – 3485)
5 min APGAR score	9 (9 – 10)	8 (8–9)
Neonatal airway support*	1 (14%)	7 (50%)
Binasal CPAP	1 (14%)	3 (21%)
Nasopharyngeal tube without CPAP	0 (0%)	1 (7%)
Nasopharyngeal tube and CPAP	0 (0%)	3 (21%)
Intratracheal intubation or LMA	0 (0%)	0 (0%)
Sleep study (MOAI events/h)		
Upon admission	0.1 (0.1 – 0.7)	7.7 (2.7 – 30.0) ^b
At discharge	– ^a	0.9 (0.1 – 1.9)
Duration of hospital stay (days)	7 (6 – 9)	17 (16 – 20)

Values are given as median (IQR) or n (%); Abbreviations: CPAP = continuous positive airway pressure, LMA = laryngeal mask airway device; * Neonatal resuscitation in the delivery room; ^a No further sleep study was performed before discharge, as initially no OSA was present; ^b In n = 3 infants, no sleep study was performed due to severe upper airway obstruction and need for a nasopharyngeal tube with CPAP. Recordings were arbitrarily (and conservatively) assigned an MOAI of 30 for statistical analysis of the sleep study results.

This retrospective study was approved by the local ethics committee (407/2020 BO).

Statistical analysis

For each of the fetal profile markers, we used regression analysis to examine if there was a significant correlation with gestational age. If present, absolute measurements were transformed into MoM values (multiple of median, observed/expected measurements).

The results are shown as median and interquartile range (IQR). We used a Kruskal-Wallis test and a Mann-Whitney U-test for the post-hoc analysis to test for differences between the three study groups (normal, isolated Retrognathia, and RS). Prior to these statistical tests, a Kolmogorov Smirnov test was done to exclude normal distribution. An ROC curve analysis was used to compare the detection and false-positive rate in screening for retrognathia and RS with the PFSR, the IFA, and the combined use of both markers. Proportions were tested by chi-square test. The statistical analysis was carried out with IBM SPSS 24 (Armonk, New York, USA). A p-value < 0.05 was set as the significance threshold.

Results

In searching our database, we identified 21 neonates including 7 with isolated retrognathia and 14 with RS who were seen in our prenatal medicine unit during the course of pregnancy. A detailed description of the cases is given in ► **Table 1**. We added another 252 normal cases from our prenatal database. Thus, our study population comprised 273 pregnancies.

The median maternal and gestational age was 31.7 (IQR 28.3 – 35.1) years and 23.6 (IQR 21.4 – 29.5) weeks of gestation in the normal population and 32.5 (IQR 28.9 – 35.0) years and 24.1 (IQR 21.1 – 30.1) weeks of gestation in the index group (t-test for MA: p = 0.707, GA: p = 0.931).

Prefrontal space ratio

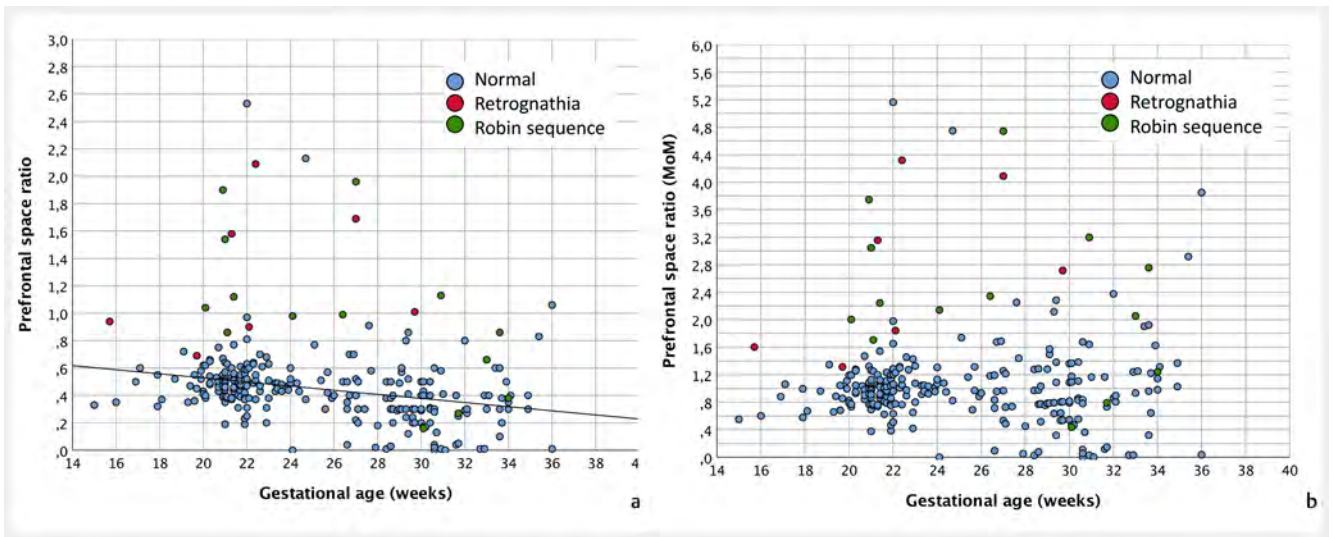
In the reference population, the median PFSR was 0.44. The ratio was dependent on gestational age (PFSR = 0.828 – 0.015 x gestational age, r = 0.291, p < 0.001). After transformation to MoM values, the median MoM was 0.96. In the groups of isolated retrognathia and RS fetuses, the median PFSR was 1.01 and 0.99, corresponding to MoM values of 2.72 and 2.19 (► **Fig. 3**). There was a significant difference between the three study groups (Kruskal-Wallis test p < 0.0001) and post-hoc testing indicated that the PFSR MoM was significantly higher in both affected groups than in the normal population. In the group of affected fetuses, the PFSR MoM distribution was not significantly different (post hoc Mann-Whitney U-test for both index groups vs. the reference group p < 0.0001 each; for isolated retrognathia vs. RS group p = 0.636).

Maxilla-nasion-mandible angle

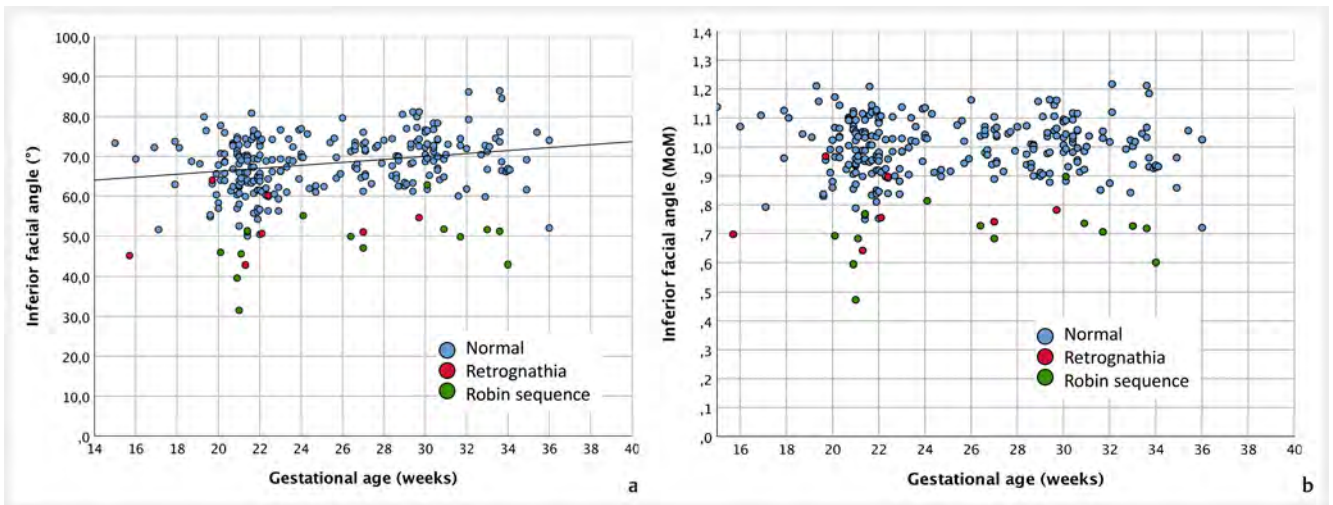
The median MNM angle in the normal and in both symptomatic groups was 17.5°, 18.6°, and 18.9°, respectively, without any significant difference (Kruskal-Wallis test p = 0.862).

Inferior facial angle

In the normal population, the median IFA angle was 68.8°. After transformation into MoM values, the median IFA angle was 1.0



► **Fig. 3a:** Prefrontal space ratio (PFSR) in absolute measurements. The line in the left graph indicates the regression line between the measurements and the gestational age in the normal population; **b:** Prefrontal space ratio (PFSR) in MoM values.



► **Fig. 4a:** Inferior facial angle (IFA) in absolute measurements. The line in the left graph indicates the regression line between the measurements and the gestational age in the normal population; **b:** Inferior facial angle (IFA) in MoM values.

MoM (IFA = $58.8 + 0.371 \times \text{gestational age}$, $r = 0.264$, $p < 0.0001$). In the group of isolated retrognathia and RS, the median IFA was 51.0° and 49.9° corresponding to 0.76 MoM and 0.71 MoM, respectively. Similar to the PFSR results, there was a significant difference between the three groups. Both affected groups had smaller IFA MoM measurements than the reference population (► **Fig. 4**). However, there was no difference between the two affected populations (Kruskal-Wallis test $p < 0.0001$, post hoc Mann-Whitney U-test for both index groups vs. the normal group, each $p < 0.0001$; for isolated retrognathia vs. the RS group $p = 0.128$).

Fetal profile line

In the normal and in the affected group, the fetal profile line was placed anterior to the frontal bone in 2 (0.8%) and 7 (33.3%)

cases (chi square $p < 0.0001$). In the isolated retrognathia and the RS group, 1 (14.3%) and 6 (42.9%) fetuses had an abnormal FPL (chi square $p = 0.190$).

The median values for the PFSR, the MNM, the IFA, and the FPL and their distribution in the group of fetuses with retrognathia and RS are summarized in ► **Table 2**.

Detection and false-positive rates in screening for isolated retrognathia and RS

The ROC curve analysis indicated that in screening for isolated retrognathia and RS, the combined use of PFSR and IFA was better than screening by each marker alone. However, the differences between the three approaches were not significant (► **Fig. 5**), (ROC curve analysis: area under the curve: PFSR: 0.888 (95% CI 0.787 – 0.989), IFA 0.966 (95% CI 0.929 – 1.000), PFSR + IFA

► **Table 2** Prenatal ultrasound markers.

	Normal fetuses n = 252	All affected fetuses n = 21	Isolated retrognathia n = 7	Robin sequence n = 14
PFSR Median (IQR)	0.44 (0.30 – 0.52)	0.99 (0.86 – 1.54)	1.01 (0.90 – 1.69)	0.99 (0.66 – 1.13)
▪ PFSR (MoM) ▪ Median (IQR)	0.96 (0.77 – 1.18)	2.24 (1.71 – 3.15)	2.72 (1.60 – 4.09)	2.19 (1.71 – 3.05)
MNM (angle) Median (IQR)	17.5 (15.5 – 20.6)	18.7 (15.0 – 20.6)	18.6 (15.6 – 20.3)	18.9 (14.4 – 22.8)
IFA (angle) Median (IQR)	68.8 (63.6 – 73.0)	50.6 (45.5 – 51.7)	51.0 (45.1 – 60.2)	49.9 (45.5 – 51.6)
▪ IFA (MoM) ▪ Median (IQR)	1.00 (0.94 – 1.06)	0.73 (0.68 – 0.77)	0.76 (0.70 – 0.90)	0.71 (0.68 – 0.74)
FPL abnormal n (%)	2 (0.8)	7 (33.3)	1 (14.3)	6 (42.9)

PFSR = prefrontal space ratio, MNM = maxilla-nasion-mandible angle; IFA = inferior facial angle, FPL = fetal profile line

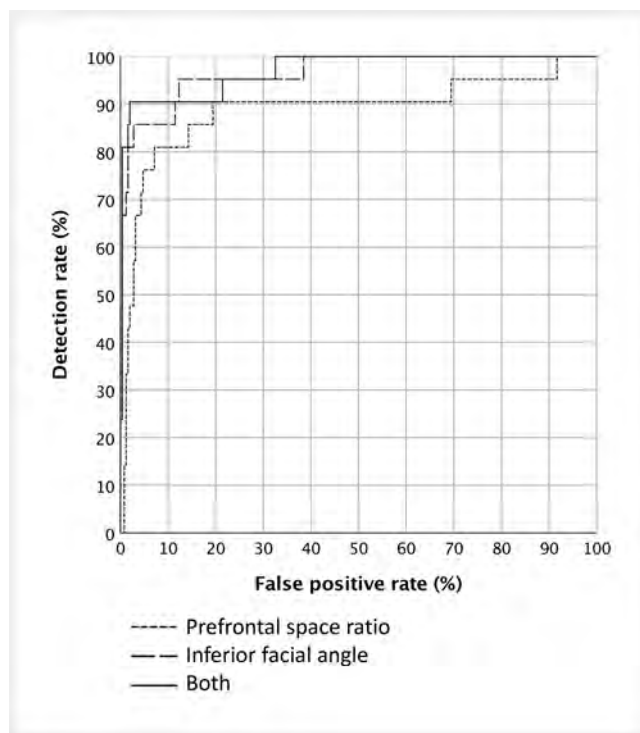
0.970 (95 % CI 0.935 – 1.000). For a false-positive rate of 5 %, the detection rate was 76.2 % for the PFSR, 85.7 % for the IFA, and 90.5 % for the combined use.

Discussion

In this study we have shown that PFSR, IFA, and the FPL are useful measurements to identify fetuses with isolated retrognathia or RS. For a false-positive rate of 5 %, the detection rate was up to 91 %. However, these parameters fail to distinguish between isolated retrognathia and RS.

Prenatal detection of RS is important for subsequent management and may improve the postnatal outcome. Although the diagnosis can initially cause psychological stress and negative parental emotions, it provides an opportunity for appropriate counseling and decision making about disease-specific postnatal treatment options [21]. Furthermore, delivery in an experienced center allows clinicians to prepare for a potentially life-threatening airway obstruction immediately after birth [3, 22]. Although some newborns show life-threatening airway obstruction immediately after birth, a substantial proportion of RS infants initially show more subtle clinical signs of upper airway obstruction [3, 23]. In some RS cases, the respiratory situation worsens gradually during the first postnatal weeks. Therefore, close follow-up with repeated sleep studies and careful monitoring of weight gain is required [23]. In contrast, in fetuses with isolated retrognathia, glossoptosis and upper airway obstruction are absent. Thus, postnatal management is generally less complicated. Unfortunately, it was not possible to distinguish these groups based on the facial profile markers, thus prenatal referral to a center with experience in RS management may be advisable for any fetus with retrognathia as defined above.

PFSR has been successfully used to screen for trisomy 21 in the second and third trimester of pregnancy, based on the characteristic facial profile with increased prenatal thickness and midface



► **Fig. 5** ROC curves in screening for isolated retrognathia and Robin sequence.

hypoplasia [24, 25]. The detection rate for trisomy 21 was 79 % for a false-positive rate of 5 %. In contrast to these data from trisomy 21, the median PFSR was lower in this study and dependent on gestational age. This is most probably due to the fact that we included more pregnancies from later weeks of gestation than in the study by Yazdi et al. [24], resulting in lower PFSR values. In terms of fetuses with isolated retrognathia or RS, the detection rate was 76 %, for a false-positive rate of 5 %. The MNM angle was

derived from cephalograms for assessing jaw relationships for an orthodontic diagnosis [12]. The authors examined 18 fetuses with various facial malformations and found that in all cases the MNM was below the 5th or above the 95th percentile. The series included one fetus with RS with an MNM of 22.8°. A considerably smaller MNM angle was found in normal Korean fetuses with an average of only 4.7° (SD 3.3°) [26]. This raises the question about a potential dependency on ethnic origin, which may limit the usefulness of this marker. In our cohort, the ethnic background was too homogeneously Caucasian to draw any conclusions. However, in view of fetuses with RS, the marker was not helpful in distinguishing between affected and normal fetuses.

Most research groups have focused on the IFA [1, 9, 10, 13, 27]. Our results are similar to those published previously. In our cohort, the IFA was 68.8° in the reference group and about 50° in both affected groups. Rotten et al. examined the IFA in 371 normal fetuses and the mean value in the 18th–28th gestational week was 65.5°. Eight fetuses in their study had RS, and in this group, the IFA ranged from 35 to 46°. Usually, an IFA of 50° is used as the lower limit for normal fetuses [10, 27]. We used the 5th percentile as the cut-off and observed a detection rate of 86%. In terms of FPL, we classified the examination of the fetal profile as abnormal if this line was anterior to the frontal bone. We found an abnormal FPL in 0.8% of controls and 33% of RS cases. Another group found no normal fetus with an abnormal FPL, while 81% of those with postnatally confirmed retrognathia had an abnormal FPL [11]. Lu et al. observed an association with gestational age and reported that prior to 24 weeks, the FPL was abnormal in 7% of cases, and afterwards in none of the normal fetuses [13].

In addition to the previously described ultrasound markers, there are also studies focusing on the prenatal diagnosis of micrognathia. Paladini et al. examined the jaw index, i. e., the antero-posterior and laterolateral diameter of the mandible, in a cross-sectional study [28]. In fetuses with micrognathia, the jaw index showed a sensitivity of 100% and a specificity of 98.1%, compared to 72.7% and 99.2% for the subjective assessment of the fetal profile [28]. A high sensitivity of 94% in 16 cases with micrognathia compared to healthy fetuses was shown by Kruse et al. using an index relating fetal mandibular length to femur length or gestational age [29]. However, mandibular imaging is very challenging as it requires an axial view of the mandible and is not part of the routine screening examination. The same is true for prenatal magnetic resonance tomography (MRT) studies [15, 30].

Our study has some limitations. First, it has a retrospective, single center design based on stored 2D images of the fetal profile. Second, our series of affected fetuses is relatively large compared to other studies, but after dividing it into two subgroups, the number of affected fetuses in each group became relatively small. The strength of this study lies in its image quality. We included only cases with a perfect midsagittal section of the face.

We acknowledge that a large prospective study would be a more solid basis for generalizable conclusions. However, due to the low prevalence of the disease, such a study cannot be carried out in a reasonable time frame.

In conclusion, facial profile measurements can be used to identify fetuses with isolated retrognathia or RS, but not to distinguish

between either entity. In the cohort with isolated RS, respiratory support (e. g., CPAP, nasopharyngeal tube) was required directly after birth in half of the cases, compared to one of seven neonates with isolated retrognathia. Therefore, if fetal retrognathia is suspected, delivery should take place in a center experienced in craniofacial malformations and prepared for potentially life-threatening airway obstruction immediately after birth.

Clinical Trial

Registration number (trial ID): 407/2020 BO | Trial registry: Ethical committee of the University of Tübingen, Gartenstraße 74, 72074 Tübingen

Acknowledgement

We are grateful to the nurses, midwives, speech therapists, physiotherapists, psychosocial workers, and physicians from the Departments of Obstetrics/Gynecology, Neonatology and Orthodontics.

Conflict of Interest

The authors declare that they have no conflict of interest.

References

- [1] Rotten D, Levallant JM, Martinez H et al. The fetal mandible: a 2D and 3D sonographic approach to the diagnosis of retrognathia and micrognathia. *Ultrasound Obstet Gynecol* 2002; 19: 122–130. doi:10.1046/j.0960-7692.2001.00622.x
- [2] Kaufman MG, Cassidy CI, Hyman CH et al. Prenatal Identification of Pierre Robin Sequence: A Review of the Literature and Look towards the Future. *Fetal Diagn Ther* 2016; 39: 81–89. doi:10.1159/000380948
- [3] Evans KN, Sie KC, Hopper RA et al. Robin sequence: from diagnosis to development of an effective management plan. *Pediatrics* 2011; 127: 936–948. doi:10.1542/peds.2010-2615
- [4] Vatlach S, Maas C, Poets CF. Birth prevalence and initial treatment of Robin sequence in Germany: a prospective epidemiologic study. *Orphanet J Rare Dis* 2014; 9: 9. doi:10.1186/1750-1172-9-9
- [5] Maarse W, Berge SJ, Pistorius L et al. Diagnostic accuracy of transabdominal ultrasound in detecting prenatal cleft lip and palate: a systematic review. *Ultrasound Obstet Gynecol* 2010; 35: 495–502. doi:10.1002/uog.7472
- [6] Holder-Espinasse M, Abadie V, Cormier-Daire V et al. Pierre Robin sequence: a series of 117 consecutive cases. *J Pediatr* 2001; 139: 588–590. doi:10.1067/mpd.2001.117784
- [7] Lind K, Aubry MC, Belarbi N et al. Prenatal diagnosis of Pierre Robin Sequence: accuracy and ability to predict phenotype and functional severity. *Prenat Diagn* 2015; 35: 853–858. doi:10.1002/pd.4619
- [8] Bronshtein M, Blazer S, Zalel Y et al. Ultrasonographic diagnosis of glossoptosis in fetuses with Pierre Robin sequence in early and mid pregnancy. *Am J Obstet Gynecol* 2005; 193: 1561–1564. doi:10.1016/j.ajog.2005.03.052
- [9] Nguyen JQN, Calabrese CE, Heaphy KJ et al. Can Robin Sequence Be Predicted From Prenatal Ultrasonography? *J Oral Maxillofac Surg* 2020; 78: 612–618. doi:10.1016/j.joms.2019.10.015
- [10] Di Pasquo E, Amiel J, Roth P et al. Efficiency of prenatal diagnosis in Pierre Robin sequence. *Prenat Diagn* 2017; 37: 1169–1175. doi:10.1002/pd.5162

- [11] de Jong-Pleij EA, Ribbert LS, Pistorius LR et al. The fetal profile line: a proposal for a sonographic reference line to classify forehead and mandible anomalies in the second and third trimester. *Prenat Diagn* 2012; 32: 797–802. doi:10.1002/pd.3904
- [12] de Jong-Pleij EA, Ribbert LS, Manten GT et al. Maxilla-nasion-mandible angle: a new method to assess profile anomalies in pregnancy. *Ultrasound Obstet Gynecol* 2011; 37: 562–569. doi:10.1002/uog.7768
- [13] Lu J, Sahota DS, Poon LC et al. Objective assessment of the fetal facial profile at second and third trimester of pregnancy. *Prenat Diagn* 2019; 39: 107–115. doi:10.1002/pd.5371
- [14] Nicholls W, Jennings R, Yeung Y et al. Antenatal Ultrasound Detection of Cleft in Western Australia from 2003 to 2012: A Follow-Up Study. *Cleft Palate Craniofac J* 2017; 54: 321–326. doi:10.1597/15-127
- [15] Nemeč U, Nemeč SF, Brugger PC et al. Normal mandibular growth and diagnosis of micrognathia at prenatal MRI. *Prenat Diagn* 2015; 35: 108–116. doi:10.1002/pd.4496
- [16] Buchenau W, Urschitz MS, Sautermeister J et al. A randomized clinical trial of a new orthodontic appliance to improve upper airway obstruction in infants with Pierre Robin sequence. *J Pediatr* 2007; 151: 145–149. doi:10.1016/j.jpeds.2007.02.063
- [17] Poets CF, Koos B, Reinert S et al. The Tübingen palatal plate approach to Robin sequence: Summary of current evidence. *J Craniomaxillofac Surg* 2019. doi:10.1016/j.jcms.2019.08.002
- [18] Poets CF, Maas C, Buchenau W et al. Multicenter study on the effectiveness of the pre-epiglottic baton plate for airway obstruction and feeding problems in Robin sequence. *Orphanet J Rare Dis* 2017; 12: 46. doi:10.1186/s13023-017-0602-8
- [19] Berry RB, Budhiraja R, Gottlieb DJ et al. Rules for scoring respiratory events in sleep: update of the 2007 AASM Manual for the Scoring of Sleep and Associated Events. Deliberations of the Sleep Apnea Definitions Task Force of the American Academy of Sleep Medicine. *J Clin Sleep Med* 2012; 8: 597–619. doi:10.5664/jcsm.2172
- [20] Berry RB, Gamaldo CE, Harding SM et al. AASM Scoring Manual Version 2.2 Updates: New Chapters for Scoring Infant Sleep Staging and Home Sleep Apnea Testing. *J Clin Sleep Med* 2015; 11: 1253–1254. doi:10.5664/jcsm.5176
- [21] Sreejith VP, Arun V, Devarajan AP et al. Psychological Effect of Prenatal Diagnosis of Cleft Lip and Palate: A Systematic Review. *Contemp Clin Dent* 2018; 9: 304–308. doi:10.4103/ccd.ccd_673_17
- [22] Duek I, Gil Z, Solt I. Modified ex utero intrapartum treatment procedure in a bicornuate uterus breech presentation Pierre Robin fetus with severe micrognathia and cleft palate. *Clin Case Rep* 2018; 6: 2040–2044. doi:10.1002/ccr3.1799
- [23] Poets CF, Wiechers C, Koos B et al. Pierre Robin and Breathing: What To Do and When. *Pediatr Pulmonol* 2021. doi:10.1002/ppul.25317
- [24] Yazdi B, Sonek J, Oetting C et al. Prefrontal space ratio in second- and third-trimester screening for trisomy 21. *Ultrasound Obstet Gynecol* 2013; 41: 262–266. doi:10.1002/uog.12261
- [25] Sonek J, Molina F, Hiett AK et al. Prefrontal space ratio: comparison between trisomy 21 and euploid fetuses in the second trimester. *Ultrasound Obstet Gynecol* 2012; 40: 293–296. doi:10.1002/uog.11120
- [26] Ko HS, Lee UY, Choi SK et al. Craniofacial inclination at 14 to 39 weeks' gestation in normal Korean fetuses. *J Ultrasound Med* 2012; 31: 569–576. doi:10.7863/jum.2012.31.4.569
- [27] Luedders DW, Bohlmann MK, Germer U et al. Fetal micrognathia: objective assessment and associated anomalies on prenatal sonogram. *Prenat Diagn* 2011; 31: 146–151. doi:10.1002/pd.2661
- [28] Paladini D, Morra T, Teodoro A et al. Objective diagnosis of micrognathia in the fetus: the jaw index. *Obstet Gynecol* 1999; 93: 382–386. doi:10.1016/s0029-7844(98)00414-1
- [29] Kruse T, Neuschulz J, Wilhelm L et al. Prenatal Diagnosis of Robin Sequence: Sensitivity, Specificity, and Clinical Relevance of an Index for Micrognathia. *Cleft Palate Craniofac J* 2020. doi:10.1177/1055665620972297
- [30] Resnick CM, Kooiman TD, Calabrese CE et al. An algorithm for predicting Robin sequence from fetal MRI. *Prenat Diagn* 2018; 38: 357–364. doi:10.1002/pd.5239