


# Percutaneous Aspiration Thrombectomy for Arterial Thromboembolic Occlusion Following Percutaneous Transluminal Angioplasty: Technical Success Rates and Clinical Outcomes

## Perkutane Aspirationstherombektomie bei thromboembolischer arterieller Okklusion nach perkutaner transluminaler Angioplastie: technische Erfolgsraten und klinisches Outcome

### Authors

Andreas Schicho<sup>1</sup>, Wolf Bäuml<sup>1</sup>, Niklas Verloh<sup>1</sup>, Lukas Philipp Beyer<sup>2</sup>, Wilma Schierling<sup>3</sup>, Wibke Uller<sup>4</sup>, Holger Gößmann<sup>5</sup>, Christian Stroszczyński<sup>1</sup>, Marco Dollinger<sup>1</sup> 

### Affiliations

- 1 Radiology, University Hospital Regensburg, Germany
- 2 Diagnostische und Interventionelle Radiologie, Klinikum Ernst von Bergmann gGmbH, Potsdam, Germany
- 3 Vascular and Endovascular Surgery, University Hospital Regensburg, Germany
- 4 Radiology, University Hospital Freiburg, Department of Radiology, Freiburg, Germany
- 5 Diagnostic and Interventional Radiology, University of Leipzig, Faculty of Medicine, Leipzig, Germany

### Key words

angiography, angioplasty, embolization, thrombectomy, interventional radiology

received 13.05.2021

accepted 10.09.2021

published online 21.10.2021

### Bibliography

Fortschr Röntgenstr 2022; 194: 291–295

DOI 10.1055/a-1652-1726

ISSN 1438-9029

© 2021. Thieme. All rights reserved.

Georg Thieme Verlag KG, Rüdigerstraße 14, 70469 Stuttgart, Germany

### Correspondence

PD Dr. Marco Dollinger

Radiology, University Hospital Regensburg, Franz-Josef-Strauss-Allee 11, 93053 Regensburg, Germany

Tel.: +49/941/944 74 10

Fax: +49/941/944 74 02

marco.dollinger@ukr.de

### ABSTRACT

**Purpose** We aimed to analyze the technical success rate of manual percutaneous aspiration thrombectomy (PAT) in patients with peripheral arterial thromboembolism as a complication of infrainguinal percutaneous transluminal angio-

plasty (PTA) and we sought to evaluate the 30-day postintervention clinical outcome.

**Materials and Methods** We retrospectively identified 29 patients (men/women, 18/11; mean age, 74 years) who underwent infrainguinal PAT to treat thromboembolic complications of infrainguinal PTA. Primary and secondary technical successes were defined as residual stenosis of <50% of the vessel diameter after PAT alone and PAT with additional PTA, respectively. Clinical outcome parameters (e.g., amputation, need for further intervention) were evaluated during the first 30 days after intervention.

**Results** The primary and secondary technical success rates were 58.6% (17/29) and 79.3% (23/29), respectively. Clinical outcome data were available for 93.1% (27/29) of patients. No further intervention was required within 30 days in 81.5% (22/27) of patients. Four patients underwent minor amputations owing to preexisting ulcerations (Rutherford Category 5), and no patients underwent major amputations (Rutherford Category 6). Revascularization of the previously treated vessel segment with PTA was necessary on the first postintervention day in one patient.

**Conclusion** Manual PAT, with PTA if needed, has a good technical success rate and satisfactory early clinical outcome in patients with iatrogenic thromboembolic complications after infrainguinal PTA.

### Key Points:

- Manual PAT is a possible first-choice treatment of infrainguinal PTA-induced acute thromboembolism.
- Performing additional PTA increases the success rate of manual PAT.
- Unlike catheter-directed intraarterial lysis, manual PAT carries no risk of bleeding.

### Citation Format

- Schicho A, Bäuml W, Verloh N et al. Percutaneous Aspiration Thrombectomy for Arterial Thromboembolic Occlusion Following Percutaneous Transluminal Angioplasty: Technical Success Rates and Clinical Outcomes. Fortschr Röntgenstr 2022; 194: 291–295

## ZUSAMMENFASSUNG

**Ziel** Bestimmung der technischen Erfolgsrate einer manuell durchgeführten, perkutanen Aspirationsthorombektomie (PAT) in Patienten mit peripherer arterieller Thrombembolie als Komplikation einer infrainguinalen perkutanen transluminalen Angioplastie (PTA) sowie Erhebung des klinischen Outcomes innerhalb der ersten 30 Tage nach der Intervention.

**Material und Methoden** Es wurden retrospektiv 29 Patienten (männlich/weiblich, 18/11; mittleres Alter, 74 Jahre) identifiziert, bei denen eine infrainguinale PAT zur Behandlung einer thrombembolischen Komplikation im Rahmen einer infrainguinalen PTA durchgeführt wurde. Primärer bzw. sekundärer technischer Erfolg wurden definiert als residuelle Gefäßstenose <50 % des Gefäßdurchmessers nach alleiniger PAT bzw. nach PAT mit additiver PTA. Parameter des klinischen Outcomes (bspw. Amputation, Notwendigkeit eines Folgeeingriffs) wurden für die ersten 30 postinterventionellen Tage erhoben.

**Ergebnisse** Die primäre bzw. sekundäre technische Erfolgsrate lag bei 58,6 % (17/29) bzw. 79,3 % (23/29). Daten über das klinische Outcome waren von 93,1 % (27/29) der Patienten

verfügbar. Innerhalb der ersten 30 Tage nach der Intervention war in 81,5 % (22/27) der Patienten kein Folgeeingriff nötig. Bei 4 Patienten wurden Minor-Amputationen aufgrund vorbestehender Ulcera (Rutherford-Kategorie 5) durchgeführt; es erfolgten keine Major-Amputationen (Rutherford-Kategorie 6). Bei einer Patientin war am ersten postinterventionellen Tag eine neuerliche Revaskularisation des am Vortag mittels PTA behandelten Gefäßabschnitts notwendig.

**Schlussfolgerung** Bei Patienten mit thrombembolischer Komplikation i.R.e. infrainguinalen PTA weist eine manuelle PAT, falls notwendig in Kombination mit PTA, gute technische sowie klinische Erfolgsraten auf.

### Kernaussagen:

- Eine manuelle PAT ist eine mögliche primäre Behandlungsmethode akuter thrombembolischer Komplikationen nach infrainguinaler PTA.
- Deutliche Steigerung des PAT-Erfolgs durch additive PTA möglich.
- PAT hat gegenüber der intraarteriellen Katheterlyse keine Blutungsrisiken.

## Introduction

Acute thromboembolic arterial occlusion is a potential complication of peripheral endovascular revascularization. According to previous reports, the incidence of symptomatic thromboembolic complications is approximately 5 % [1–5]. Before the introduction of catheter-based percutaneous aspiration thrombectomy (PAT) in the 1980s, surgical extraction was the method of choice for treating arterial emboli and thrombi [6]. Currently, several endovascular approaches, such as catheter-directed thrombolysis and PAT, are available. Since PAT can be performed simultaneously with percutaneous transluminal angioplasty (PTA) and – in contrast to catheter-directed thrombolysis – can be performed in patients with contraindications to thrombolysis, it has quickly become widely accepted and is the preferred technique for endovascular revascularization [7].

The aim of this study was to investigate the technical success rates and early clinical outcomes of patients who underwent manual PAT to treat arterial thromboembolic complications of infrainguinal PTA.

## Materials and Methods

### Study design and patients

We conducted a single-center, retrospective, observational study to analyze the technical success rates and early clinical outcomes of patients who underwent PAT to treat arterial thromboembolic complications of infrainguinal PTA between 2011 and 2019. Each patient signed an informed consent form for the endovascular procedure. The local ethics committee approved this study (decision/protocol number 19–1483–104). Two radiologists (eight and

six years of experience in interventional radiology) reviewed all cases in detail in consensus reading. The 29 participants included in this study consisted of 18 men (62.1 %) and 11 women (37.9 %), with a mean age of 74.2 years  $\pm$  9.4 (range: 57–89 years). Among all participants, 93.1 % (27/29) had hypertension, 51.7 % (15/29) had diabetes mellitus, 34.5 % (10/29) had atrial fibrillation, 51.7 % (15/29) had chronic renal failure, 44.8 % (13/29) had a history of nicotine abuse, and 13.8 % (4/29) had a history of stroke.

### Percutaneous transluminal angioplasty

All interventions were performed under sterile conditions. Local anesthetics were applied subcutaneously at the intended puncture site. The common femoral artery was punctured in an antegrade manner, a 5- or 6-French sheath (Terumo, Leuven, Belgium) was inserted, and diagnostic contrast-enhanced digital subtraction angiography (DSA) was performed. If PTA was being performed to treat a stenotic or occluded infrainguinal arterial segment, 5000 units of heparin were administered intra-arterially. 27 patients (93.1 %) had been receiving oral aspirin therapy before PTA. Intravenous administration of 500 mg of aspirin was recommended for patients who were not receiving oral aspirin before the intervention. At the end of the procedure, DSA was performed again to identify possible complications and to document the outcomes of the procedure.

### Percutaneous aspiration thrombectomy

PAT was considered indicated and was attempted if DSA demonstrated acute thromboembolic complications resulting in significantly impaired lower extremity perfusion. To perform PAT, 5- or 6-French end-hole catheters (e. g., Guider Softip™, Boston Scientific, Marlborough, Massachusetts, USA) were used, depending on

the size of the occluded vessel. In patients with crural artery occlusion, 4- or 5-French diagnostic catheters (e. g., Glidecath, Terumo, Leuven, Belgium) were used. In all patients, an attempt was made to place a guidewire (crural arteries: 0.014 inch, Boston Scientific, Marlborough, MA, USA; level above crural arteries: 0.035 inch, Terumo, Leuven, Belgium) past the thromboembolism. Via this guidewire, the catheter was introduced, and its tip was placed immediately distal to the distal end of the thromboembolism. After removal of the guidewire, PAT was performed by slow withdrawal of the catheter with manual aspiration using a 20- or 50-mL syringe. This procedure was typically performed several times to achieve complete clot removal. Outcomes of the PAT were documented using DSA. We recommended postintervention anticoagulation using intravenous heparin and a target partial thromboplastin time of 60–80 seconds for at least 48 h. Additionally, 75 mg of clopidogrel daily for 4 weeks and 100 mg of aspirin daily for life were recommended.

### Technical and clinical success

The following definitions were used to assess technical and clinical success:

- Primary technical success: residual stenosis of <50 % of the vessel diameter after PAT alone.
- Secondary technical success: residual stenosis of <50 % of the vessel diameter after PAT with additional PTA [8, 9].
- Clinical success: no need for additional intervention (e. g., endovascular angioplasty and/or catheter-directed thrombolysis and/or PAT or major/minor amputation) within the first 30 days after intervention.

## Results

### Technical success

In all patients (29/29), a vessel below the knee joint level was occluded by acute thromboembolism (popliteal P3 segment,  $n = 2$  [6.9 %]; crural arteries,  $n = 27$  [93.1 %]). Primary and secondary technical success was achieved in 58.6 % (17/29) and 79.3 % (23/29) of patients, respectively; the difference in the primary and secondary success rates was due to six patients requiring additional balloon PTA. ► **Fig. 1** shows the angiographic images of a patient who successfully underwent PAT for thromboembolic occlusion of a peripheral crural artery after successful PTA for a superficial femoral/popliteal artery occlusion. No patients included in this study had complications following PAT.

Neither primary nor secondary technical success was achieved in 20.7 % (6/29) of patients. Four (66.7 %) and one (16.7 %) were successfully revascularized with catheter-directed thrombolysis and surgical thrombectomy, respectively. No further measures were taken in the remaining patient (16.7 %) because this patient was asymptomatic with an adequately vascularized anterior tibial artery; the patient had no impairments and an uneventful follow-up.

After the intervention, intravenous heparin was administered with a target partial thromboplastin time of 60–80 seconds for a

median duration of two days (range: 2–6 days) in 26 (89.7 %) patients.

### Clinical outcome

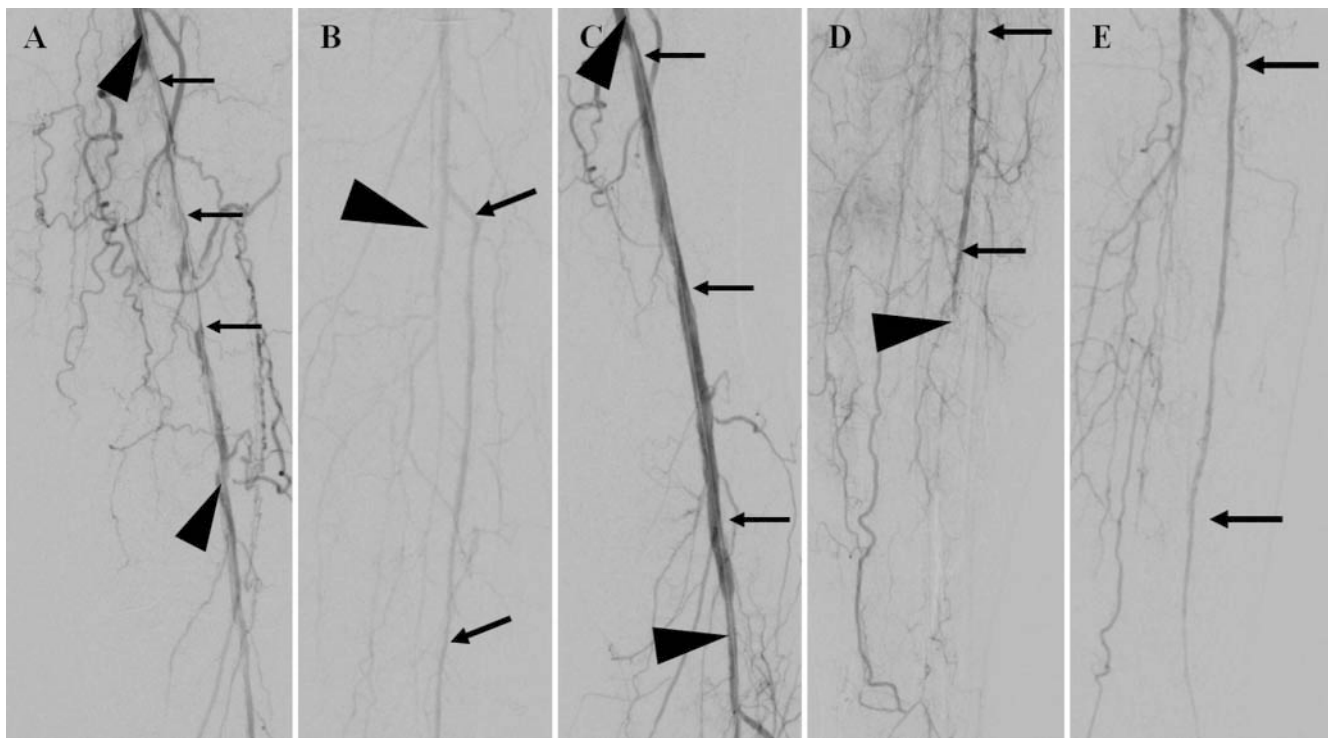
Clinical outcome data for the first 30 days after intervention were available for 27/29 (93.1 %) patients; two (6.9 %) patients, neither of whom required further revascularization or amputation during their hospital stay, were lost to follow-up. During the 30-day follow-up period, minor amputations (forefoot or toe) were performed in 4/27 (14.8 %) patients due to preexisting tissue damage. Furthermore, one (3.7 %) patient had reocclusion on the day after successful popliteal artery PAT; this patient underwent interventional angiography. Since PAT was unsuccessful, the reocclusion was successfully treated with catheter-directed thrombolysis.

## Discussion

Up to 5 % of infrainguinal arterial interventions are complicated by symptomatic acute thromboembolism [2–5, 8]. The feasibility and efficacy of PAT has been reported in previous studies. Starck et al. [10] reported a clinical success rate of 93 % (42/45 procedures) for PAT alone or PAT with PTA and/or lytic infusion therapy. Wagner et al. [11] reported a primary technical success rate of 92 % (95/102 patients) for PAT in patients with acute embolic occlusion of infrainguinal arteries unrelated to PTA or chronic atherosclerotic arterial occlusive disease. In a recent study, Vorwerk et al. [12] reported that 98 % (153/156) of patients with acute lower limb ischemia underwent PAT. To restore adequate vessel patency, rotational thrombectomy was added in 38 % (60/156) of them. Occlusion sites below the knee joint level were noted in 39.7 % (62/156) of patients and rotational thrombectomy was added to PAT in 16 % (10/62) of them. Rotational thrombectomy was added to PAT in 53 % (50/94) of patients with an occlusion site at or above the knee level (94/156 [60.3 %]) [12]. In total, they achieved a technical success rate of 93 % (145/156) [12]. Schleder et al. studied the treatment of arterial thromboembolism with PAT followed by PTA and reported a success rate of 64 % (30/47) for PAT alone and 96 % (45/47) for PAT with PTA and/or stenting [7].

In this study, we evaluated the effectiveness of PAT, with PTA if needed, for the treatment of acute infrainguinal artery thromboembolism as a complication of infrainguinal PTA. The primary technical success rate was 59 % (17/29). In 21 % (6/29) of patients, additional balloon PTA was required to achieve adequate vessel revascularization. Consequently, the secondary technical success rate was 79 % (23/29). These rates are similar to those reported by Vorwerk et al. and Schleder et al. Vorwerk et al. needed to perform rotational thrombectomy with PAT in 16 % (10/62) of patients with vessel occlusion below the knee joint level and achieved a secondary success rate of 93 % [12]. Schleder et al. performed PAT with additional treatment to restore adequate vessel patency in 32 % of patients (15/47 patients, PTA and/or stenting) and achieved a secondary technical success rate of 96 % [7].

In this study, 81 % (22/27) of patients did not require further intervention or bypass surgery within the first 30 days after intervention. Despite successful revascularization with PAT, 18.5 %



► **Fig. 1** Digital subtraction angiography (DSA) images of an 80-year-old woman with peripheral artery disease (Rutherford Category 4). **A** Initial DSA image showing long-segment occlusion of the superficial femoral artery (SFA) and P1 segment of the popliteal artery (arrows), which is being passed with a 0.89 mm guide wire (arrowhead). **B** Preintervention DSA image of arteries below the knee joint level showing the anterior tibial artery (arrows) and tibioperoneal trunk (arrowheads) without therapeutically relevant stenosis. **C** DSA image obtained after balloon angioplasty showing good revascularization of the SFA and P1 segment of the popliteal artery (arrows) without relevant residual stenosis. Arrowheads: 0.89 mm guide wire. **D** DSA image of vessels below the knee joint level indicates acute thromboembolic occlusion (arrowhead) of the anterior tibial artery (arrows). Manual percutaneous aspiration thrombectomy (PAT) was performed using a diagnostic 5-French catheter. **E** DSA image obtained after PAT showing sufficient revascularization of the anterior tibial artery (arrows).

► **Abb. 1** . Digitale Subtraktionsangiografie (DSA) einer 80-jährigen Frau mit peripherer arterieller Verschlusskrankheit (Rutherford-Kategorie 4). **A** Die initiale DSA zeigt einen längerstreckigen Verschluss der A. femoralis superficialis (AFS) sowie des P1-Segments der A. poplitea (Pfeile), der mittels eines 0,89-mm-Führungsdrahts passiert wurde (Pfeilspitze). **B** Die präinterventionelle DSA der Arterien kaudal des Kniegelenks zeigt eine weitgehend regelrechte Kontrastierung der A. tibialis anterior (ATA) (Pfeile) sowie des Tractus tibiofibularis (Pfeilspitzen) ohne H.a. behandlungsbedürftige Stenosen. **C** Die DSA nach Ballon-PTA zeigt eine gute Revaskularisation der AFS und des P1-Segments der A. poplitea (Pfeile) ohne H.a. relevante Stenose. Pfeilspitzen: 0,89-mm-Führungsdraht. **D** Die DSA der Gefäße kaudal des Kniegelenks zeigt eine akute thromboembolische Okklusion (Pfeilspitze) der ATA (Pfeile). Mittels eines 5-French-Katheters wurde eine manuelle perkutane Aspirationsthorbektomie (PAT) durchgeführt. **E** Die DSA nach der PAT zeigt eine suffiziente Revaskularisation der ATA (Pfeile).

(5/27) of patients who achieved technical success required partial minor amputations (forefoot or toe) during the 30-day postintervention period owing to preexisting tissue damage (Rutherford Category 5).

Catheter-directed thrombolysis with recombinant tissue plasminogen activator could be an effective alternative or complementary treatment option for arterial thromboembolism following infrainguinal PTA. A recent study reported a technical success rate of 80.2 % (601/749) for intraarterial thrombolysis for treating lower limb ischemia. However, 30.3 % (227/749) of patients had bleeding, 13.9 % (104/749) had bleeding requiring transfusion, and 0.4 % (3/749) had intracranial bleeding with a fatal outcome [13]. Moreover, patients need to be admitted to the intensive care unit (ICU) following catheter-directed thrombolysis. Due to the possibility of major complications and potentially fatal sequelae following intraarterial thrombolysis and the necessity of patient monitoring in the ICU, PAT should be considered as the

preferred treatment for acute peripheral thromboembolic complications following infrainguinal PTA. Additionally, PAT can be performed simultaneously with PTA without the need for relocation or additional vascular access. Furthermore, PAT is minimally invasive, has a low cost, and enables the achievement of quick revascularization results and high technical success rates [7, 12]. Finally, previous reports of cumulative primary patency rates of 68 % and 58 % at one and four years, respectively, and limb salvage rates of 88 % and 86 % at one and four years, respectively [14], further establish PAT as the method of choice for treating acute thromboembolic arterial vessel occlusion.

Limitations of the current study are its retrospective design, the relatively small study population, and missing direct comparison with catheter-directed lysis.

## Conclusion

In conclusion, manual PAT, with PTA if needed, should be the first-choice treatment for acute thromboembolic complications of the infrainguinal arteries following infrainguinal PTA because of its high technical efficacy and the satisfactory clinical outcomes associated with it. Moreover, it can be performed simultaneously with PTA without the need for relocation, transportation of the patient, or additional vascular access, and – in contrast to intraarterial thrombolysis – there is no additional risk of complications such as bleeding.

### CLINICAL RELEVANCE OF THE STUDY

- Manual PAT should be considered as the first-choice treatment for acute peripheral thromboembolic complications following infrainguinal PTA because it is minimally invasive, cheap, and – in contrast to catheter-directed thrombolysis – carries no risk of bleeding.
- The success rate of manual PAT can be increased by performing additional PTA.
- Manual PAT makes it possible to achieve quick revascularization and high technical success rates.

## Conflict of Interest

The authors declare that they have no conflict of interest.

## References

- [1] Spiliopoulos S, Katsanos K, Fragkos G et al. Treatment of infrainguinal thromboembolic complications during peripheral endovascular procedures with AngioJet rheolytic thrombectomy, intraoperative thrombolysis, and selective stenting. *Journal of vascular surgery* 2012; 56: 1308–1316
- [2] Karnabatidis D, Katsanos K, Kagadis GC et al. Distal embolism during percutaneous revascularization of infra-aortic arterial occlusive disease: an underestimated phenomenon. *Journal of endovascular therapy: an official journal of the International Society of Endovascular Specialists* 2006; 13: 269–280
- [3] Tsetis D, Uberoi R. Quality improvement guidelines for endovascular treatment of iliac artery occlusive disease. *Cardiovascular and interventional radiology* 2008; 31: 238–245
- [4] Gardiner JrGA, Meyerovitz MF, Stokes KR et al. Complications of transluminal angioplasty. *Radiology* 1986; 159: 201–208
- [5] Sniderman KW, Bodner L, Saddekni S et al. Percutaneous embolectomy by transcatheter aspiration. Work in progress. *Radiology* 1984; 150: 357–361
- [6] Fogarty TJ, Cranley JJ, Krause RJ et al. A method for extraction of arterial emboli and thrombi. *Surgery, gynecology & obstetrics* 1963; 116: 241–244
- [7] Schleder S, Diekmann M, Manke C et al. Percutaneous aspiration thrombectomy for the treatment of arterial thromboembolic occlusions following percutaneous transluminal angioplasty. *Cardiovascular and interventional radiology* 2015; 38: 60–64
- [8] Starck EE, Wagner HJ. Rotations-Aspirations-Thromboembolktomie. *Deutsche medizinische Wochenschrift* (1946) 1991; 116: 1–6
- [9] Rastan A, Sixt S, Schwarzwälder U et al. Initial experience with directed laser atherectomy using the CLiRpath photoablation atherectomy system and bias sheath in superficial femoral artery lesions. *Journal of endovascular therapy: an official journal of the International Society of Endovascular Specialists* 2007; 14: 365–373
- [10] Starck EE, McDermott JC, Crummy AB et al. Percutaneous aspiration thromboembolctomy. *Radiology* 1985; 156: 61–66
- [11] Wagner HJ, Starck EE. Acute embolic occlusions of the infrainguinal arteries: percutaneous aspiration embolectomy in 102 patients. *Radiology* 1992; 182: 403–407
- [12] Vorwerk D, Triebe S, Ziegler S et al. Percutaneous Mechanical Thromboembolctomy in Acute Lower Limb Ischemia. *Cardiovascular and interventional radiology* 2019; 42: 178–185
- [13] Grip O, Kuoppala M, Acosta S et al. Outcome and complications after intra-arterial thrombolysis for lower limb ischaemia with or without continuous heparin infusion. *The British journal of surgery* 2014; 101: 1105–1112
- [14] Wagner HJ, Starck EE, Reuter P. Long-term results of percutaneous aspiration embolectomy. *Cardiovascular and interventional radiology* 1994; 17: 241–246