





# Peroral endoscopic myotomy for management of cricopharyngeal bars (CP-POEM): a retrospective evaluation

## Authors

Sarah S. Al Ghamdi<sup>\*,1,2</sup> , Michael Bejjani<sup>\*,1</sup>, Oscar V. Hernández Mondragón<sup>3</sup>, Nasim Parsa<sup>4</sup> , Muhammad N. Yousaf<sup>5</sup> , Mohammad Aghaie Meybodi<sup>1</sup>, Bachir Ghandour<sup>1</sup> , Chonlada Krustri<sup>6</sup>, Chainarong Phalanusitthepha<sup>6</sup>, Saowanee Ngamruengphong<sup>1</sup>, Jose M. Nieto<sup>7</sup>, Mouen A. Khashab<sup>1</sup>

## Institutions

- 1 Division of Gastroenterology and Hepatology, Johns Hopkins Hospital, Baltimore, Maryland, United States
- 2 Division of Gastroenterology and Hepatology, Department of Medicine, King Abdulaziz University, Jeddah, Saudi Arabia
- 3 Division of Endoscopy, Specialties Hospital, National Medical Center Century XXI, Mexico City, Mexico
- 4 University of Missouri Health System, Columbia, Missouri, United States
- 5 Medstar Union Memorial Hospital, Baltimore, Maryland, United States
- 6 Department of Surgery, Mahidol University, Bangkok, Thailand
- 7 Borland Groover Clinic Advanced Therapeutic Endoscopy Center and Baptist Medical Center, Jacksonville, Florida, United States

submitted 19.3.2021

accepted after revision 23.7.2021

published online 28.10.2021

## Bibliography

Endoscopy 2022; 54: 498–502

DOI 10.1055/a-1646-1151

ISSN 0013-726X

© 2021. Thieme. All rights reserved.

Georg Thieme Verlag KG, Rüdigerstraße 14, 70469 Stuttgart, Germany



Fig. 1 s, Table 1 s

Supplementary material is available under

<https://doi.org/10.1055/a-1646-1151>

## Corresponding author

Mouen A. Khashab, MD, Division of Gastroenterology and Hepatology, Johns Hopkins Hospital, 1800 Orleans Street, Sheikh Zayed Tower, Baltimore, MD 21287, United States  
mkhasha1@jhmi.edu

## ABSTRACT

**Background** Cricopharyngeal bars (CPBs) are a unique etiology of oropharyngeal dysphagia. Symptomatic patients are managed with endoscopic dilation or surgical myotomy. Cricopharyngeal peroral endoscopic myotomy (CP-POEM) is an emerging technique for the management of dysphagia due to CPBs. This study evaluated technical success, clinical success, adverse events, and long-term recurrence following CP-POEM.

**Methods** Consecutive patients who underwent POEM for management of CPBs between May 2015 and December 2020 at four tertiary care centers were included. Primary outcome was clinical success (defined as improvement of dysphagia score to  $\leq 1$ ). Secondary outcomes were technical success, rate and severity of adverse events, procedure duration, and symptom recurrence.

**Results** 27 patients (mean age 69 years; 10 female) underwent CP-POEM during the study period. The most common presenting symptoms at the time of index procedure were dysphagia (26; 96.3%) and regurgitation (20; 74.1%). Clinical and technical success were achieved in all patients. Mild/moderate adverse events occurred in two patients (7.4%). CP-POEM significantly reduced the median dysphagia score.

**Conclusions** CP-POEM was a safe and effective treatment for symptomatic CPBs. Although symptom recurrence was low, long-term outcome data are needed. CP-POEM should be considered as a management option for symptomatic CPBs at centers with POEM expertise.

## Introduction

Cricopharyngeal bars (CPBs) are a unique etiology of oropharyngeal dysphagia resulting from fibrous replacement of the cricopharyngeal muscle (CPM) due to acid reflux or me-

chanical injury. The CPM is a major component of the upper esophageal sphincter (UES). Located in the transition zone between the pharynx and esophagus, the CPM is distinct from the surrounding pharyngeal and esophageal muscles. It plays a vital role in the swallowing mechanism and protects from the risk of aspiration into the respiratory tract. Fibrotic thickening

\* Co-first authors.

of the CPM seen in CPBs may cause dysphagia due to reduced passive compliance of the UES [1]. Although symptoms are rare overall, the most common are dysphagia, regurgitation, and less frequently, aspiration pneumonia, all of which mimic the manifestations of Zenker's diverticulum [2]. CPBs are more frequently associated with dysphagia when there is prominent obstruction in the setting of a narrowed lumen due to small UES diameter, when a Zenker's diverticulum is present, or when the patient has associated pharyngeal weakness or neuromuscular dysfunction.

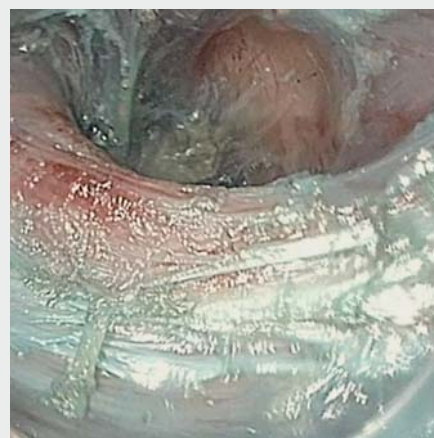Endoscopic evaluation of dysphagia due to CPBs may be challenging owing to the difficulty in identifying the CPM. Barium swallow study is most commonly used for initial evaluation of CPBs, with findings of posterior esophageal wall indentation on lateral view. High resolution manometry is not essential for diagnosis but may show an increase in intrabolus pressure that represents the resistance to flow across the UES [2].

While no therapy is required in asymptomatic patients, symptomatic patients are managed with botulinum toxin injection (BTI) [3], endoscopic dilation [4], or endoscopic or open neck surgical myotomy of the CPM. BTI and dilation have been found to be only temporarily effective, necessitating repeated procedures. Surgical myotomy is preferred in patients with no contraindications and has been found to be effective in relieving UES pressure [5]. Endoscopic laser cricopharyngeal myotomy is relatively safe and effective compared with traditional open myotomy. Despite the benefits of endoscopic laser cricopharyngeal myotomy over open surgery, concern remains over the possibility of post-procedure pharyngo-esophageal perforation and mediastinitis [6]. Amidst the rapid evolution of third space endoscopy over the past decade, cricopharyngeal peroral endoscopic myotomy (CP-POEM) has emerged as a novel technique in the management of dysphagia due to CPBs [7–9]. As no observational studies have assessed the outcomes of CP-POEM, this study aimed to assess the clinical and technical outcomes of patients undergoing CP-POEM for CPBs.

## Methods

This multicenter, international, retrospective cohort study involved four centers: one in Mexico, one in Thailand, and two in the USA. The study was approved by individual participating institutional review boards. Consecutive patients who underwent CP-POEM for symptomatic CPB between May 2015 and December 2020 were included. CPB was diagnosed on barium esophagram. Patients with a concomitant Zenker's diverticulum or other possible causes of dysphagia were excluded.

Dysphagia score was quantified according to the Dakkak and Bennett score (0, no dysphagia; 1, dysphagia to solids; 2, dysphagia to semisolids; 3, dysphagia to liquids; 4, complete dysphagia) [10]. Patient dysphagia scores were collected during clinical follow-ups, phone calls, and/or chart reviews. Patients were identified using center-specific endoscopic or billing databases. Electronic records were reviewed to capture the following variables: demographics, dysphagia score, additional symptoms (aspiration, choking, halitosis, regurgitation, weight loss, and others), imaging findings, prior surgical or endoscopic in-



**Video 1** Peroral endoscopic myotomy of a symptomatic cricopharyngeal bar in a 64-year-old patient..

Online content viewable at:  
<https://doi.org/10.1055/a-1646-1151>

terventions, procedure time, clinical success, technical success, type of anesthesia, length of hospital stay, symptom recurrence at follow-up, adverse events with severity graded according to the American Society for Gastrointestinal Endoscopy (ASGE) lexicon [11], and duration of follow-up. The authors acknowledge that one patient from this study has been included in a video case report publication [7]; no other cases from this study cohort have been published.

## Procedure techniques

CP-POEM was performed under general anesthesia using a flexible endoscope fitted with a soft, clear, straight plastic cap (e.g. 12.4 mm × 4 mm Olympus distal attachment cap, Model No. D-201–11804; Olympus, Southborough, Massachusetts, USA; or equivalent) (► **Video 1**). Submucosal injection of a viscous solution mixed with methylene blue was performed (see **Fig. 1 sa** in the online-only supplementary material). A 1.5–2-cm mucosal incision was then made either over or proximal to the CPM prominence to expose the submucosal space, using EndoCut Q current (ERBE USA; Marietta, Georgia, USA) (**Fig. 1 sb**). The gastroscope was advanced into the submucosal space and submucosal tunneling commenced distally (**Fig. 1 sc**) to identify the fibers of the thickened CPM (**Fig. 1 sd**). Tunneling was performed using spray coagulation current (Effect 3, 40W), with fluid expansion of the submucosal space by pumping a mixture of saline and indigo carmine or methylene blue solution. Once the CPM fibers were identified, the tunnel was expanded distally by 2 cm. A full-thickness myotomy was performed (**Fig. 1 se**), starting distally to the CPM and then extending proximally to include the CPM. Closure of the submucosal entry site was achieved using endoclips, in a distal to proximal fashion (**Fig. 1 sf**). All procedures were performed by endoscopists with prior experience in third space endoscopy, specifically with POEM procedures.

## Outcomes

The primary outcome was clinical success (defined as improvement of dysphagia score to  $\leq 1$  or complete resolution of other symptoms if dysphagia score was  $\leq 1$  at baseline). Patients who did not achieve clinical success at first follow-up were considered to have “clinical failure.” Patients who achieved clinical success at the initial follow-up visit but recurrence of symptoms at later visits were classified as having “clinical recurrence.” Secondary outcomes included technical success (defined as successful completion of all procedural steps), rate of adverse events (severity graded as per ASGE lexicon [11]), total procedure duration, and symptom recurrence during follow-up.

## Statistical analysis

The Fisher's exact test or chi-squared test for categorical variables was used to analyze the clinical outcomes and adverse event rates. Continuous variables were reported as mean with standard deviation (SD) or median with interquartile range (IQR), where appropriate, and compared by unpaired student's *t* test. The dysphagia score was analyzed as a continuous variable. Statistical significance of  $P < 0.05$  was adopted for all inferential testing. Analysis was performed using SPSS software version 16.0 (SPSS, Chicago, Illinois, USA).

## Results

A total of 27 patients (mean age 69.6 [SD 10.6] years; 10 female) underwent CP-POEM during the study period (► **Table 1**). The most common presenting symptoms at the time of the index procedure were dysphagia ( $n = 26$ , 96.3%) and regurgitation ( $n = 20$ , 74.1%). Six patients had undergone previous CPB treatment (three surgical myotomy, two endoscopic dilation, one BTI). Mean ASA score was 2.6 (SD 0.8). Eight patients were on antiplatelet therapy prior to the procedure (seven aspirin, one clopidogrel).

All patients underwent CP-POEM while under general anesthesia (► **Table 1**). The site of mucosal incision was proximal to the CPM in 17 patients (63.0%) and over the CPM in 10 patients (37.0%). All patients underwent full-thickness myotomy. The mean total procedure time was 45.6 (SD 21.5) minutes (► **Table 2**). Procedure time was similar between those patients with and those without prior treatment (47.2 [SD 16.3] minutes vs. 45.2 [SD 23] minutes, respectively;  $P = 0.81$ ). The mean number of clips used for mucosal closure was 5.2 (SD 1.2). All patients received pre- and post-procedure antibiotics. Post-procedure, the mean length of hospital stay was 2.6 (SD 2.1) days. The most common knife used was an insulated tip knife (Olympus), in 13 (48.2%). Further knives are detailed in **Table 1 s**.

## Primary outcomes

Clinical success was achieved in 100% of patients, with improvement of dysphagia score to  $\leq 1$  in 24 patients and complete resolution of other symptoms (regurgitation, choking, and aspiration) in 3 patients whose dysphagia score was  $\leq 1$  at baseline. CP-POEM significantly reduced the median dysphagia score of patients by 2 (from 3 to 1). During a median follow-up

► **Table 1** Baseline demographics.

	CP-POEM (n = 27)
Female sex, n (%)	10 (37.0)
Age, mean (SD), years	69.6 (10.6)
Symptoms, n (%)	
▪ Dysphagia	26 (96.3)
▪ Regurgitation	20 (74.1)
▪ Weight loss	10 (37.0)
▪ Aspiration	5 (18.5)
▪ Halitosis	4 (14.8)
▪ Choking	3 (11.1)
Dysphagia score, median (IQR)	3 (2–3)
CPB size, mean (SD), mm	18.2 (6)
ASA score, mean (SD)	2.6 (0.8)
Relevant medications, n (%)	
▪ Aspirin	7 (25.9)
▪ Clopidogrel*	1 (3.7)
▪ None	19 (70.4)
Anesthesia type, n (%)	
▪ General	27 (100)
Antibiotics, n (%)	
▪ Pre- and post-procedure	27 (100)
Prior CPB treatment, n (%)	
▪ Surgical myotomy	3 (11.1)
▪ Endoscopic dilation	2 (7.4)
▪ Botox injection	1 (3.7)
▪ POEM	0
▪ None	21 (77.8)

ASA, American Society of Anesthesiologists; CPB, cricopharyngeal bar; CP-POEM, cricopharyngeal peroral endoscopic myotomy; IQR, interquartile range; SD, standard deviation.

\* Paused for 7 days pre- and post-procedure.

of 42.3 months (IQR 14.6–69.4) (3.5 years), one patient developed recurrence of regurgitation without dysphagia, which occurred at 3 years post-procedure. This patient had undergone previous surgical myotomy 18 months prior to CP-POEM and significant fibrosis was encountered during the procedure. The patient's regurgitation was treated with dietary modification alone as symptoms were mild.

## Secondary outcomes

Technical success was achieved in 27 patients (100%). Adverse events occurred in two patients (7.4%), one of which was rated as mild and the other moderate. The first patient developed a mucosotomy during the procedure, which was managed with

► **Table 2** Primary and secondary outcomes.

	CP-POEM (n = 27)
Technical success, n (%)	27 (100)
Successful submucosal tunneling, n (%)	27 (100)
Total submucosal tunnel length, mean (SD), mm	32.7 (11.3)
Successful complete myotomy, n (%)	27 (100)
No. clips used for closure, mean (SD)	5.2 (1.2)
Total procedure duration, mean (SD), minutes	45.6 (21.5)
Length of hospital stay, mean (SD), days	2.6 (2.1)
Clinical success, n (%)	27 (100)
Resolution/improvement of symptoms*, n (%)	27 (100)
Symptom recurrence, n (%)	1 (3.7)
Foreign body sensation, n (%)	6 (22.2)
Intraprocedure adverse events, n (%)	
▪ Mucosotomy	1 (3.7)
▪ Bleeding	0
▪ Other	0
Post-procedure adverse events, n (%)	
▪ Leak	1 (3.7)
CP-POEM, cricopharyngeal peroral endoscopic myotomy; SD, standard deviation.	
* Dysphagia score 0 or 1.	

application of two endoclips. A repeat endoscopy was performed on Day 2 post-procedure and confirmed that the clips were in place. A barium swallow on Day 3 post-procedure showed no leak. This patient had undergone a surgical myotomy 18 months prior to the CP-POEM and significant fibrosis was encountered during the procedure. The second patient had a contained leak within the submucosal tunnel on the Day-1 barium swallow. An esophagogastroduodenoscopy was performed, which revealed dislodgment of one of the clips; the clip was replaced and no further issues arose. There were no other post-procedure adverse events, including infections, hematoma, or mediastinitis (► **Table 2**). Foreign body sensation occurred in six patients (22.2%); this was encountered immediately post-procedure and resolved during follow-up.

## Discussion

The treatment of CPBs is indicated in symptomatic patients in whom other causes of oropharyngeal dysphagia are ruled out. As previously mentioned, management consists of BTI [3], endoscopic dilation [4], endoscopic or open neck surgical myotomy of the CPM. CP-POEM is a novel technique in the management of dysphagia due to CPBs [7, 8]. To the authors' knowledge, no previous study has assessed the clinical and technical outcomes of patients undergoing CP-POEM for CPBs.

One retrospective review by Marston et al. compared the outcomes and complication rates of endoscopic CPB dilation with myotomy (transcervical or rigid endoscopic transoral carbon dioxide laser) in 23 patients with dysphagia due to a CPB [12]. Results showed a nonsignificant difference in swallow function at the initial follow-up following dilation and myotomy, but superior long-term outcomes in the myotomy patient cohort. A smaller study by Wang et al. reported that out of six patients who underwent dilation for CPB, all experienced initial symptomatic improvement, with 50% demonstrating sustained long-term benefit up to 27 months [4].

In the Marston et al. study comparing surgical myotomy with dilation, both procedures led to similar initial improvement in swallow function but dilation was more likely to provide temporary benefit [12]. Complications are rarely encountered following esophageal dilation [13,14]. Although myotomy is deemed to have an acceptable safety profile, complication rates are generally higher for myotomy than for dilation, with reports of 0–6.3% for rigid endoscopic cricopharyngeal myotomy [15–17] and 3.7%–15.8% for transcervical cricopharyngeal myotomy [18]. The most commonly reported complications were subcutaneous edema and local infections. Less frequent but more severe complications, such as cricopharyngeal fistula formation and mediastinitis, have also been reported. As such, dilation seems to have grown as a more desirable treatment modality for individuals with CPB, as most patients in this population are elderly with multiple medical comorbidities.

Our study shows similar efficacy results to surgical myotomy, with a clinical success rate of 100% and recurrence of regurgitation (without dysphagia) occurring in only one patient during a follow-up duration of 3.5 years. In our study, two mild adverse events occurred in two patients, both of which were managed endoscopically. There were no moderate or severe adverse events.

The retrospective observations made in this study carry some expected limitations. This was a multicenter study with potentially significant variability in techniques and follow-up protocols across multiple centers/providers. The sample size was also relatively small, which is due to both the infrequency of symptomatic CPBs as well as the novelty of performing CP-POEM. As with other types of POEM, we suspect that this technique will be increasingly adopted with time. In addition, this is the first study to formally assess CP-POEM. As with the evolution of Zenker's peroral endoscopic myotomy (Z-POEM) for the management of Zenker's diverticulum, CP-POEM appears to be promising as a novel treatment option for symptomatic CPBs.

In conclusion, this study suggests that CP-POEM is a safe and effective alternative treatment option for symptomatic CPBs. Symptom recurrence was found to be low, indicating excellent long-term results. Long-term outcomes compared with other treatment modalities should be further evaluated in prospective studies. CP-POEM should be considered as a management option in centers with expertise in POEM.

## Competing interests

Financial Disclosures: Mouen A. Khashab is a consultant for Boston Scientific, Olympus, Medtronic, GI Supply and Triton. Jose M. Nieto is a consultant for Boston Scientific and ERBE Saowanee Ngamruengphong is a consultant for Boston Scientific. All other others have nothing to disclose.

## References

- [1] et al. Principles of deglutition: a multidisciplinary text for swallowing and its disorders. Shaker R, Belafsky PC, Postma GN. New York: Springer; 2013: 1–1017
- [2] Kühn D, Miller S, Ptak M. Cricopharyngeal bar und dysphagie. *Laryngorhinootologie* 2013; 92: 230–233
- [3] Alberty J, Oelerich M, Ludwig K et al. Efficacy of botulinum toxin A for treatment of upper esophageal sphincter dysfunction. *Laryngoscope* 2000; 110: 1151–1156
- [4] Wang AY, Kadkade R, Kahrilas PJ et al. Effectiveness of esophageal dilation for symptomatic cricopharyngeal bar. *Gastrointest Endosc* 2005; 61: 148–152
- [5] Allen J, White CJ, Leonard R et al. Effect of cricopharyngeus muscle surgery on the pharynx. *Laryngoscope* 2010; 120: 1498–1503
- [6] Van Abel KM, Moore EJ, Kasperbauer JL et al. Functional outcomes and quality of life associated with cricopharyngeal myotomy for cricopharyngeal dysfunction: a prospective study. *Otolaryngol Neck Surg* 2014; 151: (Suppl. 01): P40
- [7] Al Ghamdi SS, Farha J, Runge TM et al. No pouch, no problem: successful endoscopic division of a symptomatic cricopharyngeal bar using a modified peroral endoscopic myotomy technique for Zenker's diverticulum. *VideoGIE* 2020; 5: 281–282
- [8] Elmunzer BJ, Moran RA. Peroral endoscopic myotomy for cricopharyngeal bar. *VideoGIE* 2020; 5: 378–379
- [9] Nieto J, Deshmukh AA, Elmeligui AM et al. S1864 Cricopharyngeal peroral myotomy (C-POEM) for treatment of a cricopharyngeal bar: a novel technique. *Am J Gastroenterol* 2020; 115: S965–S965
- [10] Dakkak M, Bennett JR. A new dysphagia score with objective validation. *J Clin Gastroenterol* 1992; 14: 99–100
- [11] Cotton PB, Eisen GM, Aabakken L et al. A lexicon for endoscopic adverse events: report of an ASGE workshop. *Gastrointest Endosc* 2010; 71: 446–454
- [12] Marston AP, Maldonado FJ, Ravi K et al. Treatment of oropharyngeal dysphagia secondary to idiopathic cricopharyngeal bar: surgical cricopharyngeal muscle myotomy versus dilation. *Am J Otolaryngol* 2016; 37: 507–512
- [13] Solt J, Bajor J, Moizis M et al. Primary cricopharyngeal dysfunction: treatment with balloon catheter dilatation. *Gastrointest Endosc* 2001; 54: 767–771
- [14] Clary MS, Daniero JJ, Keith SW et al. Efficacy of large-diameter dilatation in cricopharyngeal dysfunction. *Laryngoscope* 2011; 121: 2521–2525
- [15] Brøndbo K. Treatment of cricopharyngeal dysfunction by endoscopic laser myotomy. *Acta Otolaryngol Suppl* 2000; 543: 222–224
- [16] Pitman M, Weissbrod P. Endoscopic CO2 laser cricopharyngeal myotomy. *Laryngoscope* 2009; 119: 45–53
- [17] Herberhold C, Walther EK. Endoscopic laser myotomy in cricopharyngeal achalasia. *Adv Otorhinolaryngol* 1995; 49: 144–147
- [18] Brigand C, Ferraro P, Martin J et al. Risk factors in patients undergoing cricopharyngeal myotomy. *Br J Surg* 2007; 94: 978–983