

Microvascular Skin Manifestations Caused by COVID-19

Andrea Gawaz¹ Emmanuella Guenova²

¹Universitätshautklinik Tübingen, Tübingen, Germany

²Department of Dermatology, Lausanne University Hospital, Lausanne, Switzerland

Address for correspondence Andrea Gawaz, Dr. med, Universitätshautklinik Tübingen, Liebermeisterstr. 25, 72076 Tübingen, Germany (e-mail: andrea.gawaz@med.uni-tuebingen.de).

Hamostaseologie 2021;41:387–396.

Abstract

Hypercoagulability and vascular injury, which characterize morbidity in COVID-19 disease, are frequently observed in the skin. Several pathomechanisms, such as inflammation caused by angiotensin-converting enzyme 2–mediated uptake into endothelial cells or SARS-CoV-2-initiated host immune responses, contribute to microthrombus formation and the appearance of vascular skin lesions. Besides pathophysiologic mechanisms observed in the skin, this review describes the clinical appearance of cutaneous vascular lesions and their association with COVID-19 disease, including acroischemia, reticular lesions, and cutaneous small vessel vasculitis. Clinicians need to be aware that skin manifestations may be the only symptom in SARS-CoV-2 infection, and that inflammatory and thrombotic SARS-CoV-2-driven processes observed in multiple organs and tissues appear identically in the skin as well.

Keywords

- ▶ COVID-19
- ▶ skin manifestation
- ▶ microvascular

Introduction

In the past 20 years, coronavirus-related severe respiratory infections with high morbidity and mortality affected millions of people. SARS-CoV (severe acute respiratory syndrome coronavirus) in 2002/2003 and MERS-CoV (Middle East respiratory syndrome coronavirus) in 2012 caused two major disease outbreaks.¹ In 2019, the new SARS-CoV-2 spread in a pandemic outbreak resulting in 125,781,957 infected and 2,759,432 deceased individuals by March 2021.² SARS-CoV-2 is a member of the beta-subfamily of coronaviruses (*Coronaviridae*) and is an enveloped, single-stranded RNA virus covered with spike proteins.^{1,3}

Since November 2019, more than 120 million cases of SARS-CoV-2 infection worldwide have been reported. About 20 to 25% of patients with confirmed SARS-CoV-2 infection show cutaneous symptoms connected to microcirculation impairment or microvascular damage.^{4,5} Several mechanisms have been suggested in patients infected with SARS-CoV-2. The different pathomechanisms merge together into common pathways, the results of which can be directly observed on the skin.

The focus of this review is to summarize the effects of SARS-CoV-2 on cutaneous microvasculature and to describe clinical vascular pathologies seen in dermatologic patients with COVID-19 disease.

Pathomechanisms Observed in the Skin

Inflammation of Vessel Walls: Endothelial Damage Due to Viral Entry into Cells via ACE2

Several studies have shown that SARS-CoV-2 is able to enter host cells. The virus expresses a class I fusion protein on its envelope, known as the spike protein.⁶ The spike protein possesses a receptor-binding region to angiotensin-converting enzyme 2 (ACE2) receptor that is expressed on the cells' surface.^{7–9} Physiologically, ACE2 is part of the counterregulatory axis of the renin–angiotensin system (RAS) converting angiotensin II into a protective peptide, angiotensin 1-7 (Ang 1-7). Ang 1-7 binds to the Mas-receptor and antagonizes effects of angiotensin II. Thus, angiotensin 1-7 causes vasodilatation, reduces oxidative stress, and counteracts the

received

March 31, 2021

accepted after revision

August 9, 2021

© 2021. Thieme. All rights reserved.
Georg Thieme Verlag KG,
Rüdigerstraße 14,
70469 Stuttgart, Germany

DOI <https://doi.org/10.1055/a-1581-6899>.
ISSN 0720-9355.

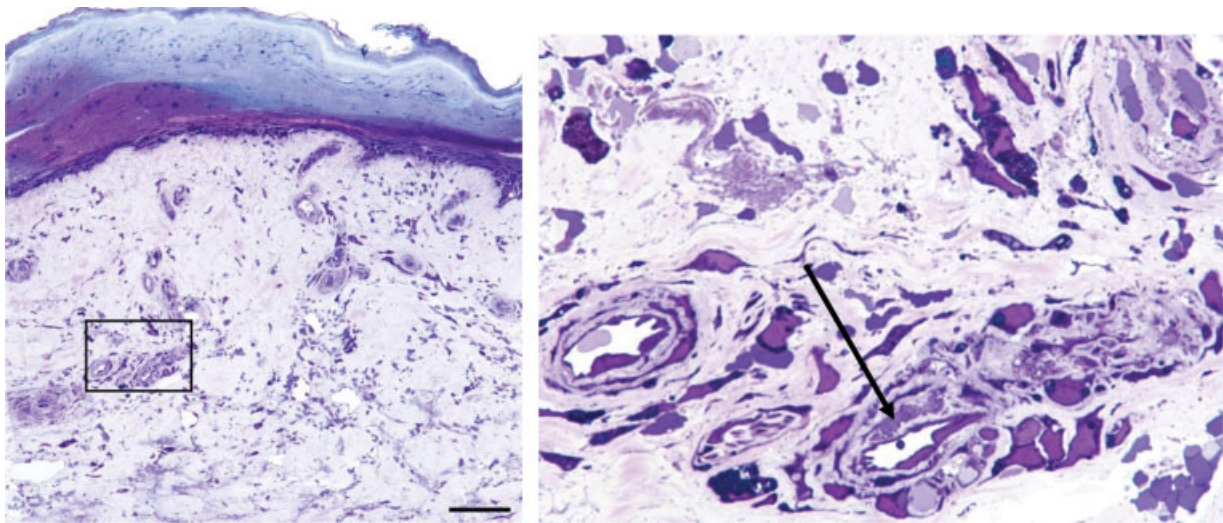


Fig. 1 Endotheliitis (arrow) in dermal vessels in a patient with COVID-19 (semi-thin sections of glutaraldehyde-fixed human skin biopsies, toluidine blue staining).

proinflammatory, prothrombotic, and profibrotic activity of angiotensin II.^{10,11}

In the skin, ACE2 is found in the basal cell layer of the epidermis, the endothelium of dermal arterioles and venules, in eccrine gland epithelial cells, and in subcutaneous fat tissue.^{12–14} Binding to ACE2 and priming by cofactor TMPRSS2 (transmembrane protease serine subtype 2) facilitates entry into the cell, followed by membrane fusion, internalization of the virus, and eventually cell death.^{6,15–18} Binding of SARS-CoV-2 to ACE2 subsequently leads to downregulation of ACE2 and reduces the protective effects of Ang 1-7, which changes the balance in the RAS toward oxidative stress, inflammation, and vasoconstriction.^{18–20} Furthermore, extensive production of inflammatory cytokines, adhesion molecules, and chemokines, in the context of SARS-CoV-2-driven cytokine storm, imposes local inflammatory cell infiltration, vascular leakage, and indirect endothelial inflammation on the one side.²¹ On the other side, endothelial inflammation caused directly by virus uptake into the cell and the following immune response (e.g., complement deposition) further promotes apoptosis, endothelial injury, and thrombus formation (–Fig. 1).^{8,10,22}

Of note, Magro et al²⁴ distinguished between the virus itself that is found in lung tissue in high copies and virus particles, called “pseudovirions,” that contain viral capsid proteins, but no RNA, and that circulate systemically to organs other than the lung, such as skin, brain, and liver, causing endothelial injury and production of cytokines.

Microthrombus Formation Due to High Cytokine Levels

Cytokines are a large group of secreted proteins important for cellular communication and guidance of the direction of the host immune responses. During inflammation, they are produced by immune cells (e.g., lymphocytes and macrophages) as well as by endothelial cells, stromal cells, and fibroblasts.^{25–27} In severe COVID-19 infection, high levels of

proinflammatory and prothrombotic cytokines are observed, in particular, interleukin-1 β , -6, -8, and tumor necrosis factor- α . Positive feedback mechanisms in combination with insufficient clearance of chemokines can result in a cytokine storm, a serious complication in SARS-CoV-2 infection with progressive thromboinflammatory response and hypercoagulability.^{8,17,18,28–30}

Especially type I interferons (IFN) play an important role in SARS-CoV-2 infection.³¹ In the early phase of inflammation, type I IFNs limit viral dissemination.³¹ However, prolonged and uncontrolled type I IFN signal results in abrogated immune response, ongoing inflammation, and poor clinical outcome.^{32–34} The pathophysiology of microangiopathy and thrombotic complications related to SARS-CoV-2 infection is not yet completely understood. Currently, both direct endothelial cell involvement and recruitment of innate and adaptive immune cells are focus of extensive research.³⁵ Especially of interest is the immune-mediated, type I IFN-driven endothelial dysfunction, resulting in endothelial cell apoptosis observed most commonly in the lung, and also in the skin.^{21,22}

Activation of the Complement System

The complement system is part of the innate immune system and involves more than 40 plasma proteins and proteases with major role in clearing damaged cells and eliminating pathogens from the organism.³⁶ Upon activation, an amplifying cascade of proteolytic cleavage results in proinflammatory reactions and phagocytosis of pathogens. Moreover, in the course of activation, the membrane attack complex formed by the proteins C5b, C6, C7, C8, and C9 causes disruption of the cell membrane with subsequent lysis and cell death.^{37,38} Both C5b-9 and C4d deposits have been shown in thrombotic microangiopathy earlier.³⁹ In COVID-19 pathology, several studies have described activation of the alternative and lectin complement pathway in the presence of SARS-CoV-2 envelope protein leading to microthrombotic vascular injury with deposition of C5b-9 and C4d

in both lesional and normal-appearing skin.^{10,12} Moreover, Magro et al¹⁰ demonstrated codeposition of the SARS-CoV-2 spike protein and the complement component C4d in dermal microvasculature.

Elevation of Antiphospholipid Antibodies

Antiphospholipid antibodies are autoantibodies directed against proteins that bind to phospholipids and are associated with arterial and venous thrombosis.⁴⁰ Zuo et al⁴¹ found that in 52% of patients hospitalized with COVID-19, several types of antiphospholipid antibodies were transiently elevated. Occurrence of antiphospholipid antibodies has been described by several authors and is assumed to contribute to microvascular pathology in COVID-19 infection, possibly aggravating thromboinflammatory events arising in severe disease.^{40,42–44}

COVID-19-Associated Coagulability

Hypercoagulability due to COVID-19 infection is characterized by elevated fibrinogen and D-dimer levels in connection with prolongation of prothrombin time (PT).^{45,46} Also, minor differences in platelet count are observed in up to 41% of patients infected with SARS-CoV-2.⁴⁷ Usually, these changes are mild, but several studies indicated that COVID-19 coagulopathy is related to the severity of the disease and elevated D-dimer levels have been shown to positively correlate with mortality in COVID-19-affected individuals.^{48–50}

Hypercoagulability is a pathomechanism observed in viral infections in general and associated with clearance of pathogens from the organism.^{38,50} It is currently assumed that SARS-CoV-2 is not directly procoagulant; more likely, hypercoagulability in COVID-19 infection is triggered by increased cytokine release and endothelial damage as described earlier.⁵¹ As a difference to disseminated intravascular coagulation (DIC), CAC is not associated with a clinical bleeding tendency and thrombocytopenia is mild.^{46,50,51}

Type III Hypersensitivity

Bacterial or viral pathogens, such as hepatitis or influenza virus, as well as medical drugs are common triggers of cutaneous small vessel vasculitis.⁵² Antigen-antibody immune complex aggregates are deposited in the vessel walls of postcapillary venules in the dermis with subsequent activation of the complement system causing inflammation with edema, purpura, and necrosis.^{53,54} Camprodon Gómez et al⁵³ confirmed the presence of viral SARS-CoV-2 RNA in the vessel endothelium in biopsies taken from the skin of patients presenting with vasculitis.

Clinical Presentations

Endotheliitis caused by SARS-CoV-2 and microthrombosis in the dermal vasculature lead to different skin lesions. Clinical appearance of these skin lesions can give an indication of the underlying pathology. Vascular skin lesions that can be observed in patients in association with COVID-19 infection are listed in [Table 1](#).

Acral Ischemia

The term “acral ischemia” summarizes a heterogeneous group of lesions on the digits and toes caused by acute vasomotoric or thrombotic interruption of the blood flow and subsequent ischemia.⁵⁵ Acral ischemia has been described in 1.2% of COVID-19 patients with a higher prevalence (23%) in critically ill patients.⁵⁶

The clinical patterns reported in acro-ischemia include Raynaud’s phenomenon, pernio-like lesions, reticular lesions including livedoid lesions and retiform purpura, as well as true acral ischemia with dry gangrene.⁵⁶

Acral Purpura (Pernio-Like Lesions)

Acral purpura describes a chilblain-like acral pattern of erythematous or violaceous skin lesions.⁵⁷ Due to inconsistent designations in various reports concerning SARS-CoV-2, it may be assumed that the terms “chilblain-like lesions,” “acral pernio,” “acral erythema,” and the colloquial “COVID toe” are used synonymously and refer to the same disease entity.

Patients commonly affected are adolescents and younger adults with no relevant medical history, which show mild to moderate symptoms of COVID-19 infection, and also in asymptomatic patients; in about 25%, chilblain-like lesions present the only symptom of COVID-19 infection.^{58–61} Lesions typically appear late in the course of disease (mean after 12.7 days), possibly indicating a delayed-type immunological reaction to the virus.^{58,62} Although the pathology of chilblain-like lesions is still unknown, histological changes suggest a lymphocytic vasculitis in the vessels of the dermis.^{63,64}

Symptoms reported include pruritic (30–39%) or tender (22–32%) violaceous macules and dusky, purpuric plaques, predominantly (85.7%) appearing on the distal part of the toes and in 7% affecting both toes and fingers.^{62,65,66} In more severe cases, digits appear edematous, sometimes presenting with superficial blistering and hemorrhagic crust without apparent ischemia or necrosis.⁶⁷ Moreover, history of cold exposure is usually lacking, as reported by Mawhirt et al.²³

Interestingly, SARS-CoV-2 polymerase chain reaction (PCR) test is frequently negative in nasopharyngeal and oropharyngeal swabs in patients with chilblain-like lesions.⁶⁸ In turn, SARS-CoV-2 spike protein was detected in biopsies of pernio-like lesions in vascular endothelial cells of the upper dermis and also in epithelial cells of eccrine glands.^{68–70}

It has been suggested that the mild course of the disease can be explained by a strong type I interferon reaction to the SARS-CoV-2 virus, an antiviral host response more often found in young, healthy patients that leads to accelerated virus elimination and abortive infection at an early stage.^{61,63,70–72} Older patients, in contrast, may have weaker or delayed type I interferon response that leads to subsequent cytokine release and increased morbidity and mortality.⁶³

“True” Acral Ischemia

While in some studies, the term “acral ischemia” is used to describe pernio-like lesions, true acral ischemia is caused by

Table 1 Overview of microvascular changes in the skin caused by SARS-CoV-2

	Etiology	Pathomechanism	Prevalence in cutaneous findings (%)	Clinical appearance	Histological findings	Typical age	Appearance	Severeness	References
Acro-ischemic lesions									
Pernio-like lesions (chilblain-like lesions, "Covid toe," acral erythema, acral purpura, pseudopernio)	Direct viral-induced endothelial damage, endotheliitis	Lymphocytic vasculitis followed by strong innate type I interferon response	19–63	Mainly toes (85.7%), violaceous or bluish maculae, with formation of bullae	Dermal lymphocytic infiltrate perivascular and periecrine with a prevalence of cytotoxic CD8 ⁺ lymphocytes, vacuolar degeneration of the basal epidermal layer	Adolescents and younger adults, mean age 44 y	Late	Mild to moderate, 25.4% asymptomatic	23, 61, 58, 63, 62, 56, 59, 60, 92
"True" acral ischemia (dry gangrene, acute limb ischemia, acral necrosis)	Arterial or venous occlusion	Likely a combination of arterial vasculitis and coagulopathy compromising perfusion to acres	1.20	Ischemia of fingers, toes, nose with livid erythema, dry gangrene		Older, mean age 70 y	Late	Critically ill	56:73,75–77
Reticular lesions									
Livedo reticularis	Vasomotoric	Inflammatory effect of SARS-CoV-2 on endothelial cells or smooth muscle cells that express ACE 2	2.3–4	Transient regular purple or bluish net-like pattern with complete rings and a pale center	Chronic inflammatory component. C4c deposition in the EBM and the endothelium of vessels			Mild to moderate	23,59,62,74,89
Livedo racemosa	Cutaneous microthrombosis	Partial occlusion of cutaneous blood vessels	Not known due to different denomination	Persistent livid-violaceous, irregular and discontinuous broken rings	Noninflammatory to pauci-inflammatory thrombi, complement including C5b-9 in skin biopsies	Older, mean 78 y	Late	More often in critically ill	56:61,62,70
Retiform purpura	Cutaneous microthrombosis	Full occlusion of cutaneous blood vessels by complement activation	7.1–8.2	Central necrotic area with variable surrounding erythema	Pauci-inflammatory vascular thrombosis with endothelial cell deposits of C5b-9 in the microvasculature	older, mean 78 y	Late	Severe and critically ill	56:62,70,87,95
Cutaneous small vessel vasculitis									
Small vessel vasculitis (non-IgA)	Type III hypersensitivity reaction (IgC, IgM)	Antigen-antibody complexes that target the vascular endothelium of the skin with immune complex deposition in postcapillary venules	1.8	Symmetrical palpable purpura, mostly in the lower legs, may be accompanied by systemic symptoms	Endothelial swelling, neutrophilic vessel wall infiltration with nuclear debris in vessel walls/scant leukocytoclasia, fibrin deposition in small- and medium-size dermal vessels with extravasation of erythrocytes. Microthrombi occluding dermal capillaries		Late onset (latent period 1–4 wk)	Mainly mild disease	53,92,99

Table 1 (Continued)

	Etiology	Pathomechanism	Prevalence in cutaneous findings (%)	Clinical appearance	Histological findings	Typical age	Appearance	Severity	References
IgA vasculitis (Schönlein–Henoch purpura)	Type III hypersensitivity reaction (IgA)	Immune complex deposits containing IgA in skin and organs	Reported casuistically	Palpable purpura symmetrically over all extremities, gluteal region, lower abdomen; accompanied by systemic symptoms; focal IgA nephropathy	Perivascular and vessel wall infiltration by neutrophils and lymphocytes, leukocytoclasia, and C3 and IgA deposits in dermal capillaries		Late, after latent period		101–104
Urticarial vasculitis	Type III hypersensitivity reaction (IgM, IgG)	Immune complex deposition and complement system activation	Reported casuistically	Urticarial lesions similar to wheals, but lasting more than 24h, may be accompanied by periorbital and acral edema	Dermal edema and evidence of leukocytoclastic vasculitis; sparse infiltrates, nuclear debris, or fibrin deposits		Latent period > 4 wk		105,106
Kawasaki-like disease (Kawa-COVID-19)	Probably postinfectious syndrome	Vasculitis of small- and medium-size arteries	Rare; more frequent occurrence since March 2020	Fever, conjunctivitis, abdominal pain, myocardial involvement; macular papular exanthema, mainly on the trunk, necrotizing vasculitis; coronary arteries often involved	Leukocytoclastic vasculitis with necrosis of the epidermis and most of the dermis with extravasation of erythrocytes and fibrin thrombi in the capillaries; infiltration of neutrophils with nuclear debris in vessel walls, and C3 and IgA deposition in a vascular pattern	Mainly children, but also reported in adults	Latent period of several weeks		30,54,92,109,110,113

complete interruption of blood flow causing ischemia with subsequent dry gangrene, which may result in loss of that limb. Several cases of acute limb ischemia have been reported in critically ill patients diagnosed with COVID-19,^{56,73–76} the extent of limb ischemia depending on the size of occluded vessel. Although the pathophysiology remains unclear, it has been assumed that a number of different factors, alone or in combination, may contribute to severe limb ischemia. Arterial and venous thromboembolism due to COVID-19-related coagulopathy with elevated D-dimer levels, possibly aggravated by the application of inotropic drugs used in critically ill patients, has been suggested in the pathogenesis of these lesions.^{43,73,77,78} Besides that, in several reports, venous gangrene following extensive venous thrombosis has been described.^{79–81} In some of the patients, concurrently elevated antiphospholipid antibodies have been detected, possibly contributing to thrombus formation.^{43,75,79} Therapeutic attempts with low-molecular-weight heparin have not always been successful in preventing complete limb ischemia.⁵⁶

Balestri et al⁸² reported a case of acral necrosis and dry gangrene 20 days after being tested negative again after COVID-19 infection, confirming the hypothesis formulated by Piccolo et al⁶⁶ about a delayed-type immune reaction caused by the virus. Moreover, they speculated that acral necrosis might be caused by the same delayed pathomechanism as are chilblain-like lesions, but with a weaker type I interferon response in elderly people, that may progress to “true” acral ischemia with dry gangrene.^{70,82}

Retiform Lesions

Livedo Reticularis

Livedoid lesions have been described in a number of dermatological conditions earlier.⁸³ Several studies report an incidence of livedoid lesions in 2.8 to 6.9% in COVID-19 patients with cutaneous manifestations.^{59,62,84–86} In some publications, the terms “livedo reticularis” and “livedo racemosa” are used synonymously. Nonetheless, it is necessary to differentiate these two entities due to their different pathophysiology.

Livedo Reticularis

Livedo reticularis, also called *cutis marmorata*, results from constriction of cutaneous central arterioles and slowed arteriolar blood flow with subsequent dilatation of venules in the skin and desaturation of the blood,^{87,88} thus forming a regular purple or bluish net-like pattern with complete rings and a pale center (–Fig. 2).^{87,89} It may be transient or persistent and may physiologically be found in children and young to middle-age women⁹⁰ as a result of vasoconstriction of cutaneous vessels (e.g., cold-induced).⁸⁷ In COVID-19, the transient livedo pattern has been associated with mild to moderate disease, and may be unilateral or symmetrical often leaving out the trunk.^{87,91} Coagulation parameters are usually normal which supports the theory of endotheliitis caused by direct viral uptake into endothelial cells and vascular smooth muscle cells leading to vasoconstriction.^{22,91,92}

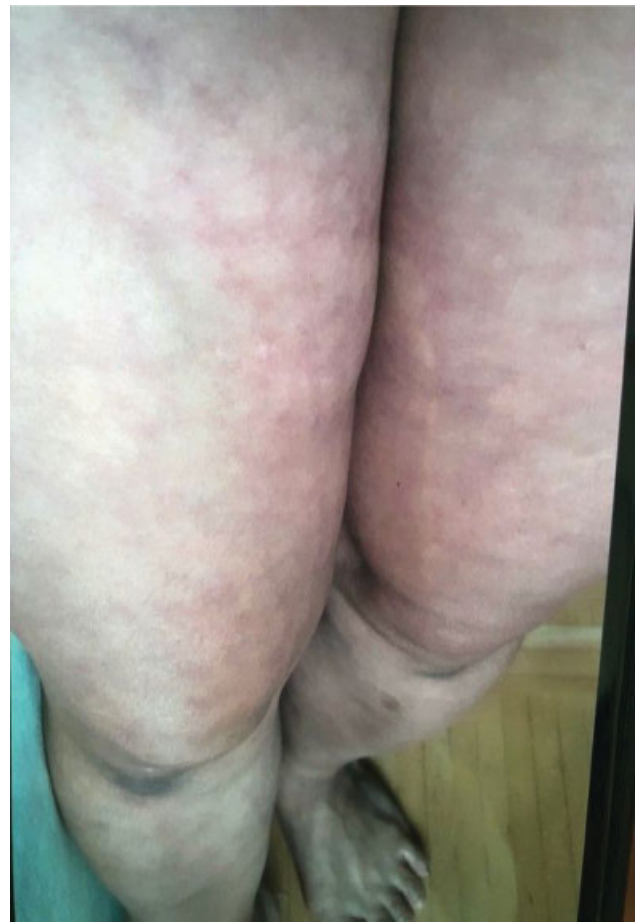

Fig. 2 Clinical image of livedo reticularis. Representative photograph of the lower extremities in a 49-year-old female patient. Livedo reticularis occurred 3 days after the patient developed respiratory symptoms. (Courtesy of Wolfram Hoetzenecker and Isabella Pospischil, Department of Dermatology, Kepler University Hospital, Johannes Kepler University, Linz, Austria).

Livedo Racemosa

Livedo racemosa, in contrast, is always pathologic, and more commonly associated with impairment of the blood flow.^{87,88} With occlusion of cutaneous arterioles and venules, it forms persistent livid-violaceous, irregular, and discontinuous broken rings, which are seen in a number of systemic vascular disorders such as livedoid vasculopathy or antiphospholipid syndrome.⁸⁷ In COVID-19, it is related to more severe disease and understood as a cutaneous manifestation of the procoagulant state.^{4,56} Unlike transient livedo reticularis, which is connected to mild to moderate disease and good clinical outcome, fixed livedo racemosa is more often found in older patients with more severe disease, unfavorable outcome, and high mortality up to 10%.^{10,61,62} Biopsy samples have revealed occlusive fibrin thrombi and significant microvascular deposition of complement (C4c, C4d, C5b-9) in the dermis.^{93,94} While in livedo reticularis, therapeutic options may include a wait-and-see strategy, in livedo racemosa, application of low-molecular-weight heparin in preventive dosing has been recommended.^{87,91}

Retiform Purpura

The term “retiform purpura” refers to stellate, violaceous lesions of the skin caused by a complete interruption of dermal and subcutaneous vessel blood flow.^{55,88} Purpuric lesions are more frequently found in elderly and critically ill patients, associated with the highest mortality rate in cutaneous lesions.^{62,70} Indeed, in contrast to the earlier-mentioned pernio-like lesions, patients with thrombotic retiform purpura show impaired interferon response to the virus.⁷⁰ Subsequently, extensive amounts of SARS-CoV-2 envelope and spike proteins were detected in the endothelium in thrombosed and normal-appearing dermal vasculature.⁷⁰

Clinical morphology of retiform purpura is painful purpuric, reticular patches with hemorrhagic bullae and crusts that transform into a necrotic area with variable surrounding erythema. It may be accompanied by nonblanching hemorrhage (purpura). The distribution of the lesions varies depending on the pathology and may be localized in acral or intertriginous areas or generalized.^{87,94}

The pathology of retiform purpura reflects microvascular deposition of complement components C3d, C4d, C5b-9, and MASP-2 with consecutive vessel wall damage.⁷⁰ This may be aggravated by microvascular occlusion phenomena (e.g., antiphospholipid antibody syndrome or thrombotic thrombocytopenic purpura as well as disseminated intravascular coagulation),⁸⁸ conditions that have been recognized in COVID-19 infection.^{96,97}

Vasculitis

Small Vessel Vasculitis

Cutaneous small vessel vasculitis is a type III hypersensitivity reaction of small vessels in the dermis. It can be idiopathic or caused by an excessive immune system response to pathogens or drugs, in malignancy or autoimmune disease.^{53,54} Deposition of IgM or IgG immunocomplex aggregates along postcapillary venule walls leads to the activation of the complement cascade causing inflammation with leakage.⁵² Clinical symptoms typically occur after a latent period of 1 to 4 weeks.^{52,98} The cardinal symptom is palpable purpura mainly concerning dependent areas of the body, notably the lower legs, but may also affect thighs, arms, and abdomen.^{99–101} In cases with high levels of inflammation, bullae and necrosis may develop in the purpuric skin lesions.⁹⁹ Skin symptoms may be accompanied by fever, fatigue, or arthralgia.⁵² Small vessel vasculitis has been described as a cutaneous manifestation in COVID-19.^{53,99,100} PCR of skin biopsies has been positive for SARS-CoV-2 virus as reported by previous studies,^{53,99,100} confirming the presence of SARS-CoV-2 RNA in vascular endothelium, which may be indicative of a causal relation in vasculitis.

IgA Vasculitis (Schonlein–Henoch Purpura)

Immunoglobulin A (IgA) vasculitis, a subtype of small vessel vasculitis that primarily affects children,¹⁰¹ is likewise due to type III hypersensitivity. Complexes of IgA and complement component C3 are deposited in arterioles, venules, and

capillaries in the skin and connective tissues, and also in other organs like the gastrointestinal tract and kidneys.^{102,103} Upper respiratory tract infection is commonly preceding the symptoms of vasculitis, which include palpable purpura, arthralgia, and abdominal pain.¹⁰⁴ In COVID-19, only a few cases of IgA vasculitis have been described affecting both children and adults.^{100,101,103,104} Allez et al¹⁰⁴ reported the case of a patient with IgA vasculitis COVID-19 serology was positive for IgA only.

Urticarial Vasculitis

Urticarial vasculitis, another subtype of small vessel vasculitis, presents clinically like acute urticaria with or without angioedema, but then shows a different course of the disease. While in allergic urticaria, lesions are typically volatile and transient, in urticarial vasculitis, the wheals typically persist stationary more than 24 hours. Histologically, changes are discreet with scanty focal, neutrophilic infiltrate, fibrin deposits, or nuclear debris and may show erythrocyte extravasation.¹⁰⁵ Urticarial vasculitis has been reported casuistically in COVID-19.^{105,106}

Kawasaki-Like Disease

Kawasaki-like disease is caused by inflammatory vascular disease of small- and medium-size arteries of unknown cause.¹⁰⁷ It is assumed that it can be triggered by pathogens, likely on the basis of genetic susceptibility.¹⁰⁸ Kaya et al³⁰ reported the presence of leukocytoclastic vasculitis in biopsies of patients with Kawasaki-like disease. Skin lesions, however, are unspecific and may present as maculopapular or polymorphic exanthema accompanied by mucocutaneous symptoms as well as palmar and plantar erythema.^{109,110} Although there are a few reports about Kawasaki-like disease in adults,^{111,112} it mainly occurs in children.¹¹³ Therefore, Kawasaki-like disease in COVID-19 infection has been termed “multisystem inflammatory syndrome in children” (MIS-C), or alternatively “pediatric inflammatory multisystem syndrome temporally associated with SARS-CoV-2 infection” (PIMS-TS).¹¹⁰ Diagnostic criteria include prolonged fever and multisystem organ involvement of more than two organ systems including cardiac, renal, neurological, hematological, respiratory, cutaneous, and gastrointestinal manifestations in combination with positive SARS-CoV-2 antigen test, PCR or serology, or COVID-19 exposure in the past 4 weeks.¹¹⁴ Verdoni et al¹¹⁰ reported an increase in monthly incidence of Kawasaki’s syndrome in spring 2020 that is 30 times higher than in the 5 years before. Though only few children were tested positive in SARS-CoV-2 PCR, seroconversion was observed in almost all cases, suggesting an association with COVID-19 infection. It has been proposed that Kawasaki-like disease caused by SARS-CoV-2 occurs due to STING pathway activation after binding to ACE2, which, after a latent period, would cause an excessive immune response.¹¹⁵

Conclusion

Systemic coagulopathy and vascular injury underlie morbidity due to COVID-19 infection.¹⁰ Vascular skin manifestations

in SARS-CoV-2 infection are manifold and may be the first clinical sign of underlying hypercoagulability and inflammation. In some patients, they may even be the only symptom in COVID-19 disease.⁵⁸ It is necessary that clinicians are aware of the different pathologies that demand for different therapeutic strategies. Moreover, it is necessary to be aware that pathologies directly observed and diagnosed in the skin are the same that occur in other organs, representing both inflammatory and thrombotic pathomechanisms.²⁴ By understanding the pathomechanisms in COVID-19 infection, therapies can be more specific in counteracting effects caused by SARS-CoV-2.

Conflict of Interest

The authors declare that they have no conflict of interest.

References

- Suhail S, Zajac J, Fossum C, et al. Role of oxidative stress on SARS-CoV (SARS) and SARS-CoV-2 (COVID-19) infection: a review. *Protein J* 2020;39(06):644–656
- Accessed September 26, 2021 at: <https://covid19.who.int>
- Velavan TP, Meyer CG. The COVID-19 epidemic. *Trop Med Int Health* 2020;25(03):278–280
- Conforti C, Dianzani C, Agozzino M, et al. Cutaneous manifestations in confirmed COVID-19 patients: a systematic review. *Biology (Basel)* 2020;9(12):449
- Unterluggauer L, Pospischil I, Krall C, et al. Cutaneous manifestations of SARS-CoV-2 - a two-center, prospective, case-controlled study. *J Am Acad Dermatol* 2021:S0190-9622(21)00619-8. Doi: 10.1016/j.jaad.2021.03.064
- Ou X, Liu Y, Lei X, et al. Characterization of spike glycoprotein of SARS-CoV-2 on virus entry and its immune cross-reactivity with SARS-CoV. *Nat Commun* 2020;11(01):1620
- Satarker S, Nampoothiri M. Structural proteins in severe acute respiratory syndrome coronavirus-2. *Arch Med Res* 2020;51(06):482–491
- Thomas C. Reply to: "A dermatologic manifestation of COVID-19: transient livedo reticularis". *J Am Acad Dermatol* 2020;83(02):e155–e156
- Li MY, Li L, Zhang Y, Wang XS. Expression of the SARS-CoV-2 cell receptor gene ACE2 in a wide variety of human tissues. *Infect Dis Poverty* 2020;9(01):45
- Magro C, Mulvey JJ, Berlin D, et al. Complement associated microvascular injury and thrombosis in the pathogenesis of severe COVID-19 infection: a report of five cases. *Transl Res* 2020;220:1–13
- Santos RA. Angiotensin-(1-7). *Hypertension* 2014;63(06):1138–1147
- Rotman JA, Dean KE, Magro C, Nuovo G, Bartolotta RJ. Concomitant calciphylaxis and COVID-19 associated thrombotic retiform purpura. *Skeletal Radiol* 2020;49(11):1879–1884
- Hamming I, Timens W, Bulthuis ML, Lely AT, Navis G, van Goor H. Tissue distribution of ACE2 protein, the functional receptor for SARS coronavirus. A first step in understanding SARS pathogenesis. *J Pathol* 2004;203(02):631–637
- Magro CM, Mulvey JJ, Laurence J, et al. Docked severe acute respiratory syndrome coronavirus 2 proteins within the cutaneous and subcutaneous microvasculature and their role in the pathogenesis of severe coronavirus disease 2019. *Hum Pathol* 2020;106:106–116
- Mousavizadeh L, Ghasemi S. Genotype and phenotype of COVID-19: their roles in pathogenesis. *J Microbiol Immunol Infect* 2020;S1684-1182(20)30082-7. Doi: 10.1016/j.jmii.2020.03.022
- Shang J, Wan Y, Luo C, et al. Cell entry mechanisms of SARS-CoV-2. *Proc Natl Acad Sci U S A* 2020;117(21):11727–11734
- Khadke S, Ahmed N, Ahmed N, et al. Harnessing the immune system to overcome cytokine storm and reduce viral load in COVID-19: a review of the phases of illness and therapeutic agents. *Virology* 2020;17(01):154
- Colantuoni A, Martini R, Caprari P, et al. COVID-19 sepsis and microcirculation dysfunction. *Front Physiol* 2020;11:747
- Gencer S, Lacy M, Atzler D, van der Vorst EPC, Döring Y, Weber C. Immunoinflammatory, thrombohaemostatic, and cardiovascular mechanisms in COVID-19. *Thromb Haemost* 2020;120(12):1629–1641
- Ferrario CM, Jessup J, Chappell MC, et al. Effect of angiotensin-converting enzyme inhibition and angiotensin II receptor blockers on cardiac angiotensin-converting enzyme 2. *Circulation* 2005;111(20):2605–2610
- Teuwen LA, Geldhof V, Pasut A, Carmeliet P. COVID-19: the vasculature unleashed. [published correction appears in *Nat Rev Immunol*. 2020 Jun 4] *Nat Rev Immunol* 2020;20(07):389–391
- Varga Z, Flammer AJ, Steiger P, et al. Endothelial cell infection and endotheliitis in COVID-19. *Lancet* 2020;395(10234):1417–1418
- Mawhirt SL, Frankel D, Diaz AM. Cutaneous manifestations in adult patients with COVID-19 and dermatologic conditions related to the COVID-19 pandemic in health care workers. *Curr Allergy Asthma Rep* 2020;20(12):75
- Magro CM, Mulvey J, Kubiak J, et al. Severe COVID-19: a multifaceted viral vasculopathy syndrome. *Ann Diagn Pathol* 2021;50:151645
- Ragab D, Salah Eldin H, Taeimah M, Khattab R, Salem R. The COVID-19 cytokine storm; what we know so far. *Front Immunol* 2020;11:1446
- Conti P, Caraffa A, Tetè G, et al. Mast cells activated by SARS-CoV-2 release histamine which increases IL-1 levels causing cytokine storm and inflammatory reaction in COVID-19. *J Biol Regul Homeost Agents* 2020;34(05):1629–1632
- West NR. Coordination of immune-stroma crosstalk by IL-6 family cytokines. *Front Immunol* 2019;10:1093
- Libby P, Lüscher T. COVID-19 is, in the end, an endothelial disease. *Eur Heart J* 2020;41(32):3038–3044
- Connors JM, Levy JH. Thromboinflammation and the hypercoagulability of COVID-19. *J Thromb Haemost* 2020;18(07):1559–1561
- Kaya G, Kaya A, Saurat JH. Clinical and histopathological features and potential pathological mechanisms of skin lesions in COVID-19: review of the literature. *Dermatopathology (Basel)* 2020;7(01):3–16
- Park A, Iwasaki A. Type I and Type III interferons - induction, signaling, evasion, and application to combat COVID-19. *Cell Host Microbe* 2020;27(06):870–878
- Lee JS, Shin EC. The type I interferon response in COVID-19: implications for treatment. *Nat Rev Immunol* 2020;20(10):585–586
- Hadjadj J, Yatim N, Barnabei L, et al. Impaired type I interferon activity and inflammatory responses in severe COVID-19 patients. *Science* 2020;369(6504):718–724
- Chua RL, Lukassen S, Trump S, et al. COVID-19 severity correlates with airway epithelium-immune cell interactions identified by single-cell analysis. *Nat Biotechnol* 2020;38(08):970–979
- Cameron MJ, Ran L, Xu L, et al; Canadian SARS Research Network. Interferon-mediated immunopathological events are associated with atypical innate and adaptive immune responses in patients with severe acute respiratory syndrome. *J Virol* 2007;81(16):8692–8706
- Stoermer KA, Morrison TE. Complement and viral pathogenesis. *Virology* 2011;411(02):362–373
- Ram Kumar Pandian S, Arunachalam S, Deepak V, Kunjiappan S, Sundar K. Targeting complement cascade: an alternative strategy for COVID-19. *J Biotech* 2020;10(11):479

- 38 Campbell CM, Kahwash R. Will complement inhibition be the new target in treating COVID-19 related systemic thrombosis? *Circulation* 2020;141(22):1739–1741
- 39 Chua JS, Baelde HJ, Zandbergen M, et al. Complement factor C4d is a common denominator in thrombotic microangiopathy. *J Am Soc Nephrol* 2015;26(09):2239–2247
- 40 Xiao M, Zhang Y, Zhang S, et al. Antiphospholipid antibodies in critically ill patients with COVID-19. *Arthritis Rheumatol* 2020;72(12):1998–2004
- 41 Zuo Y, Estes SK, Ali RA, et al. Prothrombotic autoantibodies in serum from patients hospitalized with COVID-19. *Sci Transl Med* 2020;12(570):eabd3876
- 42 Showers CR, Nuovo GJ, Lakhanpal A, et al. A COVID-19 patient with complement-mediated coagulopathy and severe thrombosis. *Pathobiology* 2021;88(01):28–36
- 43 Zhang Y, Xiao M, Zhang S, et al. Coagulopathy and antiphospholipid antibodies in patients with Covid-19. *N Engl J Med* 2020;382(17):e38
- 44 Bowles L, Platton S, Yartey N, et al. Lupus anticoagulant and abnormal coagulation tests in patients with Covid-19. *N Engl J Med* 2020;383(03):288–290
- 45 Chen N, Zhou M, Dong X, et al. Epidemiological and clinical characteristics of 99 cases of 2019 novel coronavirus pneumonia in Wuhan, China: a descriptive study. *Lancet* 2020;395(10223):507–513
- 46 Iba T, Levy JH, Levi M, Connors JM, Thachil J. Coagulopathy of coronavirus disease 2019. *Crit Care Med* 2020;48(09):1358–1364
- 47 Zhang Y, Zeng X, Jiao Y, et al. Mechanisms involved in the development of thrombocytopenia in patients with COVID-19. *Thromb Res* 2020;193:110–115
- 48 Zhou F, Yu T, Du R, et al. Clinical course and risk factors for mortality of adult inpatients with COVID-19 in Wuhan, China: a retrospective cohort study. *Lancet* 2020;395(10229):1054–1062
- 49 Zhang L, Yan X, Fan Q, et al. D-dimer levels on admission to predict in-hospital mortality in patients with Covid-19. *J Thromb Haemost* 2020;18(06):1324–1329
- 50 Zhang X, Yang X, Jiao H, Liu X. Coagulopathy in patients with COVID-19: a systematic review and meta-analysis. *Aging (Albany NY)* 2020;12(24):24535–24551
- 51 Connors JM, Levy JH. COVID-19 and its implications for thrombosis and anticoagulation. *Blood* 2020;135(23):2033–2040
- 52 Carlson JA. The histological assessment of cutaneous vasculitis. *Histopathology* 2010;56(01):3–23
- 53 Camprodon Gómez M, González-Cruz C, Ferrer B, Barberá MJ. Leucocytoclastic vasculitis in a patient with COVID-19 with positive SARS-CoV-2 PCR in skin biopsy. *BMJ Case Rep* 2020;13(10):e238039
- 54 Jennette JC, Falk RJ, Bacon PA, et al. 2012 revised International Chapel Hill Consensus Conference Nomenclature of Vasculitides. *Arthritis Rheum* 2013;65(01):1–11
- 55 Tan SW, Tam YC, Oh CC. Skin manifestations of COVID-19: a worldwide review. *JAAD Int* 2021;2:119–133
- 56 Alonso MN, Mata-Forte T, García-León N, et al. Incidence, characteristics, laboratory findings and outcomes in acro-ischemia in COVID-19 patients. *Vasc Health Risk Manag* 2020;16:467–478
- 57 Marzano AV, Cassano N, Genovese G, Moltrasio C, Vena GA. Cutaneous manifestations in patients with COVID-19: a preliminary review of an emerging issue. *Br J Dermatol* 2020;183(03):431–442
- 58 Andina D, Belloni-Fortina A, Bodemer C, et al. Skin manifestations of COVID-19 in children: Part 2. *Clin Exp Dermatol* 2021;46(03):451–461
- 59 Almeida G, Arruda S, Marques E, Michalany N, Sadick N. Presentation and management of cutaneous manifestations of COVID-19. *J Drugs Dermatol* 2021;20(01):76–83
- 60 Fernandez-Nieto D, Jimenez-Cauhe J, Suarez-Valle A, et al. Characterization of acute acral skin lesions in nonhospitalized patients: a case series of 132 patients during the COVID-19 outbreak. *J Am Acad Dermatol* 2020;83(01):e61–e63
- 61 Freeman EE, McMahon DE, Lipoff JB, et al; American Academy of Dermatology Ad Hoc Task Force on COVID-19. Pernio-like skin lesions associated with COVID-19: a case series of 318 patients from 8 countries. *J Am Acad Dermatol* 2020;83(02):486–492
- 62 Galván Casas C, Català A, Carretero Hernández G, et al. Classification of the cutaneous manifestations of COVID-19: a rapid prospective nationwide consensus study in Spain with 375 cases. *Br J Dermatol* 2020;183(01):71–77
- 63 Kolivras A, Dehavay F, Delplace D, et al. Coronavirus (COVID-19) infection-induced chilblains: a case report with histopathologic findings. *JAAD Case Rep* 2020;6(06):489–492
- 64 Novak N, Peng W, Naegeli MC, et al. SARS-CoV-2, COVID-19, skin and immunology - What do we know so far? *Allergy* 2021;76(03):698–713
- 65 Rosés-Gibert P, Gimeno Castillo J, Saenz Aguirre A, et al. Acral lesions in a pediatric population during the COVID-19 pandemic: a case series of 36 patients from a single hospital in Spain. *World J Pediatr* 2020;16(06):629–632
- 66 Piccolo V, Neri I, Filippeschi C, et al. Chilblain-like lesions during COVID-19 epidemic: a preliminary study on 63 patients. *J Eur Acad Dermatol Venereol* 2020;34(07):e291–e293
- 67 Cordero KM, Reynolds SD, Wattier R, McCalmont TH. Clustered cases of acral perniosis: clinical features, histopathology, and relationship to COVID-19. *Pediatr Dermatol* 2020;37(03):419–423
- 68 Colmenero I, Santonja C, Alonso-Riaño M, et al. SARS-CoV-2 endothelial infection causes COVID-19 chilblains: histopathological, immunohistochemical and ultrastructural study of seven paediatric cases. *Br J Dermatol* 2020;183(04):729–737
- 69 Gambichler T, Reuther J, Stücker M, et al. SARS-CoV-2 spike protein is present in both endothelial and eccrine cells of a chilblain-like skin lesion. *J Eur Acad Dermatol Venereol* 2021;35(03):e187–e189
- 70 Magro CM, Mulvey JJ, Laurence J, et al. The differing pathophysiologies that underlie COVID-19-associated perniosis and thrombotic retiform purpura: a case series. *Br J Dermatol* 2021;184(01):141–150
- 71 Roca-Ginés J, Torres-Navarro I, Sánchez-Arráez J, et al. Assessment of acute acral lesions in a case series of children and adolescents during the COVID-19 pandemic. *JAMA Dermatol* 2020;156(09):992–997
- 72 Damsky W, Peterson D, King B. When interferon tiptoes through COVID-19: Pernio-like lesions and their prognostic implications during SARS-CoV-2 infection. *J Am Acad Dermatol* 2020;83(03):e269–e270
- 73 Novara E, Molinaro E, Benedetti I, Bonometti R, Lauritano EC, Boverio R. Severe acute dried gangrene in COVID-19 infection: a case report. *Eur Rev Med Pharmacol Sci* 2020;24(10):5769–5771
- 74 Manalo IF, Smith MK, Cheeley J, Jacobs R. A dermatologic manifestation of COVID-19: transient livedo reticularis. *J Am Acad Dermatol* 2020;83(02):700
- 75 Ramachandran R, Vasudevan Pillai A, Raja S, Sailesh S. Axillary artery thrombosis resulting in upper limb amputation as a COVID-19 sequela. *BMJ Case Rep* 2021;14(01):e240981
- 76 Galanis N, Stavrika C, Agathangelidis F, Petsatodis E, Giankoulof C, Givissis P. Coagulopathy in COVID-19 infection: a case of acute upper limb ischemia. *J Surg Case Rep* 2020(6):rjaa204
- 77 Bellosta R, Luzzani L, Natalini G, et al. Acute limb ischemia in patients with COVID-19 pneumonia. *J Vasc Surg* 2020;72(06):1864–1872
- 78 Bikdeli B, Madhavan MV, Jimenez D, et al. COVID-19 and thrombotic or thromboembolic disease: implications for prevention, antithrombotic therapy, and follow-up: JACC state-of-the-art review. *J Am Coll Cardiol* 2020;75(23):2950–2973
- 79 Bamgboje A, Hong J, Mushiyevev S, Pekler G. A 61-year-old man with SARS-CoV-2 infection and venous thrombosis presenting

- with painful swelling and gangrene of the lower limb consistent with phlegmasia cerulea dolens. *Am J Case Rep* 2020;21:e928342
- 80 Adekiigbe R, Ugbo F, Seoparson S, Katriyar N, Fetterman A. A 47-year-old Hispanic man who developed cutaneous vasculitic lesions and gangrene of the toes following admission to hospital with COVID-19 pneumonia. *Am J Case Rep* 2020;21:e926886
 - 81 Visveswaran GK, Morparia K, Narang S, et al. SARS-CoV-2 infection and thrombosis: phlegmasia cerulea dolens presenting with venous gangrene in a child. *J Pediatr* 2020;226:281–284
 - 82 Balestri R, Termine S, Rech G, Girardelli CR. Late onset of acral necrosis after SARS-CoV-2 infection resolution. *J Eur Acad Dermatol Venereol* 2020;34(09):e448–e449
 - 83 Sajjan VV, Lunge S, Swamy MB, Pandit AM. Livedo reticularis: a review of the literature. *Indian Dermatol Online J* 2015;6(05):315–321
 - 84 Sachdeva M, Gianotti R, Shah M, et al. Cutaneous manifestations of COVID-19: report of three cases and a review of literature. *J Dermatol Sci* 2020;98(02):75–81
 - 85 Jindal R, Chauhan P. Cutaneous manifestations of coronavirus disease 2019 in 458 confirmed cases: a systematic review. *J Family Med Prim Care* 2020;9(09):4563–4569
 - 86 Giavedoni P, Podlipnik S, Pericàs JM, et al. Skin manifestations in COVID-19: prevalence and relationship with disease severity. *J Clin Med* 2020;9(10):3261
 - 87 Genovese G, Moltrasio C, Berti E, Marzano AV. Skin manifestations associated with COVID-19: current knowledge and future perspectives. *Dermatology* 2021;237(01):1–12
 - 88 Wysong A, Venkatesan P. An approach to the patient with retiform purpura. *Dermatol Ther (Heidelb)* 2011;24(02):151–172
 - 89 Verheyden M, Grosber M, Gutermuth J, Velkeniers B. Relapsing symmetric livedo reticularis in a patient with COVID-19 infection. *J Eur Acad Dermatol Venereol* 2020;34(11):e684–e686
 - 90 Cappel JA, Wetter DA. Clinical characteristics, etiologic associations, laboratory findings, treatment, and proposal of diagnostic criteria of pernio (chilblains) in a series of 104 patients at Mayo Clinic, 2000 to 2011. *Mayo Clin Proc* 2014;89(02):207–215
 - 91 Khalil S, Hinds BR, Manalo IF, Vargas IM, Mallela S, Jacobs R. Livedo reticularis as a presenting sign of severe acute respiratory syndrome coronavirus 2 infection. *JAAD Case Rep* 2020;6(09):871–874
 - 92 Becker RC. COVID-19-associated vasculitis and vasculopathy. *J Thromb Thrombolysis* 2020;50(03):499–511
 - 93 Occidental M, Flaifel A, Lin LH, Guzzetta M, Thomas K, Jour G. Investigating the spectrum of dermatologic manifestations in COVID-19 infection in severely ill patients: a series of four cases. *J Cutan Pathol* 2021;48(01):110–115
 - 94 García-Gil MF, García García M, Monte Serrano J, Prieto-Torres L, Ara-Martín M. Acral purpuric lesions (erythema multiforme type) associated with thrombotic vasculopathy in a child during the COVID-19 pandemic. *J Eur Acad Dermatol Venereol* 2020;34(09):e443–e445
 - 95 Bosch-Amate X, Giavedoni P, Podlipnik S, et al. Retiform purpura as a dermatological sign of coronavirus disease 2019 (COVID-19) coagulopathy. *J Eur Acad Dermatol Venereol* 2020;34(10):e548–e549
 - 96 Zhang Y, Cao W, Xiao M, et al. Clinical and coagulation characteristics of 7 patients with critical COVID-2019 pneumonia and acro-ischemia [in Chinese]. *Zhonghua Xue Ye Xue Za Zhi* 2020;41(0):E006
 - 97 Tehrani HA, Darnahal M, Vaezi M, Haghighi S. COVID-19 associated thrombotic thrombocytopenic purpura (TTP): a case series and mini-review. *Int Immunopharmacol* 2021;93:107397
 - 98 Mayor-Ibarguren A, Feito-Rodriguez M, Quintana Castanedo L, Ruiz-Bravo E, Montero Vega D, Herranz-Pinto P. Cutaneous small vessel vasculitis secondary to COVID-19 infection: a case report. *J Eur Acad Dermatol Venereol* 2020;34(10):e541–e542
 - 99 Gouveia PADC, Cipriano IC, de Melo MAZ, et al. Exuberant bullous vasculitis associated with SARS-CoV-2 infection. *IDCases* 2021;23:e01047
 - 100 Jamiolkowski D, Mühleisen B, Müller S, Navarini AA, Tzankov A, Roeder E. SARS-CoV-2 PCR testing of skin for COVID-19 diagnostics: a case report. *Lancet* 2020;396(10251):598–599
 - 101 AlGhoozi DA, AlKhayat HM. A child with Henoch-Schönlein purpura secondary to a COVID-19 infection. *BMJ Case Rep* 2021;14(01):e239910
 - 102 Sandhu S, Chand S, Bhatnagar A, et al. Possible association between IgA vasculitis and COVID-19. *Dermatol Ther (Heidelb)* 2021;34(01):e14551
 - 103 Suso AS, Mon C, Oñate Alonso I, et al. IgA vasculitis with nephritis (Henoch-Schönlein purpura) in a COVID-19 patient. *Kidney Int Rep* 2020;5(11):2074–2078
 - 104 Allez M, Denis B, Bouaziz JD, et al. COVID-19-related IgA vasculitis. *Arthritis Rheumatol* 2020;72(11):1952–1953
 - 105 Nasiri S, Dadkhahfar S, Abasifar H, Mortazavi N, Gheisari M. Urticarial vasculitis in a COVID-19 recovered patient. *Int J Dermatol* 2020;59(10):1285–1286
 - 106 de Perosanz-Lobo D, Fernandez-Nieto D, Burgos-Blasco P, et al. Urticarial vasculitis in COVID-19 infection: a vasculopathy-related symptom? *J Eur Acad Dermatol Venereol* 2020;34(10):e566–e568
 - 107 Jindal AK, Paliana RK, Prithvi A, Guleria S, Singh S. Kawasaki disease: characteristics, diagnosis, and unusual presentations. *Expert Rev Clin Immunol* 2019;15(10):1089–1104
 - 108 Ebina-Shibuya R, Namkoong H, Shibuya Y, Horita N. Multisystem inflammatory syndrome in children (MIS-C) with COVID-19: insights from simultaneous familial Kawasaki disease cases. *Int J Infect Dis* 2020;97:371–373
 - 109 Burgi Vieira C, Ferreira AT, Botelho Cardoso F, Pelicano Paulos J, Germano N. Kawasaki-like syndrome as an emerging complication of SARS-CoV-2 infection in young adults. *Eur J Case Rep Intern Med* 2020;7(10):001886
 - 110 Verdoni L, Mazza A, Gervasoni A, et al. An outbreak of severe Kawasaki-like disease at the Italian epicentre of the SARS-CoV-2 epidemic: an observational cohort study. *Lancet* 2020;395(10239):1771–1778
 - 111 Sokolovsky S, Soni P, Hoffman T, Kahn P, Scheers-Masters J. COVID-19 associated Kawasaki-like multisystem inflammatory disease in an adult. *Am J Emerg Med* 2021;39:253.e1–253.e2
 - 112 Shaigany S, Gnirke M, Guttmann A, et al. An adult with Kawasaki-like multisystem inflammatory syndrome associated with COVID-19. *Lancet* 2020;396(10246):e8–e10
 - 113 Kabeerdoss J, Paliana RK, Karkhele R, Kumar TS, Danda D, Singh S. Severe COVID-19, multisystem inflammatory syndrome in children, and Kawasaki disease: immunological mechanisms, clinical manifestations and management. *Rheumatol Int* 2021;41(01):19–32
 - 114 CDC Health Alert Network. Multisystem Inflammatory Syndrome in Children (MIS-C) Associated with Coronavirus Disease 2019. Accessed September 26, 2021 at: <https://emergency.cdc.gov/han/2020/han00432.asp>
 - 115 Wen W, Su W, Tang H, et al. Immune cell profiling of COVID-19 patients in the recovery stage by single-cell sequencing [published correction appears in *Cell Discov*. 2020 Jun 20;6:41]. *Cell Discov* 2020;6:31. Published 2020 May 4. Doi: 10.1038/s41421-020-0168-9