

The EFSUMB Guidelines and Recommendations for Musculoskeletal Ultrasound – Part I: Extraarticular Pathologies

Die EFSUMB-Leitlinien und -Empfehlungen für den muskuloskelettalen Ultraschall. Teil I: Extraartikuläre Pathologien

Authors

Daniela Fodor¹, Sebastián C Rodriguez-Garcia², Vito Cantisani³, Hilde B. Hammer⁴, Wolfgang Hartung⁵, Andrea Klauer⁶, Carlo Martinoli^{7, 8}, Lene Terslev⁹, Fernando Alfageme¹⁰, David Bong¹¹, Angel Bueno¹², Paz Collado¹³, Maria Antonietta D'Agostino¹⁴, Javier de la Fuente¹⁵, Gabriella Iohom¹⁶, Jens Kessler¹⁷, Manuela Lenghel¹⁸, Clara Malattia¹⁹, Peter Mandl²⁰, Dolores Mendoza-Cembranos²¹, Mihaela Micu²², Ingrid Möller¹¹, Aurelie Najm²³, Levent Özçakar²⁴, Riccardo Picasso^{7, 8}, Athena Plagou²⁵, Xavier Sala-Blanch²⁶, Luca Maria Sconfienza^{27, 28}, Oana Serban¹, Paolo Simoni²⁹, Iwona Sudoł-Szopińska³⁰, Christian Tesch³¹, Plamen Todorov³², Jacqueline Uson³³, Violeta Vlad³⁴, Federico Zaottini^{7, 8}, Diana Bilous¹, Roxana Gutiu¹, Michael Pelea¹, Anamaria Marian¹, Esperanza Naredo³⁵

Affiliations

- 1 2nd Internal Medicine Department, "Iuliu Hatieganu" University of Medicine and Pharmacy, Cluj-Napoca, Romania
- 2 Rheumatology Department, La Princesa University Hospital, Princesa Health Research Institute, Madrid, Spain
- 3 Department of Radiological, Oncological and Anatomopathological Sciences, "Sapienza" University, Rome, Italy
- 4 Department of Rheumatology, Diakonhjemmet Hospital and Faculty of Medicine, University of Oslo, Oslo, Norway
- 5 Clinic for Rheumatology and Clinical Immunology, Asklepios Clinic, Bad Abbach, Germany
- 6 Department of Radiology, Medical University Innsbruck, Section Head Rheumatology and Sports Imaging, Innsbruck, Austria
- 7 Department of Health Science – DISSAL, University of Genova, Italy
- 8 UO Radiologia, IRCCS Policlinico San Martino, Genova, Italy
- 9 Copenhagen Center for Arthritis Research, Center for Rheumatology and Spine Diseases, Rigshospitalet, Glostrup, Denmark; Department of Clinical Medicine, University of Copenhagen, Copenhagen, Denmark
- 10 Dermatology Department, Hospital Universitario Puerta de Hierro Majadahonda, Madrid, Spain
- 11 Instituto Poal de Reumatologia Barcelona, EULAR Working Group Anatomy for the Image, University of Barcelona, International University of Catalunya, Spain
- 12 Department of Musculoskeletal Radiology, Hospital Universitario Fundación Alcorcón, Madrid, Spain
- 13 Rheumatology Department, Transitional Care Clinic, Hospital Universitario Severo Ochoa, Madrid, Spain
- 14 Istituto di Reumatologia Università Cattolica del Sacro Cuore, UOC Reumatologia, Fondazione Policlinico Universitario Agostino Gemelli, IRCCS, Rome, Italy
- 15 Orthopedic Department, Clinica Pakea de Mutua, San Sebastián, Spain
- 16 Department of Anaesthesiology and Intensive Care Medicine, Cork University Hospital and University College Cork, Cork, Ireland
- 17 Department of Anaesthesiology, Division of Pain Medicine, University Hospital Heidelberg, Heidelberg, Germany
- 18 Radiology Department, "Iuliu Hatieganu" University of Medicine and Pharmacy, Cluj-Napoca, Romania
- 19 UOC Clinica Pediatrica e Reumatologia, IRCCS Istituto Giannina Gaslini, Department of Neurosciences, Rehabilitation, Ophthalmology, Genetic and Maternal Infantile Sciences (DINOGLMI) University of Genoa, Genoa, Italy
- 20 Division of Rheumatology, Medical University of Vienna, Vienna, Austria
- 21 Department of Dermatology, Hospital Universitario Fundación Jiménez Díaz, Madrid, Spain
- 22 Rheumatology Division, 2nd Rehabilitation Department, Rehabilitation Clinical Hospital Cluj-Napoca, Romania
- 23 Institute of Infection, Immunity and Inflammation, College of Medical Veterinary and Life Sciences, University of Glasgow, Glasgow, United Kingdom
- 24 Department of Physical and Rehabilitation Medicine, Hacettepe University Medical School, Ankara, Turkey
- 25 Ultrasound Unit, Private Radiological Institution, Athens, Greece
- 26 Department of Anaesthesiology, Hospital Clinic, Department of Human Anatomy, Faculty of Medicine, University of Barcelona, Spain
- 27 IRCCS Istituto Ortopedico Galeazzi, Milano Italy
- 28 Department of Biomedical Sciences for Health, University of Milano, Milano, Italy
- 29 Paediatric Imaging Department, "Reine Fabiola" Children's University Hospital, Université Libre de Bruxelles, Brussels, Belgium
- 30 Department of Radiology, National Institute of Geriatrics, Rheumatology and Rehabilitation, Warsaw, Poland
- 31 Orthopedics and Trauma Surgery, Praxis, Hamburg, Germany

32 Department of Internal Disease Propaedeutic and Clinical Rheumatology, Medical University of Plovdiv, Plovdiv, Bulgaria

33 Department of Rheumatology Hospital Universitario Móstoles, Universidad Rey Juan Carlos, Madrid, Spain

34 Sf. Maria Hospital, Rheumatology Department, Bucharest, Romania

35 Department of Rheumatology, Bone and Joint Research Unit, Hospital Universitario Fundación Jiménez Díaz, IIS Fundación Jiménez Díaz, and Universidad Autónoma de Madrid, Madrid, Spain

Key words

ultrasound, musculoskeletal, EFSUMB, guidelines, recommendations

received 24.03.2021

accepted 08.07.2021

published online 03.09.2021

Bibliography

Ultraschall in Med 2022; 43: 34–57

DOI 10.1055/a-1562-1455

ISSN 0172-4614

© 2021. Thieme. All rights reserved.

Georg Thieme Verlag KG, Rüdigerstraße 14, 70469 Stuttgart, Germany


Correspondence

Prof. Daniela Fodor

2nd Internal Medicine, “Iuliu Hatieganu” University of Medicine and Pharmacy, 2–4 Clinicilor str, 35009 Cluj-Napoca, Romania

Tel.: +40/7 45/38 16 03

dfodor@umfcluj.ro

 Supplementary material is available under <https://doi.org/10.1055/a-1562-1455>

ABSTRACT

The first part of the guidelines and recommendations for musculoskeletal ultrasound, produced under the auspices of the European Federation of Societies for Ultrasound in Medicine and Biology (EFSUMB), provides information about the use of musculoskeletal ultrasound for assessing extraarticular structures (muscles, tendons, entheses, ligaments, bones, bursae, fasciae, nerves, skin, subcutaneous tissues, and nails) and their pathologies. Clinical applications, practical points, limitations, and artifacts are described and discussed for every structure. After an extensive literature review, the recommendations have been developed according to the Oxford Centre for Evidence-based Medicine and GRADE criteria and the consensus level was established through a Delphi process. The document is intended to guide clinical users in their daily practice.

ZUSAMMENFASSUNG

Der erste Teil der Leitlinien und Empfehlungen für den muskuloskelettalen Ultraschall, die unter der Schirmherrschaft der European Federation of Societies for Ultrasound in Medicine and Biology (EFSUMB) erstellt wurden, enthält Informationen über den Einsatz des muskuloskelettalen Ultraschalls zur Beurteilung von extraartikulären Strukturen (Muskeln, Sehnen, Gelenke, Bänder, Knochen, Schleimbeutel, Faszien, Nerven, Haut, subkutanes Gewebe und Nägel) und deren Pathologien. Für jede Struktur werden die klinische Anwendung, praktische Punkte, Einschränkungen und Artefakte beschrieben und diskutiert. Nach einer ausführlichen Literaturrecherche wurden die Empfehlungen gemäß den Kriterien des Oxford Centre for Evidence-based Medicine und den GRADE-Kriterien entwickelt, und der Konsensgrad wurde durch die Delphi-Methode ermittelt. Das Dokument ist als Leitfaden für klinische Anwender in der täglichen Praxis gedacht.

Introduction

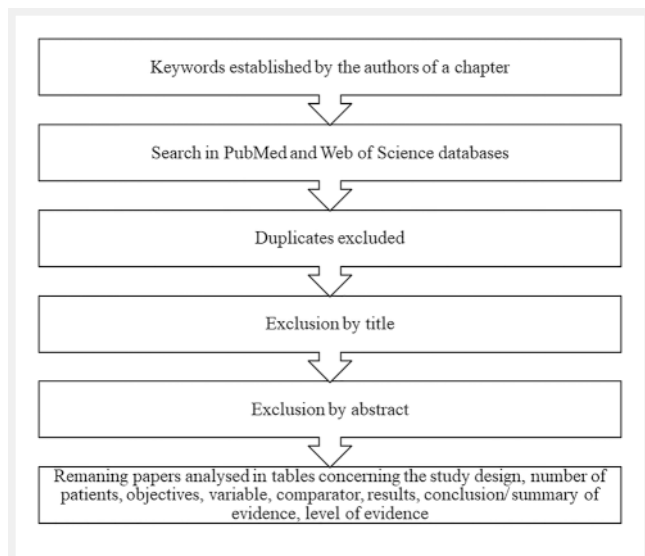
General considerations

Musculoskeletal ultrasound (MSUS) has become a routine imaging modality in clinical practice. Its use has increased substantially not only in radiology but also in rheumatology, orthopedics, physical medicine and rehabilitation, sports medicine, podiatry, neurology, anesthetics, and many others. Several professional societies have contributed over time to the standardization, implementation, and training in MSUS. In Europe, significant work has been carried out by the European League Against Rheumatism (EULAR), European Society of Musculoskeletal Radiology (ESSR), and European Federation of Societies for Ultrasound in Medicine and Biology (EFSUMB) [1–10].

Taking into consideration the huge number of MSUS indications and the multitude of users from a variety of medical special-

ties, the need for a multidisciplinary consensual position among MSUS experts has become evident. For this reason, under the umbrella of EFSUMB, a Steering Committee consisting of 8 international experts from 7 countries was created. The group identified the main topics that needed to be analyzed and invited other MSUS experts (rheumatologists, radiologists, orthopedic surgeons, physical and rehabilitation medicine doctors, pediatricians, dermatologists, anesthesiologists) in order to draw up valid recommendations. The authors group consists of 36 experts from 15 countries.

Based on an extensive literature review on the previously selected topics (► **Fig. 1**), the panel members produced a descriptive text on different aspects of clinical applications and a number of recommendations for each field. The level of evidence (LoE) was appraised using the Oxford Centre for Evidence-based Medicine (OCEMB) criteria [11]. The strength of the recommendation (SoR) was analyzed using the Grading of Recommendations



► **Fig. 1** The flowchart of the searching process used for every chapter of the musculoskeletal ultrasound recommendations.

Assessment, Development and Evaluation (GRADE approach) [12], and the consensus level between the task force members was established through a Delphi process following the EFSUMB policy document development strategy for Clinical Practice Guidelines [13].

Initially, 84 recommendations/statements were proposed. After the first round of voting, 2 recommendations were discarded and 75 were approved. After a second round of voting, an additional 7 recommendations were proposed and approved. In total, we produced 82 consensual recommendations. The results of the voting process are presented as follows: percent of participants who agree/disagree/abstain and the percentage of agreement. Consensus was considered strong when the percentage who voted in favor of a statement/recommendation was >95% and broad when the percentage was between 75–95% [13].

US techniques used in MSUS

The US techniques used in MSUS are detailed in ► **Supplementary Table 1**.

Training

There are many forms of MSUS training (mentorship, theoretical and practical courses, cadaver courses stressing sonoanatomy and procedural proficiency, E-learning, self-teaching, team-based learning) that vary between different professional societies and across Europe [14–16]. In 2008, EFSUMB published the minimum training requirements for the practice of MSUS, comprising 3 levels, with the need to acquire competency for each level [17]. Many MSUS courses endorsed by EFSUMB take place throughout Europe.

EULAR has organized dozens of MSUS courses and published guidelines for conducting these courses (basic, intermediate, and advanced levels) [18]. The minimum training requirements for rheumatologists performing MSUS were also published, and a 3-level competency assessment (COMPASS) was established [9]

and implemented [19]. Recommendations for Teaching the Teachers courses have been developed [20]. Important efforts have been made to standardize the MSUS examination and reporting [3, 21].

ESSR produced technical guidelines for the ultrasound examination of joints [22] and guidelines on clinical indications of MSUS [4, 6] and organized many courses accompanying their annual meetings [23].

Courses organized by national professional societies, including some with integrated competency assessment, deserve explicit acknowledgement, along with the general trend towards embedding MSUS into fellowship curricula of various specialties [24].

Terminology

► **Supplementary Table 2** provides the current US definitions of the main musculoskeletal structures and those of US pathologies [25–37].

Safety

Diagnostic US has been widely used in clinical medicine for many years with no proven deleterious effects [38], with possible biological effects of non-thermal origin being reported in animals [39] but none in humans. Contrast agents used for US are administered safely in several settings with minimal risk to patients. They are not excreted through the kidneys and hence can be safely administered to patients with renal impairment without risking contrast induced nephropathy or nephrogenic systemic fibrosis [40]. Based on the scientific evidence of US-induced biological effects to date, there is no reason to withhold diagnostic scanning during pregnancy, provided it is medically indicated and is used prudently by fully trained operators [41, 42].

In the last decade new imaging methods have been introduced, such as elastography, plane wave imaging, and vector Doppler. The EFSUMB Committee for Medical Ultrasound Safety (ECMUS) drew the following conclusions regarding the safety of elastography [43]: when acoustic radiation force impulses are used, significant temperature rises may occur, especially if bone lies in the beam; and when using ARFI, the temperature has its maximum at the focus, whereas in B-mode the maximum is close to the transducer.

Therefore, according to the ALARA (As Low As Reasonably Achievable) principle, diagnostic ultrasound can be considered safe [38] when the thermal and mechanical index values are as small as possible, while keeping the quality of the scan as high as possible [44].

Overarching principles

1. B-mode (grayscale), Doppler techniques, elastography and CEUS can be used for the musculoskeletal system examination. Broad consensus (27/3/6, 90%)
2. Appropriate knowledge and training are necessary for performing MSUS. Strong consensus (34/0/2, 100%)
3. The use of standardized US terminology is highly recommended. Strong consensus (34/0/2, 100%)

4. Although no side effects of grayscale and Doppler US are known, ALARA principles should be taken into consideration. Broad consensus (27/6/3, 81 %)

Extraarticular anatomical structures

Muscles

Background

The US appearance of skeletal muscles is determined by their histological structure, which consists of an alternance of hypoechoic bundles of myofibrils and hyperechoic intramuscular aponeuroses, septae, and fasciae. The blending of these fundamental components inside each muscle belly results in an inconsistent US appearance throughout the human body, as their relative quantity, respective relationship, and orientation change greatly depending on the particular specialized tasks of each muscle. Moreover, the US image of the same muscle is influenced by factors like sex, age, and fitness status [45, 46]. Thus, muscle appearance may be inconsistent among normal subjects. Finally, skeletal muscles are intrinsically highly anisotropic structures [47].

Clinical application

Intrinsic muscle injuries are most often caused by simultaneous contraction and elongation of the myofibrils and represent one of the more common indications for MSUS examinations. These injuries, which most commonly occur in muscles spanning two joints and in the proximity of the myotendinous junction [48, 49], are classified into four grades of severity [50]: Grade 0 when US is not able to detect any pathological finding in patients with local pain following an acute injury; Grade 1 lesions consist of minor destruction of the muscle fibers and may show subtle US alterations, such as intramuscular hypo- or hyperechoic areas or swollen aponeuroses; Grade 2 lesions are referred to as partial muscle tears and are caused by disruption of the muscle fibers and hematoma formation; Grade 3 lesions correspond to complete tears and are characterized by total discontinuity and retraction of the muscle belly. In Grade 0 and 1, dynamic evaluation may show hypomobility of muscle fibers. In Grade 2 and 3 lesions, US shows interruption and retraction of the muscle fibers, along with an intramuscular gap filled with blood. Torn muscle fragments may float inside the intramuscular collection, giving rise to the “clapper in bell sign” on US [51]. The role of US in patients with suspected muscle injury is to establish the extent of the damage and to rule out differential diagnoses, such as deep venous thrombosis [52]. Measurement of the cross-sectional area of muscle injuries has prognostic value, as it may predict time to recovery during rehabilitation [48]. Moreover, the time at which the hemorrhagic cavity is filled with hyperechoic connective tissue scar corresponding to the repair process can be considered safe for restarting low-level activity, in the absence of clinical symptoms [50]. However, US tends to underestimate the extent of muscle damage, especially when compared to magnetic resonance imaging (MRI) [48].

US may show the direct consequences of an extrinsic injury and it may detect local complications of muscle contusions, such as cysts, myositis ossificans, and, more rarely, calcific myonecrosis. Local swelling, focal irregularities/inhomogeneity of the muscle tissues, and partial or complete tears are the most common US findings in the context of contusion injuries. In the subacute/chronic setting, muscle hernia may develop if the external blow damaged the muscle fascia [52].

US commonly represents the imaging modality of choice for the initial evaluation of muscle masses, to confirm the presence of a mass and to gather information about its nature (solid or cystic), size, margins, compressibility, and vascularity [53–55]. US may establish the anatomical location and relationship with adjacent structures, detects signs of infiltration, and assists in imaging-guided sampling for histological evaluations. However, patients with a soft-tissue mass frequently need further evaluation with MRI [56, 57].

Recently, US has demonstrated its potential to quantify and qualify skeletal muscles in both young and old populations [58–61]. Several US parameters have proved reliable not only for the prediction of muscle strength and function, but also for the detection and monitoring of sarcopenia [62–69]. Muscle size, echogenicity, pennation angle, and vascularity appear most promising for this purpose [70, 71]. It is plausible that in the next few years US will be increasingly used for the diagnosis and follow up of sarcopenia [72].

US may assist with the diagnosis and characterization of disease activity in inflammatory myopathies (82.9% sensitivity for detecting histologically proven myositis) [73]. Inflammation and edema cause an increased echogenicity of muscles, which may also appear swollen. In chronic disease, the muscles appear atrophic with reduced volume and further increased echogenicity due to progressive infiltration of fatty tissue [74].

Practical points, limitations, and artifacts in muscle examination are detailed in ► **Supplementary Table 3, 4.**

Recommendations

1. In muscle injuries, US should be performed to confirm the lesion, define its anatomic location, and establish its extension (LoE 2, SoR strong). Broad consensus (31/2/3, 94 %)
2. US should be used to confirm the presence of a muscle mass and provide information about its structure (LoE 1, SoR strong). Strong consensus (33/0/3, 100 %)
3. US might play a role in diagnosis and the monitoring of disease activity in patients with suspected myositis (LoE 2, SoR strong). Broad consensus (26/7/3, 79 %).

Tendons

Background

Tendinopathy refers to persistent tendon pain and dysfunction related to mechanical loading. While several models of tendon pathology exist, the continuum model proposed by Cook et al. [75, 76] is widely used to clinically describe and diagnose tendinopathy. This model proposed three key stages of tendon pathology: reactive tendinopathy, tendon disrepair, and degenerative

tendinopathy. The staging of tendon pathology may be beneficial for clinicians to target treatment according to the tendon structure [77]. A clinical diagnosis of tendinopathy is primarily derived from the patient history and clinical tests. The latter have been shown to be sensitive for detecting tendinopathy, but they are not specific for identifying pathological changes when compared with imaging [78].

MSUS is the foremost imaging modality for tendon pathologies since it more sensitive than clinical examination and MRI for detecting pathological structural changes within tendons, but it does not always correlate with pain and dysfunction [79, 80]. Although reviews have demonstrated both an association and a dissociation between tendon structure, function, and pain, structural changes identified on US can be considered a risk factor for the development of symptomatic tendinopathy [81, 82]. Using Doppler US, neovascularization due to autoimmune inflammation, overuse, or trauma repair can be easily identified. Furthermore, nearly all tendons are readily accessible. The presence of blood vessels and accompanying nerves has previously been implicated as a source of pain, with moderate associations reported between the Doppler signal and the presence and location of pain [82, 83]. However, an increased Doppler signal is present in asymptomatic tendons, suggesting that blood vessels and accompanying nerves are not the primary source of pain. In addition, the reliability of detecting a Doppler signal is poor, as exercise has been shown to affect both intra- and peritendinous vascularity [84, 85].

In calcific tendinopathy, cartilaginous metaplasia spontaneously occurs, together with calcium deposition inside the tendon matrix [86, 87]. The pathogenesis is still unclear (may be related to reduced oxygen tension, which can promote spontaneous metaplasia and cellular necrosis, in turn associated with calcium deposition [88]). Calcifications may occur in all tendons [89, 90] although the rotator cuff tendons are most frequently affected [91].

Clinical applications

US is widely used to detect inflammation, traumatic lesions, and degenerative alterations in tendons. The US study of tendon ruptures allows confirmation of partial or complete ruptures at many anatomical sites [92–97]. The degree of tendon inflammation in rheumatic disease, namely tenosynovitis, paratenonitis, or tendinitis, as well as the extent of tendon damage can be evaluated [98, 99]. Several US scores have been introduced and validated with good intra- and interobserver reliability [100–102].

The most common parameters used to characterize tendon pathology include tendon thickness, echogenicity, vascularity [103], and stiffness [104]. Abnormal tenocyte morphology and changes in proteoglycan content with a resultant increase in bound water are the primary changes in tendinosis. These changes have been described on US as increases in tendon dimensions and heterogeneous or diffuse changes in echogenicity [105, 106]. Furthermore, the shadowing generated by fibrillar disorganization and the lack of parallel-aligned fibers contribute to areas of hypoechogenicity within the tendon matrix [78].

US is the most accurate imaging modality to detect calcific deposits (sensitivity of 94 %, specificity of 99 %) [107]. Calcific tendinopathy usually shows hyperechoic foci within the tendon, with or without acoustic shadowing. However, the appearance changes depending on calcium content, which varies according to the stage of this condition. Occasionally, calcifications may also appear as hypo/anechoic fluid collections with no acoustic shadowing [108, 109].

Practical points, limitations, and artifacts in tendon examination are detailed in ► **Supplementary Table 3, 4.**

Recommendations

1. In patients with suspected tendon pathology, US is recommended as the first imaging modality after clinical examination (LoE 1, SoR strong). Strong consensus (33/0/3, 100 %)
2. Color/power Doppler US should be used to evaluate active inflammation in tendons and tendon sheaths (LoE 1, SoR strong). Broad consensus (30/3/3, 91 %)

Enthesis

Background

Enthesis is the insertion of a tendon, ligament, or capsule into the bone. Entheses may be affected in inflammatory conditions grouped under the term spondyloarthritis (SpA), where enthesitis is considered a key feature. The enthesitis may also be the subject of overuse as seen in sport injuries and in crystal diseases. However, while the enthesitis is the origin of the disease in SpA (with potential subsequent involvement of the tendon), the overuse condition is perceived to be a tendon disease with potential subsequent involvement of the enthesitis.

The term “enthesitis” (i. e., inflammation of the enthesitis) should only be used in relation to SpA and the term “enthesopathy” for any pathological condition of the enthesitis regardless of cause. US provides a more sensitive assessment of entheses than clinical evaluation, comparable with MRI (except for locations not accessible to ultrasound, such as pelvis entheses, cruciate ligaments entheses, spinal, etc.) [110–119].

Clinical points

Definition

On grayscale US, pathological entheses are characterized by the loss of normal fibrillar echogenicity of the tendon insertion with or without an increase in tendon thickness, or intralesional focal changes at the tendon insertion, such as calcium deposits, fibrotic scars and bone or periosteal changes (erosions or new bone formation – enthesophytes). When using Doppler US, active inflammation is detected as abnormal vascularity in the area adjacent to the cortical insertion (<2 mm). Additionally, involvement of the body of the tendon far from the enthesitis, of adjacent bursae, and fat tissue may be observed. However, these processes can also be observed in the absence of enthesitis in other inflammatory and non-inflammatory diseases [28, 120].

Diagnosis

US may be used for the early diagnosis of enthesitis and especially the presence of Doppler activity has been shown to be a sensitive marker [121–136]. Several enthesitis scoring systems exist for distinguishing between SpA and other joint diseases but the only consensus-based scoring system is the OMERACT (Outcome Measures in Rheumatology) enthesitis scoring system [28, 120].

Monitoring

At the moment only the consensus-based OMERACT scoring system appears suitable for monitoring purposes [28, 120]. Large international, multi-center studies assessing validity and sensitivity to change are still lacking, thus hindering the routine use of such instruments in both clinical practice and clinical trials. Only a few studies have evaluated sensitivity to change over time or responsiveness of US in SpA patients under anti-TNF α treatment, where Doppler activity has been shown to be the most sensitive to change [122, 124, 125, 130, 137–153].

Differential diagnosis

Whether and to what extent US can distinguish between enthesitis of different origins including local non-inflammatory conditions needs to be established [144–153].

Practical points, limitations, and artifacts in entheses examination are detailed in ► **Supplementary Table 3, 4.**

Statements

1. Ultrasound might be more sensitive than clinical examination and MRI for detecting peripheral enthesitis accessible to US (LoE 4). Broad consensus (27/6/3, 82 %)
2. Ultrasound findings should be interpreted in the context of clinical and laboratory data for etiological diagnosis of peripheral enthesitis (LoE 4). Strong consensus second round (31/1/4, 97 %)

Recommendation

1. US should be used as the first-line imaging modality for peripheral enthesitis diagnosis (LoE 2, SoR strong). Strong consensus (33/0/3, 100 %)
2. Increased vascularity of enthesitis on Doppler US should be considered as the most diagnostic feature of enthesitis. (LoE 2, SoR strong). Broad consensus (28/2/6, 93 %)
3. Ultrasound may be used to monitor peripheral enthesitis (LoE 2, SoR strong). Broad consensus (30/2/4, 94 %)

Bursae

Background

Bursae, sac-like structures containing a small amount of synovial fluid, some communicating with the adjacent articular cavity, reduce the friction between soft tissues and bones [154–156]. Bursitis, inflammation of the bursa, appears in various pathological conditions: mechanical, degenerative, septic, inflammatory rheumatic diseases, tumors, etc. [157, 158]. The main US findings consist of an increased amount of synovial fluid (of variable echogenicity) with or without synovial hypertrophy, internal septation,

mural nodules or loose bodies, but generally no specific appearance can be linked to any particular etiology [154]. Distinguishing from normal bursae is important, as in many situations a small amount of intrabursal fluid can be detected by US in healthy subjects [156, 159].

Clinical application

In patients with shoulder pain, the presence of subacromial-subdeltoid (SASD) bursitis was associated with acromioclavicular joint arthritis (70.4 %), supraspinatus calcific tendinopathy (67.8 %), rotator cuff full-thickness (96.7 %) or partial (72.7 %) tear, trauma (95.6 %), rheumatoid arthritis (RA) (94.7 %), or infection (100 %), often independently from the underlying pathology [160]. US can accurately detect subacromial bursitis in patients with painful arc syndrome (100 % specificity, 87 % accuracy) [161].

The detection of SASD bursitis by US improves the specificity of clinical and serological criteria for the diagnosis of polymyalgia rheumatica (PMR) from 68 % to 89 % [162]. Bilateral SASD had a specificity of 89 % (95 %CI 66 % to 97 %) and a sensitivity of 66 % (43 % to 87 %) for the diagnosis of PMR [163] and US was confirmed to be a useful tool to improve the classification and management of patients with PMR [164]. Bursitis is more severe and of proliferative type in the shoulders of patients with elderly onset RA compared with the exudative type in PMR [165, 166]. The severity of tenosynovitis of the long head of the biceps and that of SASD bursitis are independent predictors of an inadequate response to glucocorticoid treatment in patients with PMR [167].

Subcoracoid bursae are rarely distended, generally in the presence of subcoracoid impingement [168, 169]. Bicipitoradial bursitis results more commonly from chronic mechanical friction and less commonly from inflammation, tumors, or infections [170]. Only case reports have been published about the bicipitoradial bursa [171, 172].

The most common etiology of olecranon bursitis is trauma and infection [173, 174]. Despite its superficiality, few reports about the US appearance of the olecranon bursae have been published [175, 176]. The olecranon bursa is very commonly involved in tophaceous gout [177, 178] and rarely in calcium pyrophosphate dihydrate crystal deposition disease [179].

Iliopsoas bursitis was identified by US in 2.2 % of patients with hip osteoarthritis (OA) [180] and in 5–6 % of patients with post-arthroplasty complications [181]. As compared to surgery, US had excellent results in evaluating the iliopsoas bursa wall thickness and internal texture but underestimated its size and the presence of communication with the joint [182]. US identified bursitis in 20.2 % of patients with great trochanteric pain syndrome [183]. Agreement with MRI was good to excellent [184, 185]. When compared to surgical findings, US had a sensitivity of 0.61, specificity of 1.0, positive predictive value of 1.0, and negative predictive value of 1.0 for diagnosing trochanteric bursa pathology [186]. However, US was unable to distinguish between bursitis in inflammatory diseases and bursitis with a mechanical origin [185].

US was able to identify bursitis in 9.5 % of patients with knee pain and, compared to MRI, had a sensitivity of 88.67 % and a specificity of 100 % with a kappa index of 0.92 [187]. In medial knee

pain, US could detect pes anserine bursitis in 20 % of patients, with the incidence increasing with patient age and grade of knee OA [188]. US was as specific, but less sensitive than knee arthrography and as accurate as MRI in detecting Baker cysts [189].

In the heel area, a significant increase in both retrocalcaneal bursa detection and its thickness were shown in SpA patients [190]. A positive likelihood ratio of 4.6% was found when a cut-off of >2 mm for retrocalcaneal bursa thickness was used. Of note, the retrocalcaneal bursa could be seen by US in 27.6% of healthy people [191] and in nearly 50% of military recruits [156]. In addition, retrocalcaneal bursitis was frequently observed in RA (in 24% of established and 38% of early RA patients) [165].

In the foot, US was able to identify forefoot bursae distention (intermetatarsal and plantar) with a high prevalence in both OA (94%) and RA (88%) compared to healthy subjects (56%) [191]. These bursae are often missed by clinical examination (US vs. clinical examination: 92.6% vs. 23.5% in RA) and their presence is associated with self-reported activity restrictions and foot impairment [192]. In patients with metatarsalgia, US detected intermetatarsal bursae distention as the most common underlying pathology (in 20.5% of cases, including in 21.5% of clinically suspected Morton neuromas) [193].

Practical points, limitations, and artifacts in bursae examination are detailed in ► **Supplementary Table 3, 4.**

Statement

1. US findings in bursitis are nonspecific and must be completed with clinical and laboratory data and fluid analysis (**LoE 3b**). Strong consensus (30/1/5, 96%)

Recommendation

1. US should be used as the first-line imaging method for diagnosing bursitis (**LoE 2b, SoR strong**). Strong consensus (31/1/4, 97%).

Ligaments and retinacula

Background

US and MRI are complementary tools for assessing intrinsic and extrinsic ligaments and for diagnosing ligament tears, pulleys, and retinacular lesions [194, 195] including lax, torn, thickened, or absorbed ligaments and non-union avulsion fractures [196, 197]. US has the potential to provide a novel approach to the rating and treating of ligament injuries [198].

Ligaments, pulleys, and retinacula are composed mostly of collagen and appear as less echogenic, fibrillar structures on US. Ligaments are best visualized under strain, highlighting the importance of dynamic examination. Point-of-care ankle US was shown to be as precise as MRI for detecting ligament and tendon injuries and may be used for immediate diagnosis and further preoperative imaging [199].

Clinical applications

Lateral collateral ankle ligament complex

Acute ankle sprains are the most common reason for visiting the doctor after sports-related incidents.

Compared with operative findings, the sensitivity, specificity, and accuracy of US were 98.9%, 96.2%, and 84.2%, respectively, for anterior talofibular ligament (ATFL) injury and 93.8%, 90.9%, and 83.3%, respectively, for calcaneofibular ligament (CFL) injury, comparable to MRI results [200, 201]. A systematic review with meta-analysis showed that the pooled sensitivities were 0.99 (0.96, 1.00) with specificities of 0.91 (0.82, 0.97) for diagnosing chronic ATFL injury and 0.94 (0.85, 0.98) with specificities of 0.91 (0.80, 0.97) for chronic CFL injury [202].

Medial collateral ankle ligament (deltoid) complex

In the case of disruption, comparison between US and stress radiography revealed high sensitivity and specificity, proving that US is an accurate method for identifying the involved ligament components dynamically [203]. Although US may provide important information about the spring ligament complex and the ankle syndesmosis, available evidence for their US assessment is scarce [204]. Thickness measurement in a weightbearing position has been recommended to assess the dorsal Lisfranc ligament [205, 206].

Knee

Anterolateral knee ligament injuries that occur with anterior cruciate ligament tears are often associated with bone avulsion at the enthesis and are better viewed with US [207–209].

Structural changes of the lateral and medial patellofemoral joint retinaculum were found to be associated with patellofemoral pain. High-frequency US and MRI showed similarly high accuracy in diagnosing medial patellofemoral joint retinaculum lesions, with very good interobserver agreement for high-frequency US [210, 211].

Two meta-analyses demonstrated high diagnostic performance in anterior and posterior cruciate ligament injuries. However, future prospective studies comparing US and MRI are warranted [212, 213].

Acromio-clavicular joint (ACJ)

The acromio-clavicular ligament, which is always damaged when the ACJ is injured, can be reliably examined by US. Both distortion and rupture can be recognized morphologically, while instabilities due to a height difference between the clavicle and acromion edge or due to hypermobility, should be assessed in a dynamic examination. Two studies demonstrated the diagnostic value of US in comparison to X-ray imaging [214, 215]. Direct visualization of the coraco-clavicular ligament is almost as reliable with US as with the “gold standard” MRI [216].

Shoulder

The coraco-humeral and coraco-acromial ligaments, which stabilize the interval between the subscapularis and supraspinatus ten-

dons, are relevant for the diagnosis of subacromial impingement. In adhesive capsulitis, the ligaments are noticeably different morphologically [217] or using elastography [218] and may show Doppler signal. The glenohumeral ligaments are difficult to visualize.

Elbow

The radial ligament complex can be examined morphologically as well as by testing the stability. The same applies to the ulnar ligament complex [219–221].

Visualization of the Struthers ligament may be helpful in the median nerve entrapment syndrome [222]. Similarly, assessment of the Osborne's ligament and the arcuate ligament in the entrapment syndrome of the ulnar nerve may provide relevant information.

Hand and wrist

The scapho-lunar ligament can be examined with US both for morphology and stability under dynamic conditions [223], albeit with low sensitivity but high specificity [224]. The trapezio-metacarpal ligament can be well visualized and examined for its stability [225]. In cases of instability of the ulnar collateral ligament of the thumb, its morphology can be examined and assessed in conjunction with a dynamic examination, especially if the ligament is dislocated over the aponeurosis of the adductor pollicis muscle [226].

The thickness of the flexor retinaculum of the carpal tunnel (transverse carpal ligament) and its position in relation to the median nerve can be readily assessed on US [227]. The triangular fibrocartilage complex is difficult to detect sonographically. Nevertheless, high-resolution US allows for radial and ulnar collateral wrist ligament assessment [228] and US findings have been shown to correlate with ulnar-sided pain and instability [229].

US can be used to evaluate finger pulleys in trigger fingers and annular pulley ruptures. Accurate static and dynamic US evaluation are of comparable value to MRI in distinguishing partial, complete, and combined pulley ruptures from overuse injuries [230–232]. Flexor tendon thickness and annular pulley measurements have been proven to be feasible and valid in cadaver studies as well as in patients and healthy volunteers with good inter- and intraobserver reliabilities [233, 234]. Collateral ligament tears, palmar plate injuries, and thumb sesamoid fractures may be critical in the diagnostic workup of closed finger joint trauma and US may help improve outcomes [235].

Practical points, limitations, and artifacts in ligament examination are detailed in Supplementary ► **Supplementary Table 3, 4.**

Statement

1. For the knee, US can be considered as an accurate and reproducible imaging technique for diagnosing medial/lateral ligament and retinaculum injuries (**LoE 2**). Broad consensus (23/7/6, 77%)

Recommendations

1. US is useful to diagnose acute lateral ankle ligament injury (**LoE 1, SoR strong**). Strong consensus (31/1/4, 96%)
2. US is useful to predict the prognosis of acute ankle sprain (**LoE 1, SoR strong**). Broad consensus (27/4/5, 87%)
3. In addition to the manual anterior drawer test and stress radiography, dynamic stress US might be useful for diagnosing chronic ankle instability (**LoE 3, SoR weak**). Broad consensus (27/3/6, 90%)
4. US might be used to evaluate the injuries of acromio-clavicular joint and ligament, as well as of the coraco-humeral and coraco-acromial ligaments (**LoE 3, SoR weak**). Broad consensus (28/5/3, 85%)
5. In the elbow, US may be used to evaluate the medial/lateral collateral and annular ligaments, particularly during dynamic examination (**LoE 3, SoR weak**). Broad consensus (28/2/6, 93%)
6. In the hand and wrist, US may be used for the assessment of injuries in ligaments (scapholunate and thumb ulnar collateral) or the annular pulley, as well as trigger finger pathology (**LoE 3, SoR weak**). Broad consensus (29/3/4, 91%)

Bones

Background and clinical application

Enthesophytes

Enthesophytes have been defined in the OMERACT ultrasound group [28] and are included as one of the core elementary lesions of US-detected enthesitis [27]. High reliability has been found for enthesophytes compared to other elementary lesions in enthesitis [119]. Enthesitis is typical for psoriatic arthritis (PsA), and enthesophytes at typical sites were included among potential elemental US abnormalities able to distinguish PsA from controls [236]. However, a recent study on healthy volunteers found enthesophytes to be the most common lesion at tendon insertions, detected in 87.5% of participants and 23.1% of the entheses [237].

Bone erosions

In accessible areas, US was found to be highly accurate for the detection and semiquantitative assessment of bone erosions in patients with RA [238]. However, a recent review on the ability of US to detect erosions in patients with RA found a pooled sensitivity and specificity of US for the detection of early bone erosion of 58.4% and 93.9%, respectively [239].

Erosions, however, are not specific for RA. A study including patients with several inflammatory joint diseases found the presence of US-detected erosions not to be specific for RA, while larger erosions in selected joints, especially the 2nd and 3rd MCP, 5th metatarso-phalangeal (MTP) joint, and distal ulna, were highly specific for and predictive of RA [240]. This was supported by a recent study exploring differences in radiographic and US detection of erosions between ACPA-positive and -negative patients. On both imaging methods, the most discriminating joint between the two groups was MTP5, especially in patients with bilateral erosion [241].

Periostitis

Periostitis is a nonspecific finding corresponding to a thickening and elevation of the periosteum from the underlying cortex. It can be seen in malignant tumors, infections and inflammation, eosinophilic granuloma, aneurismal bone cyst, osteoid osteoma, hemophilia, or trauma [242, 243]. Radiographs are the first imaging modality to study periostitis although MRI or CT is the imaging reference standard.

Fractures

Bone fractures are a very common occurrence. Plain radiography is the imaging method of choice. In acute fractures, US can be used as a complementary method when radiographic imaging is negative but clinical suspicion is high. In these cases, US shows interruption of the cortical line, frequently together with periosteal thickening and hematoma [244, 245]. In stress fractures, plain radiography is often normal in the early stages. US may be highly effective in detecting the periosteal reaction and callus formation. MRI may also be used in cases where US is still negative [246]. After an acute fracture, US is superior to plain radiography for showing early organization of the bone callus. US and CEUS can be used to evaluate callus status in patients with bone non-union before and after treatment, also predicting clinical outcome [247, 248].

Practical points, limitations, and artifacts in bones examination are detailed in ► **Supplementary Table 3, 4.**

Recommendations

1. US should be used to detect peripheral enthesophytes and erosions (**LoE 1, SoR strong**). Broad consensus (**30/4/2, 88 %**)
2. In accessible bone areas, when radiography is negative but clinical suspicion of acute fracture is high, US should be used (**LoE 1, SoR strong**). Strong consensus (**32/2/2, 95 %**)
3. In regions with an acoustic window, US should be used for monitoring fracture healing (**LoE 2, SoR strong**). Broad consensus (**22/7/7, 76 %**)
4. In regions with an acoustic window, US might be used to detect periostitis (**LoE 4, SoR weak**). Broad consensus (**25/8/3, 76 %**).

Nerves

Expanding evidence has supported the use of US as a valuable imaging modality to investigate the peripheral nervous system [249–252]. In the short axis, normal peripheral nerves demonstrate a characteristic stippled (honeycomb-like) appearance (axons arranged in fascicles and multiple layers of connective tissue supporting and binding the fascicle bundles together) [253]. In long-axis planes, nerves appear as elongated structures with alternating hypo- and hyperechoic bands. The development of ultrahigh frequency probes (up to 30 MHz) has provided new perspectives in the evaluation of sub-millimetric terminal nerve branches, visualized as single small hypoechoic dots within a hyperechoic frame lacking the expected classic “honeycomb” appearance [254–261].

Clinical application

Compression neuropathies

When investigating compression neuropathies, three main classes of nerves should be considered:

- Class 1 includes large nerves (e. g., median, ulnar, peroneal, tibial, etc.), which are readily evaluated by probe frequencies of up to 13 MHz. Diagnosis is based on pattern recognition analysis and on calculation of the nerve cross-sectional area (CSA) [262–267].
- Class 2 consists of small nerves (e. g., posterior and anterior interosseous, sural, suprascapular, etc.), which require probe frequencies of up to 24 MHz. In this case, pattern recognition together with side-to-side comparison of the major nerve diameter plays a significant role in diagnosing compressive neuropathies [268, 269].
- Class 3 includes both large nerves (e. g., the femoral and sciatic nerves in their intrapelvic course) and small nerves (e. g., the deep peroneal nerves) which are poorly visualized or undetectable with US due to their anatomical location. In this case, US diagnosis relies only on indirect signs of nerve damage, including signs of denervation of the skeletal muscles supplied by the affected nerve [270, 271].

US signs of compressive neuropathy consist of nerve flattening at the compression point and nerve swelling proximal or (less commonly) distal to it [272, 273]. The transition between swollen and flattened segments is abrupt (“notch sign”). In the early phases of compression, nerve enlargement is detected due to intraneural edema and venous congestion. With time, the nerve echotexture may appear massively subverted due to loss of the fascicular pattern and diffuse nerve hypoechogenicity. If nerve compression persists, irreversible intraneural fibrosis may occur and nerves with fibrotic changes remain swollen after decompressive surgery [256, 274, 275].

Nerve injuries

In *penetrating injuries* with complete nerve transection, stump neuromas develop in continuity with the edges of the nerve (round hypoechoic masses which may be displaced or retracted from the site of injury) [276, 277]. In partial nerve tears, a spindle neuroma may develop along the injured nerve tract and US can estimate the percentage of involved and preserved fascicles [278–280]. *Stretching injuries* most commonly affect nerves with a tortuous course and typically occur in relation to fixation points, such as where the nerve pierces fascial planes or crosses tight osteofibrous tunnels [281]. *Contusion injuries* most often occur where nerves run close to bony surfaces and are vulnerable to external pressure. The nerve may show various degrees of swelling with or without preservation of the fascicular echotexture, depending on the severity of trauma [282, 283].

Polyneuropathies

US findings in patients with dysimmune neuropathies are similar among the various forms and mainly consist of segmental nerve/fascicle swelling, which typically involves the nerve sections where

conduction blocks are identified by electrophysiology [284–288]. US may demonstrate focal changes in nerve/fascicle thickness in early phases, when electrophysiology is still negative, and reduced fascicular swelling during treatment, before neurophysiological improvement occurs [289–291].

In leprosy, US findings consist of markedly swollen nerves with loss of the fascicular echotexture, thickened epineurium, and intense intraneural hyperemia on Doppler imaging (“nerve inferno”) in acute neuritic phases [292]. In Charcot-Marie-Tooth (CMT), marked generalized fascicular enlargement, akin to an “onion bulb”, and Schwann cell hypertrophy due to attempted remyelination are typical findings of CMT-1A [293–296]. In hereditary neuropathy with liability to pressure palsies patients, US demonstrates multifocal nerve enlargements (tomaculae) following minor trauma, which most commonly occur in areas where the nerves are prone to compression [297, 298].

Nerve tumors and tumor-like conditions

The US diagnosis of peripheral nerve sheath tumors relies on the detection of a soft-tissue mass in continuity with a nerve. Alternatively, the “fat-split sign”, which consists of a rim of fat at the poles of an intramuscular mass, may suggest a lesion originating in the intermuscular space about the neurovascular bundle instead of the muscle itself [299, 300]. Although schwannoma and neurofibroma are often indistinguishable on US, schwannomas appear as eccentric ovoid masses arising from a single fascicle and displacing the unaffected fascicles to the periphery, whereas neurofibromas encase the fascicles of the parent nerve developing in a fusiform shape. Moreover, neurofibromas may show a “target sign” with a hyperechoic (fibrous) core and a hypoechoic (myxomatous tissue) rim. Compared to schwannomas, they are usually avascular or less vascular on Doppler imaging [301–303]. Malignant peripheral nerve sheath tumors tend to be larger (>5 cm) and more heterogeneous and often show indistinct margins, calcifications, areas of internal bleeding and necrosis [304–307]. However, a definite diagnosis usually requires histological sampling.

Practical points, limitations, and artifacts in the examination of nerves are detailed in ► **Supplementary Table 3, 4.**

Recommendations

1. The cross-sectional area (CSA) of 10 mm² of the median nerve at the carpal tunnel inlet, together with wrist-to-forearm ratio of the median nerve CSA, should be used in the diagnosis of median nerve compression (LoE 2A, SoR strong). Broad consensus (24/6/6, 80%)
2. In the diagnosis of carpal tunnel syndrome, cross-sectional area measurements of the median nerve should be considered complementary to electrodiagnostic tests (LoE 2A, SoR strong). Broad consensus (30/2/4, 94%)
3. An ulnar nerve cross-sectional area within the epitrochlear groove of 10 mm² should be assumed as the cut-off value for diagnosing ulnar nerve entrapment at the elbow region (LoE 2A, SoR strong). Strong consensus second round (30/1/5, 97%)

4. US should be used to identify, localize, and follow up full and partial thickness nerve injuries (LoE 1C, SoR strong). Broad consensus (29/2/5, 94%)
5. US might be used to detect nerve alterations in acquired and inherited polyneuropathies (LoE 3B, SoR weak). Broad consensus (24/6/6, 80%)
6. US might be used to recognize peripheral nerve sheath tumors, but histopathological examination is mandatory for differential diagnosis (LoE 3B, SoR weak). Strong consensus (32/1/3, 96%)

Skin and subcutaneous tissues

Background

US of the skin is nowadays considered part of a wider US application known as dermatologic US [308]. Musculoskeletal diseases and alterations may affect the skin to some extent or may be an incidental finding during exploration.

Skin US is an imaging method complementary to clinical examination and histopathology. Correct interpretation of skin US images requires corroboration of all available patient information and thorough knowledge of skin diseases and their management [309].

Clinical applications

Normal skin

Aging and ultraviolet- or sex-related changes have been effectively studied using high-frequency B-mode (thickness or echodensity) US and elastography [310–314]. Of note, using even higher frequencies (>50 MHz), US imaging correlates well with histological findings as far as hair follicles/tracts, glands, and erector pili muscles are concerned [315].

Scar

While scar type/depth or echogenicity differences can be safely ascertained on US [316], unlike normal skin, scar tissues have not been shown to correlate with histology in terms of skin thickness [317, 318].

Hidradenitis suppurativa

For more prompt diagnosis, staging, treatment planning, and monitoring, B-mode or Doppler US has recently been used to scan patients with hidradenitis suppurativa (HS) [318–326] including children [327, 328].

Infection

Point-of-care US has high sensitivity and specificity (range 89%–96% and 64%–88%, respectively) for diagnosing skin abscesses [329], distinguishing them from cellulitis [330], and following up treatment [331]. Furthermore, these values remained high for novice sonographers as well as experts [332–334].

Systemic sclerosis

Compared to clinical evaluation, US examination proved more sensitive and reliable for quantifying systemic sclerosis (SSc) skin involvement in both patients and controls [335–339]. A better

discrimination between clinical and subclinical skin involvement [335–340], different forms of SSc, and disease stages [335–337] was achieved. An inverse relationship between skin echogenicity and thickness was identified in patients with SSc in the edematous phase of the disease [335, 336]. US findings were found to correlate with clinical activity scores (Rodnan Skin Score), degree of pulmonary involvement, specific histologic and pathogenetic features [336, 341, 342] and are sensitive for detecting longitudinal skin thickness changes and vascularity [341].

Elastography can quantify skin stiffness by adding information about the disease stage and helping to distinguish subclinical SSc involvement from healthy skin [340, 343, 344]. Shear wave velocity values were significantly higher in SSc patients than in controls at almost all modified Rodnan Skin Score sites and thus correlated with the degree of pulmonary involvement [339, 343].

Morphea

US provided qualitative and quantitative anatomical data, such as thickness measurements, detection of structural abnormalities, and Doppler analysis of the lesional and perilesional vessels in both clinical and subclinical stages of the disease [345–349].

Psoriatic plaque

In a psoriatic plaque, the epidermis and dermis appear thicker compared with the normal surrounding skin. A hypoechoic band in the upper dermis can be observed, representing inflammatory edema and vasodilatation within the papillary dermis. This sign was shown to be linked to the most active stages of the disease [350–354].

Lymphatic vessels

Currently, several studies have assessed the applicability of US and elastography as early methods for the diagnosis, staging, and assessment of clinical and subclinical lymphedema [355, 356]. High-resolution US was proven to distinguish lower limb lymphedema from other edematous conditions [357, 358].

Melanoma

In melanoma staging, US contributes to the primary staging and detection of metastases. The Breslow index (measurement from the granular epidermal layer to the deepest melanoma extension in millimeters) is the main predictor of lymphatic extension and prognosis worsening [359]. Most studies showed a high correlation between the Breslow Index and US measurements. In a retrospective cohort study [360–362], correlation with manual measurements reached $r = 0.88$, permitting a single stage excision in most cases.

Regarding US follow-up of melanoma patients, US was not superior to clinical follow-up in terms of survival in a prospective cohort study comparing these two follow-up modalities in stage IB IIA patients [363–365].

Nonmelanoma skin cancer (NMSC)

Most common NMSCs are basal cell and squamous cell carcinomas. The heterogeneity of studies and techniques does not per-

mit a clear recommendation on the systematic use of US in NMSC management [364]. However, some retrospective cohort studies [366, 367] and multiple case series indicate the possibility of using US to detect occult basal cell carcinoma foci, to discriminate between high- and low-risk forms.

Other neoplastic and inflammatory skin lesions

US features of other skin lesions such as mycosis fungoides, other skin lymphomas [368, 369], Kaposi sarcoma [370], and dermatofibrosarcoma protuberans [371] have also been described.

Other benign skin tumors, such as pilomatrixomas [372], cysts [373], lipomas [374], and neurofibromas [375], have also been characterized and they present distinct sonographic patterns that are potentially useful for noninvasive diagnosis. However, these observations were derived from cross-sectional studies and small case series.

In other inflammatory skin diseases, such as panniculitis [376], pseudoxanthoma elasticum [377], atopic dermatitis [368], and sarcoidosis [378], US provides additional information that is useful for early diagnosis or follow-up.

Practical points, limitations, and artifacts in skin and subcutaneous tissue examination are detailed in ► **Supplementary Table 3, 4.**

Recommendations

1. US is recommended for prompt diagnosis, staging, treatment planning, and monitoring in patients with hidradenitis suppurativa (**LoE 2, SoR strong**). Strong consensus (32/1/3/ 97%)
2. US is recommended as the first-line modality in the detection of skin abscesses (**LoE 2, SoR strong**). Strong consensus (33/1/2, 97%)
3. US is recommended for the qualitative and quantitative evaluation of skin layers, the differentiation between disease forms, and the staging and monitoring of skin abnormalities in systemic sclerosis patients (**LoE1, GoR strong**). Broad consensus (28/3/5, 90%)

Fascia

Background

The fascia is a collagenous tissue continuum that surrounds and separates muscles, forms sheaths for nerves and vessels, and strengthens ligaments around joints [379]. The deep fascia has a complex structure formed by two or three layers of densely packed collagen fibers, interpolated by a layer of loose connective tissue [380].

Both morphological and dynamic properties (sliding, displacement) are important for the functional integrity of the fascia system [381]. Fascial layers have some sites of potential weakness which could give rise to hernias (sports hernia or incisional hernia). Herniation of skeletal muscles through fascial defects has also been described. The tibialis anterior, extensor digitorum longus, peroneus longus and brevis, the gastrocnemius are the most commonly affected muscles [382].

Deep fascia can be affected, though rarely, by a severe infection (necrotizing fasciitis) or inflammation (eosinophilic fasciitis).

The former is a fulminant infection, which can follow minor injuries, while the latter is a chronic progressive condition which usually affects the limbs symmetrically.

Neoplastic lesions involving the fascia are generally uncommon, with benign lesions being far more frequent.

Clinical application

High-resolution US of fasciae can assess morphometric characteristics such as thickness and echogenicity [383] and allows visualization of fascia sliding or displacing [381].

The fascia generally appears as a linear hyperechoic structure with boundaries easily identifiable due to the adjacent hypoechoic muscles. It consists of a single or several discrete layers [380].

The plantar fascia is by far the most studied fascia with a well standardized scanning protocol (longitudinal scan at its most proximal part) [383] and an accepted cut-off point of 4 mm for its normal thickness [384]. There are no agreed-upon reference values for the normal thickness of other fasciae, though aponeurotic fasciae seem to be generally thicker than epimysial ones [381].

In detecting sport hernias, with laparoscopy as the gold standard, US has a high sensitivity (95 %) and specificity (100 %), as well as a positive and a negative predictive value close to 100% [385]. In identifying incisional hernias, US was found to have an added value of 29.4 % over clinical examination alone [386]. Dynamic US or MRI can be used to confirm muscle hernias. An additional advantage of US is that the patient can be examined in a standing position [387].

Necrotizing fasciitis shows on US as marked subcutaneous edema and thickening, with interconnected fluid collections resulting in a cobblestone appearance and small bright foci with dirty acoustic shadowing representing microbubbles of gas [388]. Regarding the amount of deep fascia fluid accumulation, a study showed that a cut-off value of 2 mm had the best accuracy (72.7 %) with a sensitivity of 75 % and a specificity of 70.2 %. Patients with this level of fluid accumulation were hospitalized longer and needed amputation more often [389].

Eosinophilic fasciitis appears on US as a thickened fascia of altered echogenicity with thickening, hyperechogenicity, and markedly reduced compressibility of the subcutaneous tissue [390]. Thickness reduction was observed with treatment [391].

Plantar fibromatosis frequently exhibits mixed echogenicity in large lesions [392, 393] and hypoechoic areas in small lesions [392], with acoustic enhancement, a comb sign (linear hypoechoic areas located near isoechoic areas), and, possibly, internal vascularity. Increased stiffness of the nodular thickening on elastography was described in Dupuytren disease [394]. Hypoechoic areas of the nodules does not predict the progression of this condition [395].

Nodular fasciitis may have various appearances: a hypoechoic mass with internal echogenic foci [396, 397], a peripheral hyperechoic nodule or an echoic rim [397, 398], oval or round in shape with irregular or lobular margins, fascial tail [397], and usually avascular [398]. In children, this condition is found most frequently in the head or neck [399]. Proliferative fasciitis is a rare lesion

described as an ill-defined hyperechoic structure with a thickened hypoechoic reticular pattern [400].

The relative reliability of thickness and echogenicity measurement of the plantar fascia was proven to be high (interclass correlation coefficient, ICC = 0.88) [401]. Good reproducibility was also found (intra- and interrater reliability, ICC > 0.821, ICC > 0.849) [402], as well as good agreement between an experienced and a novel sonographer [403]. In another study the intra-tester reliability was shown to significantly surpass the inter-tester reliability in plantar fasciitis (0.89 vs. 0.61, respectively) [404]. Multiple measurements showed higher reliability compared to a single measurement (ICC > 0.90) [404].

The inter-rater reliability proved to be good also for the abdominal fasciae (ICC = 0.83) [405]. The intraobserver reliability of the echogenicity of Dupuytren's nodules was excellent (ICC = 0.996; 95 %CI, 0.993 to 0.998), while the interobserver reliability was fairly good but imprecise (ICC = 0.688; 95 %CI, 0.329 to 0.977) [388].

Practical points, limitations, and artifacts in fascia examination are detailed in ► **Supplementary Table 3, 4.**

Recommendations

1. Ultrasound may be used to assess muscular fascia's morphometric characteristics like thickness and echogenicity, as well as fascia sliding and displacement (LoE 3, SoR weak). Broad consensus (29/5/2, 85 %)
2. US should be used as point-of-care diagnostic imaging method in fascia infection (necrotizing fasciitis), proliferative diseases, and fascia defects (LoE 3, SoR strong). Broad consensus (29/4/3, 82 %)

Nails

Background

The nail plates, nail matrix, and nail bed form the nail unit. The periungual area is composed of the periungual folds, i. e., the proximal fold (eponychium), lateral folds (perionychium), and distal fold (hyponychium). The bilaminar nail plate is visualized as two parallel hyperechoic bands, i. e., ventral plate and dorsal plate, separated by a hypoechoic virtual space, i. e., the interplate space. The nail plate thickness varies between 0.3 and 0.65 mm. The nail matrix appears as a 1–5.3 mm long echogenic structure, located in the proximal aspect of the nail bed. The nail bed is seen as a 0.7–6 mm thick hypoechoic structure immediately deep to the nail plate and extending to the bone profile of the distal phalanx. Doppler mode shows a high level of low-resistance, low-velocity blood flow in the nail, especially in the nail bed [406–409].

Performance of nail US has been standardized through a consensus-based methodology by an international expert working group [410].

Clinical application

Psoriatic onychopathy (PsO)

US assessment of nails in psoriasis has recently emerged based on the fact that the nail is conceptually an extension of the distal

interphalangeal entheses. It is aimed at detecting early signs of psoriatic involvement [411]. A systematic review [412] showed that the evidence for the role of US in the detection of PsO is low, mainly due to methodology limitations, based on case-control cross-sectional studies with high variability in the US features measured. Despite these considerations, there is a marked tendency to show differences between patients with PsO and healthy controls mainly in nail bed and nail plate thickness, even before clinical PsO signs are evident [413]. However, no study was able to predict more severe disease or the development of PsA based solely on this parameter [414].

In both clinical and subclinical PsO patients there is a tendency towards increased Doppler signals [415]. The spatial relationship of these CD/PD signals with anatomical structures of the nails, such as the ventral plate [416] may warrant assessment in future studies.

The EFSUMB'S Position Statement on Dermatologic Ultrasound suggested US assessment of nails in patients with suspicion of clinical psoriasis to support the diagnosis of this condition [308].

Nail tumors

Scientific evidence to date on US and subungual tumors is very scarce, mostly as isolated clinical cases describing the ultrasonographic features of tumors, such as subungual schwannoma [417], keratoacanthoma [418], and squamous cell carcinoma [419].

In the review of onychomatricoma imaging tests by Cinnoti et al. [420], dermoscopy is highlighted as a first diagnostic step. In six cases US techniques were performed. In four cases hypoechogenic solid areas affecting the unguis matrix with hyperechogenic dots corresponding to the finger-like projections that deform the plate were found. Doppler US showed a non-specific hypovascular pattern.

Nakamura et al. [421] measured the tumor-to-bone distance of invasive subungual melanoma. In tumor sizes below 4 mm, the probability of bone involvement was low and non-amputative surgery was possible. This study was performed on surgical specimens and the authors raised the possibility of using US techniques to measure this distance.

The subungual glomus tumor is described as a subungual hypervascular mass, with bone erosion or bone remodeling. US is able to locate the tumor, is more cost-effective than MRI, and detects small tumors. US may be used as a complementary technique to clinical diagnosis and for surgical planning [422–427].

In subungual exostosis a hyperechogenic subungual image with acoustic shadowing connected to the phalanx was described as a pathognomonic finding in two case series [428, 429].

Other nail conditions

US can differentiate solid and cystic nail lesions and can be used as a valuable aid to optimize the clinical diagnosis of a number of nail disorders [430–435]. In onycholysis an anechoic gap between the nail plate and the nail bed is seen on US. In onychomadesis, the separation of the proximal edge of the nail plate from the nail matrix and bed is detected.

Based on a retrospective case-control study [434], diagnostic criteria for retronychia have been described as follows: 1) hypoechogenic halo surrounding the origin of the nail plate; 2) distance between the origin of the nail plate and the base of the distal phalanx of 5.1 mm or less in big toes and thumbs and/or a difference of 0.5 mm of this distance or greater between the affected nail and the contralateral healthy nail; and 3) proximal nail fold thickness of 2.2 mm or greater for male patients or 1.9 mm or greater for female patients and/or a proximal nail fold 0.3 mm thicker or greater in comparison with the contralateral healthy nail. The presence of all criteria supports the diagnosis of unilateral retronychia and the presence of 2 or more criteria (one of them criterion 1) supports the diagnosis of bilateral cases.

In onychomycosis, US shows an increased thickness of the nail bed, diffuse thickening and irregularity of the nail plates, fusion of the nail plates, and later acoustic shadowing in the nail bed. On US, in paronychia, diffuse thickening of the periungual fold is seen, with areas of increased echogenicity interposed with hypoechogenic areas and increased vascularity in Doppler mode. US abnormalities in SSc, lupus, and dermatomyositis can be found within the nail bed, mainly described as a decrease of both echogenicity and blood flow, secondary to microvascular changes. US has shown a high diagnostic accuracy for traumatic nail bed lesions and distal phalanx fractures [435].

Practical points, limitations, and artifacts in nails examination are detailed in ► **Supplementary Table 3, 4.**

Recommendations

1. US might be used to increase clinical diagnostic accuracy in structural, infectious, inflammatory, and vascular nail disorders (LoE 4, SoR weak). Broad consensus (25/4/7, 86 %)
2. US assessment of nails in patients with clinical suspicion of psoriasis may support diagnosis (LoE 4, SoR weak). Broad consensus (28/2/6, 93 %)
3. US assessment of subungual glomus tumors and exostoses may support the clinical diagnosis and help in surgical planning (LoE 4, SoR weak). Strong consensus (29/1/6, 96 %)

Conflict of Interest

Fernando Alfageme: Speaker honoraria: GE, Mindray; Equipment support: Esaote

David Bong: No Conflicts of interest

Angel Bueno: No Conflicts of interest

Vito Cantisani: Speaker honoraria: Bracco, Samsung, Canon

Paz Collado: No Conflicts of interest

Maria Antonietta D'Agostino: No Conflicts of interest

Daniela Fodor: No Conflicts of interest

Javier de la Fuente: No Conflicts of interest

Wolfgang Hartung: Speaker honoraria: Abbvie, GE Healthcare, Alpinion Medical; Ultrasound equipment support; Alpinion Medical Germany, Canon Medical Germany

Hilde Hammer: Speaker honoraria and/or consultancy; AbbVie, Lilly, Roche, Novartis

Andrea Klausner: No Conflicts of interest

Jens Kessler: No Conflicts of interest

Manuela Lenghel: No Conflicts of interest

Carlo Martinoli: Speaker honoraria and equipment support: Philips, Canon

Dolores Mendoza-Cembranos: No Conflicts of interest
 Mihaela Micu: No Conflicts of interest
 Ingrid Möller: No Conflicts of interest
 Aurelie Najm: No Conflicts of interest
 Gabriella Iohom: No Conflicts of interest
 Clara Malattia: No Conflicts of interest
 Peter Mandl: No Conflicts of interest
 Esperanza Naredo: No Conflicts of interest
 Levent Ozcakar: No Conflicts of interest
 Riccardo Picasso: No Conflicts of interest
 Athena Plagou: Speaker honoraria: GE
 Sebastian C Rodriguez-Garcia: No Conflicts of interest
 Xavier Sala-Blanch: No Conflicts of interest
 Luca Scofienza: Non-financial support: Samsung Imaging, Abiogen, Bracco Imaging Italia; Speaker honoraria: Esaote SPA, Abiogen, Biolive, Fidia Pharma Group, Novartis, Pfizer
 Oana Serban: No Conflicts of interest
 Paolo Simoni: No Conflicts of interest
 Iwona Sudol-Szopińska: No Conflicts of interest
 Lene Terslev: Speaker honoraria: GE
 Christian Tesch: No Conflicts of interest
 Plamen Todorov: No Conflicts of interest
 Jacqueline Uson: No Conflicts of interest
 Violeta Vlad: No Conflicts of interest
 Federico Zaottini: No Conflicts of interest
 Michael Pelea, Diana Bilous, Anamaria Marian, Roxana Gutiu: No conflict of interest

Acknowledgment

The authors thanks Lynne Rudd, Daniele Fresilli and Patrizia Pacini for all the support.

References

- [1] Mandl P, Ciechomska A, Terslev L et al. Implementation and role of modern musculoskeletal imaging in rheumatological practice in member countries of EULAR. *RMD Open* 2019; 5: e000950
- [2] Möller I, Janta I, Backhaus M et al. The 2017 EULAR standardised procedures for ultrasound imaging in rheumatology. *Ann Rheum Dis* 2017; 76: 1974–1979
- [3] Naredo E, D'Agostino MA, Conaghan PG et al. Current state of musculoskeletal ultrasound training and implementation in Europe: results of a survey of experts and scientific societies. *Rheumatology* 2010; 49: 2438–2443
- [4] Plagou A, Teh J, Grainger AJ et al. Recommendations of the ESSR Arthritis Subcommittee on Ultrasonography in Inflammatory Joint Disease. *Semin Musculoskelet Radiol* 2016; 20: 496–506
- [5] Sakellariou G, Conaghan PG, Zhang W et al. EULAR recommendations for the use of imaging in the clinical management of peripheral joint osteoarthritis. *Ann Rheum Dis* 2017; 76: 1484–1494
- [6] Sconfienza LM, Albano D, Allen G et al. Clinical indications for musculoskeletal ultrasound updated in 2017 by European Society of Musculoskeletal Radiology (ESSR) consensus. *Eur Radiol* 2018; 28: 5338–5351
- [7] Siddle HJ, Mandl P, Aletaha D et al. The EULAR points to consider for health professionals undertaking musculoskeletal ultrasound for rheumatic and musculoskeletal diseases. *Ann Rheum Dis* 2018; 77: 311–313
- [8] Tagliafico AS, Wilson D, Sconfienza LM. European Society of Musculoskeletal Radiology (ESSR) Research Committee. Encouraging MSK imaging research towards clinical impact is a necessity: opinion paper of the European Society of Musculoskeletal Radiology (ESSR). *Eur Radiol* 2019; 29: 3410–3413
- [9] Terslev L, Hammer HB, Torp-Pedersen S et al. EFSUMB minimum training requirements for rheumatologists performing musculoskeletal ultrasound. *Ultraschall in Med* 2013; 34: 475–477
- [10] Uson J, Loza E, Möller I et al. Recommendations for the Use of Ultrasound and Magnetic Resonance in Patients With Spondyloarthritis, Including Psoriatic Arthritis, and Patients With Juvenile Idiopathic Arthritis. *Rheumatol Clin* 2018; 14: 27–35
- [11] Phillips B, Ball C, Sackett D et al. Oxford Centre for Evidence-based Medicine – Levels of Evidence 1. In: Oxford Centre for Evidence-Based Medicine. 2009
- [12] Guyatt GH, Oxman AD, Vist GE et al. GRADE: an emerging consensus on rating quality of evidence and strength of recommendations. *BMJ* 2008; 336: 924–926
- [13] Janssen C, Gilja OH, Serra AL et al. European Federation of Societies for Ultrasound in Medicine and Biology (EFSUMB) Policy Document Development Strategy – Clinical Practice Guidelines, Position Statements and Technological Reviews. *Ultrasound Int Open* 2019; 5: E2–E10
- [14] Boyce SH, Murray AD, Jeffrey M. A review of musculoskeletal ultrasound training guidelines and recommendations for sport and exercise medicine physicians. *Ultrasound* 2013; 21: 155–158
- [15] Cremerius C, Gradl-Dietsch G, Beeres FJP et al. Team-based learning for teaching musculoskeletal ultrasound skills: a prospective randomised trial. *Eur J Trauma Emerg Surg* 2020. doi:10.1007/s00068-019-01298-9
- [16] Iagnocco A, Naredo E, Bijlsma JW. Becoming a musculoskeletal ultrasonographer. *Best Pract Res Clin Rheumatol* 2013; 27: 271–281
- [17] European Federation of Societies for Ultrasound in Medicine and Biology (EFSUMB). Online: www.efsumb.org
- [18] Naredo E, Bijlsma JW, Conaghan PG et al. Recommendations for the content and conduct of European League Against Rheumatism (EULAR) musculoskeletal ultrasound courses. *Ann Rheum Dis* 2008; 67: 1017–1022
- [19] Janta I, Terslev L, Ammitzbøll-Danielsen M et al. EFSUMB COMPASS for Rheumatologists dissemination and implementation—an international survey. *Med Ultrason* 2016; 18: 42–46
- [20] Iagnocco A, Terslev L, Backhaus M et al. Educational recommendations for the conduct, content and format of EULAR musculoskeletal ultrasound Teaching the Teachers Courses. *RMD Open* 2015; 1: e000139
- [21] Iagnocco A, Porta F, Cuomo G. Musculoskeletal Ultrasound Study Group of the Italian Society of Rheumatology et al. The Italian MSUS Study Group recommendations for the format and content of the report and documentation in musculoskeletal ultrasonography in rheumatology. *Rheumatology (Oxford)* 2014; 53: 367–373
- [22] European Society of Musculoskeletal Radiology (ESSR). Online: www.essr.org
- [23] Klauser AS, McNally E, Chhem RK. Training Musculoskeletal Ultrasound Specialists: European Education and Clinical Guidelines: Work in Progress. In: *The Practice of Radiology Education*. Berlin, Heidelberg: Springer; 2010: 143–159
- [24] Akram Q. Training issues in ultrasound and the benefits of an International Fellowship. *Rheumatology (Oxford)* 2018; 57: 947–948
- [25] D'Agostino MA, Terslev L, Aegerter P et al. Scoring ultrasound synovitis in rheumatoid arthritis: a EULAR-OMERACT ultrasound taskforce. Part 1: definition and development of a standardised, consensus-based scoring system. *RMD Open* 2017; 3: e000428
- [26] Mandl P, Studenic P, Filippucci E. OMERACT Ultrasound Cartilage Task Force Group et al. Development of semiquantitative ultrasound scoring system to assess cartilage in rheumatoid arthritis. *Rheumatology (Oxford)* 2019; 58: 1802–1811
- [27] Naredo E, D'Agostino MA, Wakefield RJ et al. Reliability of a consensus-based ultrasound score for tenosynovitis in rheumatoid arthritis. *Ann Rheum Dis* 2013; 72: 1328–1334
- [28] Terslev L, Naredo E, Iagnocco A et al. Defining enthesitis in spondyloarthritis by ultrasound: results of a Delphi process and of a reliability reading exercise. *Arthritis Care Res (Hoboken)* 2014; 66: 741–748
- [29] Roth J, Jousse-Joulin S, Magni-Manzoni S. Outcome Measures in Rheumatology Ultrasound Group et al. Definitions for the sonographic fea-

- tures of joints in healthy children. *Arthritis Care Res (Hoboken)* 2015; 67: 136–142
- [30] Wakefield RJ, Balint PV, Szkudlarek M et al. Musculoskeletal ultrasound including definitions for ultrasonographic pathology. *J Rheumatol* 2005; 32: 2485–2487
- [31] Roth J, Ravagnani V, Backhaus M. OMERACT Ultrasound Group et al. Preliminary Definitions for the Sonographic Features of Synovitis in Children. *Arthritis Care Res (Hoboken)* 2017; 69: 1217–1223
- [32] Bruyn GA, Hanova P, Iagnocco A et al. Ultrasound definition of tendon damage in patients with rheumatoid arthritis. Results of a OMERACT consensus-based ultrasound score focussing on the diagnostic reliability. *Ann Rheum Dis* 2014; 73: 1929–1934
- [33] Hammer HB, Iagnocco A, Mathiessen A et al. Global ultrasound assessment of structural lesions in osteoarthritis: a reliability study by the OMERACT ultrasonography group on scoring cartilage and osteophytes in finger joints. *Ann Rheum Dis* 2016; 75: 402–407
- [34] Keen HI, Lavie F, Wakefield RJ et al. The development of a preliminary ultrasonographic scoring system for features of hand osteoarthritis. *Ann Rheum Dis* 2008; 67: 651–655
- [35] Filippou G, Scirè CA, Damjanov N et al. Definition and Reliability Assessment of Elementary Ultrasonographic Findings in Calcium Pyrophosphate Deposition Disease: A Study by the OMERACT Calcium Pyrophosphate Deposition Disease Ultrasound Subtask Force. *J Rheumatol* 2017; 44: 1744–1749
- [36] Gutierrez M, Schmidt WA, Thiele RG et al. International Consensus for Ultrasound Lesions in Gout. Results of Delphi Process and Web-Reliability Exercise. *Rheumatology (Oxford)* 2015; 54: 1797–1805
- [37] Möller I, Miguel M, Bong DA et al. The peripheral nerves: update on ultrasound and magnetic resonance imaging. *Clin Exp Rheumatol* 2018; 36 (Suppl. 114): 145–158
- [38] Kollmann C, Jenderka KV, Moran CM et al. EFSUMB Clinical Safety Statement for Diagnostic Ultrasound – (2019 revision). *Ultraschall in Med* 2020; 41: 387–389
- [39] Ang ES Jr, Gluncic V, Duque A et al. Prenatal exposure to ultrasound waves impacts neuronal migration in mice. *Proc Natl Acad Sci USA* 2006; 103: 12903–12910
- [40] Sidhu PS, Cantisani V, Dietrich CF et al. The EFSUMB Guidelines and Recommendations for the Clinical Practice of Contrast-Enhanced Ultrasound (CEUS) in Non-Hepatic Applications: Update 2017 (Short Version). *Ultraschall in Med* 2018; 39: 154–180
- [41] Harris GR, Church CC, Dalecki D. American Institute of Ultrasound in Medicine; Health Canada; British Medical Ultrasound Society et al. Comparison of Thermal Safety Practice Guidelines for Diagnostic Ultrasound Exposures. *Ultrasound Med Biol* 2016; 42: 345–357
- [42] Nelson TR, Fowlkes JB, Abramowicz JS et al. Ultrasound biosafety considerations for the practicing sonographer and sonologist. *J Ultrasound Med* 2009; 28: 139–150
- [43] ECMUS safety aspects of elastography 2014. Online: www.efsumb.org/ecmus
- [44] Nowicki A. Safety of ultrasonic examinations; thermal and mechanical indices. *Med Ultrason* 2020; 22: 203–210
- [45] Scholten RR, Pillen S, Verrips A et al. Quantitative ultrasonography of skeletal muscles in children: normal values. *Muscle Nerve* 2003; 27: 693–698
- [46] Hioki M, Kanehira N, Koike T et al. Age-related changes in muscle volume and intramuscular fat content in quadriceps femoris and hamstrings. *Exp Gerontol* 2020; 132: 110834
- [47] Woodhouse JB, McNally EG. Ultrasound of skeletal muscle injury: an update. *Semin Ultrasound CT MR* 2011; 32: 91–100
- [48] Bianchi S, Martinoli C, Waser NP et al. Central aponeurosis tears of the rectus femoris: sonographic findings. *Skeletal Radiol* 2002; 31: 581–586
- [49] Koulouris G, Connell D. Hamstring muscle complex: an imaging review. *Radiographics* 2005; 25: 571–586
- [50] Peetrons P. Ultrasound of muscles. *Eur Radiol* 2002; 12: 35–43
- [51] Campbell SE, Adler R, Sofka CM. Ultrasound of muscle abnormalities. *Ultrasound Q* 2005; 21: 87–94
- [52] Beggs I. Sonography of Muscle Hernias. *Am J Roentgenol* 2003; 180: 395–399
- [53] Carra BJ, Bui-Mansfield LT, O'Brien SD et al. Sonography of musculoskeletal soft-tissue masses: techniques, pearls, and pitfalls. *Am J Roentgenol* 2014; 202: 1281–1290
- [54] Tranquart F, Grenier N, Eder V et al. Clinical use of ultrasound tissue harmonic imaging. *Ultrasound Med Biol* 1999; 25: 889–894
- [55] Klausner AS, Peetrons P. Developments in musculoskeletal ultrasound and clinical applications. *Skeletal Radiol* 2010; 39: 1061–1071
- [56] Suspected cancer: recognition and referral. NICE Guidance NG12 June 2015, Section 1.11. Online (Accessed 25 Jan 2016): <http://www.nice.org.uk/guidance/ng12>
- [57] Dangoor A, Seddon B, Gerrand C et al. UK guidelines for the management of soft tissue sarcomas. *Clin Sarcoma Res* 2016; 6: 20
- [58] Arts IMP, Pillen S, Schelhaas HJ et al. Normal values for quantitative muscle ultrasonography in adults. *Muscle Nerve* 2010; 41: 32–41
- [59] English C, Fisher L, Thoires K. Reliability of real-time ultrasound for measuring skeletal muscle size in human limbs in vivo: a systematic review. *Clin Rehabil* 2012; 26: 934–944
- [60] Nijholt W, Scafoglieri A, Jager-Wittenaar H et al. The reliability and validity of ultrasound to quantify muscles in older adults: a systematic review. *J Cachexia Sarcopenia Muscle* 2017; 8: 702–712
- [61] Ticinesi A, Meschi T, Narici MV et al. Muscle Ultrasound and Sarcopenia in Older Individuals: A Clinical Perspective. *J Am Med Dir Assoc* 2017; 18: 290–300
- [62] Albano D, Messina C, Vitale J et al. Imaging of sarcopenia: old evidence and new insights. *Eur Radiol* 2020; 30: 2199–2208
- [63] Berger J, Bunout D, Barrera G et al. Rectus femoris (RF) ultrasound for the assessment of muscle mass in older people. *Arch Gerontol Geriatr* 2015; 61: 33–38
- [64] Sipilä S, Suominen H. Muscle ultrasonography and computed tomography in elderly trained and untrained women. *Muscle Nerve* 1993; 16: 294–300
- [65] Koppenhaver SL, Hebert JJ, Parent EC et al. Rehabilitative ultrasound imaging is a valid measure of trunk muscle size and activation during most isometric sub-maximal contractions: a systematic review. *Aust J Physiother* 2009; 55: 153–169
- [66] Pretorius A, Keating JL. Validity of real time ultrasound for measuring skeletal muscle size. *Phys Ther Rev* 2008; 13: 415–426
- [67] MacGillivray TJ, Ross E, Simpson HA et al. 3D freehand ultrasound for in vivo determination of human skeletal muscle volume. *Ultrasound Med Biol* 2009; 35: 928–935
- [68] Reeves ND, Maganaris CN, Narici MV. Ultrasonographic assessment of human skeletal muscle size. *Eur J Appl Physiol* 2004; 91: 116–118
- [69] Sconfienza LM. Sarcopenia: ultrasound today, smartphones tomorrow? *Eur Radiol* 2019; 29: 1–2
- [70] Galindo Martín CA, Monares Zepeda E, Lescas Méndez OA. Bedside Ultrasound Measurement of Rectus Femoris: A Tutorial for the Nutrition Support Clinician. *J Nutr Metab* 2017; 2017: 2767232
- [71] Ticinesi A, Narici MV, Lauretani F et al. Assessing sarcopenia with vastus lateralis muscle ultrasound: an operative protocol. *Aging Clin Exp Res* 2018; 30: 1437–1443
- [72] Cruz-Jentoft AJ, Bahat G, Bauer J et al. Sarcopenia: revised European consensus on definition and diagnosis. *Age Ageing* 2019; 48: 16–31
- [73] Reimers CD, Fleckenstein JL, Witt TN et al. Muscular ultrasound in idiopathic inflammatory myopathies of adults. *J Neurol Sci* 1993; 116: 82–92

- [74] Gonzalez NL, Hobson-Webb LD. Neuromuscular ultrasound in clinical practice: A review. *Clin Neurophysiol Pract* 2019; 4: 148–163
- [75] Cook JL, Purdam CR. Is tendon pathology a continuum? A pathology model to explain the clinical presentation of load-induced tendinopathy. *Br J Sports Med* 2009; 43: 409–416
- [76] Cook JL, Rio E, Purdam CR et al. Revisiting the continuum model of tendon pathology: what is its merit in clinical practice and research? *Br J Sports Med* 2016; 50: 1187–1191
- [77] Fu SC, Rolf C, Cheuk YC et al. Deciphering the pathogenesis of tendinopathy: a three-stages process. *Sports Med Arthrosc Rehabil Ther Technol* 2010; 2: 30
- [78] Matthews W, Ellis R, Furness JW et al. Staging achilles tendinopathy using ultrasound imaging: the development and investigation of a new ultrasound imaging criteria based on the continuum model of tendon pathology. *BMJ Open Sport Exerc Med* 2020; 6: e000699
- [79] Khan KM, Forster BB, Robinson J et al. Are ultrasound and magnetic resonance imaging of value in assessment of Achilles tendon disorders? A two year prospective study. *Br J Sports Med* 2003; 37: 149–153
- [80] Westacott DJ, Minns JL, Foguet P. The diagnostic accuracy of magnetic resonance imaging and ultrasonography in gluteal tendon tears—a systematic review. *Hip Int* 2011; 21: 637–645
- [81] Mc Auliffe S, Mc Creesh K, Purtil H et al. A systematic review of the reliability of diagnostic ultrasound imaging in measuring tendon size: Is the error clinically acceptable? *Phys Ther Sport* 2017; 26: 52–63
- [82] Docking SI, Ooi CC, Connell D. Tendinopathy: Is Imaging Telling Us the Entire Story? *J Orthop Sports Phys Ther* 2015; 45: 842–852
- [83] Gisslen K, Alfredson H. Neovascularisation and pain in jumper's knee: a prospective clinical and sonographic study in elite junior volleyball players. *Br J Sports Med* 2005; 39: 423–428
- [84] Boesen MI, Koenig MJ, Torp-Pedersen S et al. Tendinopathy and Doppler activity: the vascular response of the Achilles tendon to exercise. *Scand J Med Sci Sports* 2006; 16: 463–469
- [85] Adler RS, Fealy S, Rudzki JR et al. Rotator cuff in asymptomatic volunteers: contrast-enhanced US depiction of intratendinous and peritendinous vascularity. *Radiology* 2008; 248: 954–961
- [86] Albano D, Coppola A, Gitto S et al. Imaging of calcific tendinopathy around the shoulder: usual and unusual presentations and common pitfalls. *Radiol Med* 2020. doi:10.1007/s11547-020-01300-0
- [87] Chianca V, Albano D, Messina C et al. Rotator cuff calcific tendinopathy: from diagnosis to treatment. *Acta Biomed* 2018; 89: 186–196
- [88] Uthoff HK, Sarkar K. Calcifying tendinitis. *Baillieres Clin Rheumatol* 1989; 3: 567–581
- [89] De Zordo T, Ahmad N, Ødegaard F et al. US-guided therapy of calcific tendinopathy: clinical and radiological outcome assessment in shoulder and non-shoulder tendons. *Ultraschall in Med* 2011; 32 (Suppl. 1): S117–S123
- [90] Albano D, Vicentin I, Messina C et al. Post-surgical Achilles calcific tendinopathy treated with ultrasound-guided percutaneous irrigation. *Skeletal Radiol* 2020; 49: 1475–1480
- [91] Sconfienza LM, Viganò S, Martini C et al. Double-needle ultrasound-guided percutaneous treatment of rotator cuff calcific tendinitis: tips & tricks. *Skeletal Radiol* 2013; 42: 19–24
- [92] Roy JS, Braen C, Leblond J et al. Diagnostic accuracy of ultrasonography, MRI and MR arthrography in the characterisation of rotator cuff disorders: a systematic review and meta-analysis. *Br J Sports Med* 2015; 49: 1316–1328
- [93] de la Fuente J, Blasi M, Martinez S et al. Ultrasound classification of traumatic distal biceps brachii tendon injuries. *Skeletal Radiol* 2018; 47: 519–532
- [94] Arnoldner MA, Gruber M, Syre S et al. Imaging of posterior tibial tendon dysfunction – Comparison of high-resolution ultrasound and 3T MRI. *Eur J Radiol* 2015; 84: 1777–1781
- [95] Fischer CA, Weber MA, Neubecker C et al. Ultrasound vs. MRI in the assessment of rotator cuff structure prior to shoulder arthroplasty. *J Orthop* 2015; 12: 23–30
- [96] Lobo Lda G, Fessell DP, Miller BS et al. The role of sonography in differentiating full versus partial distal biceps tendon tears: correlation with surgical findings. *Am J Roentgenol* 2013; 200: 158–162
- [97] Foley R, Fessell D, Yablon C et al. Sonography of traumatic quadriceps tendon tears with surgical correlation. *J Ultrasound Med* 2015; 34: 805–810
- [98] Ammitzboll-Danielsen M, Ostergaard M, Naredo E et al. Validity and sensitivity to change of the semi-quantitative OMERACT ultrasound scoring system for tenosynovitis in patients with rheumatoid arthritis. *Rheumatology (Oxford)* 2016; 55: 2156–2166
- [99] Danielsen MA. Ultrasonography for diagnosis, monitoring and treatment of tenosynovitis in patients with rheumatoid arthritis. *Dan Med J* 2018; 65: B5474
- [100] Bruyn GA, Moller I, Garrido J et al. Reliability testing of tendon disease using two different scanning methods in patients with rheumatoid arthritis. *Rheumatology (Oxford)* 2012; 51: 1655–1661
- [101] Alcalde M, D'Agostino MA, Bruyn GA et al. A systematic literature review of US definitions, scoring systems and validity according to the OMERACT filter for tendon lesion in RA and other inflammatory joint diseases. *Rheumatology (Oxford)* 2012; 51: 1246–1260
- [102] Naredo E, D'Agostino MA, Wakefield RJ et al. Reliability of a consensus-based ultrasound score for tenosynovitis in rheumatoid arthritis. *Ann Rheum Dis* 2013; 72: 1328–1334
- [103] Matthews W, Ellis R, Furness J et al. Classification of tendon matrix change using ultrasound imaging: a systematic review and meta-analysis. *Ultrasound Med Biol* 2018; 44: 2059–2080
- [104] Säftoiu A, Gilja OH, Sidhu PS et al. The EFSUMB Guidelines and Recommendations for the Clinical Practice of Elastography in Non-Hepatic Applications: Update 2018. *Ultraschall in Med* 2019; 40: 425–453
- [105] Cook JL, Feller JA, Bonar SF et al. Abnormal tenocyte morphology is more prevalent than collagen disruption in asymptomatic athletes' patellar tendons. *J Orthop Res* 2004; 22: 334–338
- [106] Malliaras P, Purdam C, Maffulli N et al. Temporal sequence of greyscale ultrasound changes and their relationship with neovascularity and pain in the patellar tendon. *Br J Sports Med* 2010; 44: 944–947
- [107] Farin PU, Jaroma H. Sonographic findings of rotator cuff calcifications. *J Ultrasound Med* 1995; 14: 7–14
- [108] Sconfienza LM, Bandirali M, Serafini G et al. Rotator cuff calcific tendinitis: does warm saline solution improve the short-term outcome of double-needle US-guided treatment? *Radiology* 2012; 262: 560–566
- [109] Orlandi D, Mauri G, Lacelli F et al. Rotator Cuff Calcific Tendinopathy: Randomized Comparison of US-guided Percutaneous Treatments by Using One or Two Needles. *Radiology* 2017; 285: 518–527
- [110] Balint PV, Kane D, Wilson H et al. Ultrasonography of enthesal insertions in the lower limb in spondyloarthropathy. *Ann Rheum Dis* 2002; 61: 905–910
- [111] Baraliakos X, Kiltz U, Appel H et al. Chronic but not inflammatory changes at the Achilles' tendon differentiate patients with peripheral spondyloarthritis from other diagnoses – Results from a prospective clinical trial. *RMD Open* 2017; 3: e000541
- [112] Kamel M, Eid H, Mansour R. Ultrasound detection of heel enthesitis: A comparison with magnetic resonance imaging. *J Rheumatol* 2003; 30: 774–778
- [113] Ruta S, Gutierrez M, Pena C et al. Prevalence of Subclinical Enthesopathy in Patients With Spondyloarthropathy An Ultrasound Study. *J Clin Rheumatol* 2011; 17: 18–22
- [114] Wiell C, Szkudlarek M, Hasselquist M et al. Power Doppler ultrasonography of painful Achilles tendons and entheses in patients with and

- without spondyloarthropathy—a comparison with clinical examination and contrast-enhanced MRI. *Clin Rheumatol* 2013; 32: 301–308
- [115] Freeston JE, Coates LC, Helliwell PS et al. Is there subclinical enthesitis in early psoriatic arthritis? A clinical comparison with power doppler ultrasound. *Arthritis Care Res* 2012; 64: 1617–1621
- [116] Macchioni P, Salvarani C, Possemato N et al. Ultrasonographic and Clinical Assessment of Peripheral Enthesitis in Patients with Psoriatic Arthritis, Psoriasis, and Fibromyalgia Syndrome: The ULISSE Study. *J Rheumatol* 2019; 46: 904–911
- [117] Michelsen B, Diamantopoulos AP, Hammer HB et al. Ultrasonographic evaluation in psoriatic arthritis is of major importance in evaluating disease activity. *Ann Rheum Dis* 2016; 75: 2108–2113
- [118] Delle Sedie A, Riente L, Filippucci E et al. Ultrasound imaging for the rheumatologist XXVI. Sonographic assessment of the knee in patients with psoriatic arthritis. *Clin Exp Rheumatol* 2010; 28: 147–152
- [119] Iagnocco A, Spadaro A, Marchesoni A et al. Power Doppler ultrasonographic evaluation of enthesitis in psoriatic arthritis. A multi-center study. *Joint Bone Spine* 2012; 79: 323–334
- [120] Balint PV, Terslev L, Aegerter P et al. Reliability of a consensus-based ultrasound definition and scoring for enthesitis in spondyloarthritis and psoriatic arthritis: an OMERACT US initiative. *Ann Rheum Dis* 2018; 77: 1730–1735
- [121] D’Agostino MA, Said-Nahal R, Hacquard-Bouder C et al. Assessment of peripheral enthesitis in the spondylarthropathies by ultrasonography combined with power Doppler – A cross-sectional study. *Arthritis Rheum* 2003; 48: 523–533
- [122] D’Agostino MA, Aegerter P, Bechara K et al. How to diagnose spondyloarthritis early? Accuracy of peripheral enthesitis detection by power Doppler ultrasonography. *Ann Rheum Dis* 2011; 70: 1433–1440
- [123] Falcao S, Castillo-Gallego C, Peiteado D et al. Can we use enthesitis ultrasound as an outcome measure of disease activity in spondyloarthritis? A study at the Achilles level. *Rheumatology* 2015; 54: 1557–1562
- [124] Hu Z, Xu M, Wang Q et al. Colour Doppler ultrasonography can be used to detect the changes of sacroiliitis and peripheral enthesitis in patients with ankylosing spondylitis during adalimumab treatment. *Clin Exp Rheumatol* 2015; 33: 844–850
- [125] Wink F, Bruyn GA, Maas F et al. Ultrasound Evaluation of the Entheses in Daily Clinical Practice during Tumor Necrosis Factor-alpha Blocking Therapy in Patients with Ankylosing Spondylitis. *J Rheumatol* 2017; 44: 587–593
- [126] Hartung W, Nigg A, Strunk J et al. Clinical assessment and ultrasonography in the follow-up of enthesitis in patients with spondyloarthritis: a multicenter ultrasound study in daily clinical practice. *Open Access Rheumatol* 2018; 10: 161–169
- [127] Ozsoy Unubol T, Yagci I. Is ultrasonographic enthesitis evaluation helpful for diagnosis of non-radiographic axial spondyloarthritis? *Rheumatol Int* 2018; 38: 2053–2061
- [128] Perrotta FM, Astorri D, Zappia M et al. An ultrasonographic study of enthesitis in early psoriatic arthritis patients naive to traditional and biologic DMARDs treatment. *Rheumatol Int* 2016; 36: 1579–1583
- [129] Poulain C, D’Agostino MA, Thibault S et al. Can power Doppler ultrasound of the entheses help in classifying recent axial spondyloarthritis? Data from the DESIR cohort. *RMD Open* 2018; 4: e000686
- [130] Sakellariou G, Iagnocco A, Delle Sedie A et al. Ultrasonographic evaluation of entheses in patients with spondyloarthritis: a systematic literature review. *Clin Exp Rheumatol* 2014; 32: 969–978
- [131] Baccouche K, Mani L, Elamri N et al. Musculoskeletal ultrasonography of the Achilles tendon and plantar fascia in spondyloarthritis patients. *Egypt Rheumatol* 2018; 40: 249–253
- [132] Ezzat Y, Gaber W, EL-Rahman SFA et al. Ultrasonographic evaluation of lower limb enthesitis in patients with early spondyloarthropathies. *Egypt Rheumatol* 2013; 35: 29–35
- [133] Spadaro A, Iagnocco A, Perrotta FM et al. Clinical and ultrasonography assessment of peripheral enthesitis in ankylosing spondylitis. *Rheumatology (Oxford)* 2011; 50: 2080–2086
- [134] Moshrif A, Mosallam A, Mohamed EE et al. Subclinical enthesopathy in patients with psoriasis and its association with other disease parameters: a power Doppler ultrasonographic study. *Eur J Rheumatol* 2017; 4: 24–28
- [135] Marchesoni A, De Lucia O, Rotunno L et al. Enthesial Power Doppler Ultrasonography: A Comparison of Psoriatic Arthritis and Fibromyalgia. *J Rheumatol Suppl* 2012; 39: 29–31
- [136] Hamdy M, Omar G, Elshereef RR et al. Early detection of spondyloarthropathy in patients with psoriasis by using the ultrasonography and magnetic resonance image. *Eur J Rheumatol* 2015; 2: 10–15
- [137] Alcalde M, Acebes JC, Cruz M et al. A Sonographic Enthesitic Index of lower limbs is a valuable tool in the assessment of ankylosing spondylitis. *Ann Rheum Dis* 2007; 66: 1015–1019
- [138] de Miguel E, Muñoz-Fernández S, Castillo C et al. Diagnostic accuracy of enthesitis ultrasound in the diagnosis of early spondyloarthritis. *Ann Rheum Dis* 2011; 70: 434–439
- [139] Milutinovic S, Radunovic G, Veljkovic K et al. Construct validity and sensitivity to change of Belgrade Ultrasound Enthesitis Score in patients with spondyloarthritis: a pilot study. *Rheumatol Int* 2018; 38: 383–391
- [140] Ruta S, Acosta Felquer ML, Rosa J et al. Responsiveness to therapy change of a global ultrasound assessment in spondyloarthritis patients. *Clin Rheumatol* 2015; 34: 125–132
- [141] Aydin SZ, Karadag O, Filippucci E et al. Monitoring Achilles enthesitis in ankylosing spondylitis during TNF-alpha antagonist therapy: an ultrasound study. *Rheumatology (Oxford)* 2010; 49: 578–582
- [142] Naredo E, Batlle-Gualda E, García-Vivar ML et al. Power Doppler ultrasonography assessment of entheses in spondyloarthropathies: response to therapy of enthesial abnormalities. *J Rheumatol* 2010; 37: 2110–2117
- [143] Litinsky I, Balbir-Gurman A, Wollman J et al. Ultrasound assessment of enthesitis thickening in psoriatic arthritis patients treated with adalimumab compared to methotrexate. *Clin Rheumatol* 2016; 35: 363–370
- [144] Vahidfar S, Sunar I, Ataman S et al. Ultrasonographic evaluation of Achilles tendon: Is there any difference between ankylosing spondylitis, non-radiographic axial spondyloarthropathy and controls? *Int J Rheum Dis* 2020; 23: 511–519
- [145] Falsetti P, Frediani B, Fioravanti A et al. Sonographic study of calcaneal entheses in erosive osteoarthritis, nodal osteoarthritis, rheumatoid arthritis and psoriatic arthritis. *Scand J Rheumatol* 2003; 32: 229–234
- [146] Frediani B, Falsetti P, Storri L et al. Ultrasound and clinical evaluation of quadriceps tendon enthesitis in patients with psoriatic arthritis and rheumatoid arthritis. *Clin Rheumatol* 2002; 21: 294–298
- [147] Groves C, Chandramohan M, Chew NS et al. Clinical Examination, Ultrasound and MRI Imaging of The Painful Elbow in Psoriatic Arthritis and Rheumatoid Arthritis: Which is Better, Ultrasound or MR, for Imaging Enthesitis? *Rheumatol Ther* 2017; 4: 71–84
- [148] Oguz ID, Gul U, Koparal SS et al. Investigation of Enthesopathy with Ultrasonography and Comparison with Skin Findings in Asymptomatic Psoriatic Patients. *Dermatology* 2016; 232: 312–318
- [149] Tinazzi I, McGonagle D, Zabotti A et al. Comprehensive evaluation of finger flexor tendon enthesial soft tissue and bone changes by ultrasound can differentiate psoriatic arthritis and rheumatoid arthritis. *Clin Exp Rheumatol* 2018; 36: 785–790
- [150] Tom S, Zhong Y, Cook R et al. Development of a Preliminary Ultrasonographic Enthesitis Score in Psoriatic Arthritis – GRAPPA Ultrasound Working Group. *J Rheumatol* 2019; 46: 384–390
- [151] Ibrahim G, Groves C, Chandramohan M et al. Clinical and ultrasound examination of the leeds enthesitis index in psoriatic arthritis and rheumatoid arthritis. *ISRN Rheumatol* 2011; 2011: 731917

- [152] Fournie B, Margarit-Coll N, de Ribes TLC et al. Extrasynovial ultrasound abnormalities in the psoriatic finger. Prospective comparative power-doppler study versus rheumatoid arthritis. *Joint Bone Spine* 2006; 73: 527–531
- [153] Harman H, Suleyman E. Features of the Achilles tendon, paratenon, and enthesitis in inflammatory rheumatic diseases. A clinical and ultrasonographic study. *Z Rheumatol* 2018; 77: 511–521
- [154] Ivanoski S, Nikodinovska VV. Sonographic assessment of the anatomy and common pathologies of clinically important bursae. *J Ultrason* 2019; 19: 212–221
- [155] Ruangchaijatuporn T, Gaetke-Udager K, Jacobson JA et al. Ultrasound evaluation of bursae: anatomy and pathological appearances. *Skeletal Radiol* 2017; 46: 445–462
- [156] Gao YY, Wu CQ, Liu WX et al. High-resolution Sonographic Measurements of Lower Extremity Bursae in Chinese Healthy Young Men. *Chin Med J* 2016; 129: 309–312
- [157] Situ-LaCasse E, Grieger RW, Crabbe S et al. Utility of point-of-care musculoskeletal ultrasound in the evaluation of emergency department musculoskeletal pathology. *World J Emerg Med* 2018; 9: 262–266
- [158] Iagnocco A, Filippucci E, Sakellariou G et al. Ultrasound imaging for the rheumatologist XLIV. Ultrasound of the shoulder in healthy individuals. *Clin Exp Rheumatol* 2013; 31: 165–171
- [159] Wang L, Xiang X, Tang Y et al. Sonographic appearance of fluid in peripheral joints and bursae of healthy asymptomatic Chinese population. *Quant Imaging Med Surg* 2018; 8: 781–787
- [160] Draghi F, Scudeller L, Draghi AG et al. Prevalence of subacromial-subdeltoid bursitis in shoulder pain: an ultrasonographic study. *J Ultrasound* 2015; 18: 151–158
- [161] Singh H, Yuvarajan P, Maini L et al. Evaluation of ultrasound as a tool for etiological diagnosis of painful arc syndrome. *J Clin Orthop Trauma* 2010; 1: 81–84
- [162] Dasgupta B, Cimmino MA, Maradit-Kremers H et al. 2012 provisional classification criteria for polymyalgia rheumatica: a European League Against Rheumatism/American College of Rheumatology collaborative initiative. *Ann Rheum Dis* 2012; 71: 484–492
- [163] Mackie SL, Koduri G, Hill CL et al. Accuracy of musculoskeletal imaging for the diagnosis of polymyalgia rheumatica: systematic review. *RMD Open* 2015; 1: e000100
- [164] Sakellariou G, Iagnocco A, Riente L et al. Ultrasound imaging for the rheumatologist XLIII. Ultrasonographic evaluation of shoulders and hips in patients with polymyalgia rheumatica: a systematic literature review. *Clin Exp Rheumatol* 2013; 31: 1–7
- [165] Suzuki T, Yoshida R, Hidaka Y et al. Proliferative Synovitis of the Shoulder Bursae is a Key Feature for Discriminating Elderly Onset Rheumatoid Arthritis Mimicking Polymyalgia Rheumatica From Polymyalgia Rheumatica. *Clin Med Insights Arthritis Musculoskelet Disord* 2017; 10: 1179544117745851
- [166] Falsetti P, Acciai C, Volpe A et al. Ultrasonography in early assessment of elderly patients with polymyalgic symptoms: a role in predicting diagnostic outcome? *Scand J Rheumatol* 2011; 40: 57–63
- [167] Ayano M, Arinobu Y, Tsukamoto H. Shoulder ultrasound and serum lactate dehydrogenase predict inadequate response to glucocorticoid treatment in patients with polymyalgia rheumatica. *Rheumatol Int* 2020; 40: 1101–1109
- [168] Schraner AB, Major NM. MR imaging of the subcoracoid bursa. *Am J Roentgenol* 1999; 172: 1567–1571
- [169] Meraj S, Bencardino JT, Steinbach L. Imaging of cysts and bursae about the shoulder. *Semin Musculoskelet Radiol* 2014; 18: 436–447
- [170] Yap SH, Griffith JF, Lee RKL. Imaging bicipitoradial bursitis: a pictorial essay. *Skeletal Radiol* 2019; 48: 5–10
- [171] Espiga X, Alentorn-Geli E, Lozano C et al. Symptomatic bicipitoradial bursitis: a report of two cases and review of the literature. *J Shoulder Elbow Surg* 2011; 20: e5–e9
- [172] Kegels L, Van Oyen J, Siemons W et al. Bicipitoradial bursitis. A case report. *Acta Orthop Belg* 2006; 72: 362–365
- [173] Blackwell JR, Hay BA, Bolt AM et al. Olecranon bursitis: a systematic overview. *Shoulder Elbow* 2014; 6: 182–190
- [174] Reilly D, Kamineni S. Olecranon bursitis. *J Shoulder Elbow Surg* 2016; 25: 158–167
- [175] Blankstein A, Ganel A, Givon U et al. Ultrasonographic findings in patients with olecranon bursitis. *Ultraschall in Med* 2006; 27: 568–571
- [176] Harris-Spinks C, Nabhan D, Khodae M. Noniatrogenic Septic Olecranon Bursitis: Report of Two Cases and Review of the Literature. *Curr Sports Med Rep* 2016; 15: 33–37
- [177] Falasca GF. Metabolic diseases: gout. *Clin Dermatol* 2006; 24: 498–508
- [178] Özdemiř G, Deveci A, Andıç K et al. Bilateral Olecranon Tophaceous Gout Bursitis. *Case Rep Med* 2017; 2017: 3514796
- [179] Patel J, Girishkumar B, Mruthyunjaya P et al. Bilateral Olecranon Bursitis – A Rare Clinical presentation of Calcium Pyrophosphate Crystal Deposition Disease. *J Orthop Case Rep* 2014; 4: 3–6
- [180] Tormenta S, Sconfienza LM, Iannesi F et al. Prevalence study of iliopsoas bursitis in a cohort of 860 patients affected by symptomatic hip osteoarthritis. *Ultrasound Med Biol* 2012; 38: 1352–1356
- [181] Douis H, Dunlop DJ, Pearson AM et al. The role of ultrasound in the assessment of post-operative complications following hip arthroplasty. *Skeletal Radiol* 2012; 41: 1035–1046
- [182] Wunderbaldinger P, Bremer C, Schellenberger E et al. Imaging features of iliopsoas bursitis. *Eur Radiol* 2002; 12: 409–415
- [183] Long SS, Surrey DE, Nazarian LN. Sonography of greater trochanteric syndrome and the rarity of primary bursitis. *Am J Roentgenol* 2013; 201: 1083–1086
- [184] Ruta S, Quiroz C, Marin J et al. Ultrasound Evaluation of the Greater Trochanter Pain Syndrome Bursitis or Tendinopathy? *J Clin Rheumatol* 2015; 21: 99–101
- [185] Ramirez J, Pomes I, Sobrino-Guijarro B et al. Ultrasound evaluation of greater trochanter pain syndrome in patients with spondyloarthritis: Are there any specific features? *Rheumatol Int* 2014; 34: 947–952
- [186] Fearon AM, Scarvell JM, Cook JL et al. Does Ultrasound Correlate with Surgical or Histologic Findings in Greater Trochanteric Pain Syndrome? A Pilot Study. *Clin Orthop Relat Res* 2010; 468: 1838–1844
- [187] Draghi F, Corti R, Urciuoli L et al. Knee bursitis: a sonographic evaluation. *J Ultrasound* 2015; 18: 251–257
- [188] Uysal F, Akbal A, Gökmen F et al. Prevalence of pes anserine bursitis in symptomatic osteoarthritis patients: an ultrasonographic prospective study. *Clin Rheumatol* 2015; 34: 529–533
- [189] Handy JR. Popliteal cysts in adults: A review. *Semin Arthritis Rheum* 2001; 31: 108–118
- [190] Falcao S, de Miguel E, Castillo-Gallego C et al. Achilles enthesitis ultrasound: the importance of the bursa in spondyloarthritis. *Clin Exp Rheumatol* 2013; 31: 422–427
- [191] Hooper L, Bowen CJ, Gates L et al. Comparative Distribution of Ultrasound-Detectable Forefoot Bursae in Patients with Osteoarthritis and Rheumatoid Arthritis. *Arthritis Care Res* 2014; 66: 869–877
- [192] Bowen CJ, Hooper L, Culliford D et al. Assessment of the Natural History of Forefoot Bursae Using Ultrasonography in Patients With Rheumatoid Arthritis: A Twelve-Month Investigation. *Arthritis Care Res* 2010; 62: 1756–1762
- [193] Iagnocco A, Coari G, Palombi G et al. Sonography in the study of metatarsalgia. *J Rheumatol* 2001; 28: 1338–1340

- [194] Hetta WM, Niazi G. Concordance of US and MRI for diagnosis of ligamentous and tendinous injuries around the ankle. *Egypt J Radiol Nucl Med* 2018; 49: 131–137
- [195] Boutry N, Lapegue F, Masi L et al. Ultrasonographic evaluation of normal extrinsic and intrinsic carpal ligaments: preliminary experience. *Skeletal Radiol* 2005; 34: 513–521
- [196] Shalaby MH, Sharara SM, Abdelbary MH. High resolution ultrasonography in ankle joint pain: Where does it stand? *Egypt J Radiol Nucl Med* 2017; 48: 645–652
- [197] Kemmochi M, Sasaki S, Fujisaki K et al. A new classification of anterior talofibular ligament injuries based on ultrasonography findings. *J Orthop Sci* 2016; 21: 770–778
- [198] Radwan A, Bakowski J, Dew S et al. Effectiveness of ultrasonography in diagnosing chronic lateral ankle instability: a systematic review. *Int J Sports Phys Ther* 2016; 11: 164–174
- [199] Lee SH, Yun SJ. The feasibility of point-of-care ankle ultrasound examination in patients with recurrent ankle sprain and chronic ankle instability: Comparison with magnetic resonance imaging. *Injury* 2017; 48: 2323–2328
- [200] Elkaïm M, Thès A, Lopes R et al. Agreement between arthroscopic and imaging study findings in chronic anterior talo-fibular ligament injuries. *Orthop Traumatol Surg Res* 2018; 104: S213–S218
- [201] Cheng Y, Cai Y, Wang Y. Value of ultrasonography for detecting chronic injury of the lateral ligaments of the ankle joint compared with ultrasonography findings. *Br J Radiol* 2014; 87: 20130406
- [202] Cao S, Wang C, Ma X et al. Imaging diagnosis for chronic lateral ankle ligament injury: a systemic review with meta-analysis. *J Orthop Surg Res* 2018; 13: 122
- [203] Rosa I, Rodeia J, Fernandes PX et al. Ultrasonographic Assessment of Deltoid Ligament Integrity in Ankle Fractures. *Foot Ankle Int* 2020; 41: 147–153
- [204] Sconfienza LM, Orlandi D, Lacelli F et al. Dynamic high-resolution US of ankle and midfoot ligaments: normal anatomic structure and imaging technique. *Radiographics* 2015; 35: 164–178
- [205] Marshall JJ, Graves NC, Rettedal DD et al. Ultrasound assessment of bilateral symmetry in dorsal Lisfranc ligament. *J Foot Ankle Surg* 2013; 52: 319–323
- [206] Kaicker J, Zajac M, Shergill R et al. Ultrasound appearance of the normal Lisfranc ligament. *Emerg Radiol* 2016; 23: 609–614
- [207] Faruch Bilfeld M, Cavaignac E, Wytrykowski K et al. Anterolateral ligament injuries in knees with an anterior cruciate ligament tear: Contribution of ultrasonography and MRI. *Eur Radiol* 2018; 28: 58–65
- [208] Cavaignac E, Faruch M, Wytrykowski K et al. Ultrasonographic Evaluation of Anterolateral Ligament Injuries: Correlation With Magnetic Resonance Imaging and Pivot-Shift Testing. *Arthroscopy* 2017; 33: 1384–1390
- [209] Kandel M, Cattrysse E, De Maeseneer M et al. Inter-rater reliability of an ultrasound protocol to evaluate the anterolateral ligament of the knee. *J Ultrason* 2019; 19: 181–186
- [210] Zhang GY, Zheng L, Ding HY et al. Evaluation of medial patellofemoral ligament tears after acute lateral patellar dislocation: comparison of high-frequency ultrasound and MR. *Eur Radiol* 2015; 25: 274–281
- [211] Lack S, Anthony L, Noake J et al. Medial and Lateral Patellofemoral Joint Retinaculum Thickness in People With Patellofemoral Pain: A Case-Control Study. *J Ultrasound Med* 2019; 38: 1483–1490
- [212] Lee SH, Yun SJ. Efficiency of knee ultrasound for diagnosing anterior cruciate ligament and posterior cruciate ligament injuries: a systematic review and meta-analysis. *Skeletal Radiol* 2019; 48: 1599–1610
- [213] Wang J, Wu H, Dong F et al. The role of ultrasonography in the diagnosis of anterior cruciate ligament injury: A systematic review and meta-analysis. *Eur J Sport Sci* 2018; 18: 579–586
- [214] Fenkl R, Gotzen L. Sonographic diagnosis of the injured acromioclavicular joint A standardized examination procedure. *Unfallchirurg* 1992; 95: 393–400
- [215] Kock HJ, Jurgens C, Hirche H et al. Standardized ultrasound examination for evaluation of instability of the acromioclavicular joint. *Arch Orthop Trauma Surg* 1996; 115: 136–140
- [216] Faruch Bilfeld M, Lapegue F, Chiavassa Gandois H et al. Ultrasound of the coracoclavicular ligaments in the acute phase of an acromioclavicular disjunction: Comparison of radiographic, ultrasound and MRI findings. *Eur Radiol* 2017; 27: 483–490
- [217] Homsí C, Bordalo-Rodrigues M, da Silva JJ et al. Ultrasound in adhesive capsulitis of the shoulder: is assessment of the coracohumeral ligament a valuable diagnostic tool? *Skeletal Radiol* 2006; 35: 673–678
- [218] Wu CH, Chang KV, Su PH et al. Dynamic ultrasonography to evaluate coracoacromial ligament displacement during motion in shoulders with supraspinatus tendon tears. *J Orthop Res* 2012; 30: 1430–1434
- [219] Farrow LD, Mahoney AP, Sheppard JE et al. Sonographic assessment of the medial ulnar collateral ligament distal ulnar attachment. *J Ultrasound Med* 2014; 33: 1485–1490
- [220] Hendawi TK, Rendos NK, Warrell CS et al. Medial elbow stability assessment after ultrasound-guided ulnar collateral ligament transection in a cadaveric model: ultrasound versus stress radiography. *J Shoulder Elbow Surg* 2019; 28: 1154–1158
- [221] Park JY, Kim H, Lee JH et al. Valgus stress ultrasound for medial ulnar collateral ligament injuries in athletes: is ultrasound alone enough for diagnosis? *J Shoulder Elbow Surg* 2020; 29: 578–586
- [222] Camerlinck M, Vanhoenacker FM, Kiekens G. Ultrasound demonstration of Struthers' ligament. *J Clin Ultrasound* 2010; 38: 499–502
- [223] Griffith JF, Chan DP, Ho PC et al. Sonography of the normal scapholunate ligament and scapholunate joint space. *J Clin Ultrasound* 2001; 29: 223–229
- [224] Dao KD, Solomon DJ, Shin AY et al. The efficacy of ultrasound in the evaluation of dynamic scapholunate ligamentous instability. *J Bone Joint Surg Am* 2004; 86: 1473–1478
- [225] Gondim Teixeira PA, Omoumi P, Trudell DJ et al. High-resolution ultrasound evaluation of the trapeziometacarpal joint with emphasis on the anterior oblique ligament (beak ligament). *Skeletal Radiol* 2011; 40: 897–904
- [226] Mattox R, Welk AB, Battaglia PJ et al. Sonographic diagnosis of an acute Stener lesion: a case report. *J Ultrasound* 2016; 19: 149–152
- [227] Karabay N, Kayalar M, Ada S. Sonographic assessment of transverse carpal ligament after open surgical release of the carpal tunnel. *Acta Orthop Traumatol Turc* 2013; 47: 73–78
- [228] Lee SH, Yun SJ. Point-of-care wrist ultrasonography in trauma patients with ulnar-sided pain and instability. *Am J Emerg Med* 2018; 36: 859–864
- [229] Türker T, Sheppard JE, Klauser AS et al. The radial and ulnar collateral ligaments of the wrist are true ligaments. *Diagn Interv Radiol* 2019; 25: 473–479
- [230] Klauser A, Bodner G, Frauscher F et al. Finger injuries in extreme rock climbers. Assessment of high-resolution ultrasonography. *Am J Sports Med* 1999; 27: 733–737
- [231] Klauser A, Frauscher F, Bodner G et al. Finger pulley injuries in extreme rock climbers: depiction with dynamic US. *Radiology* 2002; 222: 755–761
- [232] Bianchi S, Gitto S, Draghi F. Ultrasound Features of Trigger Finger: Review of the Literature. *J Ultrasound Med* 2019; 38: 3141–3154
- [233] Klauser A, Stadlbauer KH, Frauscher F et al. Value of transducer positions in the measurement of finger flexor tendon thickness by sonography. *J Ultrasound Med* 2004; 23: 331–337

- [234] Klauser A, Fruscher F, Bodner G et al. Value of high-resolution ultrasound in the evaluation of finger injuries in extreme sport climbers. *Ultraschall in Med* 2000; 21: 73–78
- [235] Martinoli C, Perez MM, Bignotti B et al. Imaging finger joint instability with ultrasound. *Semin Musculoskelet Radiol* 2013; 17: 466–476
- [236] Tom S, Zhong Y, Cook R et al. Development of a Preliminary Ultrasonographic Enthesitis Score in Psoriatic Arthritis – GRAPPA Ultrasound Working Group. *J Rheumatol* 2019; 46: 384–390
- [237] Bakirci S, Solmaz D, Stephenson W et al. Enteseal Changes in Response to Age, Body Mass Index, and Physical Activity: An Ultrasound Study in Healthy People. *J Rheumatol* 2020; 47: 968–972
- [238] Döhn UM, Terslev L, Szkudlarek M et al. Detection, scoring and volume assessment of bone erosions by ultrasonography in rheumatoid arthritis: comparison with CT. *Ann Rheum Dis* 2013; 72: 530–534
- [239] Hassan R, Hussain S, Bacha R et al. Reliability of Ultrasound for the Detection of Rheumatoid Arthritis. *J Med Ultrasound* 2019; 27: 3–12
- [240] Zayat AS, Ellegaard K, Conaghan PG et al. The specificity of ultrasound-detected bone erosions for rheumatoid arthritis. *Ann Rheum Dis* 2015; 74: 897–903
- [241] Grosse J, Allado E, Roux C et al. ACPA-positive versus ACPA-negative rheumatoid arthritis: two distinct erosive disease entities on radiography and ultrasonography. *Rheumatol Int* 2020; 40: 615–624
- [242] Moraux A, Gitto S, Bianchi S. Ultrasound Features of the Normal and Pathologic Periosteum. *J Ultrasound Med* 2019; 38: 775–784
- [243] Hoffman DF, Adams E, Bianchi S. Ultrasonography of fractures in sports medicine. *Br J Sports Med* 2015; 49: 152–160
- [244] Yousefifard M, Baikpour M, Ghelichkhani P et al. Comparison of Ultrasonography and Radiography in Detection of Thoracic Bone Fractures; a Systematic Review and Meta-Analysis. *Emerg (Tehran)* 2016; 4: 55–64
- [245] Tsou PY, Ma YK, Wang YH et al. Diagnostic accuracy of ultrasound for upper extremity fractures in children: A systematic review and meta-analysis. *Am J Emerg Med* 2020. doi:10.1016/j.ajem.2020.04.071
- [246] Wright AA, Hegedus EJ, Lenchik L et al. Diagnostic Accuracy of Various Imaging Modalities for Suspected Lower Extremity Stress Fractures: A Systematic Review With Evidence-Based Recommendations for Clinical Practice. *Am J Sports Med* 2016; 44: 255–263
- [247] Fischer C, Preuss EM, Tanner M et al. Dynamic contrast-enhanced sonography and dynamic contrast-enhanced magnetic resonance imaging for preoperative diagnosis of infected nonunions. *J Ultrasound Med* 2016; 35: 933–942
- [248] Pozza S, De Marchi A, Albertin C et al. Technical and clinical feasibility of contrast-enhanced ultrasound evaluation of long bone non-infected nonunion healing. *Radiol Med* 2018; 123: 703–709
- [249] Silvestri E, Martinoli C, Derchi LE et al. Echotexture of peripheral nerves: correlation between US and histologic findings and criteria to differentiate tendons. *Radiology* 1995; 197: 291–296
- [250] Agarwal A, Chandra A, Jaipal U et al. Can imaging be the new yardstick for diagnosing peripheral neuropathy? A comparison between high resolution ultrasound and MR neurography with an approach to diagnosis. *Insights Imaging* 2019; 10: 104
- [251] Agarwal A, Chandra A, Jaipal U et al. A panorama of radial nerve pathologies- an imaging diagnosis: a step ahead. *Insights Imaging* 2018; 9: 1021–1034
- [252] Agarwal A, Chandra A, Jaipal U et al. Imaging in the diagnosis of ulnar nerve pathologies-a neoteric approach. *Insights Imaging* 2019; 10: 37
- [253] Brown JM, Yablon CM, Morag Y et al. US of the Peripheral Nerves of the Upper Extremity: A Landmark Approach. *Radiographics* 2016; 36: 452–463
- [254] Picasso R, Zaottini F, Pistoia F et al. High-Resolution Ultrasound of Small Clinically Relevant Nerves Running Across the Posterior Triangle of the Neck. *Semin Musculoskelet Radiol* 2020; 24: 101–112
- [255] Koenig RW, Pedro MT, Heinen CP et al. High-resolution ultrasonography in evaluating peripheral nerve entrapment and trauma. *Neurosurg Focus* 2009; 26: E13
- [256] Martinoli C, Bianchi S, Gandolfo N et al. US of nerve entrapments in osteofibrous tunnels of the upper and lower limbs. *Radiographics* 2000; 20: S199–213
- [257] Mallon S, Starcevic V, Rheinboldt M et al. Sonographic evaluation of peripheral nerve pathology in the emergency setting. *Emerg Radiol* 2018; 25: 521–531
- [258] Choi SJ, Ahn JH, Ryu DS et al. Ultrasonography for nerve compression syndromes of the upper extremity. *Ultrasonography* 2015; 34: 275–291
- [259] Chen YT, Williams L, Zak MJ et al. Review of Ultrasonography in the Diagnosis of Carpal Tunnel Syndrome and a Proposed Scanning Protocol. *J Ultrasound Med* 2016; 35: 2311–2324
- [260] Baute Penry V, Cartwright MS. Neuromuscular Ultrasound for Peripheral Neuropathies. *Semin Neurol* 2019; 39: 542–548
- [261] Powell GM, Baffour FI, Erie AJ et al. Sonographic evaluation of the lateral femoral cutaneous nerve in meralgia paresthetica. *Skeletal Radiol* 2020; 49: 1135–1140
- [262] Akcar N, Ozkan S, Mehmetoglu O et al. Value of power Doppler and gray-scale US in the diagnosis of carpal tunnel syndrome: contribution of cross-sectional area just before the tunnel inlet as compared with the cross-sectional area at the tunnel. *Korean J Radiol* 2010; 11: 632–639
- [263] Klauser AS, Halpern EJ, De Zordo T et al. Carpal tunnel syndrome assessment with US: value of additional cross-sectional area measurements of the median nerve in patients versus healthy volunteers. *Radiology* 2009; 250: 171–177
- [264] Klauser AS, Halpern EJ, Faschingbauer R et al. Bifid median nerve in carpal tunnel syndrome: assessment with US cross-sectional area measurement. *Radiology* 2011; 259: 808–815
- [265] Gruber H, Glodny B, Peer S. The validity of ultrasonographic assessment in cubital tunnel syndrome: the value of a cubital-to-humeral nerve area ratio (CHR) combined with morphologic features. *Ultrasound Med Biol* 2010; 36: 376–382
- [266] Cornelson SM, Sclocco R, Kettner NW. Ulnar nerve instability in the cubital tunnel of asymptomatic volunteers. *J Ultrasound* 2019; 22: 337–344
- [267] Chang KV, Wu WT, Han DS et al. Ulnar Nerve Cross-Sectional Area for the Diagnosis of Cubital Tunnel Syndrome: A Meta-Analysis of Ultrasonographic Measurements. *Arch Phys Med Rehabil* 2018; 99: 743–757
- [268] Chang KV, Mezian K, Naïka O et al. Ultrasound Imaging for the Cutaneous Nerves of the Extremities and Relevant Entrapment Syndromes: From Anatomy to Clinical Implications. *J Clin Med* 2018; 7: 457
- [269] Jakobsen RL, Fuglsang-Frederiksen A, Hellfritzsch MB et al. A prospective study of high-resolution ultrasound in brachial plexopathies – Correlation with electrophysiological measurements. *Clin Neurophysiol* 2019; 130: 1144–1150
- [270] Çelebi UO, Burulday V, Özveren MF et al. Sonoelastographic evaluation of the sciatic nerve in patients with unilateral lumbar disc herniation. *Skeletal Radiol* 2019; 48: 129–136
- [271] Bilgici A, Cokluk C, Aydın K. Ultrasound neurography in the evaluation of sciatic nerve injuries. *J Phys Ther Sci* 2013; 25: 1209–1211
- [272] Chen SF, Huang CR, Tsai NW et al. Ultrasonographic assessment of carpal tunnel syndrome of mild and moderate severity in diabetic patients by using an 8-point measurement of median nerve cross-sectional areas. *BMC Med Imaging* 2012; 12: 15
- [273] Kerasnoudis A, Pitarokoili K, Behrendt V et al. Cross-sectional area reference values for sonography of peripheral nerves and brachial plexus. *Clin Neurophysiol* 2013; 124: 1881–1888

- [274] Lee RKL, Griffith JF, Ng AWH et al. Cross-sectional area of the median nerve at the wrist: Comparison of sonographic, MRI, and cadaveric measurements. *J Clin Ultrasound* 2019; 47: 122–127
- [275] Mhoon JT, Juel VC, Hobson-Webb LD. Median nerve ultrasound as a screening tool in carpal tunnel syndrome: correlation of cross-sectional area measures with electrodiagnostic abnormality. *Muscle Nerve* 2012; 46: 871–878
- [276] O'Reilly MA, O'Reilly PM, Sheahan JN et al. Neuromas as the cause of pain in the residual limbs of amputees. An ultrasound study. *Clin Radiol* 2016; 71: 1068.e1–6
- [277] Chen KH, Lee KF, Hsu HC et al. The role of high-resolution ultrasound in the diagnosis of a traumatic neuroma in an injured median nerve. *Am J Phys Med Rehabil* 2009; 88: 771–774
- [278] Lauretti L, D'Alessandris QG, Granata G et al. Ultrasound evaluation in traumatic peripheral nerve lesions: from diagnosis to surgical planning and follow-up. *Acta Neurochir (Wien)* 2015; 157: 1947–1951
- [279] Kowalska B. Assessment of the utility of ultrasonography with high-frequency transducers in the diagnosis of posttraumatic neuropathies. *J Ultrason* 2015; 15: 15–28
- [280] Hollister AM, Simoncini A, Sciuk A et al. High frequency ultrasound evaluation of traumatic peripheral nerve injuries. *Neurol Res* 2012; 34: 98–103
- [281] Suh DH, Kim DH, Park JW et al. Sonographic and electrophysiologic findings in patients with meralgia paresthetica. *Clin Neurophysiol* 2013; 124: 1460–1464
- [282] Coraci D, Pazzaglia C, Doneddu PE et al. Post-traumatic neuroma due to closed nerve injury. Is recovery after peripheral nerve trauma related to ultrasonographic neuroma size? *Clin Neurol Neurosurg* 2015; 139: 314–318
- [283] Choi SY, Park JW, Kim DH. Ultrasonographic and Surgical Findings of Acute Radial Neuropathy Following Blunt Trauma. *Am J Phys Med Rehabil* 2016; 95: E177–E182
- [284] Di Pasquale A, Morino S, Loreti S et al. Peripheral nerve ultrasound changes in CIDP and correlations with nerve conduction velocity. *Neurology* 2015; 84: 803–809
- [285] Fisse AL, Pitarokoli K, Trampe N et al. Sonographic, and Electrophysiologic Longitudinal Features of Chronic Inflammatory Demyelinating Polyneuropathy. *J Neuroimaging* 2019; 29: 223–232
- [286] Hobson-Webb LD. Neuromuscular ultrasound in polyneuropathies and motor neuron disease. *Muscle Nerve* 2013; 47: 790–804
- [287] Goede HS, Brekelmans CJ, van Asseldonk JT et al. High resolution sonography in the evaluation of the peripheral nervous system in polyneuropathy—a review of the literature. *Eur J Neurol* 2013; 20: 1342–1351
- [288] Kerasnoudis A, Pitarokoli K, Behrendt V et al. Nerve ultrasound score in distinguishing chronic from acute inflammatory demyelinating polyneuropathy. *Clin Neurophysiol* 2014; 125: 635–641
- [289] Mori A, Nodera H, Takamatsu N et al. Sonographic evaluation of peripheral nerves in subtypes of Guillain-Barré syndrome. *J Neurol Sci* 2016; 364: 154–159
- [290] Grimm A, Décard BF, Axer H. Ultrasonography of the peripheral nervous system in the early stage of Guillain-Barré syndrome. *J Peripher Nerv Syst* 2014; 19: 234–241
- [291] Grimm A, Décard BF, Schramm A et al. Ultrasound and electrophysiologic findings in patients with Guillain-Barré syndrome at disease onset and over a period of six months. *Clin Neurophysiol* 2016; 127: 1657–1663
- [292] Martinoli C, Derchi LE, Bertolotto M et al. US and MR imaging of peripheral nerves in leprosy. *Skeletal Radiol* 2000; 29: 142–150
- [293] Martinoli C, Schenone A, Bianchi S et al. Sonography of the median nerve in Charcot-Marie-Tooth disease. *Am J Roentgenol* 2002; 178: 1553–1556
- [294] Padua L, Coraci D, Lucchetta M et al. Different nerve ultrasound patterns in charcot-marie-tooth types and hereditary neuropathy with liability to pressure palsies. *Muscle Nerve* 2018; 57: E18–E23
- [295] Yiu EM, Brockley CR, Lee KJ et al. Peripheral nerve ultrasound in pediatric Charcot-Marie-Tooth disease type 1A. *Neurology* 2015; 84: 569–574
- [296] Zanette G, Fabrizi GM, Taioli F et al. Nerve ultrasound findings differentiate Charcot-Marie-Tooth disease (CMT) 1A from other demyelinating CMTs. *Clin Neurophysiol* 2018; 129: 2259–2267
- [297] Bayrak AO, Bayrak IK, Battaloglu E et al. Ultrasonographic findings in hereditary neuropathy with liability to pressure palsies. *Neurol Res* 2015; 37: 106–111
- [298] Beekman R, Visser LH. Sonographic detection of diffuse peripheral nerve enlargement in hereditary neuropathy with liability to pressure palsies. *J Clin Ultrasound* 2002; 30: 433–436
- [299] Gruber H, Glodny B, Bendix N et al. High-resolution ultrasound of peripheral neurogenic tumors. *Eur Radiol* 2007; 17: 2880–2888
- [300] Lee SJ, Yoon ST. Ultrasonographic and Clinical Characteristics of Schwannoma of the Hand. *Clin Orthop Surg* 2017; 9: 91–95
- [301] Tagliafico AS, Isaac A, Bignotti B et al. Nerve Tumors: What the MSK Radiologist Should Know. *Semin Musculoskelet Radiol* 2019; 23: 76–84
- [302] Zhang H, Li Y, Shao J et al. High-Resolution Ultrasound of Schwannomas of the Limbs: Analysis of 72 Cases. *Ultrasound Med Biol* 2016; 42: 2538–2544
- [303] Yang F, Chen XX, Wu HL et al. Sonographic Features and Diagnosis of Peripheral Schwannomas. *J Clin Ultrasound* 2017; 45: 127–133
- [304] Ryu JA, Lee SH, Cha EY et al. Sonographic Differentiation Between Schwannomas and Neurofibromas in the Musculoskeletal System. *J Ultrason Med* 2015; 34: 2253–2260
- [305] Murphey MD, Smith WS, Smith SE et al. From the archives of the AFIP. Imaging of musculoskeletal neurogenic tumors: radiologic-pathologic correlation. *Radiographics* 1999; 19: 1253–1280
- [306] Pedro MT, Antoniadis G, Scheuerle A et al. Intraoperative high-resolution ultrasound and contrast-enhanced ultrasound of peripheral nerve tumors and tumorlike lesions. *Neurosurg Focus* 2015; 39: E5
- [307] Chiou HJ, Chou YH, Chiou SY et al. Peripheral nerve lesions: role of high-resolution US. *Radiographics* 2003; 23: e15
- [308] Wortsman X, Alfageme F, Roustan G et al. Guidelines for Performing Dermatologic Ultrasound Examinations by the DERMUS Group. *J Ultrasound Med* 2016; 35: 577–580
- [309] Alfageme F, Wortsman X, Catalano O et al. European Federation of Societies for Ultrasound in Medicine and Biology (EFSUMB) Position Statement on Dermatologic Ultrasound. *Ultraschall in Med* 2020. doi:10.1055/a-1161-8872
- [310] Crisan D, Lupsor M, Boca A et al. Ultrasonographic assessment of skin structure according to age. *Indian J Dermatol Venereol Leprol* 2012; 78: 519
- [311] Nedelec B, Forget NJ, Hurtubise T et al. Skin characteristics: normative data for elasticity, erythema, melanin, and thickness at 16 different anatomical locations. *Skin Res Technol* 2016; 22: 263–275
- [312] Sandby-Moller J, Wulf HC. Ultrasonographic subepidermal low-echogenic band, dependence of age and body site. *Skin Res Technol* 2004; 10: 57–63
- [313] Ambroziak M, Pietruski P, Noszczyk B et al. Ultrasonographic elastography in the evaluation of normal and pathological skin – a review. *Postepy Dermatol Alergol* 2019; 36: 667–672
- [314] Yang Y, Wang L, Yan F et al. Determination of Normal Skin Elasticity by Using Real-time Shear Wave Elastography. *J Ultrason Med* 2018; 37: 2507–2516
- [315] Wortsman X, Carreño L, Ferreira-Wortsman C et al. Ultrasound Characteristics of the Hair Follicles and Tracts, Sebaceous Glands, Montgomery Glands, Apocrine Glands, and Arrector Pili Muscles. *J Ultrason Med* 2019; 38: 1995–2004

- [316] Avetikov DS, Bukhanchenko OP, Skikevich MG et al. Features of ultrasound diagnostics of postoperative hypertrophic and keloid scars. *New Armen Med J* 2018; 12: 43–48
- [317] Agabalyan NA, Su S, Sinha S et al. Comparison between high-frequency ultrasonography and histological assessment reveals weak correlation for measurements of scar tissue thickness. *Burns* 2017; 43: 531–538
- [318] Dyson M, Moodley S, Verjee L et al. Wound healing assessment using 20 MHz ultrasound and photography. *Skin Res Technol* 2003; 9: 116–121
- [319] Caro RDC, Solivetti FM, Bianchi L. Power Doppler ultrasound assessment of vascularization in hidradenitis suppurativa lesions. *J Eur Acad Dermatol Venereol* 2018; 32: 1360–1367
- [320] Lacarrubba F, Dini V, Napolitano M et al. Ultrasonography in the pathway to an optimal standard of care of hidradenitis suppurativa: the Italian Ultrasound Working Group experience. *J Eur Acad Dermatol Venereol* 2019; 33: 10–14
- [321] Loo CH, Tan WC, Tang JJ et al. The clinical, biochemical, and ultrasonographic characteristics of patients with hidradenitis suppurativa in Northern Peninsular Malaysia: a multicenter study. *Int J Dermatol* 2018; 57: 1454–1463
- [322] Martorell A, Wortsman X, Alfageme F et al. Ultrasound Evaluation as a Complementary Test in Hidradenitis Suppurativa: Proposal of a Standardized Report. *Dermatol Surg* 2017; 43: 1065–1073
- [323] Martorell A, Roldan FA, Rull EV et al. Ultrasound as a diagnostic and management tool in hidradenitis suppurativa patients: a multicentre study. *J Eur Acad Dermatol Venereol* 2019; 33: 2137–2142
- [324] Nazzaro G, Passoni E, Calzari P et al. Color Doppler as a tool for correlating vascularization and pain in hidradenitis suppurativa lesions. *Skin Res Technol* 2019; 25: 830–834
- [325] Wortsman X, Moreno C, Soto R et al. Ultrasound In-Depth Characterization and Staging of Hidradenitis Suppurativa. *Dermatol Surg* 2013; 39: 1835–1842
- [326] Wortsman X, Castro A, Figueroa A. Color Doppler ultrasound assessment of morphology and types of fistulous tracts in hidradenitis suppurativa (HS). *J Am Acad Dermatol* 2016; 75: 760–767
- [327] Wortsman X, Rodriguez C, Lobos C et al. Ultrasound Diagnosis and Staging in Pediatric Hidradenitis Suppurativa. *Pediatr Dermatol* 2016; 33: e260–e264
- [328] Wortsman X, Calderon P, Castro A. Seventy-MHz Ultrasound Detection of Early Signs Linked to the Severity, Patterns of Keratin Fragmentation, and Mechanisms of Generation of Collections and Tunnels in Hidradenitis Suppurativa. *J Ultrasound Med* 2020; 39: 845–857
- [329] Alsaawi A, Alrajhi K, Alshehri A et al. Ultrasonography for the diagnosis of patients with clinically suspected skin and soft tissue infections: a systematic review of the literature. *Eur J Emerg Med* 2017; 24: 162–169
- [330] Barbic D, Chenkin J, Cho DD et al. In patients presenting to the emergency department with skin and soft tissue infections what is the diagnostic accuracy of point-of-care ultrasonography for the diagnosis of abscess compared to the current standard of care? A systematic review and meta-analysis. *Bmj Open* 2017; 7: e013688
- [331] Subramaniam S, Bober J, Chao J et al. Point-of-care Ultrasound for Diagnosis of Abscess in Skin and Soft Tissue Infections. *Acad Emerg Med* 2016; 23: 1298–1306
- [332] Berger T, Garrido F, Green J et al. Bedside ultrasound performed by novices for the detection of abscess in ED patients with soft tissue infections. *Am J Emerg Med* 2012; 30: 1569–1573
- [333] Gaspari R, Blehar D, Mendoza M et al. Use of Ultrasound Elastography for Skin and Subcutaneous Abscesses. *J Ultrasound Med* 2009; 28: 855–860
- [334] Mower WR, Crisp JC, Krishnadasan A et al. Effect of Initial Bedside Ultrasonography on Emergency Department Skin and Soft Tissue Infection Management. *Ann Emerg Med* 2019; 74: 372–380
- [335] Sulli A, Ruaro B, Smith V et al. Subclinical dermal involvement is detectable by high frequency ultrasound even in patients with limited cutaneous systemic sclerosis. *Arthritis Res Ther* 2017; 19: 61
- [336] Hesselstrand R, Carlestam J, Wildt M et al. High frequency ultrasound of skin involvement in systemic sclerosis – a follow-up study. *Arthritis Res Ther* 2015; 17: 329
- [337] Hesselstrand R, Scheja A, Wildt M et al. High-frequency ultrasound of skin involvement in systemic sclerosis reflects oedema, extension and severity in early disease. *Rheumatology* 2008; 47: 84–87
- [338] Kaloudi O, Bandinelli F, Filippucci E et al. High frequency ultrasound measurement of digital dermal thickness in systemic sclerosis. *Ann Rheum Dis* 2010; 69: 1140–1143
- [339] Santiago T, Santiago M, Coutinho M et al. How much of skin improvement over time in systemic sclerosis is due to normal ageing? A prospective study with shear-wave elastography. *Arthritis Res Ther* 2020; 22: 50
- [340] Akesson A, Hesselstrand R, Scheja A et al. Longitudinal development of skin involvement and reliability of high frequency ultrasound in systemic sclerosis. *Ann Rheum Dis* 2004; 63: 791–796
- [341] Li H, Furst DE, Jin H et al. High-frequency ultrasound of the skin in systemic sclerosis: an exploratory study to examine correlation with disease activity and to define the minimally detectable difference. *Arthritis Res Ther* 2018; 20: 181
- [342] Santiago T, Santiago M, Ruaro B et al. Ultrasonography for the Assessment of Skin in Systemic Sclerosis: A Systematic Review. *Arthritis Care Rese* 2019; 71: 563–574
- [343] Hou Y, Zhu QL, Liu H et al. A Preliminary Study of Acoustic Radiation Force Impulse Quantification for the Assessment of Skin in Diffuse Cutaneous Systemic Sclerosis. *J Rheumatol* 2015; 42: 449–455
- [344] Sobolewski P, Maslinska M, Zakrzewski J et al. Applicability of shear wave elastography for the evaluation of skin strain in systemic sclerosis. *Rheumatol Int* 2020; 40: 737–745
- [345] Wortsman X. Why, how, and when to use color Doppler ultrasound for improving precision in the diagnosis, assessment of severity and activity in morphea. *J Scleroderma Relat Disord* 2019; 4: 28–34
- [346] Arisi M, Lorenzi L, Incardona P et al. Clinical, histological and high-frequency ultrasonographic evaluation (50 MHz) of morphea treated with ultraviolet A1 phototherapy. *Clin Exp Dermatol* 2019; 44: 270–276
- [347] Chen HC, Kadono T, Mimura Y et al. High-frequency ultrasound as a useful device in the preliminary differentiation of lichen sclerosus et atrophicus from morphea. *J Dermatol* 2004; 31: 556–559
- [348] Wang L, Yan F, Yang Y et al. Quantitative assessment of skin stiffness in localized scleroderma using ultrasound shear-wave elastography. *Ultrasound Med Biol* 2017; 43: 1339–1347
- [349] Marina ME, Botar Jid C, Roman II et al. Ultrasonography in psoriatic disease. *Med Ultrason* 2015; 17: 377–382
- [350] Micali G, Lacarrubba F, Santagati C et al. Clinical, ultrasound, and videodermatoscopy monitoring of psoriatic patients following biological treatment. *Skin Res Technol* 2016; 22: 341–348
- [351] Lacarrubba F, Pellacani G, Gurgone S et al. Advances in non-invasive techniques as aids to the diagnosis and monitoring of therapeutic response in plaque psoriasis: a review. *Int J Dermatol* 2015; 54: 626–634
- [352] Cucos M, Crisan M, Lenghel M et al. Conventional ultrasonography and sonoelastography in the assessment of plaque psoriasis under topical corticosteroid treatment – work in progress. *Med Ultrason* 2014; 16: 107–113
- [353] Gutierrez M, De Angelis R, Bernardini ML et al. Clinical, power Doppler sonography and histological assessment of the psoriatic plaque: short-term monitoring in patients treated with etanercept. *Br J Dermatol* 2011; 164: 33–37

- [354] Dattola A, Altobelli S, Marsico S et al. Hypodermal Adipose Tissue Sonoelastography for Monitoring Treatment Response in Patients with Plaque Psoriasis. *Photomed Laser Surg* 2017; 35: 484–491
- [355] Hayashi A, Giacalone G, Yamamoto T et al. Ultra High-frequency Ultrasonographic Imaging with 70 MHz Scanner for Visualization of the Lymphatic Vessels. *Plast Reconstr Surg Glob Open* 2019; 7: e2086
- [356] Polat AV, Ozturk M, Polat AK et al. Efficacy of Ultrasound and Shear Wave Elastography for the Diagnosis of Breast Cancer-Related Lymphedema. *J Ultrasound Med* 2020; 39: 795–803
- [357] Naouri M, Samimi M, Atlan M et al. High-resolution cutaneous ultrasonography to differentiate lipoedema from lymphoedema. *Br J Dermatol* 2010; 163: 296–301
- [358] Iuchi T, Kobayashi M, Tsuchiya S et al. Objective assessment of leg edema using ultrasonography with a gel pad. *Plos One* 2017; 12: e0182042
- [359] Australian Cancer Database. Melanoma of the skin for Australia (ICD10 C43). Australian Cancer Incidence and Mortality (ACIM) Books. Canberra: Australian Institute of Health and Welfare, 2017. Online: <http://www.aihw.gov.au/acim-books>
- [360] Chaput L, Laurent E, Pare A et al. One-step surgical removal of cutaneous melanoma with surgical margins based on preoperative ultrasound measurement of the thickness of the melanoma. *Eur J Dermatol* 2018; 28: 202–208
- [361] Guitera P, Li LX, Crotty K et al. Melanoma histological Breslow thickness predicted by 75-MHz ultrasonography. *Br J Dermatol* 2008; 159: 364–369
- [362] Andrekute K, Valiukeviciene S, Raisutis R et al. Automated Estimation of Melanocytic Skin Tumor Thickness by Ultrasonic Radiofrequency Data. *J Ultrasound Med* 2016; 35: 857–865
- [363] Ribero S, Podlipnik S, Osella-Abate S et al. Ultrasound-based follow-up does not increase survival in early-stage melanoma patients: A comparative cohort study. *Eur J Cancer* 2017; 85: 59–66
- [364] Dinnes J, Ferrante di Ruffano L, Takwoingi Y et al. Ultrasound, CT, MRI, or PET-CT for staging and re-staging of adults with cutaneous melanoma. *Cochrane Database Syst Rev* 2019; 7: CD012806
- [365] Testori AAE, Chiellino S, van Akkooi ACJ. Adjuvant Therapy for Melanoma: Past, Current, and Future Developments. *Cancers (Basel)* 2020; 12: 1994
- [366] Wang SQ, Liu J, Zhu QL et al. High-frequency ultrasound features of basal cell carcinoma and its association with histological recurrence risk. *Chin Med J* 2019; 132: 2021–2026
- [367] Dinnes J, Bamber J, Chuchu N et al. High-frequency ultrasound for diagnosing skin cancer in adults. *Cochrane Database Syst Rev* 2018; 12: CD013188
- [368] Polanska A, Danczak-Pazdrowska A, Silny W et al. Comparison between high-frequency ultrasonography (Dermascan C, version 3) and histopathology in atopic dermatitis. *Skin Res Technol* 2013; 19: 432–437
- [369] Mandava A, Koppula V, Wortsman X et al. The clinical value of imaging in primary cutaneous lymphomas: Role of high resolution ultrasound and PET-CT. *Br J Radiol* 2019; 92: 20180904
- [370] Carrascosa R, Alfageme F, Roustan G et al. Skin Ultrasound in Kaposi Sarcoma. *Actas Dermosifiliogr* 2016; 107: e19–e22
- [371] Mujtaba B, Wang F, Taher A et al. Dermatofibrosarcoma Protuberans: Pathological and Imaging Review. *Curr Probl Diagn Radiol* 2020. doi:10.1067/j.cpradiol.2020.05.011
- [372] Wortsman X, Wortsman J, Arellano J et al. Pilomatrixomas presenting as vascular tumors on color Doppler ultrasound. *J Pediatr Surg* 2010; 45: 2094–2098
- [373] Solivetti FM, Desiderio F, Elia F et al. Sonographic appearance of sebaceous cysts. Our experience and a review of the literature. *Int J Dermatol* 2019; 58: 1353–1359
- [374] Rahmani G, McCarthy P, Bergin D. The diagnostic accuracy of ultrasonography for soft tissue lipomas: a systematic review. *Acta Radiol Open* 2017; 6: 2058460117716704
- [375] Raffin D, Zaragoza J, Georgescu G et al. High-frequency ultrasound imaging for cutaneous neurofibroma in patients with neurofibromatosis type I. *Eur J Dermatol* 2017; 27: 260–265
- [376] Romani J, Giavedoni P, Roe E et al. Inter- and Intra-rater Agreement of Dermatologic Ultrasound for the Diagnosis of Lobular and Septal Paniculitis. *J Ultrasound Med* 2020; 39: 107–112
- [377] Guerin-Moreau M, Leftheriotis G, Le Corre Y et al. High-frequency (20–50 MHz) ultrasonography of pseudoxanthoma elasticum skin lesions. *Br J Dermatol* 2013; 169: 1233–1239
- [378] Dybiec E, Pietrzak A, Bartosinska J et al. Ultrasound findings in cutaneous sarcoidosis. *Postepy Dermatol Alergol* 2015; 32: 51–55
- [379] Benjamin M. The fascia of the limbs and back—a review. *J Anat* 2009; 214: 1–18
- [380] Stecco C, Stern R, Porzionato A et al. Hyaluronan within fascia in the etiology of myofascial pain. *Surg Radiol Anat* 2011; 33: 891–896
- [381] Fede C, Gaudreault N, Fan C et al. Morphometric and dynamic measurements of muscular fascia in healthy individuals using ultrasound imaging: a summary of the discrepancies and gaps in the current literature. *Surg Radiol Anat* 2018; 40: 1329–1341
- [382] Santilli OL, Nardelli N, Santilli HA et al. Sports hernias: experience in a sports medicine center. *Hernia* 2016; 20: 77–84
- [383] Mohseni-Bandpei MA, Nakhaee M, Mousavi ME et al. Application of ultrasound in the assessment of plantar fascia in patients with plantar fasciitis: a systemic review. *Ultrasound Med Biol* 2014; 40: 1737–1754
- [384] Abul K, Ozer D, Sakizlioglu SS et al. Detection of Normal Plantar Fascia Thickness in Adults via the Ultrasonographic Method. *J Am Podiatr Med Assoc* 2015; 105: 8–13
- [385] Beggs I. Sonography of Muscle Hernias. *Am J Roentgenol* 2003; 180: 395–399
- [386] Bloemen A, van Dooren P, Huizinga BF et al. Comparison of ultrasonography and physical examination in the diagnosis of incisional hernia in a prospective study. *Hernia* 2012; 16: 53–57
- [387] Shubert AG. Exertional compartment syndrome: Review of the literature and proposed rehabilitation guidelines following surgical release. *Int J Sports Phys Ther* 2011; 6: 126–141
- [388] Wronski M, Slodkowski M, Cebulski W et al. Necrotizing Fasciitis: Early Sonographic Diagnosis. *J Clin Ultrasound* 2011; 39: 236–239
- [389] Lin CN, Hsiao CT, Chang CP et al. The relationship between fluid accumulation in ultrasonography and the diagnosis and prognosis of patients with necrotizing fasciitis. *Ultrasound Med Biol* 2019; 45: 1545–1550
- [390] Kissin EY, Garg A, Grayson PC et al. Ultrasound Assessment of Subcutaneous Compressibility A Potential Adjunctive Diagnostic Tool in Eosinophilic Fasciitis. *Jcr-J Clin Rheumatol* 2013; 19: 382–385
- [391] Chen IJ, Wang MT, Chang KV et al. Ultrasonographic images of the hand in a case with early eosinophilic fasciitis. *J Med Ultrason* 2018; 45: 641–645
- [392] Bedi DG, Davidson DM. Plantar fibromatosis: Most common sonographic appearance and variations. *J Clin Ultrasound* 2001; 29: 499–505
- [393] Cohen BE, Murthy NS, McKenzie GA. Ultrasonography of Plantar Fibromatosis: Updated Case Series, Review of the Literature, and a Novel Descriptive Appearance Termed the “Comb Sign”. *J Ultrasound Med* 2018; 37: 2725–2731
- [394] Ulusoy A, Tikiz C, Orguc S. Dupuytren’s Contracture With Rare Bilateral Thumb and Little Finger Involvement Demonstrated by Ultrasound Elastography. *Arch Rheumatol* 2015; 30: 357–360

- [395] Molenkamp S, Broekstra DC, Werker PMN. Echogenicity of Palmar Dupuytren's Nodules Is Not a Predictor of Disease Progression in Terms of Increase in Nodule Size. *Plast Reconstruct Surg* 2019; 143: 814–820
- [396] Lee KJ, Jin W, Kim GY et al. Sonographic Features of Superficial-Type Nodular Fasciitis in the Musculoskeletal System. *J Ultrasound Med* 2015; 34: 1465–1471
- [397] Khuu A, Yablon CM, Jacobson JA et al. Nodular Fasciitis Characteristic Imaging Features on Sonography and Magnetic Resonance Imaging. *J Ultrasound Med* 2014; 33: 565–573
- [398] Yen HH, Chiou HJ, Chou YH et al. Nodular fasciitis: sonographic-pathologic correlation. *Ultrasound Med Biol* 2017; 43: 860–867
- [399] Hseu A, Watters K, Perez-Atayde A et al. Pediatric Nodular Fasciitis in the Head and Neck Evaluation and Management. *JAMA Otolaryngol Head Neck Surg* 2015; 141: 54–59
- [400] Park SY, Kim GY, Chun YS. Sonographic Appearance of Proliferative Fasciitis-A Case Report. *J Clin Ultrasound* 2017; 45: 445–449
- [401] Bisi-Balogun A, Cassel M, Mayer F. Reliability of Various Measurement Stations for Determining Plantar Fascia Thickness and Echogenicity. *Diagnostics (Basel)* 2016; 6: 15
- [402] Nakhaee M, Mousavi ME, Mohseni-Bandpei MA et al. Intra and Inter-Rater Reliability of Ultrasound in Plantar Fascia Thickness Measurement. *Iran J Radiol* 2018; 15: e59022
- [403] Abd Allah MMH, Kremser C, Strobl S et al. New Approach for B-Mode Ultrasound (US) Evaluation of the Plantar Aponeurosis (PA) Thickness in Healthy Subjects. *Rofo* 2019; 191: 333–339
- [404] Cheng JW, Tsai WC, Yu TY et al. Reproducibility of sonographic measurement of thickness and echogenicity of the plantar fascia. *J Clin Ultrasound* 2012; 40: 14–19
- [405] Pirri C, Todros S, Fede C et al. Inter-rater reliability and variability of ultrasound measurements of abdominal muscles and fasciae thickness. *Clin Anat* 2019; 32: 948–960
- [406] Wortsman X, Jemec GBE. Ultrasound imaging of nails. *Dermatol Clin* 2006; 24: 323–328
- [407] Wollina U, Berger M, Karte K. Calculation of nail plate and nail matrix parameters by 20 MHz ultrasound in healthy volunteers and patients with skin disease. *Skin Res Technol* 2001; 7: 60–64
- [408] Aluja Jaramillo F, Quisáa Mejía DC, Martínez Orduz HM et al. Nail unit ultrasound: a complete guide of the nail diseases. *J Ultrasound* 2017; 20: 181–192
- [409] Berritto D, Iacobellis F, Rossi C et al. Ultra-high-frequency ultrasound: New capabilities for nail anatomy exploration. *J Dermatol* 2017; 44: 43–46
- [410] Wortsman X, Alfageme F, Roustan G et al. Guidelines for Performing Dermatologic Ultrasound Examinations by the DERMUS Group. *J Ultrasound Med* 2016; 35: 577–580
- [411] Gutierrez M, Filippucci E, De Angelis R et al. A sonographic spectrum of psoriatic arthritis: "the five targets". *Clin Rheumatol* 2010; 29: 133–142
- [412] Fassio A, Giovannini I, Idolazzi L et al. Nail ultrasonography for psoriatic arthritis and psoriasis patients: a systematic literature review. *Clin Rheumatol* 2020; 39: 1391–1404
- [413] Mendonca JA, Aydin SZ, D'Agostino MA. The use of ultrasonography in the diagnosis of nail disease among patients with psoriasis and psoriatic arthritis: a systematic review. *Adv Rheumatol* 2019; 59: 41
- [414] Gisondi P, Idolazzi L, Girolomoni G. Ultrasonography reveals nail thickening in patients with chronic plaque psoriasis. *Arch Dermatol Res* 2012; 304: 727–732
- [415] Acquitter M, Misery L, Saraux A et al. Detection of subclinical ultrasound enthesopathy and nail disease in patients at risk of psoriatic arthritis. *Joint Bone Spine* 2017; 84: 703–707
- [416] Naredo E, Janta I, Baniandres-Rodriguez O et al. To what extent is nail ultrasound discriminative between psoriasis, psoriatic arthritis and healthy subjects? *Rheumatol Int* 2019; 39: 697–705
- [417] Soto R, Aldunce MJ, Wortsman X et al. Subungual Schwannoma with Clinical, Sonographic, and Histologic Correlation. *J Am Podiatr Med Assoc* 2014; 104: 302–304
- [418] Choi JH, Shin DH, Shin DS et al. Subungual keratoacanthoma: ultrasound and magnetic resonance imaging findings. *Skeletal Radiol* 2007; 36: 769–772
- [419] Quintana-Codina M, Creus-Vila L, Iglesias-Plaza A et al. Sonographic appearance of subungual squamous cell carcinoma in the hand. *J Clin Ultrasound* 2018; 46: 212–214
- [420] Cinotti E, Veronesi G, Labelle B et al. Imaging technique for the diagnosis of onychomatricoma. *J Eur Acad Dermatol Venereol* 2018; 32: 1874–1878
- [421] Nakamura Y, Fujisawa Y, Teramoto Y et al. Tumor-to-bone distance of invasive subungual melanoma: An analysis of 30 cases. *J Dermatol* 2014; 41: 872–877
- [422] Cha SM, Shin HD, Park YC. Surgical Resection of Occult Subungual Glomus Tumors: Cold Sensitivity and Sonographic Findings. *Ann Plast Surg* 2018; 81: 411–415
- [423] Chiang YP, Hsu CY, Lien WC et al. Ultrasonographic Appearance of Subungual Glomus Tumors. *J Clin Ultrasound* 2014; 42: 336–340
- [424] Lee W, Kwon SB, Cho SH et al. Glomus Tumor of the Hand. *Arch Plast Surg* 2015; 42: 295–301
- [425] Lin YC, Hsiao PF, Wu YH et al. Recurrent Digital Glomus Tumor: Analysis of 75 Cases. *Dermatol Surg* 2010; 36: 1396–1400
- [426] Pandey CR, Singh N, Tamang B. Subungual Glomus Tumours: Is Magnetic Resonance Imaging or Ultrasound Necessary for Diagnosis? *Malays Orthop J* 2017; 11: 47–51
- [427] Wortsman X, Jemec GBE. Role of High-Variable Frequency Ultrasound in Preoperative Diagnosis of Glomus Tumors A Pilot Study. *Am J Clin Dermatol* 2009; 10: 23–27
- [428] Whittle C, Aguirre J, Catalan V et al. Subungual Exostosis: High-Resolution Ultrasound Findings. *J Diagn Med Sonogr* 2019; 35: 387–390
- [429] Wortsman X, Wortsman J, Soto R et al. Benign Tumors and Pseudotumors of the Nail A Novel Application of Sonography. *J Ultrasound Med* 2010; 29: 803–816
- [430] Wortsman X, Gutierrez M, Saavedra T et al. The role of ultrasound in rheumatic skin and nail lesions: a multi-specialist approach. *Clin Rheumatol* 2011; 30: 739–748
- [431] Singh R, Bryson D, Singh HP et al. High-resolution ultrasonography in assessment of nail-related disorders. *Skeletal Radiol* 2012; 41: 1251–1261
- [432] Rodriguez-Takeuchi SY, Villota V, Renjifo M. Anatomy and pathology of the nail and subungual space: Imaging evaluation of benign lesions. *Clin Imaging* 2018; 52: 356–364
- [433] Wortsman X, Calderon P, Baran R. Finger retronychias detected early by 3D ultrasound examination. *J Eur Acad Dermatol Venereol* 2012; 26: 254–256
- [434] Fernandez J, Reyes-Baraona F, Wortsman X. Ultrasonographic Criteria for Diagnosing Unilateral and Bilateral Retronychia. *J Ultrasound Med* 2018; 37: 1201–1209
- [435] Gungor F, Akyol KC, Eken C et al. The value of point-of-care ultrasound for detecting nail bed injury in ED. *Am J Emerg Med* 2016; 34: 1850–1854