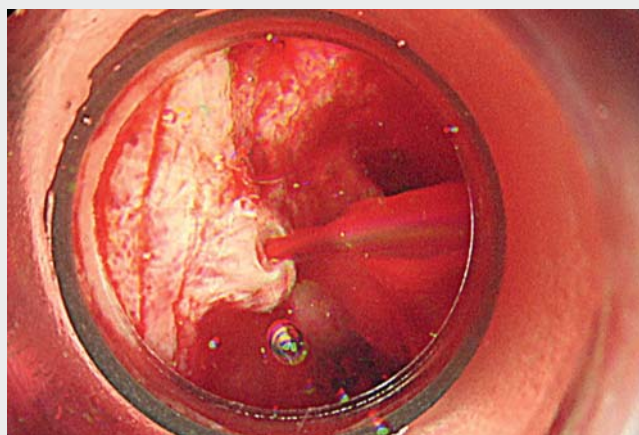


Low-pressure endoscopy using the gel immersion method facilitates endoscopic variceal ligation of ruptured esophageal varices

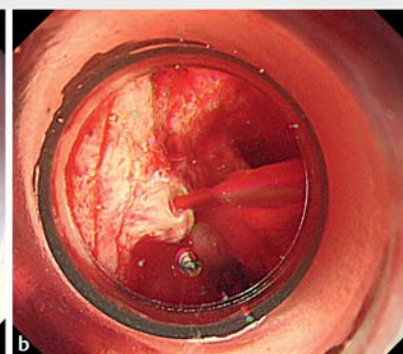
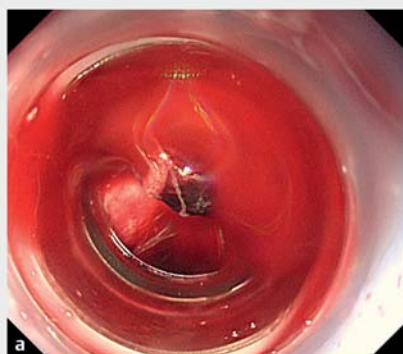
Although endoscopic variceal ligation (EVL) is a standard procedure in the management of acute variceal bleeding [1], it is often difficult to secure the visual field because the lumen is filled with fresh blood and the injected water rapidly mixes with blood. For previously treated varices, it may also be difficult to adequately aspirate fibrotic varices into the banding cap.

Gel immersion endoscopy is a new method for securing the visual field using a transparent gel. Because the injected gel does not immediately mix with blood and pushes blood and clots away, the bleeding point can be easily identified within the gel [2]. In addition, the gel immersion method maintains a lower level of intraluminal pressure and wall tension than would be the case with gas insufflation [3], thereby facilitating the aspiration of the varices, even those with fibrosis. However, just before the varices are aspirated, any remaining gel in the accessory channel should be pushed out with air or water, because otherwise it will interfere with the aspiration of the varices.

The patient was a 67-year-old man with ruptured esophageal varices (► **Video 1**). The bleeding point was inadequately identified using gas insufflation (► **Fig. 1a**), even after aspirating twice, and the varix could not be drawn into the banding cap owing to high wall tension and the presence of fibrosis from four previous EVL treatments. With the use of the “Viscogel” gel (Otsuka Pharmaceutical Factory, Tokushima, Japan) [4], the bleeding point was easily identified, while the intraluminal pressure was maintained at a low level (► **Fig. 1b**). Although the varix could not initially be adequately aspirated through the gel-filled channel, after pushing out the remaining gel, the varix was adequately aspirated into the banding cap and successfully banded (► **Fig. 2** and ► **Fig. 3**).



► **Video 1** The gel immersion method is illustrated and shown being used in a patient with a bleeding esophageal varix, allowing the bleeding point to be easily identified and, after gel remaining in the channel had been pushed out, adequately aspirated and successfully banded.



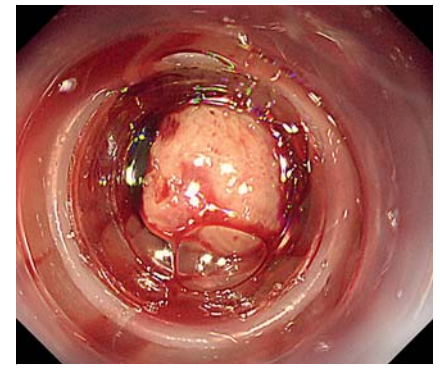
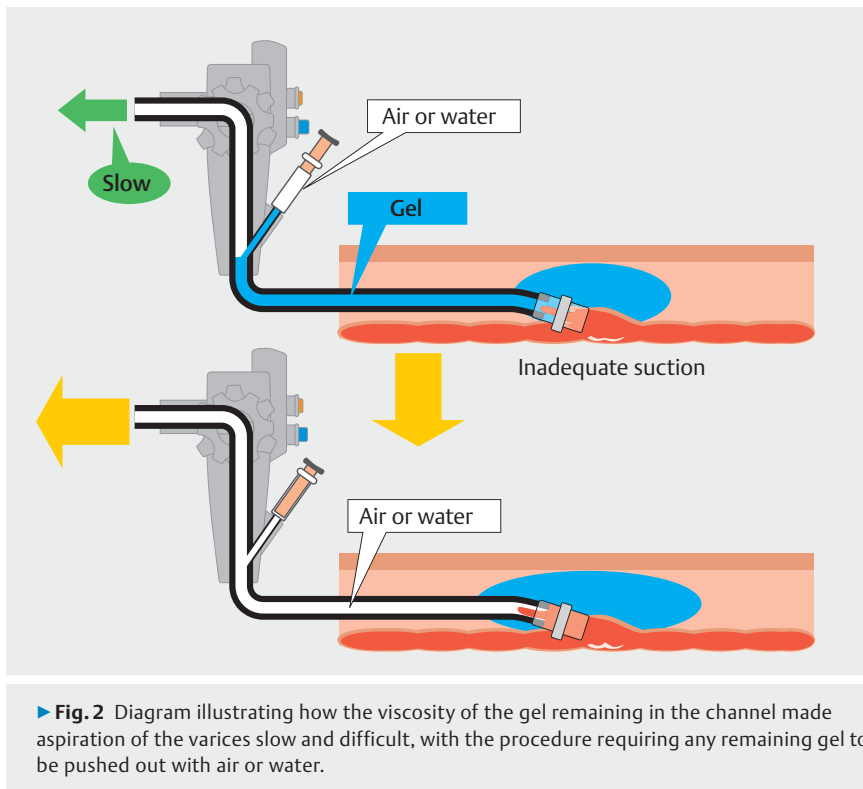
► **Fig. 1** Endoscopic view showing: **a** inadequate visualization of the bleeding point when gas insufflation was used; **b** the bleeding point, which was easily identified after injection of the gel into the lumen, with the intraluminal pressure also maintained at a low level.

Low-pressure endoscopy using the gel immersion method has the potential to facilitate EVL of ruptured esophageal varices with fibrosis.

Endoscopy_UCTN_Code_TTT_1AO_2AD

Competing interests

Tomonori Yano has patents for the dedicated electrolyte-free gel. The remaining authors declare that they have no conflict of interest.



► **Fig. 3** Endoscopic view showing the varix adequately aspirated into the banding cap and successfully banded after the gel remaining in the channel had been removed with air.

The authors

**Hiromi Sekiguchi^{1,2}, Tomonori Yano¹,
Shinnosuke Tokoro^{1,2}, Mizuho Iida^{1,2}, Shigeo
Tano², Alan Kawai Lefor³, Hironori
Yamamoto¹**

- 1 Department of Medicine, Division of Gastroenterology, Jichi Medical University, Tochigi, Japan
- 2 Department of Gastroenterology, Shin-Oyama City Hospital, Tochigi, Japan
- 3 Department of Surgery, Jichi Medical University, Tochigi, Japan

Corresponding author

Tomonori Yano, MD, PhD

Department of Medicine, Division of Gastroenterology, Jichi Medical University, 3311-1 Yakushiji, Shimotsuke, Tochigi 329-0498, Japan
tomonori@jichi.ac.jp

References

- [1] Hwang JH, Shergill AK, Acosta RD et al. The role of endoscopy in the management of variceal hemorrhage. *Gastrointest Endosc* 2014; 80: 221–227
- [2] Yano T, Nemoto D, Ono K et al. Gel immersion endoscopy: a novel method to secure the visual field during endoscopy in bleeding patients (with videos). *Gastrointest Endosc* 2016; 83: 809–811
- [3] Yano K, Yano T, Nagayama M et al. Hemostasis of an actively bleeding lesion at the ileocecal valve by low-pressure endoscopy using the gel immersion technique. *Video-GIE* 2021; 6: 184–186
- [4] Yano T, Ohata A, Hiraki Y et al. Development of a gel dedicated to gel immersion endoscopy. *Endosc Int Open* 2021; 09: E918–E924

Bibliography

Endoscopy 2022; 54: 828–829

DOI 10.1055/a-1559-2120

ISSN 0013-726X

published online 17.9.2021

© 2021. Thieme. All rights reserved.

Georg Thieme Verlag KG, Rüdigerstraße 14, 70469 Stuttgart, Germany

ENDOSCOPY E-VIDEOS

<https://eref.thieme.de/e-videos>



Endoscopy E-Videos is a free access online section, reporting on interesting cases and new techniques in gastroenterological endoscopy. All papers include a high quality video and all contributions are freely accessible online.

This section has its own submission website at
<https://mc.manuscriptcentral.com/e-videos>