

Intrahepatic Cholestasis of Pregnancy

Intrahepatische Schwangerschaftscholestase



Authors

Stanisław M. Jurk¹, Andreas E. Kremer^{2,3}, Ekkehard Schleussner⁴

Affiliations

- 1 Leipzig, Germany
- 2 Medizinische Klinik 1, Universitätsklinikum Erlangen, Erlangen, Germany
- 3 Klinik für Gastroenterologie und Hepatologie, Universitätsspital Zürich, Zürich, Switzerland
- 4 Klinik für Geburtsmedizin, Universitätsklinikum Jena, Jena, Germany

Key words

cholestasis of pregnancy, pruritus, bile acids, antenatal care, induction of labor, fetal death

Schlüsselwörter

Schwangerschaftscholestase, Pruritus, Gallensäuren, Schwangerschaftsvorsorge, Geburtseinleitung, Fruchttod

received 19. 6. 2020

accepted after revision 2. 6. 2021

Bibliography

Geburtsh Frauenheilk 2021; 81: 940–947

DOI 10.1055/a-1522-5178

ISSN 0016-5751

© 2021. The Author(s).

This is an open access article published by Thieme under the terms of the Creative Commons Attribution-NonDerivative-NonCommercial-License, permitting copying and reproduction so long as the original work is given appropriate credit. Contents may not be used for commercial purposes, or adapted, remixed, transformed or built upon. (<https://creativecommons.org/licenses/by-nc-nd/4.0/>)

Georg Thieme Verlag KG, Rüdigerstraße 14,
70469 Stuttgart, Germany

Correspondence

Dr. med. Stanisław M. Jurk
Leipzig, Germany
stjurk@web.de



Deutsche Version unter:

<https://doi.org/10.1055/a-1522-5178>

ABSTRACT

Intrahepatic cholestasis of pregnancy (ICP) is a rare but potentially serious complication of pregnancy, the main symptom of which is intense pruritus with elevated serum levels of bile acids. The elevated serum bile acid concentration is regarded as a predictor for poor perinatal outcome including intrauterine death. Ursodeoxycholic acid (UDCA) has become established as the treatment of choice in clinical management to achieve a significant improvement in symptoms and reduce the cholestasis. Pregnant women with severe intrahepatic cholestasis should always be managed in a perinatal centre with close interdisciplinary monitoring and treatment involving perinatologists and hepatologists to minimise the markedly increased perinatal morbidity and mortality as well as maternal symptoms.

ZUSAMMENFASSUNG

Die intrahepatische Schwangerschaftscholestase (ICP) ist eine seltene, aber potenziell schwerwiegende Schwangerschaftskomplikation, deren Leitsymptom ein die schwangere Frau quälender Pruritus bei erhöhten Serumspiegeln der Gallensäuren ist. Erhöhte Serumkonzentration gilt als Prädiktor für ein schlechtes perinatales Outcome bis hin zum intrauterinen Tod. Als Therapie der Wahl hat sich Ursodesoxycholsäure (UDCA) zur signifikanten Symptomverbesserung und Verminderung der Cholestase in der klinischen Versorgung etabliert. Die engmaschige Überwachung und Behandlung von Schwangeren mit einer schweren intrahepatischen Cholestase sollte immer in einem Perinatalzentrum interdisziplinär durch Perinatologen und Hepatologen erfolgen, damit neben den maternalen Beschwerden die wesentlich erhöhte perinatale Morbidität und Mortalität minimiert werden.

► **Table 1** Maternal risk factors.

Maternal risk factors
Maternal age (> 35 years)
Low selenium level
Low vitamin D level
Chronic HCV infection
Polymorphisms in bile transporters (e.g. ABCB4, ABCB11, etc.)
Multiple pregnancy

► **Table 2** Symptoms.

Clinical features
Pruritus
Effects of scratching (e.g., excoriations, prurigo nodularis)
Mental stress (insomnia, fatigue)
Malabsorption (steatorrhea, vitamin K deficiency, rarely peripartum haemorrhage)
Dyslipidaemia
Upper abdominal discomfort
Nausea
Anorexia

Introduction

Intrahepatic cholestasis of pregnancy (ICP) is a reversible liver disease that involves disturbed secretion of biliary substances and pruritus in previously healthy skin. This disorder is usually characterised by its reversible and benign course. It consists diagnostically of maternal pruritus with elevated bile acids and/or elevated transaminases in the serum, usually from the late second or third trimester. There are no primary skin changes though intense scratching can lead to secondary excoriations.

The pruritus ceases immediately postpartum, usually within a few days, and the elevated liver function tests should normalise within a few weeks. Recurrence is frequent at up to 70% in subsequent pregnancies. There is currently no guideline in Germany on intrahepatic cholestasis of pregnancy. Treatment with ursodeoxycholic acid (UDCA) can significantly reduce the maternal pruritus and the elevated bile acids.

Epidemiology

ICP is subject to considerable geographic and ethnic variation. In Germany, roughly 0.7–1% of all pregnancies are affected. Throughout Europe, the highest incidence is found in Scandinavian countries. The incidence can be much higher in South America and China [1–4]. A seasonal increase in incidence in the winter months has been described [5].

Pathogenesis and Risk Factors

The pathogenesis of ICP is so far not fully understood. It was first described by Ahlfeld in 1883 [6]. Genetic [7–9], hormonal [10] and environmental [5] factors are involved in the aetiology. The disease occurs more often in multiparous women and multiple pregnancies [2,3,11,12]. Other risk factors are maternal age >35 years and low selenium [13,14] and vitamin D levels [15,16]. An increased risk was also reported in women with chronic hepatitis C infection [17,18]. The incidence appears to be increased after assisted reproduction treatment as raised bile acids are found more often in these women [19]. Because of hormonal triggering with accumulation of progesterone metabolites there is a disturbance of hepatocyte bile acid secretion with a cholestatic effect. Certain sulphated progesterone metabolites such as

PM2DiS, PM3S and PM3DiS appear to play an important part in the pathogenesis of ICP and pruritus [20]. For instance, vaginal progesterone replacement increased the incidence of ICP compared with controls (0.75 vs. 0.23%, aOR 3.16, 95% CI 2.23–4.49, $p < 0.01$) [21]. Cholestasis parameters can increase and pruritus can occur with oral contraceptives with a high oestrogen content [22]. This should also be borne in mind when contraceptives are re-prescribed. The WHO recommends progesterone mono- or depot preparations, progesterone-containing IUDs or etonogestrel implants for these women. Combined oral contraceptives can be prescribed after a strict benefit-risk assessment provided the benefit outweighs the risk [23] (► **Table 1**).

Pruritus as the main symptom occurs particularly in the third trimester as the highest concentrations of oestrogen and progesterone metabolites in the course of the pregnancy are reached then. The function of the two important transport proteins BSEP (bile salt export pump, bile acid transporter) and MDR3 (multi-drug resistance associated protein 3, phospholipid transporter) is reduced [24] (► **Table 2**).

In pregnancy there is a physiological rise and a change in the composition of the bile acids. In women with ICP the concentration of cholic acid (CA) increases proportionally compared with that of chenodeoxycholic acid (CDCA). In normal pregnancies the ratio of CDCA to CA is the same, possibly with slight predominance of CDCA [25]. There is also a shift to the taurine-conjugated bile acids and thus to a reduction in the glycine-aurine ratio [26]. At the same time, a foeto-maternal bile acid concentration gradient develops [25]. In addition, a maternal immunological imbalance has been described in association with ICP.

The pathogenesis is also influenced by molecular genetic factors that affect the mechanisms of the bile acid receptor and bile acid transport. Genetic variations are found in ca. 10–15% of cases of ICP [27]. The most frequent genetic abnormality at 16% involves mutations in the ABCB4 gene, which codes for MDR3 (multi-drug resistance-associated protein 3), responsible for the transmembrane transport of phospholipids into bile [7,27]. In 5% there is a mutation of the ABCB11 gene, which codes for the liver-specific protein BSEP (bile salt export pump). This can result in liver cell damage due to accumulation of toxic bile acids in the hepatocytes as transport of bile acids from the hepatocytes into bile is impaired due to the mutation [27,29]. This gene mutation is also associated with an increased risk of hepatocellular carcinoma

(HCC) [27]. The altered genes can be diagnosed by means of Sanger sequencing and NGS panel sequencing. Genetic testing after a pregnancy with these clinical features could be considered in an individual case with regard to the late consequences. Other genes that play a part in ICP are ATP8B1, TJP2, ABC2, NR1H4, FGF19 and SLC4A2 [13, 27, 30, 31], and the development of cholestasis is due to the complex variability, differences in penetrance and a variety of environmental factors [13]. It can be assumed that certain pregnancy-associated changes such as the altered oestrogen and progesterone levels and pre-existing raised bile acid levels lead to increased expression of the disorder in genetically predisposed women [32].

It is important to note at this point that intrahepatic cholestasis of pregnancy is a diagnosis of exclusion and the laboratory and clinical changes must cease completely after delivery. If elevated liver and cholestasis parameters persist, further investigation by a hepatologist is important as primary biliary cholangitis (PBC), primary sclerosing cholangitis (PSC), autoimmune hepatitis (AIH) or familial cholestasis syndromes can be associated with similar laboratory abnormalities and clinical symptoms (pruritus) in pregnancy (► **Table 3**).

Complications and Prognosis

Placental insufficiency or foetal arrhythmias resulting in intrauterine foetal death (1.5%) are feared complications [9, 22, 33]. Moreover, depending on the bile acid concentration, premature delivery, often induced [33], foetal stress with meconium-containing amniotic fluid or respiratory distress syndrome (RDS) and thus the need for neonatal intensive care, can occur in up to 25% [22, 33–36]. The risk for foetal morbidity and mortality correlates with the level of the bile acids [13, 36], which accumulate in the foetal compartment [26]. The risk for the foetus appears to be caused by increased myocardial and contractile complications [37–40]. In addition, pathological vasoconstrictor mechanisms acting on the foeto-placental vessels due to bile acids are suspected [32]. Uterine contractility can increase [42] through increased expression of oxytocin receptors in the myometrium caused by bile acids [41]. The risk for intrauterine foetal death rises significantly and is more than doubled in women with a bile acid concentration of over 100 µmol/l [36, 43, 44]. The risk for IUFT also increases with pregnancy age.

Geenes et al. showed a significantly increased risk for IUFT in 713 women at a bile acid concentration of ≥ 40 µmol compared with the control group with a normal pregnancy (1.5 vs. 0.5%; adjusted OR 2.58, 95% CI 1.03–6.49). An increased rate of premature deliveries was also described compared with the control group (non-adjusted OR 7.39, 95% CI 5.33–10.25), especially iatrogenically induced [33].

In the meta-analysis by Ovdia et al. a significantly increased rate of IUFT was seen only at bile acid concentrations above 100 µmol/l (3.44%, 95% CI 2.05–5.37) while only a tendency was observed at a concentration up to 40 µmol/l (0.13%, 95% CI 0.02–0.38) and at 40–99 µmol/l (0.28%, 95% CI 0.08–0.72). The large meta-analysis also showed that women with ICP have a significantly increased risk of both spontaneous (OR 3.47, 95% CI 3.06–3.95) and iatrogenically induced premature delivery (OR 3.65,

► **Table 3** Differential diagnosis.

Differential diagnosis
Viral hepatitis (A–E)
Pre-existing liver disease (PBC, PSC)
Obstructive jaundice
Fatty liver of pregnancy
HELLP/PE

95% CI 1.94–6.85). The prevalence was high in all three groups (< 40 µmol/l [16.5%, 95% CI 15.1–18.0]; 40–99 µmol/l [19.1%, 95% CI 17.1–21.1]; ≥ 100 µmol/l [30.5%, 95% CI 26.8–34.6]). In addition, neonates of women with ICP had a significantly higher rate of meconium-stained amniotic fluid (OR 2.60, 95% CI 1.62–4.16) and also had to be admitted more often to a neonatal intensive care unit (OR 2.12, 95% CI 1.48–3.03) [36].

A systematic review based on 1200 singleton pregnancies found perinatal mortality of 6.8% at maternal bile acid concentrations of ≥ 100 µmol/l compared with 0.3% at bile acid concentrations of ≥ 40 µmol/l. The preterm delivery rate and the rate of meconium-stained amniotic fluid were also significantly increased [45]. Due to the vasoconstrictor effect of the meconium, acute foetal danger may occur as a result of reduced placental perfusion [46]. Pregnancy-associated comorbidities such as pre-eclampsia and gestational diabetes can increase the risk for intrauterine foetal death even in women with lower bile acid concentrations [36, 43]. The risk of preterm delivery increases for women above bile acid concentrations of over 40 µmol/l [36].

In a French cohort with 140 women a significantly increased risk was also found for respiratory distress syndrome (RDS) in neonates of women with ICP (17.1 vs. 4.6%, $p < 0.001$; crude OR 4.46 (95% CI 2.49–8.03) [35].

Clinical Features

The disorder manifests towards the end of the first trimester in 10%, in the second trimester in 25% and predominantly in the third trimester in 65% of cases [47]. The main symptom is new-onset severe cholestatic pruritus. This is accompanied by jaundice as a result of extrahepatic cholestasis in fewer than 10% [48]. The pruritus usually starts in the extremities, can become generalised over the entire integument and can be very troublesome for the pregnant woman [13]. Typically, the palms of the hands and soles of the feet are most affected. This can occur before any skin or laboratory manifestation. It is suspected that this pruritus is attributable to the direct pruritogenic effect of bile acids in the skin [5], though the serum concentration of the bile acids does not correlate with the severity of the pruritus [49, 50]. The subjective perception of pruritus can vary greatly individually. Other nonspecific symptoms are right-sided upper abdominal pain due to stretching of the liver capsule, nausea and anorexia. In very rare cases, secondary steatorrhea and vitamin K deficiency may develop. There are usually no primary skin changes. Secondary effects in the skin produced by intensive scratching may appear.

The association between the pruritus and the laboratory changes remains unclear as these may precede the itching but may also only occur subsequently [13].

Women with ICP are affected more often by dyslipidaemia, gestational diabetes and foetal macrosomia and pre-eclampsia [12, 15, 22, 51–54]. In a recently published study, an increased incidence of pre-eclampsia was found in women with ICP (7.78 vs. 2.41%, aOR 3.74, 95% CI 12.0–7.02, $p < 0.0001$), and also in women with a twin pregnancy. The earlier in pregnancy the ICP occurred, the higher was the association with pre-eclampsia. On average, affected women developed pre-eclampsia about 30 days after the diagnosis (29.7 ± 24 days) [52].

The incidence of intrauterine foetal death in pregnant women with ICP depends on the serum bile acid concentration and is ca. 1,5%.

As a rule, the disorder resolves completely in the mother within a few days to 6 weeks postpartum and the liver tests normalise. A protracted postpartum course occurs rarely. If the liver function tests are still abnormal 6 weeks postpartum, other causes of liver dysfunction must be considered. Recurrence in subsequent pregnancy is common, occurring in up to 70% [17]. There is an increased lifetime risk in the mother for hepatobiliary disease [17], such as gallstone disorders and cholangitis [55] and for cardiovascular and immunological diseases such as diabetes mellitus, hypothyroidism or Crohn's disease [51].

Diagnosis

ICP is a diagnosis of exclusion. Elevated transaminases in combination with elevated bile acids and pruritus confirm the suspected diagnosis. It must be ensured that the bile acids in the serum are measured in the fasting state as oral food ingestion leads to a rise in this parameter. The bile acids play an important part in fat digestion and as a solubiliser and inhibitor of cholesterol synthesis. The primary bile acids cholic acid (CA), and chenodeoxycholic acid (CDCA), which are present in conjugated compounds, are the most important representatives. They are excreted as lithocholic and deoxycholic acid. Because of their hydrophobic structure, they could play a clinically important part as a toxic metabolite in the pathomechanism of cholestasis [56].

The transaminases can be increased 2–10-fold in 20–60% [48]. The ratio of ASAT/ALAT is usually < 1 [47, 57]. The bile acid concentration in the serum is regarded as the most sensitive parameter. In late pregnancy, depending on the laboratory, a concentration of up to $11 \mu\text{mol/l}$ is considered normal [26]. Hyperbilirubinaemia occurs in only 10–20%. The partial thromboplastin time (pTT) can be prolonged because of possible vitamin K deficiency [5]. The enzyme autotaxin has been described as a highly sensitive predictive marker for cholestasis of pregnancy but it is not available in routine clinical practice [50].

Liver ultrasonography usually appears normal in women with ICP. Nevertheless, posthepatic biliary obstruction should be excluded by abdominal ultrasound, especially as the incidence of ICP is increased in patients with cholelithiasis [48]. In any case, however, this should be done postpartum at the latest if the symptoms persist longer than 4–6 weeks after delivery. Since microscopic liver changes are usually nonspecific, liver biopsy for his-

tological confirmation is not indicated. As well as other pregnancy-related dermatoses, viral hepatitis in particular (e.g., hepatitis viruses A–E), pre-existing liver disease such as primary biliary cholangitis (PBC) or primary sclerosing cholangitis (PSC), obstructive jaundice and pre-eclampsia/HELLP syndrome and acute fatty liver of pregnancy should be excluded in the differential diagnosis. Certain genetic causes for ICP are also associated with an increased risk for gallstones, cholecystitis or cholangitis and with the development of liver fibrosis and malignant disease. For this reason, affected persons, especially those with severe disease, should be offered genetic counselling and genetic testing if appropriate [27].

Treatment

The primary aim of treatment is to reduce the clinical symptoms by reducing the laboratory test results while reducing foetal complications also.

The agent of choice is ursodeoxycholic acid (UDCA), a tertiary, hydrophilic bile acid that occurs physiologically [43]. Absorption takes place both passively via diffusion in the jejunum and ileum and actively in the distal ileum [58]. A dose of 13–15 mg/kg body weight/d [2, 59] is recommended. The starting dose should be 500 mg and the maximum daily dose is 2 g [60]. In a meta-analysis, pruritus was reduced significantly with this compared with placebo (OR 0.21, 95% CI 0.07–0.62, $p < 0.01$), the transaminases were normalised (OR 0.18, 95% CI 0.06–0.52, $p < 0.001$) or reduced (OR 0.12, 95% CI 0.05–0.31, $p < 0.0001$) and the bile acids were reduced (OR 0.30, 95% CI 0.12–0.73, $p < 0.01$). The authors concluded that the use of UDCA would also be able to improve the perinatal outcome [61]. However, this was not confirmed in the recently published PITCHES study with 605 women, though the study was underpowered for patients with severe forms of ICP [43]. It is of particular importance that UDCA can also reduce the bile acids in amniotic fluid and cord blood [25, 62]. Since the drug is not licensed in pregnancy, it requires separate informed consent (off-label use). UDCA was used successfully in many thousands of pregnant women and significant side effects did not occur apart from mild diarrhoea [61].

Treatment with UDCA can increase the measured bile acids in the serum. UDCA accounts for approximately 60% of total bile acids [63]. This should be noted so as to avoid misinterpretation and resulting indication for delivery.

According to a Cochrane review from 2013 statistically significantly fewer preterm deliveries were seen in women on treatment with UDCA compared with placebo (RR 0.46, 95% CI 0.28–0.73). The results were not significant with regard to fewer signs of foetal stress and less meconium in the amniotic fluid and higher birth weight in the UDCA group [64].

Two more meta-analyses also reported a reduction in the rate of preterm deliveries [65, 79].

Cholestyramine can be used as an alternative, but this proved inferior to UDCA in a randomised study [66]. Reduced fat absorption with cholestyramine therapy can cause vitamin K deficiency and subsequently an increased bleeding tendency in mother and child. Vitamin K can be given intravenously to reduce the risk of peripartum haemorrhage in severe cases [3].

Other treatment options are S-adenosylmethionine (SAM) [47, 61], which can be used in dosages of about 1000 mg/day as second-line therapy, especially for persistent pruritus. In a randomised controlled study by Roncaglia et al. SAM proved less effective than UDCA as regards reducing the serum levels of bile acids, transaminases and bilirubin. The improvement in the pruritus was similar [67]. This is also confirmed by a meta-analysis from 2016, in which UDCA was more effective than SAM in the treatment of ICP and significantly and effectively reduced the pruritus score, bile acids and rate of preterm delivery [68]. Combined treatment with both medications in 89 pregnant women with mild ICP (bile acid concentration $<40 \mu\text{mol/l}$) was shown to be equivalent with regard to an unfavourable perinatal outcome [69].

Rifampicin in dosages of 150–300 (up to a maximum of 600) mg/d can be considered as third-line therapy. This bactericidal tuberculostatic drug exhibits anticholestatic mechanisms [59]. The intensity of the pruritus can diminish and the cholestasis parameters can be reduced by combined treatment with UDCA [70].

A Cochrane analysis from 2019 of pharmacological interventions concluded that treatment with UDCA reduces pruritus symptoms only slightly. A reduction in the foetal risks remains unclear. There is insufficient evidence for other pharmacological therapies, for example SAM, dexamethasone, cholestyramine and others [71].

Supportive treatment with moisturising and cooling effects, e.g. with menthol ingredients, is possible and may provide relief [13]. If a patient is found to have a genetic disease-associated variant of ABCB4, lifelong treatment by UDCA must be discussed [27].

Management

There are no uniform recommendations internationally on monitoring a pregnant woman with ICP [72]. Since last year, the S2k guideline on induction of delivery includes recommendations on the procedure in cases of intrahepatic cholestasis of pregnancy [73].

The severity of the maternal symptoms and the risks to the child from an iatrogenic preterm delivery must be weighed against the risk of acute placental insufficiency and subsequent intrauterine foetal death in the third trimester with expectant management.

During the pregnancy, weekly laboratory measurement of the transaminases, bilirubin and bile acids is indicated to monitor treatment so as to identify possible short-term progression of the ICP [74]. If outpatient treatment is unsuccessful, the patient must be admitted to hospital for foetal monitoring and appropriate treatment adjustment.

Termination of pregnancy must be considered depending on the age of the pregnancy at bile acid concentrations above $40 \mu\text{mol/l}$. If treatment is unsuccessful, premature delivery appears to be the only possible intervention that can prevent an unfavourable perinatal outcome. UDCA alone was unable to significantly reduce the occurrence of IUFT, the preterm delivery rate and foetal stress [43].

The extent to which maternal bile acids influence foetal heart rate alterations in women with and without ICP is currently being investigated in a prospective pilot study (Bile Acid Effects in Fetal Arrhythmia Study, “BEATS”) [75].

Delivery of pregnant women with ICP after 36 weeks proved to be the optimal procedure in a statistical decision analysis of pre- and postpartum decision-making factors [76].

In a large American retrospective study the perinatal mortality with delivery after 36 weeks was much lower compared with a wait-and-see approach (4.7 vs. 19.2 per 10000 deliveries out of a total of 1.6 million deliveries) [77].

Since severe ICP with maternal jaundice and highly elevated bile acids of $\geq 100 \mu\text{mol}$ is associated with high perinatal mortality, early inpatient foeto-maternal monitoring and delivery after 35–36 weeks should be discussed despite the paucity of data [45]. There is no absolute indication for caesarean section.

Since definite predictive factors, especially for the risk of IUFT are lacking, the bile acid concentration remains the most important factor in decision-making, even though IUFT can occur suddenly without warning as the most severe though rare complication. Management should be tailored individually all the more.

Since December 2020 the new S2k guideline on induction of delivery provides recommendations on management at term of pregnant women with ICP [73]. According to this, induction of delivery *must* be recommended from 38 + 0 weeks if ICP is present (expert consensus; consensus strength +++). It is also stated that induction of delivery *should* be recommended from 37 + 0 weeks and that induction of delivery can be recommended even in the period from 34 + 0 to 36 + 6 weeks when the bile acid concentration is above $> 100 \mu\text{mol/l}$ (expert consensus; consensus strength +++).

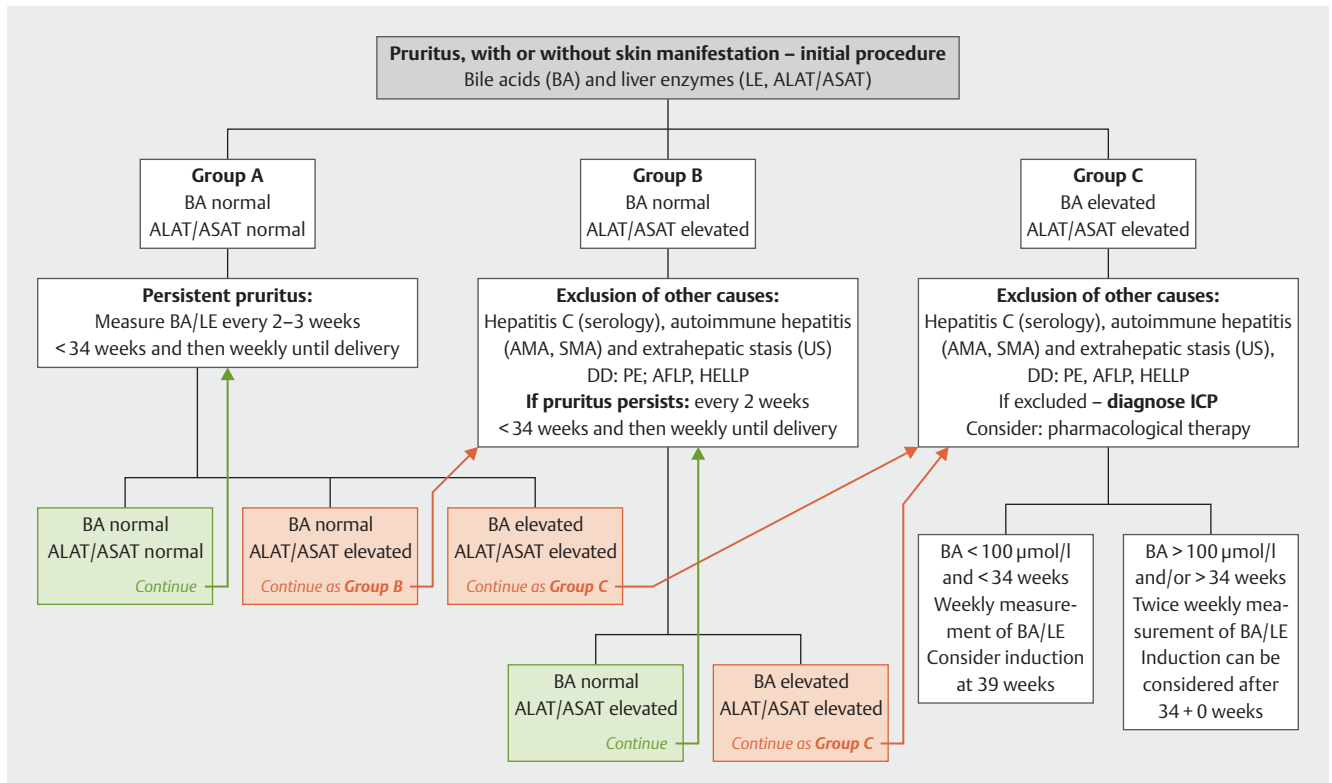
Comment: The graduation in the German-language recommendations is divided according to the respective binding strength of the recommendations. “Must” stands for a strong recommendation with highly binding character and “should” for a regular recommendation with moderately binding character [73].

A very discriminating recommendation based on constantly updated literature searches can be found at www.icpsupport.org [60]. The sometimes different treatment recommendations regarding the times in the German S2k guideline are explained by the unclear data internationally and should be noted ► **Fig. 1**.

► **Fig. 1** is based on the RCOG Green-top Guideline No. 43 from 2011 which is continually updated according to the most recent findings (see also Mitchell et al., 2021 [78] and Ovdia et al. 2021 [79]). When this article went to press, the RCOG had not yet updated its recommendations. Once their new recommendations are published, this Figure will be updated promptly and will be available at www.icpsupport.org.

In future, progesterone metabolites could be a predictive marker for ICP; these can be found in raised concentrations in early pregnancy and show an association with pruritus [20].

The decision for expectant management or active termination of pregnancy can only be made with consideration of the pregnant woman’s individual risk profile based on the subjective pruritus stress, laboratory test results and their course, additional risks (gestational diabetes, pre-eclampsia) and additional foetal diagnostics (CTG, biometry/Doppler ultrasonography) and may re-



► **Fig. 1** Management of women with ICP according to www.icpsupport.org [60], modified and adapted to the German recommendations of [73].

quire interdisciplinary consultation and care of the pregnant woman by obstetricians, neonatologists and hepatologists.

Summary

Intrahepatic cholestasis of pregnancy (ICP) is a rare but potentially serious complication of pregnancy, the main symptom of which is intense pruritus with elevated serum levels of bile acids. These are regarded as a predictor for poor perinatal outcome including intrauterine death. Ursodeoxycholic acid (UDCA) has become established as the treatment of choice in clinical management to achieve a significant improvement in symptoms and reduce the cholestasis. Pregnant women with severe intrahepatic cholestasis should always be managed in a perinatal centre with close interdisciplinary monitoring and treatment involving perinatologists and hepatologists to minimise the markedly increased perinatal morbidity and mortality as well as maternal symptoms.

Conflict of Interest

The authors declare that they have no conflict of interest.

References

- [1] Pusl T, Beuers U. Intrahepatic cholestasis of pregnancy. *Orphanet J Rare Dis* 2007; 2: 26. doi:10.1186/1750-1172-2-26
- [2] Floreani A, Gervasi MT. New insights on intrahepatic cholestasis of pregnancy. *Clin Liver Dis* 2016; 20: 177–189
- [3] Ovadia C, Williamson C. Intrahepatic cholestasis of pregnancy: recent advances. *Clin Dermatol* 2016; 34: 327–334
- [4] Geenes V, Williamson C, Chappel LC. Intrahepatic cholestasis of pregnancy. *Obstet Gynaecol* 2016; 18: 273–281. doi:10.1111/tog.12308
- [5] Smith DD, Rood KM. Intrahepatic Cholestasis of Pregnancy. *Clin Obstet Gynecol* 2020; 63: 134–151. doi:10.1097/GRF.0000000000000495
- [6] Ahlfeld F. *Berichte und Arbeiten aus der geburtshilflich-gynaekologischen Klinik zu Giessen 1881–1882*. Leipzig: Grunow FW; 1883: 148
- [7] Dixon PH, Wadsworth CA, Chambers J et al. A comprehensive analysis of common genetic variation around six candidate loci for intrahepatic cholestasis of pregnancy. *Am J Gastroenterol* 2014; 109: 76–84
- [8] Jacquemin E, De Vree JM, Cresteil D et al. The wide spectrum of multidrug resistance 3 deficiency: from neonatal cholestasis to cirrhosis of adulthood. *Gastroenterology* 2001; 120: 1448–1458
- [9] Lammert F, Marschall HU, Glantz A et al. Intrahepatic cholestasis of pregnancy: molecular pathogenesis, diagnosis and management. *J Hepatol* 2000; 33: 1012–1021
- [10] Reyes H, Sjövall J. Bile acids and progesterone metabolites in intrahepatic cholestasis of pregnancy. *Ann Med* 2000; 32: 94–106
- [11] Gonzalez MC, Reyes H, Arrese M et al. Intrahepatic cholestasis of pregnancy in twin pregnancies. *J Hepatol* 1989; 9: 84–90
- [12] Raz Y, Lavie A, Vered Y et al. Severe intrahepatic cholestasis of pregnancy is a risk factor for preeclampsia in singleton and twin pregnancies. *Am J Obstet Gynecol* 2015; 213: 395.e1–395.e8. doi:10.1016/j.ajog.2015.05.011
- [13] Kremer AE, Wolf K, Ständer S. Intrahepatische Schwangerschaftscholestase. *Hautarzt* 2017; 68: 95–102
- [14] Kaupila A, Korpela H, Mäkilä UM et al. Low serum selenium concentration and glutathione peroxidase activity in intrahepatic cholestasis of pregnancy. *Br Med J (Clin Res Ed)* 1987; 294: 150–152

- [15] Wikström Shemer E, Marschall HU. Decreased 1,25-dihydroxy vitamin D levels in women with intrahepatic cholestasis of pregnancy. *Acta Obstet Gynecol Scand* 2010; 89: 1420–1423. doi:10.3109/00016349.2010.515665
- [16] Gençosmanoğlu Türkmen G, Vural Yılmaz Z, Dağlar K et al. Low serum vitamin D level is associated with intrahepatic cholestasis of pregnancy. *J Obstet Gynaecol Res* 2018; 44: 1712–1718. doi:10.1111/jog.13693
- [17] Marshall HU, Wikstrom Shermer E, Ludvigsson JF. Intrahepatic cholestasis of pregnancy and associated hepatobiliary disease: a population-based cohort study. *Hepatology* 2013; 58: 1385–1391
- [18] Wijarnpreecha K, Thongprayoon C, Sanguankeo A et al. Hepatitis C infection and intrahepatic cholestasis of pregnancy: A systematic review and meta-analysis. *Clin Res Hepatol Gastroenterol* 2017; 41: 39–45. doi:10.1016/j.clinre.2016.07.004
- [19] Bolubkas FF, Bolubkas C, Balaban HY et al. Intrahepatic Cholestasis of Pregnancy: Spontaneous vs. in vitro Fertilization. *Euroasian J Hepat-Gastroenterol* 2017; 7: 126–129
- [20] Abu-Hayyeh S, Ovadia C, Lieu T et al. Prognostic and mechanistic potential of progesterone sulfates in intrahepatic cholestasis of pregnancy and pruritus gravidarum. *Hepatology* 2016; 63: 1287–1298
- [21] Tsur A, Kan P, Datoc i et al. 68: Vaginal progesterone treatment is associated with intrahepatic cholestasis of pregnancy. *Am J Obstet Gynecol* 2020; 222: S58–S59. doi:10.1016/j.ajog.2019.11.084
- [22] Glantz A, Marshall HU, Mattsson LA. Intrahepatic cholestasis of pregnancy: relationship between bile acid levels and fetal complication rates. *Hepatology* 2004; 40: 467–474
- [23] WHO. Medical Eligibility Criteria for Contraceptive Use. 5th ed. World Health Organization; 2015
- [24] Kondrackiene J, Kupcinskas L. Intrahepatic cholestasis of pregnancy – current achievements and unsolved problems. *World J Gastroenterol* 2008; 14: 5781–5788
- [25] Geenes V, Lövgren-Sandblom A, Benthin L et al. The Reversed Feto-Maternal Bile Acid Gradient in Intrahepatic Cholestasis of Pregnancy IS Corrected by Ursodeoxycholic Acid. *PLoS One* 2014; 9: e83828. doi:10.1371/journal.pone.0083828
- [26] Brites D. Intrahepatic cholestasis of pregnancy: changes in maternal-fetal bile acid balance and improvement by ursodeoxycholic acid therapy in cholestasis of pregnancy. *Ann Hepatol* 2002; 1: 20–28
- [27] Keitel V, Dröge C, Häussinger D. Genetische Ursachen cholestatischer Lebererkrankungen. *Falk Gastro-Kolleg* 3/2019. Accessed March 30, 2020 at: https://www.dr.falkpharma.de/uploads/tx_toccm2/FGK_3_19_Keitel_Web.pdf
- [28] Dixon PH, Williamson C. The pathophysiology on intrahepatic cholestasis of pregnancy. *Clin Res Hepatol Gastroenterol* 2016; 40: 141–153. doi:10.1016/j.clinre.2015.12.008
- [29] Dixon PH, van Mil SW, Chambers J et al. Contribution of variant alleles of ABCB11 to susceptibility to intrahepatic cholestasis of pregnancy. *Gut* 2009; 58: 537–544
- [30] Dixon PH, Sambrotta M, Chambers J et al. An expanded role for heterozygous mutations of ABCB4, ABCB11, ATP8B1, ABCC2 and TJP2 in intrahepatic cholestasis of pregnancy. *Sci Rep* 2017; 7: 11823. doi:10.1038/s41598-017-11626-x
- [31] Henkel SA, Squires JH, Ayers M et al. Expanding etiology of progressive familial intrahepatic cholestasis. *World J Hepatol* 2019; 11: 450–463. doi:10.4254/wjh.v11.i5.450
- [32] Williamson C, Geenes V. Intrahepatic cholestasis of pregnancy. *Obstet Gynecol* 2014; 124: 120–133. doi:10.1097/AOG.0000000000000346
- [33] Geenes V, Chappell LC, Seed PT et al. Association of severe intrahepatic cholestasis of pregnancy with adverse pregnancy outcomes: a prospective population-based case-control study. *Hepatology* 2014; 59: 1482–1491
- [34] Brouwers L, Koster MP, Page-Christiaens GC et al. Intrahepatic cholestasis of pregnancy: maternal and fetal outcomes associated with elevated bile acid levels. *Am J Obstet Gynecol* 2015; 212: 100.e1–100.e7. doi:10.1016/j.ajog.2014.07.026
- [35] Arthuis C, Diguisto C, Lorphelin H et al. Perinatal outcomes of intrahepatic cholestasis during pregnancy: An 8-year case-control study. *PLoS One* 2020; 15: e0228213. doi:10.1371/journal.pone.0228213
- [36] Ovadia C, Seed PT, Sklavounos A et al. Association of adverse perinatal outcomes of intrahepatic cholestasis of pregnancy with biochemical markers: results of aggregate and individual patient data meta-analyses. *Lancet* 2019; 393: 899–909. doi:10.1016/S0140-6736(18)31877-4
- [37] Al Inizi S, Gupta R, Gale A. Fetal tachyarrhythmia with atrial flutter in obstetric cholestasis. *Int J Gynecol Obstet* 2006; 93: 53–54
- [38] Ataalla WM, Ziada DH, Gaber R et al. The impact of total bile acid levels on fetal cardiac function in intrahepatic cholestasis of pregnancy using fetal echocardiography: a tissue Doppler imaging study. *J Matern Fetal Neonatal Med* 2016; 29: 1445–1450
- [39] Sanhal CY, Kara O, Yucel A. Can fetal left ventricular modified myocardial performance index predict adverse perinatal outcomes in intrahepatic cholestasis of pregnancy? *J Matern Fetal Neonatal Med* 2017; 30: 911–916
- [40] Williamson C, Miragoli M, Sheikh Abdul Kadir S et al. Bile acid signaling in fetal tissues: implications for intrahepatic cholestasis of pregnancy. *Dig Dis* 2011; 29: 58–61. doi:10.1159/000324130
- [41] Germain AM, Kato S, Carvajal JA et al. Bile acids increase response and expression of human myometrial oxytocin receptor. *Am J Obstet Gynecol* 2003; 189: 577–582
- [42] Zhao P, Zhang K, Yao Q et al. Uterine contractility in intrahepatic cholestasis of pregnancy. *J Obstet Gynaecol* 2014; 34: 221–224. doi:10.3109/01443615.2013.834878
- [43] Chappell LC, Bell JL, Smith A et al.; for the PITCHES study group. Ursodeoxycholic acid versus placebo in women with intrahepatic cholestasis of pregnancy (PITCHES): a randomised controlled trial. *Lancet* 2019; 394: 849–860
- [44] Kawakita T, Parikh LI, Ramsey PS et al. Predictors of adverse neonatal outcomes in intrahepatic cholestasis of pregnancy. *Am J Obstet Gynecol* 2015; 213: 570.e1–570.e8. doi:10.1016/j.ajog.2015.06.021
- [45] Di Mascio D, Quist-Nelson J, Riegel M et al. Perinatal death by bile acid levels in intrahepatic cholestasis of pregnancy: a systematic review. *J Matern Fetal Neonatal Med* 2019. doi:10.1080/14767058.2019.1685965
- [46] Altshuler G, Arizawa M, Molnar-Nadasdy G. Meconium-induced Umbilical Cord Vascular Necrosis and Ulceration: A Potential Link Between the Placenta and Poor Pregnancy Outcome. *Obstet Gynecol* 1992; 79 (5 Pt 1): 760–766
- [47] Lammert F, Rath W, Matern S. Lebererkrankungen in der Schwangerschaft. *Molekulare Pathogenese und interdisziplinäres Management. Gynäkologie* 2004; 37: 418–426
- [48] Lammert F, Rath W. Lebererkrankungen. In: Kainer F, Hrsg. *Facharztwissen Geburtsmedizin*. 3. Aufl. München: Elsevier GmbH; 2016: 450–453
- [49] Ghent CN, Bloomer JR, Klatskin G. Elevations in skin tissue levels of bile acids in human cholestasis: relation to serum levels and pruritus. *Gastroenterology* 1977; 73: 1125–1130
- [50] Kremer AE, Bolier R, Dixon PH et al. Autotaxin activity has a high accuracy to diagnose intrahepatic cholestasis of pregnancy. *J Hepatol* 2015; 62: 897–904. doi:10.1016/j.jhep.2014.10.041
- [51] Wikström Shemer EA, Stephansson O, Thuresson M et al. Intrahepatic cholestasis of pregnancy and cancer, immunemediated and cardiovascular diseases: A population-based cohort study. *J Hepatol* 2015; 63: 456–461

- [52] Mor M, Shmueli A, Krispin E et al. Intrahepatic cholestasis of pregnancy as a risk factor for preeclampsia. *Arch Gynecol Obstet* 2020; 301: 655–664. doi:10.1007/s00404-020-05456-y
- [53] Martineau MG, Raker C, Dixon PH et al. The metabolic profile of intrahepatic cholestasis of pregnancy is associated with impaired glucose tolerance, dyslipidemia, and increased fetal growth. *Diabetes Care* 2015; 38: 243–248
- [54] Majewska A, Godek B, Bomba-Opon D et al. Association between intrahepatic cholestasis in pregnancy and gestational diabetes mellitus. A retrospective analysis. *Ginekol Pol* 2019; 90: 458–463. doi:10.5603/GP.2019.0079
- [55] Ropponen A, Sund R, Riikonen et al. Intrahepatic cholestasis of pregnancy an indicator of liver and biliary diseases: a population-based study. *Hepatology* 2006; 43: 723–728. doi:10.1002/hep.21111
- [56] Sinakos E, Marshall HU, Kowdley KV et al. Bile acid changes after high-dose ursodeoxycholic acid treatment in primary sclerosing cholangitis: Relation to disease progression. *Hepatology* 2010; 52: 197–203
- [57] Hammoud GM, Ibdah JA. The Liver in Pregnancy. In: Boyer TD, Manns MP, Sanyal AS, eds. *Zakim and Boyer's Hepatology. A Textbook of Liver Disease*. 6th ed. Philadelphia: Saunders; 2012: 919–940
- [58] Parquet M, Metman EH, Raizman A et al. Bioavailability, gastrointestinal transit, solubilization and faecal excretion of ursodeoxycholic acid in man. *Eur J Clin Invest* 1985; 15: 171–178
- [59] European Association for the Study of the Liver. *EASL Clinical Practice Guidelines: management of cholestatic liver diseases*. *J Hepatol* 2009; 51: 237–267
- [60] Accessed June 17, 2021 at: <https://www.icpsupport.org/protocol.shtml>
- [61] Bacq Y, Sentilhes L, Reyes HB et al. Efficacy of ursodeoxycholic acid in treating intrahepatic cholestasis of pregnancy: a meta-analysis. *Gastroenterology* 2012; 143: 1492–1501
- [62] Geenes V, Williamson C. Intrahepatic cholestasis of pregnancy. *World J Gastroenterol* 2009; 15: 2049–2066
- [63] Manna LB, Ovadia C, Lövgren-Sandblom A et al. Enzymatic quantification of total serum bile acids as a monitoring strategy for women with intrahepatic cholestasis of pregnancy receiving ursodeoxycholic acid treatment: a cohort study. *BJOG* 2019; 126: 1633–1640
- [64] Gurung V, Middleton P, Milan SJ et al. Interventions for treating cholestasis in pregnancy. *Cochrane Database Syst Rev* 2013; (6): CD000493
- [65] Grand'Maison S, Durand M, Mahone M. The effects of ursodeoxycholic acid treatment for intrahepatic cholestasis of pregnancy on maternal and fetal outcomes: a meta-analysis including non-randomized studies. *J Obstet Gynaecol Can* 2014; 36: 632–641
- [66] Kondrackiene J, Beuers U, Kupcinskas L. Efficacy and safety of ursodeoxycholic acid versus cholestyramine in intrahepatic cholestasis of pregnancy. *Gastroenterology* 2005; 129: 894–901
- [67] Roncaglia N, Locatelli A, Arreghini A et al. A randomised controlled trial of ursodeoxycholic acid and S-adenosyl-L-methionine in the treatment of gestational cholestasis. *BJOG* 2004; 111: 17–21
- [68] Zhang Y, Lu L, Victor DW et al. Ursodeoxycholic Acid and S-adenosylmethionine for the Treatment of Intrahepatic Cholestasis of Pregnancy: A Meta-analysis. *Hepat Mon* 2016; 16: e38558
- [69] Triunfo S, Tomaselli M, Ferraro MI et al. Does mild intrahepatic cholestasis of pregnancy require an aggressive management? Evidence from a prospective observational study focused on adverse perinatal outcomes and pathological placental findings. *J Matern Fetal Neonatal Med* 2020. doi:10.1080/14767058.2020.1714583
- [70] Geenes V, Chambers J, Khurana R et al. Rifampicin in the treatment of severe intrahepatic cholestasis of pregnancy. *Eur J Obstet Gynecol Reprod Biol* 2015; 189: 59–63
- [71] Walker KF, Chappell LC, Hague WM et al. Pharmacological interventions for treating intrahepatic cholestasis of pregnancy. *Cochrane Database Syst Rev* 2020; (7): CD000493. doi:10.1002/14651858.CD000493.pub3
- [72] Bicocca MJ, Sperling JD, Chauhan SP. Intrahepatic cholestasis of pregnancy: Review of six national and regional guidelines. *Eur J Obstet Gynecol Reprod Biol* 2018; 231: 180–187. doi:10.1016/j.ejogrb.2018.10.041
- [73] Kehl S, Abou-Dakn M et al.; für die DGGG und Arbeitsgemeinschaft für Geburtshilfe und Pränatalmedizin in der DGGG e.V. *S2k-Leitlinie Geburtseinleitung*. Accessed December 27, 2020 at: https://www.awmf.org/uploads/tx_szleitlinien/015-088l_S2k_Geburtseinleitung_2020-12.pdf
- [74] Royal College of Obstetricians and Gynaecologists. *Obstetric Cholestasis*. RCOG Green-top Guideline No. 43. London: RCOG; 2011
- [75] *Bile Acid Effects in Fetal Arrhythmia Study (BEATS)*. Accessed August 31, 2020 at: <https://clinicaltrials.gov/ct2/show/NCT03519399>
- [76] Lo JO, Shaffer BL, Allen AJ et al. Intrahepatic Cholestasis of Pregnancy and Timing of Delivery. *J Matern Fetal Neonatal Med* 2015; 28: 2254–2258. doi:10.3109/14767058.2014.984605
- [77] Puljic A, Kim A, Page J et al. The risk of infant and fetal death by each additional week of expectant management in intrahepatic cholestasis of pregnancy by gestational age. *Am J Obstet Gynecol* 2015; 212: 667.e1–e667.e5
- [78] Mitchell A, Ovadia C, Syngelaki A et al. Re-evaluating diagnostic thresholds for intrahepatic cholestasis of pregnancy: case-control and cohort study. *Br J Obstet Gynaecol* 2021. doi:10.1111/1471-0528.16669
- [79] Ovadia C, Sajous J, Seed PT et al. Ursodeoxycholic acid in intrahepatic cholestasis of pregnancy: a systematic review and individual participant data meta-analysis. *Lancet Gastroenterol Hepatol* 2021; 6: 547–558. Online: [https://www.thelancet.com/journals/langas/article/PIIS2468-1253\(21\)00074-1/fulltext](https://www.thelancet.com/journals/langas/article/PIIS2468-1253(21)00074-1/fulltext)