

Zenker's peroral endoscopic myotomy, or flexible or rigid septotomy for Zenker's diverticulum: a multicenter retrospective comparison

Authors

Sarah S. Al Ghamdi^{1,*}, Jad Farha^{1,*}, Robert A. Moran², Mathieu Pioche³, Frédéric Moll³, Dennis J. Yang⁴, Oscar V. Hernández Mondragón⁵, Michael Ujiki⁶, Harry Wong⁶, Alina Tantau⁷, Alireza Sedarat⁸, M. Phillip Fejleh⁸, Kenneth Chang⁹, David P. Lee⁹, Jose M. Nieto¹⁰, Sherif Andrawes¹¹, Gregory G. Ginsberg¹², Monica Saumoy¹², Amol Bapaye¹³, Parag Dashatwar¹³, Mohamad Aghaie Meybodi¹, Ariana C. Lopez¹, Omid Sanaei¹, Muhammad N. Yousaf¹⁴, Manol Jovani¹, Yervant Ichkhanian¹, Olaya I. Brewer Gutierrez¹, Vivek Kumbhari¹, Ashli K. O'Rourke¹⁵, Eric J. Lentsch¹⁵, B. Joseph Elmunzer², Mouen A. Khashab¹

Institutions

- 1 Division of Gastroenterology and Hepatology, Johns Hopkins Hospital, Baltimore, Maryland, United States
- 2 Division of Gastroenterology and Hepatology, Medical University of South Carolina, Charleston, South Carolina, United States
- 3 Gastroenterology, Edouard Herriot Hospital, Lyon, France
- 4 Division of Gastroenterology, Hepatology and Nutrition, University of Florida, Gainesville, Florida, United States
- 5 Division of Endoscopy, Specialties Hospital, National Medical Center Century XXI, Mexico City, Mexico
- 6 Division of Minimally Invasive Surgery, NorthShore's Grainger Center for Simulation and Innovation, Evanston, Illinois, United States
- 7 Department of Gastroenterology, the 4th Medical Clinic, "Iuliu Hatieganu" University of Medicine and Pharmacy, Cluj-Napoca, Romania
- 8 Ronald Reagan UCLA Medical Center, UCLA Medical Center, Los Angeles, California, United States
- 9 H.H. Chao Comprehensive Digestive Disease Center, University of California, Irvine Medical Center, Irvine, California, United States
- 10 Borland Groover Clinic Advance Therapeutic Endoscopy Center and Baptist Medical Center, Jacksonville, Florida, United States
- 11 Division of Gastroenterology and Hepatology, Staten Island University Hospital – Northwell Health, Staten Island, New York, United States
- 12 Endoscopic Services, University of Pennsylvania, Perelman School of Medicine, Philadelphia, Pennsylvania, United States
- 13 Shivanand Desai Center for Digestive Disorders, Deenanath Mangeshkar Hospital and Research Center, Pune, India
- 14 Medstar Union Memorial Hospital, Columbia, Maryland, United States
- 15 Department of Otolaryngology, Medical University of South Carolina, Charleston, South Carolina, United States

submitted 28.12.2020

accepted after revision 17.5.2021

published online 1.7.2021

Bibliography

Endoscopy 2022; 54: 345–351

DOI 10.1055/a-1518-7223

ISSN 0013-726X

© 2021. Thieme. All rights reserved.

Georg Thieme Verlag KG, Rüdigerstraße 14, 70469 Stuttgart, Germany

 Fig. 1s, Tables 1s–3s

Supplementary material is available under <https://doi.org/10.1055/a-1518-7223>

Corresponding author

Mouen A. Khashab, MD, Division of Gastroenterology and Hepatology, Johns Hopkins Hospital, 1800 Orleans Street, Sheikh Zayed Tower, Baltimore, MD 21287, United States mkhasha1@jhmi.edu

ABSTRACT

Background Treatment of Zenker's diverticulum has evolved from open surgery to endoscopic techniques, including flexible and rigid endoscopic septotomy, and more recently, peroral endoscopic myotomy (Z-POEM). This study compared the effectiveness of flexible and rigid endoscopic septotomy with that of Z-POEM.

Methods Consecutive patients who underwent endoscopic septotomy (flexible/rigid) or Z-POEM for Zenker's diverticulum between 1/2016 and 9/2019 were included. Primary outcomes were clinical success (decrease in Dakkak

* Sarah S. Al Ghamdi and Jad Farha are primary coauthors.

and Bennett dysphagia score to ≤ 1), clinical failure, and clinical recurrence. Secondary outcomes included technical success and rate/severity of adverse events.

Results 245 patients (110 females, mean age 72.63 years, standard deviation [SD] 12.37 years) from 12 centers were included. Z-POEM was the most common management modality ($n = 119$), followed by flexible ($n = 86$) and rigid ($n = 40$) endoscopic septotomy. Clinical success was 92.7% for Z-POEM, 89.2% for rigid septotomy, and 86.7% for flexible septotomy ($P = 0.26$). Symptoms recurred in 24 patients (15 Z-POEM during a mean follow-up of 282.04 [SD 300.48] days, 6 flexible, 3 rigid [$P = 0.47$]). Adverse events

occurred in 30.0% rigid septotomy patients, 16.8% Z-POEM patients, and 2.3% flexible septotomy patients ($P < 0.05$).

Conclusions There was no difference in outcomes between the three treatment approaches for symptomatic Zenker's diverticulum. Rigid endoscopic septotomy was associated with the highest rate of complications, while flexible endoscopic septotomy appeared to be the safest. Recurrence following Z-POEM was similar to flexible and rigid endoscopic septotomy. Prospective studies with long-term follow-up are required.

Introduction

Zenker's diverticulum is a sac-like protrusion of the pharyngeal mucosa through a defect in the pharyngeal wall. It usually occurs in the posterior wall of the pharynx at Killian's triangle, an area of natural weakness located between the inferior constrictor and cricopharyngeus muscles [1]. Although prevalence is only 0.01%–0.11%, it is the most common false diverticulum that arises in the esophagus [2]. Zenker's diverticulum occurs predominantly in elderly men, and prevalence is expected to increase in the aging population [3].

Treatment for Zenker's diverticulum is indicated for symptomatic patients, regardless of the size of the diverticulum. The treatment approach basically consists of myotomy of the septum, composed of the cricopharyngeus muscle, which acts as a partition between the Zenker's diverticulum and the esophagus. Earliest treatment approaches dating back to 1886 began with transcervical surgery involving pharyngeal pouch excision [3]. Endoscopic septotomy using rigid endoscopy was described in 1917, and involved division of the cricopharyngeus muscle to create a common cavity to allow more adequate propulsion of the food bolus into the esophagus [4]. In the early 1990s, laparoscopic surgery techniques were introduced, comprising division of the cricopharyngeus muscle and sealing of the opposing walls of the pouch and esophagus using a stapling device [5, 6]. At around that time, flexible endoscopic septotomy was introduced and was found to be an effective approach in patients who were poor surgical candidates [7].

Over the past two decades, there have been significant advancements in endoscopic techniques and instrumentation that have led to widespread recognition of endoscopic treatment as an alternative to surgery [8]. More recently, Zenker's peroral endoscopic myotomy (Z-POEM) was introduced, with promising results [9–11]. The main premise of Z-POEM is the utilization of submucosal endoscopy techniques to fully expose and dissect the septum, which in turn may diminish the relatively high recurrence rates associated with flexible [12] and rigid [13] endoscopic septotomy. In Z-POEM, the mucosal septum is left intact whereas it is sectioned in endoscopic septotomy, and comparative data are needed to evaluate the clinical impact of this difference.

The effectiveness of flexible and rigid endoscopic techniques compared with Z-POEM has not been evaluated. This study aimed to compare this novel technique with both rigid and flexible endoscopic septotomy in terms of clinical success, technical success, adverse events, and long-term symptom recurrence.

Methods

The study was a multicenter, international, retrospective cohort study involving 12 centers: one from Asia, two from Europe, one from Mexico, and eight from the USA (see **Table 1s** in the online-only Supplementary material for case contributions). The study was approved by individual institutional review boards at participating centers.

Consecutive patients who underwent Z-POEM, flexible endoscopic septotomy, or rigid endoscopic septotomy between January 2016 and September 2019 were included. Zenker's diverticulum was diagnosed on imaging studies, including barium esophagram and/or computed tomography, and confirmed by endoscopy. Dysphagia score was quantified according to the Dakkak and Bennett score (0, no dysphagia; 1, dysphagia to solids; 2, dysphagia to semisolids; 3, dysphagia to liquids; 4, complete dysphagia) [14]. Patient dysphagia scores were collected during clinical follow-ups, phone calls, and/or chart reviews. Patients were identified using center-specific endoscopic or billing databases. Electronic records were reviewed to capture the following variables: demographics, diverticulum size (determined either endoscopically or radiographically), dysphagia score, other symptoms (aspiration, choking, halitosis, regurgitation, weight loss, and others), imaging findings, prior surgical or endoscopic interventions, procedure time, clinical success, technical success, type of anesthesia, length of hospital stay, symptom recurrence at follow-up, adverse events with severity graded according to the American Society for Gastrointestinal Endoscopy (ASGE) lexicon [15], and duration of follow-up. The authors acknowledge that 43 patients from this study have been included in previous publications [10, 16, 17]; however, no analysis comparing the three procedures has been performed previously.

Procedure techniques

Z-POEM was performed as previously described under deep sedation or general anesthesia using a flexible endoscope. Briefly, a longitudinal mucosal incision was made, allowing for creation of a submucosal tunnel extending up to the diverticular septum. The tunnel was then continued on both sides of the septum (esophageal and diverticular side) until it was completely exposed. Myotomy of the septum was then extended to the base of the septum until the longitudinal muscle fibers of the esophagus proper were exposed. Mucosal closure was achieved using clips [18, 19] (► **Fig. 1, Fig. 1 s**).

Flexible endoscopic septotomy was performed under conscious sedation or general anesthesia. A nasogastric tube, hood, endoscopic cap, or overtube were used to help visualize and stabilize the septum between the diverticulum and esophageal lumen, thus avoiding neck hyperextension. As the septum was exposed, dissection was performed by dividing the cricopharyngeus muscle [20]. For both Z-POEM and flexible endoscopic septotomy, different cutting devices and techniques have been described to incise the septum [1] (► **Fig. 2**).

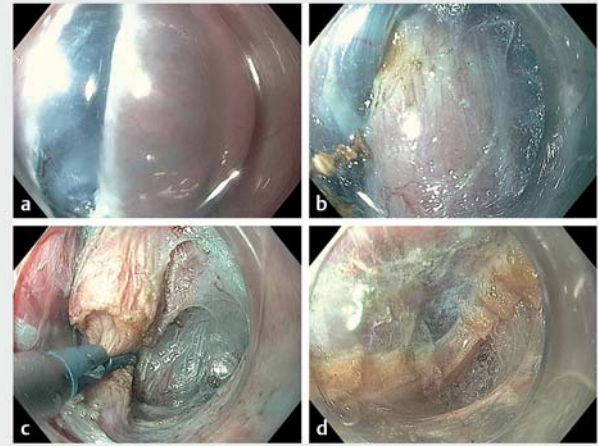
Rigid endoscopic septotomy was carried out under general anesthesia with the patient in the supine position with mandatory neck hyperextension to facilitate placement of the rigid diverticuloscope. To visualize and expose the posterior wall separating the diverticular sac from the esophageal lumen, a special diverticuloscope was used. Several techniques have been implemented for the division of the septum, including electrocautery, carbon dioxide laser, KTP/532 laser, stapler, or Harmonic Ace (Ethicon Endo-Surgery, Inc., Cincinnati, Ohio, USA) [21, 22]. The main difference is that the mucosal septum is left intact in Z-POEM whereas it is sectioned in endoscopic septotomy.

Outcomes

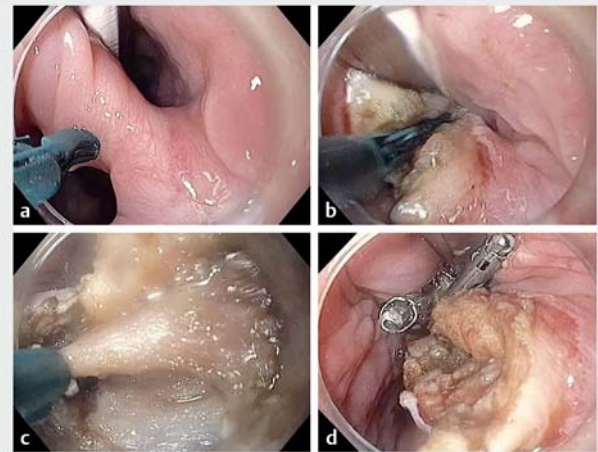
The primary outcome was clinical success, defined as a decrease in the Dakkak and Bennett dysphagia score [14] to ≤ 1 (or to 0 in patients with baseline score of 1). In those patients with no dysphagia at baseline, clinical success was defined as complete resolution of other symptoms. Patients who did not achieve clinical success at first follow-up were considered to have “clinical failure” (i. e. had persistence of symptoms at first follow-up). Patients who achieved clinical success at initial follow-up visit but recurrence of symptoms at later visits were classified as having “clinical recurrence.” Secondary outcomes included technical success (defined as successful completion of all procedural steps), and adverse event rate, timing (timing classified into intraprocedural and post-procedural), and severity (graded as per the ASGE lexicon [15]).

Statistical analysis

The Fisher’s exact test or chi-squared test for categorical variables was used to analyze the clinical outcomes and adverse event rates. Continuous variables were reported as mean and standard deviation (SD) or median and range, where appropriate, and compared by one-way analysis of variance. The dysphagia score was analyzed as a continuous variable. Subgroup



► **Fig. 1** Zenker’s peroral endoscopic myotomy technique. **a** Longitudinal mucosal incision. **b** Submucosal tunnel extending up to the diverticular septum and extending to both esophageal and diverticular sides of the septum. **c** Myotomy of the septum. **d** Complete myotomy.



► **Fig. 2** Flexible endoscopic septotomy technique. **a** A nasogastric tube is used to help visualize and stabilize the septum between the diverticulum and esophageal sides. **b, c** Dissection is performed by dividing the cricopharyngeus muscle. **d** Mucosal closure with clips.

analysis was performed to identify factors associated with clinical success. Statistical significance of $P < 0.05$ was adopted for all inferential testing. The analysis was performed using SPSS software (SPSS 16.0, Chicago, Illinois, USA).

Results

A total of 245 consecutive patients (110 females, mean age 72.63 [SD 12.37] years) from 12 centers were included. Z-POEM was the most common management modality ($n = 119$), followed by flexible ($n = 86$) and rigid ($n = 40$) endoscopic septotomy. Baseline patient characteristics were generally similar

► **Table 1** Baseline demographics.

	Total (n = 245)	Z-POEM (n = 119)	Endoscopic septotomy		P value
			Flexible (n = 86)	Rigid (n = 40)	
Female sex, n (%)	110 (44.9)	52 (43.7)	38 (44.2)	20 (50.0)	0.79
Age, mean (SD), years	72.63 (12.37)	72.49 (13.23)	72.21 (12.37)	73.98 (9.60)	0.74
Symptoms, n (%)					
▪ Dysphagia	230 (93.9)	116 (97.5)	77 (89.5)	37 (92.5)	0.06
▪ Regurgitation	165 (67.3)	79 (66.4)	64 (74.4)	22 (55.0)	0.12
▪ Weight loss	51 (20.8)	18 (15.1)	24 (27.9)	9 (22.5)	0.08
▪ Halitosis	22 (9.0)	13 (10.9)	8 (9.3)	1 (2.5)	0.27
Prior Zenker's diverticulum treatment, n (%)	46 (18.8)	25 (21.0)	14 (16.3)	7 (17.5)	0.61
Baseline diverticulum size, mean (SD), mm	32.96 (14.55)	34.85 (14.68)	28.65 (12.33)	36.47 (16.73)	0.003
ASA score, mean (SD)	2.35 (0.69)	2.45 (0.69)	2.32 (0.71)	2.15 (0.69)	0.05
Sedation, n (%)					<0.001
▪ General anesthesia	232 (94.7)	119 (100)	73 (84.9)	40 (100)	
▪ Conscious sedation	13 (5.3)	0	13 (15.1)	0	
Antibiotics, n (%)					0.04
▪ None	27 (11.0)	7 (5.9)	14 (16.3)	6 (15.0)	
▪ Perioperative	215 (87.8)	111 (93.3)	70 (81.4)	34 (85.0)	
▪ Unknown	3 (1.2)	1 (0.8)	2 (2.3)	0	

Z-POEM, Zenker's peroral endoscopic myotomy; SD, standard deviation; ASA, American Society of Anesthesiologists.

among the three groups. This included mean age (72.49 [SD 13.23] years for Z-POEM vs. 72.21 [SD 12.37] years for flexible endoscopic septotomy vs. 73.98 [SD 9.60] years for rigid endoscopic septotomy; $P=0.74$), sex (female 43.7% vs. 44.2% vs. 50.0%, respectively; $P=0.79$), and prior treatment for Zenker's diverticulum (21.0% vs. 16.3% vs. 17.5%; $P=0.61$) (► **Table 1**). The American Society of Anesthesiologists score was highest in the Z-POEM group, followed by the flexible then rigid endoscopic septotomy groups (2.45 [SD 0.69], 2.32 [SD 0.71], and 2.15 [SD 0.69], respectively; $P=0.05$). The mean size of the diverticulum was smallest in the flexible endoscopic septotomy group, followed by Z-POEM and rigid endoscopic septotomy groups (28.65 [SD 12.33] mm, 34.85 [SD 14.68], and 36.47 [SD 16.73] mm, respectively; $P=0.003$).

The most common symptoms at the time of the index procedure were dysphagia (93.9%) and regurgitation (67.3%), with a mean preprocedure dysphagia score of 1.74 (SD 1.04). Other baseline symptoms included weight loss (20.8%) and halitosis (8.9%). The majority of procedures were performed under general anesthesia (94.7%). Antibiotics were administered more frequently during Z-POEM procedures ($P=0.04$) (► **Table 1**).

Procedural and clinical outcomes

Technical success was achieved in 95.0% of Z-POEM procedures (113/119, 95% confidence interval [CI] 90.97–98.95), 95.3% of flexible endoscopic septotomy procedures (82/86, 95%CI

90.81–99.89), and 87.5% of rigid endoscopic septotomy procedures (35/40, 95%CI 76.79–98.21) ($P=0.18$). The mean procedure time for flexible endoscopic septotomy (33.72 [SD 22.34] minutes) was significantly shorter than that for both rigid endoscopic septotomy (54.03 [SD 22.45] minutes; $P<0.001$) and Z-POEM (46.13 [SD 20.34] minutes; $P<0.001$). The mean length of hospital stay was 1.47 [SD 0.97] days in the flexible endoscopic septotomy group, followed by 1.66 [SD 1.55] days in the Z-POEM group and 4.94 [14.75] days in the rigid endoscopic septotomy group ($P=0.006$). Resolution of Zenker's diverticulum on barium esophagram was similar in all three groups (75% in the Z-POEM group, 68% in the flexible endoscopic septotomy group, and 80% in the rigid endoscopic septotomy group; $P=0.34$).

Overall, 23/245 patients (9.4%) were lost to follow-up (9/119 Z-POEM, 11/86 flexible endoscopic septotomy, and 3/40 rigid endoscopic septotomy). Patients who were lost to follow-up were not included in analysis of clinical success or failure. Clinical success was evaluated at the first post-procedure follow-up in the remaining 222 patients, after a mean of 148.92 (SD 154.8) days post-procedure. The rate of clinical success was equivalent between the three groups: 92.7% (102/110) in the Z-POEM group, 89.2% (33/37) in the rigid endoscopic septotomy group, and 86.7% (65/75) in the flexible endoscopic septotomy group ($P=0.26$). Clinical failure occurred in 22 patients (10 flexible endoscopic septotomy, 8 Z-POEM, 4 rigid endo-

scopic septotomy; $P=0.28$). A comparison between clinical and technical success is depicted in ► **Fig. 3**. When comparing technical and clinical success between centers with low and high volume of procedures (cutoff for low/high, median 16 patients), there was no significant difference in outcomes (**Table 2s**).

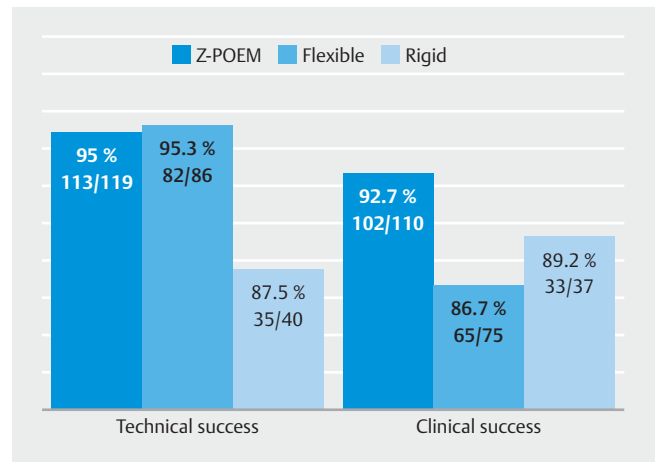
Symptoms recurred in 24 patients (14.7%, 95%CI 6.86–19.46, 15/102 Z-POEM patients with a mean follow-up of 282.04 [SD 300.48] days; 9.2%, 95%CI 1.52–12.77, 6/65 flexible endoscopic septotomy patients with a mean follow-up of 262 [SD 266] days; 9.1%, 95%CI 0–16.03, 3/33 rigid endoscopic septotomy patients with a mean follow-up of 125 [SD 237] days; $P=0.47$). A compilation of primary outcomes (clinical success, failure, and recurrence) is shown in ► **Fig. 4**.

Adverse events

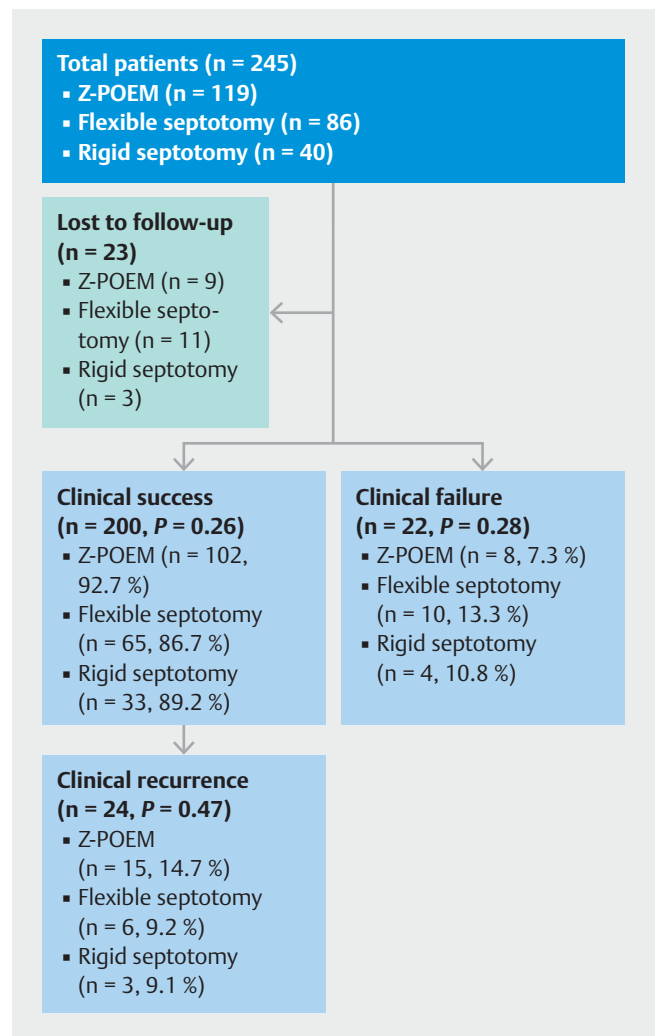
Adverse events occurred in 34/245 patients (13.9%), including 14 (5.7%) intraprocedural events and 20 (8.2%) post-procedural. Adverse events occurred in 30.0% of rigid endoscopic septotomy patients, 16.8% of Z-POEM patients, and 2.3% flexible endoscopic septotomy patients ($P<0.05$ for all comparisons). Most adverse events were mild/moderate (13.1%, 32/245), and the remainder were severe/fatal (0.8%, 2/245). Both severe/fatal adverse events occurred in the rigid endoscopic septotomy group. Esophageal mucosotomies occurred in four patients in the Z-POEM group and were identified intra-procedurally. Three of these patients were treated with endoscopic clip closure, two of whom showed a leak on barium esophagram the following day and underwent repeat endoscopy and treatment with cyanoacrylate glue to close the defect [23]. In the fourth patient with mucosotomy, closure with endoscopic clips was unsuccessful, so an esophageal stent was placed. Hematomas occurred in two patients, one following Z-POEM and one following rigid endoscopic septotomy associated with wound infection. Both were managed conservatively, with antibiotics and symptom control. Leaks were seen on esophagrams the day after the procedure in five patients; four occurred following Z-POEM, with contrast leakage within the submucosal tunnel. These were managed endoscopically with cyanoacrylate glue. One severe adverse event occurred, an esophageal perforation, which was treated conservatively but resulted in prolonged hospitalization (16 days). A second patient in the rigid endoscopic septotomy group developed a leak on computed tomography scan on post-procedure Day 1. This was treated surgically but hospital course was complicated and resulted in the patient's death 94 days following the procedure. Further stratification of adverse events can be found in **Table 3s**.

Discussion

Owing to the significant morbidity associated with open surgery, the management of Zenker's diverticulum has transitioned to less invasive endoscopic techniques [24]. Currently available endoscopic techniques include rigid endoscopic septotomy, flexible endoscopic septotomy, and the relatively new Z-POEM approach. To our knowledge, no prior studies have compared the effectiveness and safety of Z-POEM with those of flexible and rigid endoscopic techniques.



► **Fig. 3** Comparison between technical success ($P=0.18$) and clinical success ($P=0.26$). Z-POEM, Zenker's peroral endoscopic myotomy.



► **Fig. 4** Compilation of outcomes (clinical success, failure, and recurrence). Z-POEM, Zenker's peroral endoscopic myotomy.

Our results are mostly compatible with available literature. In the previously mentioned retrospective study [11], clinical success of Z-POEM was found to be 92%, which is comparable to the 92.7% in our study. In this previous study, Z-POEM was associated with promising short-term outcomes, with only one symptom recurrence (1.3%) at 3 months' follow-up, which required repeat endoscopic septotomy. In our study, symptoms recurred in 15/102 (14.7%) Z-POEM patients over a mean follow-up time of 282.04 [SD 300.48] days. This rate is higher than expected and could be attributed to inclusion of initial Z-POEM procedures at the various participating centers. Another point worth addressing is whether the length of septotomy correlates with the rate of recurrence. It is not possible to determine the exact length of the septotomy retrospectively. However, during Z-POEM, a complete septotomy is typically achieved whereas during flexible and rigid endoscopic septotomy some septum is left to avoid the risk of perforation and leakage. This should be further investigated in future studies.

A recent systematic review of 20 flexible endoscopic septotomy studies by Ishaq et al. demonstrated a pooled clinical success rate of 91% (95%CI 86%–95%), which is slightly greater than the 86.7% achieved in our cohort [25]. Leong et al. demonstrated a 12.8% recurrence rate after rigid stapled endoscopic septotomy in a meta-analysis including 585 patients; our study reported a lower recurrence rate of 9.1% [26]. A recent retrospective study demonstrated fewer residual symptoms and better postoperative quality of life following flexible endoscopic septotomy when compared with rigid endoscopic septotomy [27].

The literature pertaining to both flexible and rigid endoscopic septotomy varies widely with regard to adverse event rate. The systematic review and meta-analysis by Ishaq et al., which included 813 patients from 20 studies that examined the effectiveness and safety of flexible endoscopic septum division, demonstrated a pooled adverse event rate of 11.3% [25]. Our flexible endoscopic septotomy cohort had a much lower adverse event rate (2.3%). Multiple retrospective studies have evaluated the adverse event rate following rigid endoscopic septotomy, reporting a range of 8.3%–12% (mostly minor, with one death that was not directly related to the surgery) [28, 29]. Compared with these studies, our study had an overall higher adverse event rate of 30.0% (mostly minor/moderate, with one severe esophageal perforation and one fatal postoperative leak). For Z-POEM, the adverse event rate was previously reported to be 6.7% in an international multicenter study including 75 patients [11]. The adverse event rate in our Z-POEM group was 16.8% (all minor/moderate). This discrepancy could be explained by the greater number of patients included and the variable level of expertise in performing this novel procedure.

The retrospective observations made in this study harbor some expected limitations. This was a multicenter study with potentially significant variability in techniques and follow-up protocols across multiple centers. There is also a potential for bias with regard to under-reporting of adverse events. In addition, the number of patients in each category was relatively low, potentially reducing the power to observe significant dif-

ferences. However, this was the first study to formally compare these treatment modalities and, as it includes many centers from across the world, the findings may reflect outcomes of real-life experience in managing Zenker's diverticulum.

In conclusion, in this international multicenter study, our data suggest that all three techniques are effective in the treatment of symptomatic Zenker's diverticulum. However, Z-POEM had a higher than expected recurrence rate. Flexible endoscopic septotomy had a shorter procedure time, similar clinical success, and fewer adverse events than Z-POEM and rigid endoscopic septotomy. Prospective studies with long-term follow-up are required to establish more definitive conclusions regarding outcomes of each approach.

Competing interests

M.A. Khashab is a consultant for Boston Scientific, Olympus, Medtronic, GI Supply, and Triton. B.J. Elmunzer is a consultant for Takeda Pharmaceuticals. V. Kumbhari is a consultant for Apollo Endosurgery, Boston Scientific, Medtronic, Fujifilm, Pentax Medical, ReShape Lifesciences, and Obalon, and has received research support from ERBE and Apollo Endosurgery. D.J. Yang is a consultant for Boston Scientific, Lumendi, and Steris. G.G. Ginsberg is a consultant for Olympus Inc. and Boston Scientific. M. Ujiki is a consultant for Olympus, Boston Scientific, and Cook, and receives grant funding from Medtronic; he is also a speaker for Medtronic and Gore, and receives fellowship funding from Boston Scientific. J.M. Nieto is a consultant for Boston Scientific and ERBE. S. Andrawes is a consultant for Olympus. The remaining authors declare that they have no conflict of interest.

References

- [1] Ferreira LEVVC, Simmons DT, Baron TH. Zenker's diverticula: pathophysiology, clinical presentation, and flexible endoscopic management. *Dis Esophagus* 2008; 21: 1–8
- [2] Bizzotto A, Iacopini F, Landi R et al. Zenker's diverticulum: exploring treatment options. *Acta Otorhinolaryngol Ital* 2013; 33: 219–229
- [3] Patel NN, Singh T, Singh T. Cricopharyngeal dysphagia. In: Watkinson J, Clarke R. *Scott-Brown's Otorhinolaryngology and head and neck surgery*. Volume 3: Head and neck surgery, Plastic surgery. Boca Raton: Taylor & Francis; 2018: 853–870
- [4] Constantin A, Mates IN, Predescu D et al. Principles of surgical treatment of Zenker diverticulum. *J Med Life* 2012; 5: 92–97
- [5] Koay CB, Sharp HR, Bates GJ. Current practice in pharyngeal pouch surgery in England and Wales. *Ann R Coll Surg Engl* 1997; 79: 190–194
- [6] Collard J-M, Otte J-B, Kestens PJ. Endoscopic stapling technique of esophagodiverticulostomy for Zenker's diverticulum. *Ann Thorac Surg* 1993; 56: 5736
- [7] Ishioka S, Sakai P, Maluf Filho F et al. Endoscopic incision of Zenker's diverticula. *Endoscopy* 1995; 27: 433–437
- [8] Sakai P. Endoscopic myotomy of Zenker's diverticulum: lessons from 3 decades of experience. *Gastrointest Endosc* 2016; 83: 774–775
- [9] Sato H, Takeuchi M, Hashimoto S et al. Esophageal diverticulum: new perspectives in the era of minimally invasive endoscopic treatment. *World J Gastroenterol* 2019; 25: 1457–1464
- [10] Yang J, Zeng X, Yuan X et al. An international study on the use of peroral endoscopic myotomy (POEM) in the management of esophageal diverticula: the first multicenter D-POEM experience. *Endoscopy* 2019; 51: 346–349

- [11] Yang J, Novak S, Ujiki M et al. An international study on the use of peroral endoscopic myotomy in the management of Zenker's diverticulum. *Gastrointest Endosc* 2020; 91: 163–168
- [12] Huberty V, El Bacha S, Blero D et al. Endoscopic treatment for Zenker's diverticulum: long-term results (with video). *Gastrointest Endosc* 2013; 77: 701–707
- [13] Yuan Y, Zhao Y-F, Hu Y et al. Surgical treatment of Zenker's diverticulum. *Dig Surg* 2013; 30: 207–218
- [14] Dakkak M, Bennett JR. A new dysphagia score with objective validation. *J Clin Gastroenterol* 1992; 14: 99–100
- [15] Cotton PB, Eisen GM, Aabakken L et al. A lexicon for endoscopic adverse events: report of an ASGE workshop. *Gastrointest Endosc* 2010; 71: 446–454
- [16] Pop A, Tantau A, Tefas C et al. Flexible endoscopic treatment for Zenker's diverticulum – Experience on 31 patients. *J Gastrointest Liver Dis* 2018; 27: 227–231
- [17] Mittal C, Diehl DL, Draganov PV et al. Practice patterns, techniques, and outcomes of flexible endoscopic myotomy for Zenker's diverticulum: a retrospective multicenter study. *Endoscopy* 2021; 53: 346–353
- [18] Hernández Mondragón OV, Solórzano Pineda MO, Blancas Valencia JM. Zenker's diverticulum: submucosal tunneling endoscopic septum division (Z-POEM). *Dig Endosc* 2018; 30: 124
- [19] Brewer Gutierrez OI, Ichkhanian Y, Spadaccini M et al. Zenker's diverticulum per-oral endoscopic myotomy techniques: changing paradigms. *Gastroenterology* 2019; 156: 2134–2135
- [20] Fan HS, Stavert B, Chan DL et al. Management of Zenker's diverticulum using flexible endoscopy. *VideoGIE* 2019; 4: 87–90
- [21] Zaninotto G, Rizzetto C. Optimal therapy for cricopharyngeal diverticula. In: Ferguson MK. *Difficult decisions in thoracic surgery. An evidence-based approach*. London: Springer; 2011; 2nd edn: 293–301
- [22] Beard K, Swanström LL. Zenker's diverticulum: flexible versus rigid repair. *J Thorac Dis* 2017; 9: S154–162
- [23] Hernández M, Solórzano P, Blanco V et al. Use of cyanoacrylate to treat mucosal perforation during or after peroral endoscopic myotomy. *Endoscopy* 2016; 48: 330–331
- [24] Howell RJ, Giliberto JP, Harmon J et al. Open versus endoscopic surgery of Zenker's diverticula: a systematic review and meta-analysis. *Dysphagia* 2019; 34: 930–938
- [25] Ishaq S, Hassan C, Antonello A et al. Flexible endoscopic treatment for Zenker's diverticulum: a systematic review and meta-analysis. *Gastrointest Endosc* 2016; 83: 1076–1089
- [26] Leong SC, Wilkie MD, Webb CJ. Endoscopic stapling of Zenker's diverticulum: establishing national baselines for auditing clinical outcomes in the United Kingdom. *Eur Arch Otorhinolaryngol* 2012; 269: 1877–1884
- [27] Calavas L, Brenet E, Rivory J et al. Zenker diverticulum treatment: retrospective comparison of flexible endoscopic window technique and surgical approaches. *Surg Endosc* 2020; doi:10.1007/s00464-020-07865-1
- [28] Dissard A, Gilain L, Pastourel R et al. Functional results in endoscopic Zenker's diverticulum surgery. *Eur Ann Otorhinolaryngol Head Neck Dis* 2017; 134: 309–313
- [29] Barton MD, Detwiller KY, Palmer AD et al. The safety and efficacy of endoscopic Zenker's diverticulotomy: a cohort study. *Laryngoscope* 2016; 126: 2705–2710