

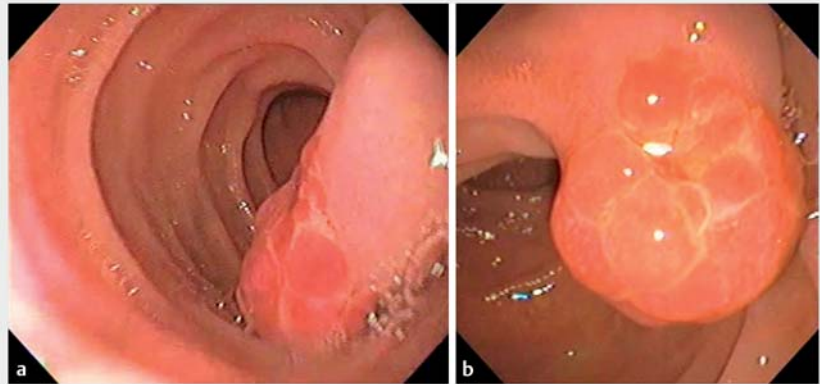
Endoscopic resection of a pediatric pyogenic granuloma of the major papilla

The lobular capillary hemangioma, also known as pyogenic granuloma, is a common benign vascular tumor that generally appears in the skin or oral cavity. Rarely, it may arise in the small intestine and cause refractory bleeding [1]. Resection is the mainstay of treatment as spontaneous regression is uncommon. We report the case of a 13-year-old girl presenting with chronic refractory iron-deficiency anemia. She complained of intermittent weakness over the past 3 years. Previous endoscopy and colonoscopy revealed only an edematous major papilla. Biopsy showed exuberant granulation tissue. At the time of referral to our center, she had already received several intravenous iron infusions and blood transfusions.

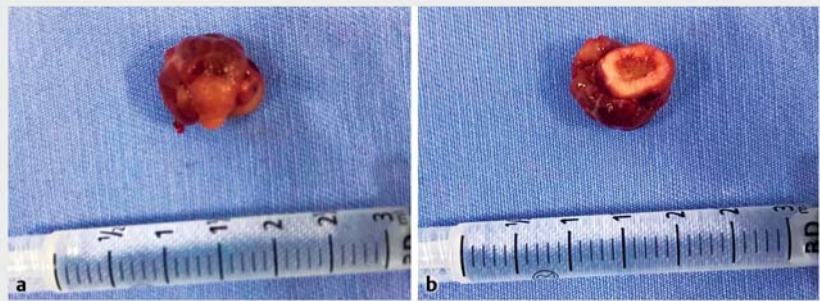
We performed a side-viewing endoscopy and found a 15-mm erythematous polypoid lesion in the major papilla (► Fig. 1). We performed new biopsies, and histopathological results were consistent with the diagnosis of pyogenic granuloma. We decided to proceed with an endoscopic papillectomy. We resected the major papilla using the standard technique, but we kept the snare entirely closed for 5 minutes before applying the electrical current. This technical peculiarity aimed to promote primary hemostasis, thus avoiding later bleeding (► Fig. 2, ► Video 1). The procedure was on an inpatient basis.

The patient had an uneventful postprocedural course and was discharged 3 days after the resection. At 6 months, hemoglobin levels and iron profile had returned to normal. She required no further intravenous iron infusion or blood transfusions. The specimen analysis confirmed the diagnosis of lobular capillary hemangioma (pyogenic granuloma) (► Fig. 3, ► Fig. 4).

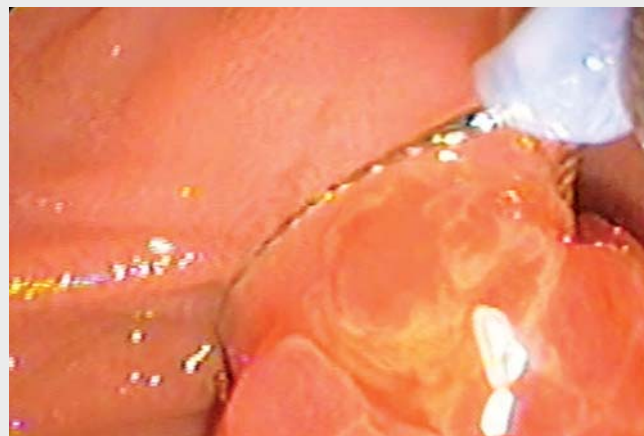This is the first report of a pediatric pyogenic granuloma in the major papilla; previous reports have all been in adults [2–5]. Pyogenic granuloma in the major papilla is rare and endoscopic resection



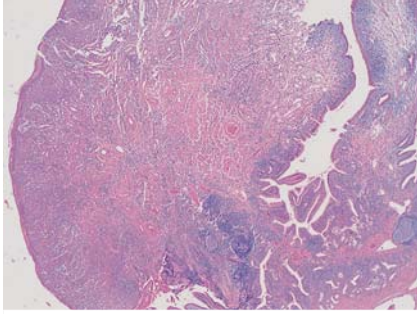
► Fig. 1 Endoscopic aspects of the pyogenic granuloma. **a, b** A 15-mm erythematous polypoid lesion was found in the major papilla.



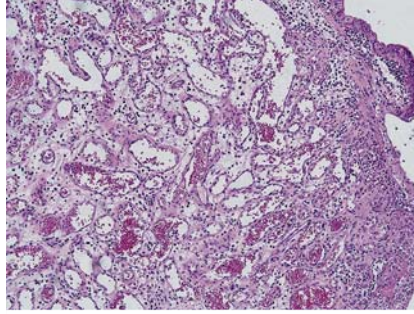
► Fig. 2 The resected specimen as a soft polypoid lesion of 20×15×12 mm. **a** Luminal side of the lesion. **b** Resection side of the lesion.



► Video 1 Endoscopic resection of a pyogenic granuloma of the major papilla.



► **Fig. 3** An ulcerated polypoid lesion in the major papilla mucosa. The lesion exhibited lobular architecture with an exophytic and non-infiltrative growth pattern (hematoxylin and eosin, $\times 20$).



► **Fig. 4** The lesion showed proliferation of capillary vessels with a rich component of inflammatory cells, edema, and sparse fibrosis, and no nuclear atypia or mitotic activity (hematoxylin and eosin, $\times 100$).

is a possible therapeutic alternative even in childhood.

Endoscopy_UCTN_Code_CPL_1AH_2AZ

Competing interests

The authors declare that they have no conflict of interest.

The authors

Ricardo Stefano da Penha¹, **Jose Eduardo Brunaldi¹**, **Gustavo Murad Pinton²**, **Lucas Tobias Almeida Queiroz¹**, **Yuri Zamban Vieira¹**, **Ligia Magnani Landell Camarero³**, **Vitor Ottoboni Brunaldi¹**

- 1 Center for Gastrointestinal Endoscopy, Surgery and Anatomy Department, Faculty of Medicine of Ribeirão Preto, Ribeirão Preto, Brazil
- 2 General Surgery Unit, São Francisco Hospital, Ribeirão Preto, São Paulo, Brazil

- 3 Pathology and Forensic Medicine Department, Faculty of Medicine of Ribeirão Preto, University of Sao Paulo, Ribeirão Preto, Brazil

Corresponding author

Ricardo Stefano da Penha, MD
Center for Gastrointestinal Endoscopy, Surgery and Anatomy Department, Faculty of Medicine of Ribeirão Preto, Bandeirantes Avenue 3900, Monte Alegre 14049-900, Ribeirão Preto, São Paulo, Brazil
stefano@hcrp.usp.br

References

- [1] Hayashi Y, Hosoe N, Takabayashi K et al. Clinical and endoscopic characteristics of pyogenic granuloma in the small intestine: a case series with literature review. *Intern Med* 2020; 59: 501–505
- [2] Korc P, McHenry L. An uncommon cause of chronic upper GI bleeding. *Gastrointest Endosc* 2016; 84: 524

- [3] Mandaliya R, Han S, Haddad N. Bleeding pyogenic granuloma of the ampulla of Vater: a rare cause of severe chronic anemia. *Gastrointest Endosc* 2019; 89: 1066–1067
- [4] Tang S, Bhajjee F. Pyogenic granuloma of the ampulla of Vater. *Video J Encycl GI Endosc* 2014; 1: 622–624
- [5] Camacho J, Pereira J, Arenas A. Hemangioma capilar como causa de colestasis extra-hepática: reporte de caso. *Gen* 2012; 66: 130–132

Bibliography

Endoscopy 2022; 54: E195–E196
DOI 10.1055/a-1480-6984
ISSN 0013-726X
published online 12.5.2021
© 2021. Thieme. All rights reserved.
Georg Thieme Verlag KG, Rüdigerstraße 14,
70469 Stuttgart, Germany

ENDOSCOPY E-VIDEOS

<https://eref.thieme.de/e-videos>



Endoscopy E-Videos is an open access online section, reporting on interesting cases

and new techniques in gastroenterological endoscopy. All papers include a high quality video and all contributions are freely accessible online. Processing charges apply (currently EUR 375), discounts and waivers acc. to HINARI are available.

This section has its own submission website at
<https://mc.manuscriptcentral.com/e-videos>