

Targeted Removal of Axillary Lymph Nodes After Carbon Marking in Patients with Breast Cancer Treated with Primary Chemotherapy

Gezielte Entfernung axillärer Lymphknoten nach Kohlenstoffmarkierung bei Patientinnen mit primär systemisch behandeltem Mammakarzinom

OPEN
ACCESS



Authors

Steffi Hartmann¹, Angrit Stachs¹, Thorsten Kühn², Jana de Boniface^{3,4}, Maggie Banys-Paluchowski^{5,6}, Toralf Reimer¹

Affiliations

- 1 Universitätsklinikum Rostock, Klinik für Gynäkologie und Geburtshilfe, Rostock, Germany
- 2 Klinikum Esslingen, Klinik für Gynäkologie und Geburtshilfe, Esslingen, Germany
- 3 Department of Molecular Medicine and Surgery, Karolinska Institutet, Stockholm, Sweden
- 4 Department of Surgery, Capio St. Görans Hospital, Stockholm, Sweden
- 5 Universitätsklinikum Schleswig-Holstein, Campus Lübeck, Klinik für Gynäkologie und Geburtshilfe, Lübeck, Germany
- 6 Medizinische Fakultät der Heinrich-Heine-Universität Düsseldorf, Düsseldorf, Germany

Key words

breast cancer, lymph nodes, carbon marking, primary chemotherapy, targeted axillary dissection, TAD

Schlüsselwörter

Mammakarzinom, Lymphknoten, Kohlenstoffmarkierung, primäre Chemotherapie, targeted axillary dissection, TAD

received 27.12.2020

accepted after revision 28.3.2021

Bibliography

Geburtsh Frauenheilk 2021; 81: 1121–1127

DOI 10.1055/a-1471-4234

ISSN 0016-5751

© 2021. The Author(s).

This is an open access article published by Thieme under the terms of the Creative Commons Attribution-NonDerivative-NonCommercial-License, permitting copying and reproduction so long as the original work is given appropriate credit. Contents may not be used for commercial purposes, or adapted, remixed, transformed or built upon. (<https://creativecommons.org/licenses/by-nc-nd/4.0/>)

Georg Thieme Verlag KG, Rüdigerstraße 14,
70469 Stuttgart, Germany

Correspondence

Dr. med. Steffi Hartmann

Universitätsklinikum Rostock, Klinik für Frauenheilkunde und Geburtshilfe am Klinikum Südstadt
Südring 81, 18059 Rostock, Germany
steffi.hartmann@kliniksued-rostock.de



Deutsche Version unter:

<https://doi.org/10.1055/a-1471-4234>

ABSTRACT

In breast cancer patients who have received primary chemotherapy and then no longer have any suspicious lymph nodes clinically and/or on imaging, marking of initially suspicious axillary lymph nodes with targeted removal has recently been discussed and practised both in Germany and internationally as an alternative to complete axillary lymph node dissection. Tattooing of the suspicious lymph nodes with a highly purified carbon suspension is currently being investigated in clinical studies. Compared with other techniques, the advantages of this method are the high rate of intraoperative lymph node detection, avoidance of an immediately preoperative localisation procedure and the low costs. The practical aspects of lymph node tattooing and the current data regarding this method will be described.

ZUSAMMENFASSUNG

Die Markierung und gezielte Entfernung initial suspekter axillärer Lymphknoten bei Mammakarzinompatientinnen, die eine primäre Systemtherapie erhalten und anschließend klinisch und/oder bildgebend keine suspekten Lymphknoten mehr aufweisen, wird aktuell sowohl in Deutschland als auch international als Alternative zur kompletten axillären Lymphknotendissektion diskutiert und praktiziert. Hierzu wird derzeit die Tätowierung der suspekten Lymphknoten mit hochgereinigter Kohlenstoffsuspension im Rahmen klinischer Studien untersucht. Im Vergleich zu anderen Techniken sind Vor-

teile dieser Methode die hohe Detektionsrate des Lymphknotens intraoperativ, der Verzicht auf Lokalisationsverfahren unmittelbar präoperativ und die geringen Kosten. Im Folgenden

sollen die praktische Durchführung der Lymphknotentätowierung und die aktuelle Datenlage zu dieser Methode erörtert werden.

Introduction

The radicality of axillary procedures in breast cancer patients with axillary lymph nodes that are not suspicious clinically and sonographically has been reduced in recent decades without a loss of oncological safety and for the benefit of patients due to lower complication rates. The ACOSOG-Z0011 study showed that complete axillary dissection (ALND) can be omitted for clinically node-negative patients having primary surgery without worsening the patients' prognosis, even when up to two sentinel lymph nodes (SLN) are affected by metastasis [1]. Whether ALND can also be omitted in initially node-positive breast cancer patients who receive primary systemic therapy (PST) is a subject of discussion and prospective data are not currently available. On the one hand, significantly worse prognosis was shown for patients who still demonstrate lymph node metastases after PST, even if micrometastases or isolated tumour cells were detectable exclusively [2]. On the other hand, ALND has not been shown to date to have an advantage regarding axillary recurrence and distant metastasis-free and overall survival after 10 years compared with sentinel lymph node biopsy (SLNB) alone for initially node-positive patients following PST [3]. These data were obtained retrospectively, however. The aim is to reduce the associated morbidity through a less radical axillary intervention while ensuring equal oncological safety, including in initially node-positive patients who are given PST and achieve complete pathological remission (pCR) in the axilla. Depending on tumour biology, such conversion is possible in 40 to 74% of patients with initially node-positive disease by means of modern systemic therapy agents [4–6]. For instance, in the subgroup of patients with HER2-positive and triple-negative breast cancer who no longer have residual tumour pathologically in the breast after PST, 89.6% also no longer have detectable lymph node metastases [7].

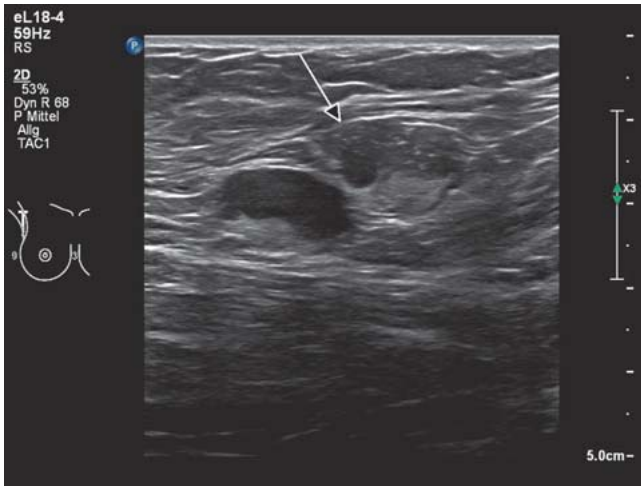
It is now also possible to omit ALND for patients who initially have suspicious axillary lymph nodes and in whom conversion to pathologically negative node status is achieved by PST. The Gynaecological Oncology Working Group (AGO) currently recommends targeted axillary dissection (TAD) for these patients as an alternative to ALND (in clinical studies where possible) [8]. This includes both axillary SLNB and targeted removal of one (or more) of the suspicious axillary lymph nodes marked before the PST ("target lymph node" – TLN) [9]. Compared with SLNB alone, for which a high false-negative rate (FNR) of 17% was found in these patients according to a meta-analysis, the FNR is 7% for removal of the TLN alone ("targeted lymph node biopsy" – TLNB). The FNR can be reduced further to 2–4% by combined removal of the lymph nodes by TAD [10–12]. Radioactive iodine¹²⁵ seeds were used initially for marking and intraoperative detection of the TLN. For radiation protection reasons, however, this procedure is not permitted in Germany and many other countries. Different methods of marking and removing the TLN are therefore being

studied currently. Marking the TLN prior to PST with a metal clip under ultrasound guidance is technically easy and can be performed safely but an intraoperative TLN detection rate of only up to 80% is described in prospective studies [11, 13]. The high detection rate recently presented at the San Antonio Breast Cancer Symposium (SABCS) 2020 for clip-marked TLNs of 94.3% in the TAXIS study (NCT03513614) cannot be translated to the situation after PST since 57.8% of the study participants had primary surgery [14]. An increase in the detection rate after PST to 96% and avoidance of additional preoperative localisation procedures are possible by using intraoperative ultrasound for TLN detection, but this requires that the operating surgeon has a high degree of sonographic experience [15]. There are currently very few data regarding the use of magnetic seeds, radar reflector and radiofrequency systems for TLNB as alternatives to marking with metal clips. Moreover, their use is associated with high costs and magnetic seeds can have a negative influence on the analysis of breast MRI scans by causing artefacts [16]. On the other hand, several prospective feasibility studies have already been published on low-cost marking of the TLN with carbon suspensions, which consistently report high detection rates. The practical TAD procedure will therefore be described below, and the available data will be presented.

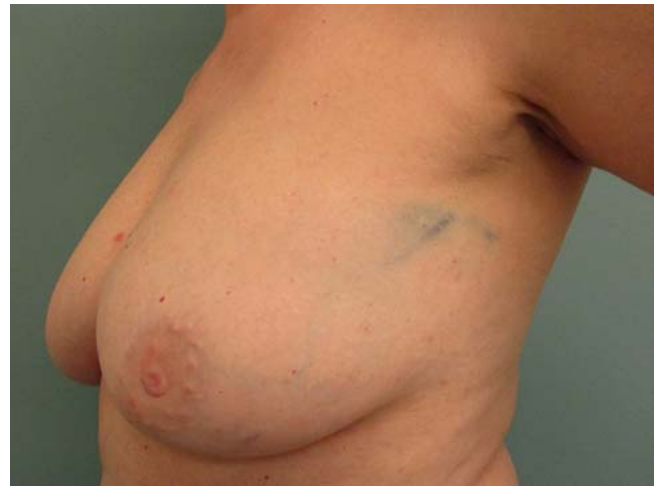Overview

Technical method of lymph node tattooing and subsequent TLNB

Tattooing of the TLN prior to PST is performed by injecting a highly purified carbon suspension under ultrasound guidance. Three carbon suspensions with the CE mark are available in Europe (► **Table 1**), which have been used to date in clinical studies of TLNB. The patient must be informed of the off-label use of the carbon solution before the tattooing, as it is licensed only for marking in the gastrointestinal tract and breast. The suspension should be shaken well immediately before the injection to ensure uniform distribution of the carbon particles. Local anaesthesia can be omitted if the injection does not take place in the same session as a minimally invasive histological or cytological biopsy of the TLN. A large enough needle should be used (CARBO-REP® at least 20 G, Spot® and Black Eye™ at least 25 G). Under ultrasound vision, the needle is advanced into the suspicious lymph node and the solution is injected into the cortex (anteriorly, as far as possible). Immediately after the injection, the hyperechoic carbon particles are visible in the lymph node on ultrasound (► **Fig. 1**). The injection volume depends on the size of the lymph node. The needle is then withdrawn from the lymph node and more of the solution is injected into the perinodal tissue, if possible anterior to the TLN. The injection channel should not be tattooed as this can lead to permanent undesirable staining in the skin (► **Fig. 2**).



► **Fig. 1** Hyperechoic carbon particles in the TLN (arrow) after tattooing. Immediately to the left of this, a further hypoechoic suspicious non-tattooed lymph node is visible.



► **Fig. 2** Permanent undesirable skin tattooing after carbon marking of the TLN.

After the PST additional marking of the TLN immediately before surgery is not necessary. After incising the skin and opening the axillary fascia, the grey to black marked perinodal tissue and the TLN are sought purely visually and removed (► **Fig. 3**). In patients with body tattoos on the upper body, detection of the iatrogenically tattooed lymph node can be more difficult if other lymph nodes are pigmented as a result of the cosmetic skin tattoo. A distinction is usually possible, however, as the perinodal tissue is pigmented only after TLN, so that a body tattoo is not an absolute contraindication to TLNB after carbon marking (► **Fig. 4**).

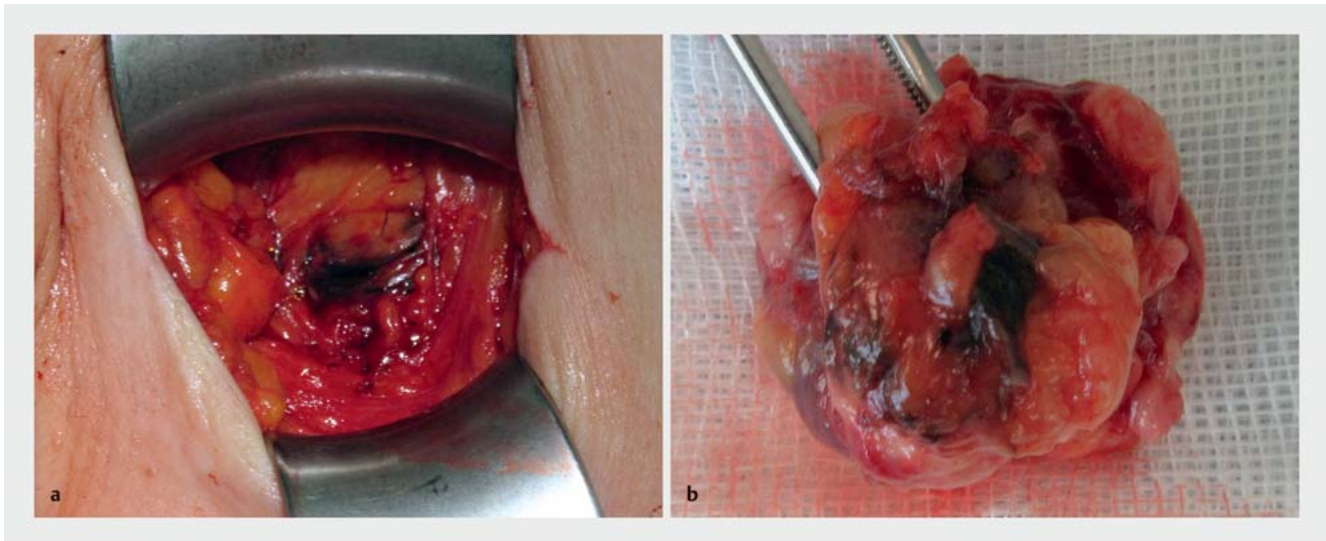
Studies of the feasibility of TLNB after carbon marking

Choy et al. published the first prospective pilot study of carbon marking of suspicious axillary lymph nodes in 2015, which included 12 breast cancer patients who had primary systemic therapy. Immediately after fine needle aspiration (FNA) or core biopsy of the lymph node, 0.1–0.5 ml Spot was injected into the biopsied lymph node and adjacent perinodal tissue. After the systemic therapy, the marked lymph node was detected purely visually in all patients and was removed [17]. Further feasibility studies have been published since then (► **Table 2**), which uniformly report high detection rates for carbon-marked TLNs. Two South Korean studies used Charcotrace™ for tattooing, a carbon suspension

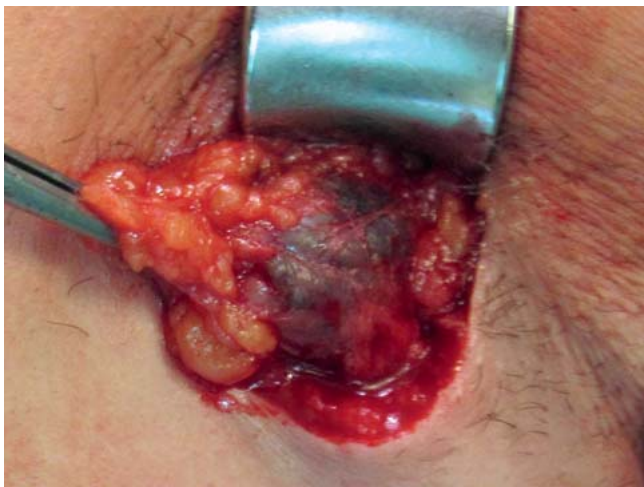from the Australian Phebra company, which does not have a CE mark. Park et al. injected 0.2–0.8 ml of the solution into the TLN of 20 patients under ultrasound vision before PST and did not observe any complications. The detection rates for TLN and SLN were 100%, and the TLN corresponded to one of the SLNs in 75% of cases. The authors report a FNR of 0% for TAD but ALND was performed in only 12 patients and the case number for assessing the FNR is therefore very low [18]. Kim et al. conducted a retrospective analysis of 45 patients, though the Charcotrace injection (1.0–3.0 ml) was given only after PST into axillary lymph nodes that remained suspicious on ultrasound. In this study, too, no adverse effects due to the tattooing were observed; the tattooed lymph node was detected at operation in 44 patients (98%) and matched the SLN in 57% [19]. The design of this study deviates, however, from the procedure currently recommended in Germany, which specifies marking of the TLN prior to PST and recommends ALND in the case of clinically suspicious lymph nodes after PST [8]. In another retrospective study from Greece, the Spot solution available in Europe as a medical device was used in 75 subjects but here all sonographically suspicious lymph nodes (n = 1–5) were tattooed prior to PST with 0.3–0.7 ml suspension. The number of tattooed lymph nodes detected at operation matched the number marked before PST in 94.6% of cases and in all cases

► **Table 1** Highly purified carbon suspensions with CE mark.

| Product | Manufacturer | Pack size | Approval | Cost per use |
|-----------------------------|------------------------------|-----------|--|--------------|
| CARBO-REP | Sterylab (Italy) | 12 × 2 ml | Preoperative marking of breast lesions | 36 Euro |
| Spot Endoscopic Marker | GI Supply (USA) | 10 × 5 ml | Marking in the gastrointestinal tract | 36 Euro |
| Black Eye Endoscopic Marker | Standard Company Ltd (Korea) | 10 × 5 ml | Marking in the gastrointestinal tract | 19 Euro |



► **Fig. 3** a Intraoperative detection of the tattooed perinodal tissue. b Tattooed TLN immediately after removal.



► **Fig. 4** Pigmented axillary SLN after cosmetic tattoo on the upper arm. (The perinodal tissue is not pigmented, unlike TLNB after iatrogenic lymph node tattooing.)

at least one tattooed lymph node was found at operation. The concordance rate of SLN and tattooed lymph nodes was 75.7%, and the FNR was not obtained as ALND was performed in only 24 subjects. The authors report that small foci of pigment deposits were visible in other lymph nodes on microscopy in 45% of the patients in the study in addition to the macroscopically visible tattooed lymph nodes. It must therefore be assumed that a certain migration of the carbon solution into other lymph nodes can take place. Microscopic detection of pigment alone (i.e., not visible with the naked eye) can therefore not be regarded as evidence of successful removal of the TLN [20]. The prospective study by Patel et al. included the 12 patients from the pilot study by Choy et al. referred to above [17] in addition to the 47 patients who received

primary systemic therapy, in whom 0.1–1.0 ml Spot was injected under ultrasound vision into the cortex of the TLN and the perinodal fat tissue prior to PST. This study obtained a detection rate of 100% for the TLN and a concordance rate between TLN und SLN likewise of 100% after PST [21]. As in the other studies in which dual SLN marking with radioisotope and blue dye took place, the detection of blue-marked SLNs in the pigmented tissue is described by the authors as more difficult but is usually successful as the blue-dyed lymphatic vessel leading to the SLN can be identified [18, 20, 21]. Possibly, the use of two dark dyes and the associated difficulty in distinguishing them contributes to the very high concordance rate between the SLN and TLN. In a prospective multicentre Israeli study, 1–2 suspicious axillary lymph nodes were marked with Spot in 63 patients before or shortly after the start of the PST. Under ultrasound guidance 0.2–0.5 ml was injected into the lymph node cortex exclusively. Unlike the other studies already described, in line with the German AGO recommendations, SLN marking was performed only in the case of lymph node status that was no longer suspicious clinically and sonographically after PST. In 60 cases (95.2%), at least one tattooed lymph node was detected at operation. In 40 of 50 cases, in which a SLN was identified, this was also tattooed (80%). In 3 cases (5.6%) TLNs were involved by metastasis but not the corresponding SLN, so that a completing ALND was indicated as a result of the additional removal of the TLN [22]. The multicentre prospective British pre-ATNEC study included 110 participants but only 22 of them received PST and 88 had primary surgery. Carbon suspension 0.3–2.9 ml was used, either Spot or Black Eye. In the 22 patients who had neoadjuvant treatment, TLN and SLN matched in 100% but the detection rate of the TLN was significantly lower at 64% than in the group that had primary surgery, where it was 86%. This lower detection rate compared with the other studies was explained by the higher median volume of carbon solution of 2.0 ml, which led in 31 cases to diffuse black staining in the axillary tissue, making it more difficult to find the TLN.

► **Table 2** Overview of published feasibility studies with targeted removal of carbon-marked axillary lymph nodes after PST of breast cancer (n = 382 in total).

| Study | Number of patients (n) | Carbon solution used | DR of tattooed LNs (%) | Tattooed LN = SLN (%) |
|--------------------------|------------------------|----------------------|------------------------|-----------------------|
| Park et al. [18] | 20 | Charcotrace | 100 | 75 |
| Kim et al. [19] | 45 | Charcotrace | 98 | 57 |
| Natsiopoulou et al. [20] | 75 | Spot | 94.6 | 75.7 |
| Patel et al. [21] | 47 | Spot | 100 | 100 |
| Allweis et al. [22] | 63 | Spot | 95.2 | 80 |
| Goyal et al. [23] | 22 | Spot Black Eye | 64 | 100 |
| Hartmann et al. [24] | 110 | Spot CARBO-REP | 93.6 | 59.7 |

PST: primary systemic therapy, DR: detection rate, LN: lymph node, SLN: sentinel lymph node

From ex vivo injection of carbon suspension into lymph nodes the authors defined a volume of 0.2–0.4 ml as sufficient to achieve leakage of carbon particles into the perinodal tissue but it remained open in the discussion whether metastatic lymph nodes were used before or after PST and which of the two suspensions was used in this study. Axillary skin staining was reported in one patient as an undesirable effect [23].

The largest feasibility study of tattooing of the axillary TLN published to date is the prospective, multicentre TATTOO study, which analysed the data from 110 patients who received primary systemic therapy. Spot or CARBO-REP 0.3–5.0 ml was used for ultrasound-guided lymph node tattooing prior to PST. Skin staining in the axilla occurred as an undesirable side effect in five patients (4.5%), and in four of these cases, besides tattooing the TLN and perinodal fat tissue, carbon was also injected actively into the injection channel towards the skin while withdrawing the needle. A TLN was detected at operation in 93.6% (103 of 110 cases) and the concordance rate with the SLN, which was marked only in the case of lymph nodes no longer clinically suspicious after PST, was 59.7%. A FNR of 9.1% (three of 33 cases) was found for TAD. This is below the generally accepted limit of 10% but is higher than in previous studies of TAD. The authors explain this, among other things, by the different definition of the SLN in the individual studies and the low total number of node-positive patients after PST in the TATTOO study as only patients with metastatic lymph nodes after PST who had complete ALND were included for calculation of the FNR [24]. Tattooing did not make histopathological lymph node assessment more difficult in any of the studies [17, 18, 21, 22, 24].

Outlook

The listed studies have shown the feasibility of TLNB after PST and initial tattooing of the TLN though the optimal volume of the carbon suspension to be injected is currently unclear. This should be the subject of future studies, especially with regard to undesirable side effects such as skin tattooing and the TLN detection rate. The data on the FNR of TAD after carbon marking are very few and inconsistent (0–9.1%) [18, 24]. In particular, there are no prospective studies in which tattooing of the TLN is compared with other

TAD techniques with regard to feasibility, detection rate and FNR. It has been shown in individual studies that the FNR is lower when several suspicious lymph nodes are marked than when only the first TLN, the so-called “lead lymph node metastasis”, is marked and removed [25]. The association between the number of marked lymph nodes and the FNR is further supported by the observation that individual lymph nodes show a heterogeneous response to PST [26]. The high costs of some markers can potentially make marking of a number of lymph nodes more difficult, however. In this context, the low cost of the carbon suspension is a further advantage.

Moreover, none of the TAD studies published hitherto had an oncological endpoint. A recent prospective cohort study in 78 patients shows that removal of the TLN in addition to the SLN led in only one case to ALND being performed and that this had no influence on the further treatment recommendation [27]. The question of an acceptable cut-off for the FNR thus remains unclear. There are also no prospective data currently for the optimal locoregional therapy of metastatic TAD lymph nodes after PST (completing ALND, radiation) so therapy options should be discussed by a multidisciplinary tumour board. In addition, none of the studies to date has evaluated quality of life and arm morbidity after TAD and TLNB. A comparison of different marking techniques appears particularly important here, as carbon-based marking, unlike probe-assisted techniques (including magnetic, radioactive and radar-based markers) and wire localisation, requires a certain degree of axillary exploration to visualise the dye.

These and other unanswered questions should be answered in the AXSANA study (NCT04373655, axsana.eubreast.com). The primary aims of this international, prospective, multicentre registry study initiated by the EUBREAST study group are both the oncological endpoints, disease-free 5-year survival and 3-year rate of axillary recurrence as well as the quality of life in 3000 initially node-positive breast cancer patients, in whom suspicious lymph nodes are no longer present on palpation and imaging following PST. The different axillary operation techniques (SLNB, TLNB, TAD, ALND) will be compared with one another. Secondary study aims that will be analysed include the different techniques for TLN marking and detection for patients who have TLNB or TAD with

► **Table 3** Advantages and disadvantages of carbon marking of the TLN compared with other marking methods.

| Advantages | Disadvantages |
|--|---|
| Simple marking technique | Optimal injection volume unclear |
| Low costs | Off-label use |
| No additional preoperative localisation procedure needed | Interaction with body tattoo |
| High patient comfort | Transcutaneous localisation not possible |
| No additional radiation | Axillary exploration necessary to visualise the dye |

regard to detection rates, complications and FNR. All techniques known to date for TAD/TLNB are permitted in the study. Recruitment to the AXSANA study started in June 2020, and on 15.02.2021 86 centres in six countries had already begun the study [28]. In addition, the TATTOO study is continuing in Sweden, where, unlike Germany, TAD alone is not yet standard in breast cancer after PST and initially suspicious lymph nodes and ALND is currently performed in these patients so that further prospective data regarding FNR can be expected from a larger patient population. Although the costs of tattooing itself are low, they are not currently reimbursed by the statutory health insurers. Invoicing to cover the costs is not possible for all other axillary lymph node marking techniques either. In addition, the less radical axillary operation of TAD is reimbursed more poorly financially compared with ALND. In future, the specialist societies in particular should work actively to ensure that the introduction of such innovative techniques for the benefit of our patients is not penalised by worse financial remuneration.

Conclusions

The feasibility of TLNB of carbon marking in patients with initially node-positive breast cancer after PST has been investigated in a number of studies in over 380 patients and has shown high detection rates and low complication rates. Compared with other techniques, the advantages are the low cost and high patient comfort due to the elimination of additional preoperative, imaging-assisted localisation procedures, which are sometimes associated with additional radiation and pain (► **Table 3**). After informing patients about the off-label use, tattooing of the TLN can be performed under ultrasound control and purely visual intraoperative detection of the marked TLN after PST is possible in the majority of cases. The AXSANA study will be the first to deliver comparative data regarding other TAD techniques.

Conflict of Interest

The authors declare that they have no conflict of interest.

References

- [1] Giuliano AE, Ballman KV, McCall L et al. Effect of axillary dissection versus no axillary dissection on 10-year overall survival among women with invasive breast cancer and sentinel node metastasis: The ACOSOG Z0011 (Alliance) randomized clinical trial. *JAMA* 2017; 318: 918–926
- [2] Wong SM, Almana N, Choi J et al. Prognostic significance of residual axillary nodal micrometastases and isolated tumor cells after neoadjuvant chemotherapy for breast cancer. *Ann Surg Oncol* 2019; 26: 3502–3509
- [3] Kahler-Ribeiro-Fontana S, Pagan E, Magnoni F et al. Long-term standard sentinel node biopsy after neoadjuvant treatment in breast cancer: a single institution ten-year follow-up. *Eur J Surg Oncol* 2020. doi:10.1016/j.ejso.2020.10.014
- [4] Dominici LS, Negron Gonzalez VM, Buzdar AU et al. Cytologically proven axillary lymph node metastases are eradicated in patients receiving preoperative chemotherapy with concurrent trastuzumab for HER2-positive breast cancer. *Cancer* 2010; 116: 2884–2889
- [5] Boughey JC, McCall LM, Ballman KV et al. Tumor biology correlates with rates of breast-conserving surgery and pathologic complete response after neoadjuvant chemotherapy for breast cancer: findings from the ACOSOG Z1071 (Alliance) Prospective Multicenter Clinical Trial. *Ann Surg* 2014; 260: 608–614
- [6] Diego EJ, McAuliffe PF, Soran A et al. Axillary staging after neoadjuvant chemotherapy for breast cancer: a pilot study combining sentinel lymph node biopsy with radioactive seed localization of pre-treatment positive axillary lymph nodes. *Ann Surg Oncol* 2016; 23: 1549–1553
- [7] Tadros AB, Yang WT, Krishnamurthy S et al. Identification of patients with documented pathologic complete response in the breast after neoadjuvant chemotherapy for omission of axillary surgery. *JAMA Surg* 2017; 152: 665–670
- [8] Arbeitsgemeinschaft Gynäkologische Onkologie e.V. Empfehlungen gynäkologische Onkologie Kommission Mamma 2021. Neoadjuvante (Primäre) systemische Therapie. Accessed May 26, 2021 at: https://www.ago-online.de/fileadmin/ago-online/downloads/_leitlinien/kommission_mamma/2021/Einzeldateien/2021D_12_Neoadjuvante_systemische_Therapie_MASTER_final_20210301.pdf
- [9] Caudle AS, Yang WT, Krishnamurthy S et al. Improved axillary evaluation following neoadjuvant therapy for patients with node-positive breast cancer using selective evaluation of clipped nodes: implementation of targeted axillary dissection. *J Clin Oncol* 2016; 34: 1072–1078
- [10] Simons JM, van Nijnatten TJA, van der Pol CC et al. Diagnostic accuracy of different surgical procedures for axillary staging after neoadjuvant systemic therapy in node-positive breast cancer. *Ann Surg* 2019; 269: 432–442
- [11] Kuemmel S, Heil J, Rueland A et al. A prospective, multicenter registry study to evaluate the clinical feasibility of targeted axillary dissection (TAD) in node-positive breast cancer patients. *Ann Surg* 2020. doi:10.1097/SLA.0000000000004572
- [12] Simons JM, van Nijnatten TJA, Koppert LB et al. Radioactive Iodine Seed placement in the Axilla with Sentinel lymph node biopsy after neoadjuvant chemotherapy in breast cancer: Results of the prospective multicenter RISAS trial. San Antonio Breast Cancer Symposium 2020, virtual edition, abstract GS1–10
- [13] Hartmann S, Reimer T, Gerber B et al. Wire localization of clip-marked axillary lymph nodes in breast cancer patients treated with primary systemic therapy. *Eur J Surg Oncol* 2018; 44: 1307–1311
- [14] Weber WP, Henke G, Hayoz S et al. Tailored axillary surgery with or without axillary lymph node dissection followed by radiotherapy in patients with clinically node-positive breast cancer: a multicenter randomized phase III trial (SAKK 23/16/IBCSG 57-18/ABCSG-53/GBG 101 – TAXIS). Poster Presentation at San Antonio Breast Cancer Symposium 08.–11.12.2020 (OT-04-03, PD 04-04)

- [15] Siso C, de Torres J, Esgueva-Colmenarejo A et al. Intraoperative ultrasound-guided excision of axillary clip in patients with node-positive breast cancer treated with neoadjuvant therapy (ILINA Trial): a new tool to guide the excision of the clipped node after neoadjuvant treatment. *Ann Surg Oncol* 2018; 25: 784–791
- [16] Banys-Paluchowski M, Gruber IV, Hartkopf A et al. Axillary ultrasound for prediction of response to neoadjuvant therapy in the context of surgical strategies to axillary dissection in primary breast cancer: a systematic review of the current literature. *Arch Gynecol Obstet* 2020; 301: 341–353
- [17] Choy N, Lipson J, Porter C et al. Initial results with preoperative tattooing of biopsied axillary lymph nodes and correlation to sentinel lymph nodes in breast cancer patients. *Ann Surg Oncol* 2015; 22: 1–6
- [18] Park S, Koo JS, Kim GM et al. Feasibility of charcoal tattooing of cytology-proven metastatic axillary lymph node at diagnosis and sentinel lymph node biopsy after neoadjuvant chemotherapy in breast cancer patients. *Cancer Res Treat* 2018; 50: 801–812
- [19] Kim WH, Kim HJ, Jung HJ et al. Ultrasound-guided restaging and localization of axillary lymph nodes after neoadjuvant chemotherapy for guidance of axillary surgery in breast cancer patients: experience with activated charcoal. *Ann Surg Oncol* 2018; 25: 494–500
- [20] Natsiopoulos I, Intzes S, Liappis T et al. Axillary lymph node tattooing and targeted axillary dissection in breast cancer patients presented cN+ before neoadjuvant chemotherapy and became cN0 after treatment. *Clin Breast Cancer* 2019; 19: 208–215
- [21] Patel R, MacKerricher W, Tsai J et al. Pretreatment tattoo marking of suspicious axillary lymph nodes: reliability and correlation with sentinel lymph node. *Ann Surg Oncol* 2019; 26: 2452–2458
- [22] Allweis TM, Menes T, Rotbart N et al. Ultrasound guided tattooing of axillary lymph nodes in breast cancer patients prior to neoadjuvant therapy, and identification of tattooed nodes at the time of surgery. *Eur J Surg Oncol* 2020; 46: 1041–1045
- [23] Goyal A, Puri S, Marshall A et al. A multicenter prospective feasibility study of carbon dye tattooing of biopsied axillary node and surgical localization in breast cancer patients. *Breast Cancer Res Treat* 2020. doi:10.1007/s10549-020-05961-3
- [24] Hartmann S, Kuehn T, de Boniface J et al. The prospective multicenter TATTOO trial evaluating carbon tattooing for targeted lymph node biopsy after primary systemic therapy in breast cancer patients. *Br J Surg* 2021. doi:10.1093/bjs/znaa083
- [25] Lim GH, Gudi M, Teo SY et al. Would removal of all ultrasound abnormal metastatic lymph nodes without sentinel lymph node biopsy be accurate in patients with breast cancer with neoadjuvant chemotherapy? *Oncologist* 2020; 25: e1621–e1627
- [26] Glaeser A, Sinn HP, Garcia-Etienne C et al. Heterogeneous responses of axillary lymph node metastases to neoadjuvant chemotherapy are common and depend on breast cancer subtype. *Ann Surg Oncol* 2019; 26: 4381–4389
- [27] Weiss A, King C, Grossmith S et al. How often does retrieval of a clipped lymph node change adjuvant therapy recommendations? A prospective consecutive patient cohort study. Poster Presentation at San Antonio Breast Cancer Symposium 08.–11.12.2020 (PD 04-06)
- [28] Banys-Paluchowski M, Stickeler E, de Boniface J et al. AXillary Surgery After NeoAdjuvant treatment: an international prospective multicenter cohort study of the EUBREAST study group to evaluate different surgical methods of axillary staging in clinically node-positive breast cancer patients treated with neoadjuvant chemotherapy. Poster Presentation at San Antonio Breast Cancer Symposium 08.–11.12.2020 (OT-04-02)