Article published online: 2021-04-28

Endoscopic ultrasound-guided rendezvous for extrahepatic bile duct recanalization after surgical transection

A 36-year-old woman developed jaundice, fever, and biliary leak after laparoscopic cholecystectomy. Endoscopic retrograde cholangiopancreatography (ERCP) (▶ **Video 1**) identified massive extravasation of contrast into the peritoneum through a large fistula, without filling of the proximal biliary tract (▶ **Fig. 1**). Cholangioscopy (SpyGlass; Boston Scientific Corp., Marlborough, Massachusetts, USA) showed the confluence between the hepatic and cystic ducts, and the peritoneal space was accessed through a complete transection of the hepatic duct (▶ **Fig. 2**), with identification of the percutaneous surgical catheter and the liver. The proximal aspect of the transected hepatic duct could not be found with the cholangioscope. Using endoscopic ultrasound (EUS), the proximal and distal segments of the extrahepatic bile duct were identified, separated by a 1.5-cm-diameter collection. Transgastric puncture of the intrahepatic bile duct with a 22-G needle was performed, hindered by lack of duct dilation. A 0.018-inch guidewire was advanced anterogradely through the transection into the distal common bile duct and duodenum. The EUS-guided rendezvous was finally completed and an 80 × 10-mm fully covered metal stent was deployed in the subsequent ERCP (▶ **Fig. 3**). The proximal end was placed immediately distal to the biliary confluence and the distal end into the duodenal lumen, securing bilateral biliary drainage. The patient's jaundice resolved within a few days, and 6 months after discharge the patient remains asymptomatic.

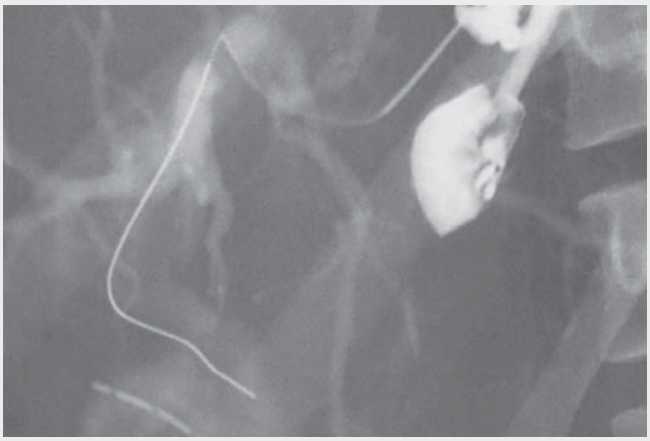

Video 1 Successful management of extrahepatic bile duct transection by means of a purely endoscopic approach combining endoscopic ultrasound-guided rendezvous and endoscopic retrograde cholangiopancreatography. This combined procedure was performed during a single endoscopic session.

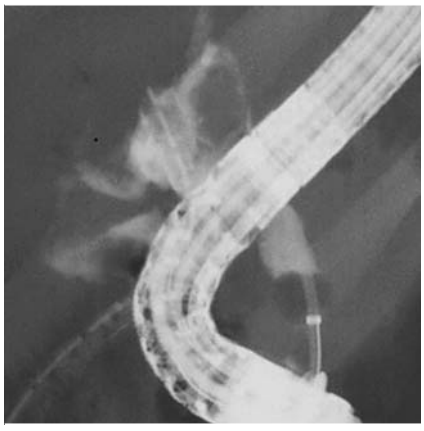

▶ **Fig. 1** Cholangiography shows massive leakage of contrast from the middle portion of the extrahepatic bile duct.

▶ **Fig. 2** Intraductal cholangioscopy shows complete transection of the hepatic duct with inflammatory changes in the borders.

Complete transection of the common bile duct is a severe complication of hepatobiliary surgery which usually requires subsequent open surgical treatment by means of Roux-en-Y hepaticojejunostomy or choledochojejunostomy. However, successful management with a less invasive percutaneous approach or a combination of percutaneous and endoscopic approaches has also been described [1–4]. EUS-guided rendezvous is commonly indicated in patients with an accessible papillary area where cannulation is not feasible [5]. We report a case in which extrahepatic bile duct transection was successfully managed with a purely endoscopic approach combining EUS-guided rendezvous and ERCP, which, so far as we know, has not been described previously.

Endoscopy_UCTN_Code_TTT_1AS_2AD

▶ **Fig. 3** After successful endoscopic ultrasound-guided rendezvous, a fully covered self-expanding metallic stent is deployed, connecting the proximal and distal segments of the extrahepatic bile duct.

Competing interests

Dr. Juan J. Vila is a consultant for Boston Scientific and has lectured for Olympus and Cook Endoscopy. The other authors declare that they have no conflict of interest.

The authors

Diego Martínez-Acitores de la Mata[1], Lucía Zabalza[1], Verónica Ubieto[1], José Luis Moya[2], Juan Carrascosa[1], Soledad Montón[2], Juan J. Vila[1]

1 Endoscopy Unit, Gastroenterology Department, Complejo Hospitalario de Navarra, Pamplona, Spain
2 Surgery Department, Hospital Garcia Orcoyen, Estella, Spain

Corresponding author

Diego Martínez-Acitores de la Mata, MD
Endoscopy Unit, Gastroenterology Department, Complejo Hospitalario de Navarra, C/ Irunlarrea 3, 31008 Pamplona, Spain
diegoacitores132@hotmail.com

References

[1] Lindemann J, Kloppers C, Burmeister S et al. Mind the gap! Extraluminal percutaneous-endoscopic rendezvous with a self-expanding metal stent for restoring continuity in major bile duct injury: a case series Int J Surg Case Rep 2019; 60: 340–344
[2] Schreuder AM, Booij KAC, de Reuver PR et al. Percutaneous-endoscopic rendezvous procedure for the management of bile duct injuries after cholecystectomy: short- and long-term outcomes. Endoscopy 2018; 50: 577–587
[3] Shin S, Klevan A, Fernandez CA et al. Rendezvous technique for the treatment of complete common bile duct transection after multiple hepatobiliary surgeries. J Laparoendosc Adv Surg Tech A 2014; 24: 728–730
[4] Schreuder AM, Booij KAC, de Reuver PR et al. Percutaneous-endoscopic rendezvous procedure for the management of bile duct injuries after cholecystectomy: short- and long-term outcomes. Endoscopy 2018; 50: 577–587
[5] Vanella G, Bronswijk M, Maleux G et al. EUS-guided intrahepatic biliary drainage: a large retrospective series and subgroup comparison between percutaneous drainage in hilar stenoses or postsurgical anatomy. Endosc Int Open 2020; 8: E1782–E1794

Bibliography

Endoscopy 2022; 54: 431–432
DOI 10.1055/a-1471-1685
ISSN 0013-726X
published online 28.4.2021

Georg Thieme Verlag KG, Rüdigerstraße 14, 70469 Stuttgart, Germany