Article published online: 2021-02-19

Endoscopic septotomy for fistula after bariatric surgery

Gastric fistula following bariatric surgery is a complication with considerable morbidity and mortality [1, 2]. After Roux-en-Y gastric bypass (RYGB), the gastric pouch may develop a chronic fistula and the formation of a perigastric cavity bounded by a septum. The altered anatomy chronically elevates the intraluminal pressure, impairing emptying of the perigastric cavity and perpetuating the fistula [3].

Endoscopic septotomy is a minimally invasive technique for cutting the septum. The goals are ensuring adequate patency of the perigastric cavity, decreasing its pressure, and draining the fistula [1, 4, 5].

A 67-year-old woman underwent a RYGB (body mass index: 48 kg/m² before, 25 kg/m² after). She developed a gastrocutaneous fistula, which was unsuccessfully treated with a long-term nasoenteric tube. Eight months after RYGB, she was referred for endoscopic assessment (▶ **Video 1**). Sutures were identified in the greater curvature of the gastric pouch. They were removed with endoscopic scissors and a perigastric cavity (bounded by a septum) with a fistula orifice in it was identified. The fistula orifice was initially treated with argon plasma coagulation and a guidewire was externalized through the fistula's cutaneous orifice (▶ **Fig. 1**), with placement of a 7-Fr double-pigtail stent in the fistula tract. After 3 months, the gastrocutaneous leak was reduced but not resolved. We removed the pigtail, performed a septotomy with an IT knife, and placed an esophageal fully covered (28 × 160 mm) self-expandable metal stent. The proximal end of the stent was fixed by endosuture to avoid migration. After 1 week, the stent was removed and the patient was able to take a soft diet. Four weeks later, the cutaneous fistula orifice was closed (▶ **Fig. 2**) and esophagogastroduodenoscopy confirmed closure of the fistula's gastric orifice (▶ **Fig. 3**). At 3 weeks' follow-up, the patient was asymptomatic and doing well on a regular diet.

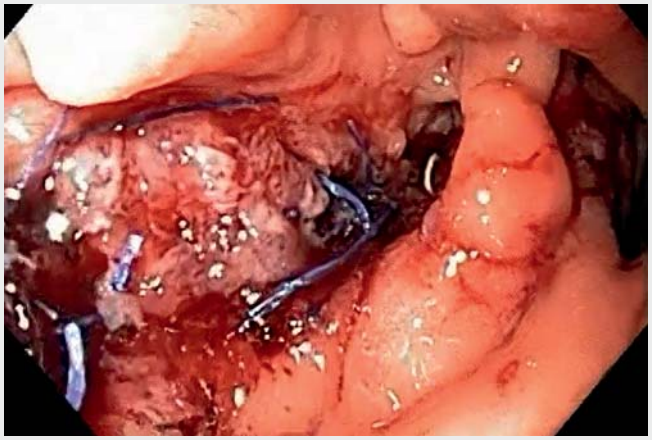

▶ **Video 1** Complex fistulas after bariatric surgery require challenging endoscopic management. We report a case of bariatric surgery complicated by gastrocutaneous fistula, which was successfully treated with endoscopic septotomy.

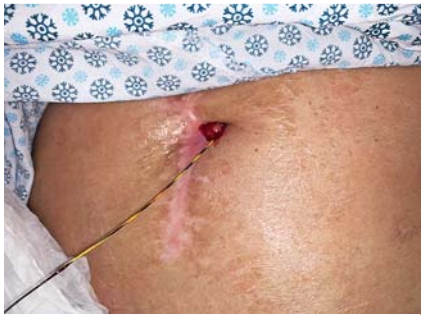

▶ **Fig. 1** Guidewire externalized through the cutaneous orifice of the fistula.

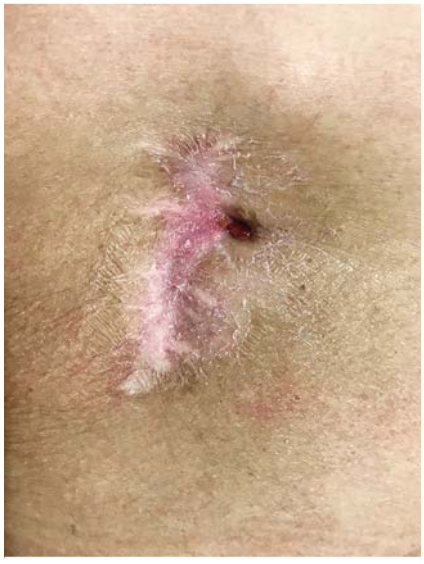

▶ **Fig. 2** The cutaneous fistula orifice is closed.

Endoscopy_UCTN_Code_CPL_1AH_2AG

Competing interests

The authors declare that they have no conflict of interest.

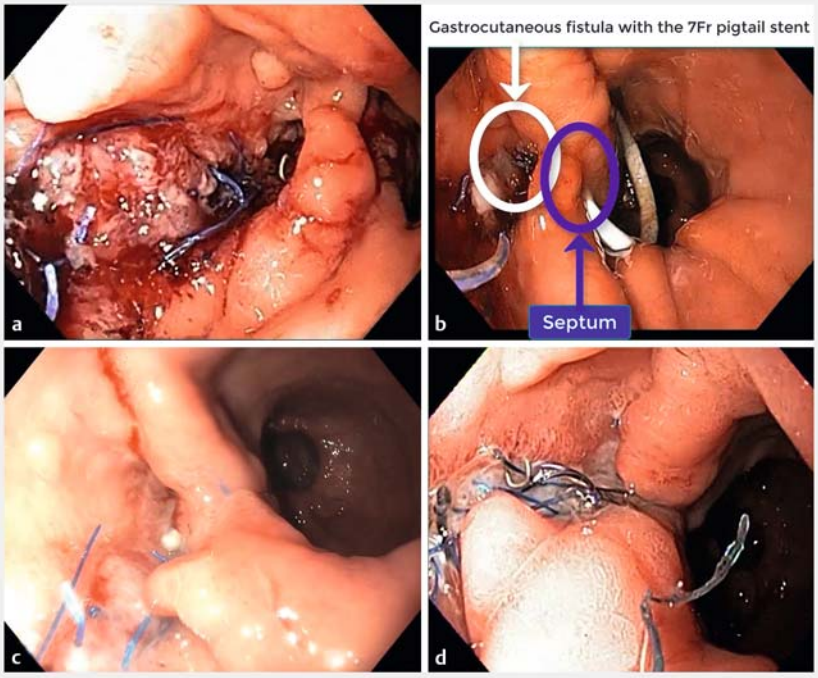

▶ **Fig. 3** Endoscopic appearance of the perigastric cavity: **a** after suture removal, **b** after 7-Fr double-pigtail insertion through the fistula orifice, and **c** after treatment with argon plasma coagulation and 7-Fr double-pigtail stent. **d** Closed fistula after septotomy (final appearance).

The authors

Mateus Bond Boghossian, Mateus Pereira Funari, Epifanio Silvino do Monte Junior, Rodrigo Silva de Paula Rocha, Diogo Turiani Hourneaux de Moura, Thiago Ferreira de Souza, Eduardo Guimarães Hourneaux de Moura
Gastrointestinal Endoscopy Unit, Hospital das Clínicas da Faculdade de Medicina da Universidade de São Paulo, São Paulo, Brazil

Corresponding author

Mateus Bond Boghossian, MD
Av. Dr Enéas de Carvalho Aguiar 225, 6º andar, bloco 3, Cerqueira César, 05403-010 – São Paulo, SP, Brazil
mateus.boghossian@hc.fm.usp.br

References

[1] Baretta G, Campos J, Correia S et al. Bariatric postoperative fistula: a life-saving endoscopic procedure. Surg Endosc 2015; 29: 1714–1720
[2] Campos JM, Pereira EF, Evangelista LF et al. Gastrobronchial fistula after sleeve gastrectomy and gastric bypass: endoscopic management and prevention. Obes Surg 2011; 21: 1520–1529
[3] Angrisani L, Hasani A, Santonicola A et al. Endoscopic septotomy for the treatment of sleeve gastrectomy fistula: timing and indications. Obes Surg 2018; 3: 846–847
[4] Rodrigues-Pinto E, Repici A, Donatelli G et al. International multicenter expert survey on endoscopic treatment of upper gastrointestinal anastomotic leaks. Endosc Int Open 2019; 7: E1671–E1682
[5] Mahadev S, Kumbhari V, Campos JM et al. Endoscopic septotomy: an effective approach for internal drainage of sleeve gastrectomy-associated collections. Endoscopy 2017; 49: 504–508

Bibliography

Endoscopy 2022; 54: E38–E39
DOI 10.1055/a-1375-0159
ISSN 0013-726X
published online 19.2.2021

Georg Thieme Verlag KG, Rüdigerstraße 14, 70469 Stuttgart, Germany