

Overutilization of surgery for the resection of benign colorectal lesions: the hidden reasons for inappropriate referral!




Authors

Mathieu Pioche¹, Eddy Cotte², Cesare Hassan³

Institutions

- 1 Hepatogastroenterology division, Edouard Herriot Hospital, Hospices civils de Lyon, France
- 2 Department of digestive and oncological surgery, Lyon Sud Hospital, Hospices Civils de Lyon, France
- 3 Department of gastroenterology and endoscopy, Nuovo Regina Margherita Hospital Rome, Italy

Bibliography

Endosc Int Open 2021; 09: E713–E715

DOI 10.1055/a-1373-5176

ISSN 2364-3722

© 2021. The Author(s).

This is an open access article published by Thieme under the terms of the Creative Commons Attribution-NonDerivative-NonCommercial License, permitting copying and reproduction so long as the original work is given appropriate credit. Contents may not be used for commercial purposes, or adapted, remixed, transformed or built upon. (<https://creativecommons.org/licenses/by-nc-nd/4.0/>)

Georg Thieme Verlag KG, Rüdigerstraße 14,
70469 Stuttgart, Germany

Corresponding author

Mathieu Pioche, MD, PHD, Service de gastro-entérologie et d'endoscopie digestive, Pavillon L, Hôpital Edouard Herriot, 5 place d'Arsonval, 69437 Lyon, France

Fax: +33472110147

mathieu.pioche@chu-lyon.fr

At the beginning, it was surgery! Surgery was the only pre-endoscopic technique to remove colorectal polyps detected at barium enema or proctoscopy. When endoscopic polypectomy was introduced, it was clear that most of the polyps could be removed noninvasively. In the pre-endoscopic mucosal resection (EMR) era, however, a gray area between endoscopy and surgery remained. When dealing with benign-appearing lesions, it was unofficially assumed that lesions >4 cm or expanding in more than two consecutive folds were to be treated surgically. BIG size, BIG treatment! Such a paradigm was somewhat facilitated by the implementation of laparoscopic colorectal surgery, which was believed to minimize surgery-related morbidity, especially in the right colon.

In the last 20 years, the existence of such a gray area has been dramatically challenged by the development of new techniques for advanced endoscopic resection, namely EMR and endoscopic submucosal dissection (ESD), which facilitate a noninvasive oncological cure for patients with benign and superficially invasive colorectal tumors (T1), irrespective of size. In addition, morphological and vascular/pit pattern classifications have been standardized to predict those lesions that are likely to be amenable to endoscopic treatment due to the lack of deep cancer invasion. Such a paradigm-shift – from surgery to endoscopy – in the treatment of benign-appearing polyps was timely as mirrored by a dramatic increase in the identification of large and complex polyps due to the implementation of population-based screening programs, on one hand, and better education of endoscopists in detecting flat lesions, on the other

hand. According to the European Society of Gastrointestinal Endoscopy (ESGE) [1], EMR and ESD represent the first-line treatments for any benign-appearing lesion, irrespective of size. On the other hand, the role for surgery, if any, has been downgraded to rare failures of endoscopic resection due to anatomical barriers, such as invaded diverticula, appendix, or invaded ileocecal valve, or non-lifting due to submucosal fibrosis, such as because of inflammatory disease or prior resections.

Several recent publications [2,3], however, including the one published in this issue of Endoscopy International Open [4], show that a relevant number of benign colorectal lesions are nevertheless referred to surgeons for colectomy from the beginning, without any attempt at or referral for endoscopic resection. Such inappropriate behavior is worsened by the added morbidity (>20% [3]) and the oncological uselessness of surgical organ resection with lymph node removal for a benign lesion without any metastatic risk.

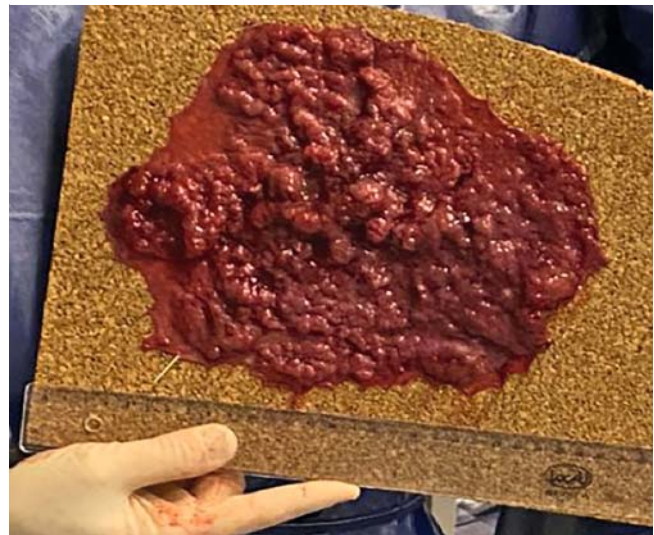
The reasons for these inappropriate surgical referrals are probably multidimensional but several studies unexpectedly show that the most critical factor of variability in the surgery referral rates of lesions measuring ≥ 20 mm is the endoscopist. Across different endoscopists, that rate ranged between 0% and 46.6% without any other plausible explanation. As with the rate of detection of adenomas, we are not all equal in our role as referrers, showing the operator-dependence of advanced endoscopic resection. What is a difficult polyp for one endoscopist may be relatively easy for a more expert one, and

vice versa. What are the hidden reasons for these differences in referral?

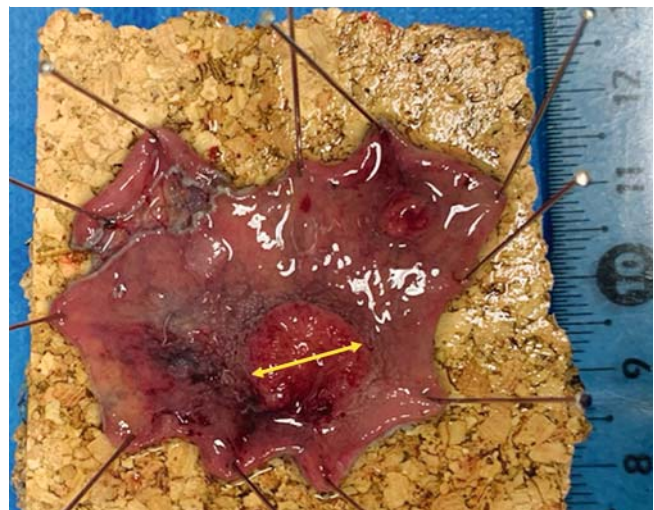There is no doubt that the availability and accessibility between interventional endoscopy and digestive surgery departments is radically different in several countries. Digestive surgery is virtually ubiquitous as representing one of the minimum units required in any local hospital to manage everyday emergencies. In these surgical units, colorectal surgery has become one of the basic techniques because of the high volume of oncological resections. Thus, a very large proportion of practitioners has been adequately trained to master such intervention, although it can be argued that quality of oncological colectomies remains heterogeneous across centers. In contrast, advanced endoscopic resection techniques for complex polyps are often performed only at a few scattered expert centers, forcing patients to be referred out of the institution that made the initial diagnosis. Such poor availability is due to two main factors. First, there is a lack of a well-structured training program for advanced resection, including EMR for complex lesions, so that most endoscopists in community practice have not been appropriately trained. Second, outside expert centers, the volume of complex polyps is too low to acquire or maintain competence, forcing centralization in a few hospitals.

Such divergence in accessibility between advanced endoscopy and surgery appears to be a key responsibility in the decision-making process. For practical reasons, it is likely that some practitioners will refer their patients for a more locally accessible technique, as they used to do before the development of interventional endoscopy, instead of referring them to a faraway expert center. There is also likely to be a local incentive for facilities ("nepotism") to employ local surgeons rather than referring patients to other expert referral facilities, despite patient interest. Some doctors will argue that sending a patient for a new endoscopic evaluation may waste the individual's time, but in reality, the lack of surgical urgency and the current surgical delays are such that an endoscopic reevaluation for possible endoscopic resection can probably be scheduled before the operative date without negative effect. Surprisingly, such an inappropriate referral by endoscopists is not offset by any reluctance of surgeons about overtreating patients with benign lesions. This may be explained by two main factors. First, it is usually the responsibility of the endoscopist to educate the surgeon on advances in endoscopic techniques. Thus, the lack of motivation by the endoscopist is likely to result in a lack of education for the surgeon. Second, surgery departments are not penalized financially or in other ways by operating on a benign polyp. Thus, what is a big difference for the endoscopic discipline may be irrelevant, at first glance, for the surgery counterpart.

Size remains the major key factor for surgical referral for many endoscopists who are apparently reluctant to replace it with optical diagnosis. Unfortunately, this impasse between size and endoscopic resectability is totally misleading as very large lesions (24 cm in the example in ► Fig. 1) may be completely benign as opposed to small, deeply invasive lesions measuring 10 mm (► Fig. 2). The lack of widespread implementation of optical diagnosis is disappointing, especially when considering the



► Fig. 1 Adenoma with low-grade dysplasia measuring 24 × 21 cm resected by ESD.



► Fig. 2 Adenocarcinoma with submucosal invasion over 2500 microns measuring 11 × 10 mm.

large investment in electronic chromoendoscopy technology, on one hand, and on the other, the development of accurate classifications. It could be argued that no classification is 100% accurate, and its false-negative/-positive results could lead to under-treatment/overtreatment. However, while it may be difficult to identify a deeply invasive malignant area within a lesion (i. e., NICE 3 sensitivity of only 63% [5]), it is extremely rare to misdiagnose a deeply invasive lesion as a noninvasive benign lesion (NICE 3 specificity >96% [6]) even by non-expert gastroenterologists [7]. What are the main barriers preventing the replacement of size with optical diagnosis? First, there was a lack of structured training for optical diagnosis in the Western setting. Only recently, ESGE developed a curriculum for optical diagnosis that includes the endoscopic prediction of deeply invasive cancer. Second, the main purpose of optical diagnosis for complex polyps is in orienting advanced techniques in resec-

tion. When endoscopists have not been trained in advanced resection, optical diagnosis appears somewhat useless.

How to address these hidden reasons? Fortunately, most European countries are implementing rigid screening programs in which measurement of quality is automated by electronic databases. The rate of appropriate referral of benign lesions to an endoscopist rather than to a surgeon should become a recognized and enforceable quality criterion for the individual endoscopist. This is critical to speed up the change in mentality and avoid ego problems interfering with the choice of resection technique at the expense of the risk-benefit balance.

Competing interests

The authors declare that they have no conflict of interest.

References

- [1] Ferlitsch M, Moss A, Hassan C et al. Colorectal polypectomy and endoscopic mucosal resection (EMR): European Society of Gastrointestinal Endoscopy (ESGE) Clinical Guideline. *Endoscopy* 2017; 49: 270–297
- [2] de Neree Tot Babberich MPM, Bronzwaer MES, Andriessen JO et al. Outcomes of surgical resections for benign colon polyps: a systematic review. *Endoscopy* 2019; 51: 961–972
- [3] Le Roy F, Manfredi S, Hamonic S et al. Frequency of and risk factors for the surgical resection of nonmalignant colorectal polyps: a population-based study. *Endoscopy* 2015; doi:10.1055/s-0034-1392976
- [4] Saade R, Tsang T, Kmeid M et al. Overutilization of surgical resection for benign colorectal polyps: analysis from a tertiary care center. *Endosc Int Open* 2021; 09: E706–E712
- [5] Backes Y, Schwartz MP, Ter Borg F et al. Multicentre prospective evaluation of real-time optical diagnosis of T1 colorectal cancer in large non-pedunculated colorectal polyps using narrow band imaging (the OPTICAL study). *Gut* 2019; 68: 271–279
- [6] Puig I, López-Cerón M, Arnau A et al. Accuracy of the narrow-band imaging international colorectal endoscopic classification system in identification of deep invasion in colorectal polyps. *Gastroenterology* 2019; 156: 75–87
- [7] Fabritius M, Jacques J, Gonzalez J-M et al. A simplified table using validated diagnostic criteria is effective to improve characterization of colorectal polyps: the CONECCT teaching program. *Endosc Int Open* 2019; 07: E1197–E1206