

Evaluation of the Effect of Captopril and Losartan on Tacrolimus-induced Nephrotoxicity in Rats

Authors

Seyedeh Mahsa Poormoosavi¹, Mohammad Amin Behmanesh², Hamed Abeyat³, Ehsan Sangtarash³

Affiliations

- 1 Department of Histology, School of Medicine, Research and Clinical Center for Infertility, Dezful University of Medical Sciences, Dezful, Iran
- 2 Department of Histology, School of Medicine, Dezful University of Medical Sciences, Dezful, Iran
- 3 School of Medicine, Dezful University of Medical Sciences, Dezful, Iran

Key words

tacrolimus, losartan, captopril, nephrotoxicity, rat

received 12.05.2020

accepted 14.12.2020

published online 12.03.2021

Bibliography

Drug Res 2021; 71: 243–249

DOI 10.1055/a-1369-8651

ISSN 2194-9379

© 2021. Thieme. All rights reserved.

Georg Thieme Verlag KG, Rüdigerstraße 14,
70469 Stuttgart, Germany

Correspondence

Dr. Mohammad Amin Behmanesh
Department of Histology, School of Medicine,
Dezful University of Medical Sciences
6136683447 Dezful
Iran (the Islamic Republic of)
Tel.: 09166421724, Fax: 06142429531
behmanesh.ma@yahoo.com

ABSTRACT

Background Tacrolimus is an immunosuppressive drug. Activation of the renin-angiotensin system (RAS) and associated inflammations may exacerbate the toxic effects of tacrolimus. Given the significant role of the kidney in RAS this study aimed to evaluate the effect of captopril as an angiotensin-converting enzyme (ACE) blocker and losartan as an angiotensin II receptor blocker on tacrolimus-induced nephrotoxicity.

Materials and Methods In total, 36 adult male rats weighing 200–250 gr were completely randomized and divided into six groups (control, tacrolimus, tacrolimus and losartan, tacrolimus and captopril, losartan, and captopril) for 30 days. Afterwards, blood urea nitrogen (BUN), creatinine (Cr) and ACE2 enzyme were measured. Also, both kidneys were collected for histological examinations.

Results The level of BUN and Cr significantly increased in tacrolimus group. The level of BUN and Cr were lower in the groups treated with a combination of tacrolimus and losartan or captopril. While ACE2 level increased in the groups receiving a combination of tacrolimus and losartan or captopril, the level of increase was insignificant, compared to the group treated with tacrolimus alone. The glomerulus diameter and the thickness of the renal proximal tubular epithelium significantly decreased in the group treated with tacrolimus alone. The mentioned variables increased in the group treated with a combination of tacrolimus and losartan or captopril, compared to the tacrolimus group.

Conclusion According to this study, tacrolimus increased the BUN and Cr levels while decreasing the ACE2 levels. However, tacrolimus in combination with losartan or captopril seemed to decrease the nephrotoxicity of the drug.

Introduction

Widely used to prevent the rejection of transplanted tissue in the treatment of autoimmune diseases, tacrolimus is an immunosuppressive drug of the family of calcineurin inhibitors [1]. According to the research, tacrolimus has other impacts in addition to immunosuppression including nephrotoxicity, neurotoxicity, gastrointestinal disorders, diabetes mellitus after transplantation and hypertension [1, 2]. Tacrolimus is an effective treatment for preventing solid-organ transplant rejection, even after the failure of standard transplant rejection treatment. Common side effects of tacrolimus include nephrotoxicity and neurotoxicity (tremor, head-

ache, movement disorders, and seizures). The inhibition of calcineurin phosphatase appears to be the cause of tacrolimus-induced neurotoxicity. Meanwhile, renal complications are attributed to decrease glomerular blood flow and increased renal vascular resistance, which is associated with the increased endothelin-1-induced release of thromboxane A2 or stimulation of renin secretion [3]. Treatment by tacrolimus leads to nephrotoxicity that causes serious problems [4, 5].

The renin-angiotensin system (RAS) directly regulates blood pressure through vascular contraction and indirectly leads to fluid and electrolyte homeostasis through central and peripheral mech-

animals of hypertension [6, 7]. This system is well known owing to its role in blood pressure regulation and fluid homeostasis. Nonetheless, many tissues need the system to function normally, and the system meets the needs of the tissues locally [8]. Recent studies show that the product of ACE gene expression is found in cardiac endothelial cells, epithelial cells of the kidney tubules, and Leydig cells [8]. Tacrolimus-induced nephrotoxicity occurs in 17–44% of renal transplant recipients and 18–42% of liver transplant recipients [9]. The mechanism of acute tacrolimus-induced nephrotoxicity remains unknown. Previous studies have demonstrated that tacrolimus may induce nephrotoxicity due to its ability to produce reactive oxygen species (ROS) through the activation of NADPH oxidase and disruption of antioxidant defenses [10].

Studies have shown the importance of RAS inhibitors in renal failure, and it has been shown that RAS inhibition is an effective method for intervening in the pathogenesis of renal disorders that reduces the clearance of creatinine (Cr) and, conversely, increases the activity of renin plasma [11, 12]. Studies show that tacrolimus disrupts RAS and is associated with increased oxidative stress. In addition, tacrolimus treatment significantly increases the blood urea nitrogen (BUN) and Cr levels. Meanwhile, evidence shows that the activation of RAS and inflammations may exacerbate the toxic effects of tacrolimus. Captopril and other drugs in this category inhibit the peptidyl dipeptidase converting enzyme, which hydrolyzes the angiotensin I converting enzyme (ACE), changing it into angiotensin II. Moreover, the mentioned drug has an inhibitory effect on the RAS. In general, ACE inhibitors play an important role in the treatment of patients with chronic renal diseases owing to their ability to eliminate proteinuria and stabilize the renal function even without reducing the blood pressure. These benefits may emerge due to the improved intramuscular hemodynamics along with decreased resistance of efferent arteriole, which reduces the glomerular capillary pressure. Angiotensin II receptor blockers (ARB) known as losartan and AT1 receptor antagonist drugs are a group of drugs that regulate the Renin-angiotensin-aldosterone system (RAAS). Losartan was the first generic ARB introduced to the market [13].

Given the increasing number of diseases affecting the immune system and the growing number of organ transplants, it is necessary to examine the drugs used in this area and the effect of their interaction on various tissues, including the urinary tract. With regard to the important role of the kidney in the RAS and considering the effects of the system's productions on the renal tissue, the present study aimed to evaluate the toxic effects of tacrolimus on renal tissues and the impact of captopril drugs as ACE inhibitors and losartan as an ARB in this regard.

Materials and Methods

Animal housing

In this research, 36 adult male rats weighing 200–250 gr were divided into six groups of six and were kept in standard conditions (a temperature of 25 °C degrees, 12–12 light-dark cycle) for 30 days [14]. The study was approved by the Ethics Committee of Dezful University (IR.DUMS.RFC.1396.24), and all the experiments were performed in accordance with the guidelines for the safe handling of animals.

Animal grouping

The first group (control) only received normal saline while the samples in the second group were administered intraperitoneally with a daily dose of 1 mg/kg of tacrolimus (Tac) (14). In addition, the third group received a concomitant daily dose of 1 mg/kg of tacrolimus and 100 mg/kg of captopril intraperitoneally (Tac + cap) [14, 15]. Moreover, the fourth group was administered intraperitoneally with a daily dose of 1 mg/kg of tacrolimus [3, 14] and 80 mg/kg of losartan as gavage (Tac + los) [16], whereas the fifth group received a daily dose of 80 mg/kg losartan as gavage (Los) [16]. Ultimately, the sixth group received a daily dose of 100 mg/kg of captopril as gavage (Cap) [15]. All treatments were given daily, for 30 days. The purpose of having groups 5 and 6 included in this study was to evaluate the possible effects of each of these drugs, when administered alone.

Samples collection

Eventually, the rats were anesthetized with chloroform and euthanized by collecting blood from their hearts. Kidney function was investigated by serum urea (BUN) and creatinine (Cr) levels and Histopathological change. Rat's serum was collected to measure BUN and Cr using the colorimetric method of Fawcett and Soctt, [17] and Peters [18] respectively and both kidneys were weighed after extraction. Afterwards, the tissues were fixed in 10% formalin buffer, followed by normal preparation of 5–6 μ series tissue sections. Hematoxylin-eosin staining was conducted, and four slides of each kidney in each group were evaluated morphometrically and histopathologically. In this regard, the thickness of the proximal tubular epithelial cells and glomerular diameter were assessed by Dino-Lite digital microscope and the related software. Moreover, the ACE2 enzyme status was evaluated in different groups to determine the status of RAS using special rat kits (Catalog#MBS014209, MyBio-source Company) and the ELISA method.

Statistical analysis

All the analyses were performed using SPSS version 16. Group's variance were analyzed by one way Analysis of Variation (ANOVA) and Fisher's least significant difference test (LSD) for evaluation of significant differences between groups. A $P \leq 0.05$ was considered statistically significant.

Results

In this research, as shown in ► **Table 1**. The BUN level increased significantly in the group of animals treated solely with tacrolimus, compared to the control group ($P \leq 0.05$). However, the BUN level was significantly lower in other groups administered concomitantly with tacrolimus and captopril and losartan, compared to the group treated with tacrolimus alone ($P \leq 0.05$). Nonetheless, there was still a significant increase in the mentioned groups, compared to the control group ($P \leq 0.05$). On the other hand, no significant difference was observed between the control group and the groups treated with captopril and losartan alone in terms of the BUN level ($P > 0.05$). According to statistical results, as shown in ► **Table 1**. the Cr level was significantly higher in the group treated with tacrolimus alone, compared to the control group ($P \leq 0.05$). Neverthe-

► **Table 1** Serum urea and creatinine levels of control and treated rats.

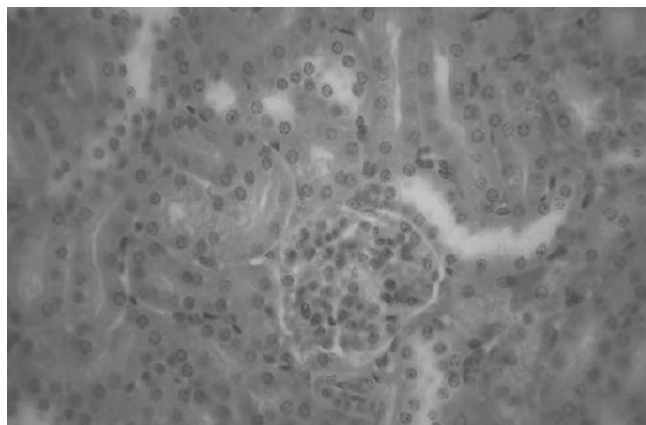
Parameters	Urea (mg dL ⁻¹)	Creatinine (mg dL ⁻¹)	angiotensin-converting enzyme (U/L)
Group			
Control	25.7 ± 4.61 ^c	3.23 ± 5.13 ^c	6.64 ± 3.53 ^a
Tac	98.24 ± 3.72 ^a	12.75 ± 4.21 ^a	2.91 ± 4.43 ^b
Tac + Cap	49.31 ± 5.1 ^b	6.62 ± 3.64 ^b	3.67 ± 3.71 ^b
Tac + Los	57.55 ± 2.93 ^b	5.97 ± 6.23 ^b	3.18 ± 4.2 ^b
Los	24.31 ± 4.9 ^c	3.59 ± 3.16 ^c	5.98 ± 4.3 ^a
Cap	26.57 ± 3.12 ^c	3.98 ± 4.23 ^c	5.23 ± 4.1 ^a

Values are presented as mean ± S.E. (n = 6 animals/group). Letters a, b and c in each column indicate significant differences at p ≤ 0.05.

► **Table 2** Weight and histopathological changes of kidneys in different groups.

Parameters	Kidney weight (g)	glomerulus diameter (μ)	thickness of proximal tubular (μ)
Group			
Control	4.65 ± 3.74 ^a	295.7 ± 4.2 ^a	48.33 ± 4.7 ^a
Tac	3.93 ± 4.33 ^a	126.7 ± 3.56 ^c	13.42 ± 4.1 ^c
Tac + Cap	4.3 ± 3.15 ^a	166.3 ± 3.9 ^b	32.17 ± 3.3 ^b
Tac + Los	3.88 ± 5.24 ^a	159.4 ± 4.5 ^b	30.36 ± 4.1 ^b
Los	4.23 ± 3.17 ^a	315.6 ± 5.7 ^a	47.74 ± 6.1 ^a
Cap	4.71 ± 4.12 ^a	287.3 ± 4.2 ^a	49.38 ± 5.4 ^a

Values are presented as mean ± S.E. (n = 6 animals/group). Letters a, b and c in each column indicate significant differences at p ≤ 0.05.



► **Fig. 1** Light photomicrographs of the kidney in control group. (H&E, X400). glomerulus has normal diameter. thickness of the proximal tubular epithelium is normal.

less, it was significantly lower in the group of rats treated with a combination of captopril and tacrolimus, compared to the group administered with tacrolimus alone ($P \leq 0.05$). Still, the Cr level was higher in the mentioned group, compared to the control group ($P \leq 0.05$). On the other hand, no significant difference was observed between the control group and the groups treated with losartan alone and captopril alone regarding Cr levels ($P > 0.05$).

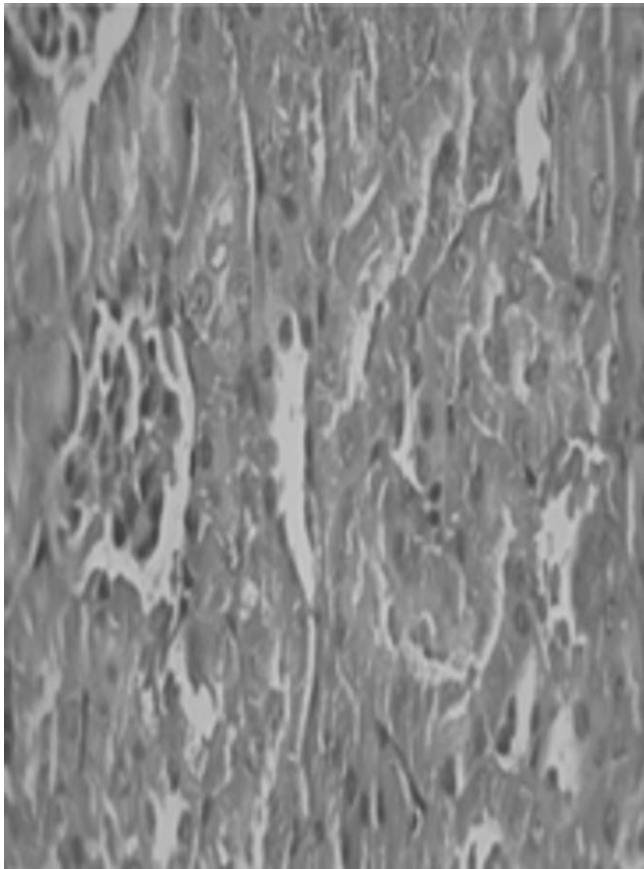
In this study, as shown in ► **Table 1**, the amount of ACE2 was significantly lower in the group treated with tacrolimus alone, compared to the control group ($P \leq 0.05$). However, the ACE2 level increased in the groups administered concomitantly with tacrolimus and captopril and losartan, compared to the group administered with tacrolimus alone. Nevertheless, this increase was insignificant ($P > 0.05$). According to the results, there was no significant difference between the control group and the groups treated with losartan alone and captopril alone in terms of ACE2 amount ($P > 0.05$).

The results as shown in ► **Table 2**, were indicative of no significant difference among the groups regarding kidney weight ($P > 0.05$). However, the glomerulus's diameter was significantly reduced in the group treated with tacrolimus, compared to the control group ($P \leq 0.05$). While the mentioned variable was significantly higher in the groups treated with a combination of captopril and tacrolimus and a combination of losartan and tacrolimus, compared to the group administered with tacrolimus alone ($P \leq 0.05$), it was still significantly lower, compared to the control group ($P \leq 0.05$). Furthermore, no significant difference was observed between the control group and the groups treated with losartan alone and tacrolimus alone in terms of glomerulus diameter ($P > 0.05$). The thickness of the renal proximal tubular epithelium was significantly lower in the group treated with tacrolimus alone, compared to the control group ($P \leq 0.05$). However, the mentioned variable was significantly higher in the group treated with a combination of captopril and tacrolimus and the group administered with a combination of losartan and tacrolimus, compared to the group administered with tacrolimus alone ($P \leq 0.05$). Nonetheless, this amount was still significantly lower, compared to the control group. Meanwhile, no significant difference was observed between the control group and the groups treated with losartan alone and captopril alone in terms of the thickness of the renal proximal tubular epithelium ($P > 0.05$). (► **Table 2**) (► **Fig. 1–4**).

According to ► **Fig. 5** and **6** necrosis in the tubules and kidney glomerular hemorrhage was observed in the kidney cross section of all rats administered with a combination of losartan and tacrolimus or captopril and tacrolimus respectively. However, the level of necrosis and hemorrhage was lower, compared to the group treated with tacrolimus alone ► **Fig. 7**.

Discussion

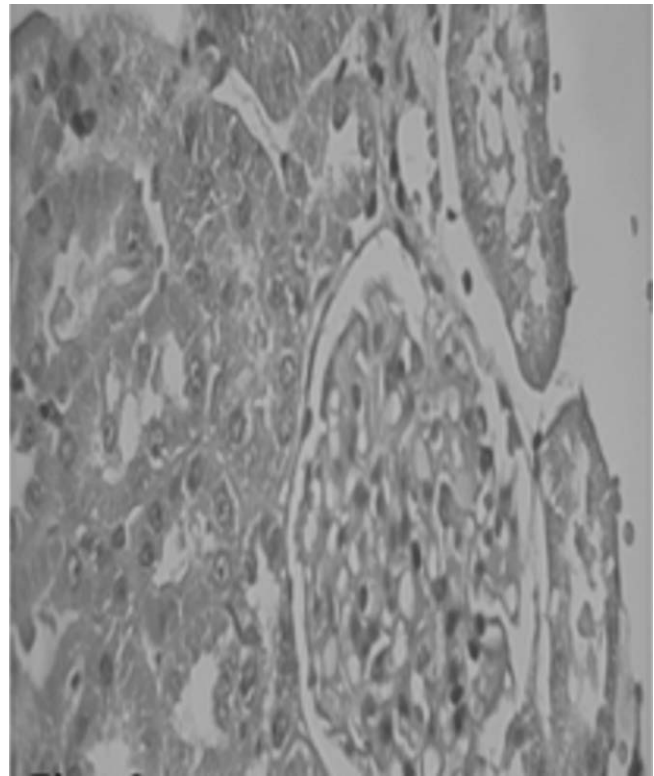
Tacrolimus is a macrolide drug with immunosuppressive activity used as an immunosuppressant to reduce the level of organ transplant rejection. One of the complications of the long-term use of this drug is nephrotoxicity. However, the acute toxicity mechanism of tacrolimus remains unknown. Previous studies have suggested that tacrolimus's ability to produce ROSs through the activation of NADPH oxidase and disruption of antioxidant defenses might be responsible for nephrotoxicity caused by the drug [19]. Several studies have also explained the role of RAS in tacrolimus-induced nephrotoxicity [11, 20]. Given the crucial role of kidneys in the RAS and with regard to the effect of the productions of the system on the renal tissue, and considering other toxic impacts of tacrolimus on kidney tissue structure, we evaluated the effects of captopril as an ACE blocker and losartan as an ARB on the nephrotoxicity of tac-



► **Fig. 2** Light photomicrographs of the kidney in tacrolimus group. (H&E, X400). The glomerulus's diameter was reduced. The thickness of the renal proximal tubular epithelium was lower than control group.

rolimus. According to the results, the BUN level significantly increased in the group treated with tacrolimus, compared to the control group. In this regard, our findings are in line with the results obtained by Nakatani et al. (2003). In the mentioned research, the daily consumption of tacrolimus for two weeks significantly increased BUN and Cr in the samples [21]. However, the BUN level significantly decreased in the groups administered with a combination of tacrolimus and captopril or losartan, compared to the group treated with tacrolimus alone.

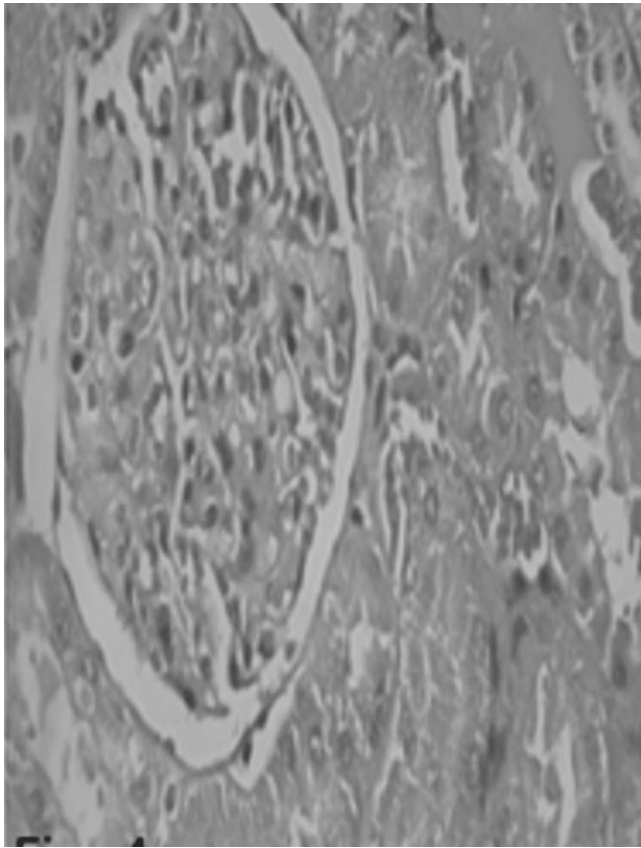
According to the results of the current research, the Cr level significantly increased in rats treated with tacrolimus alone, compared to the samples in the control group, which is consistent with the results obtained by Nakatani et al. While the level of Cr was lower in the groups treated with a combination of tacrolimus and captopril and losartan, compared to the group administered with tacrolimus alone, it was still higher than the control group. Nakatani et al. (2003) concluded that the activity of RAS increased BUN and Cr in the samples [21], which is similar to the results obtained in the present study. Moreover, our findings demonstrated that the administration of tacrolimus increased BUN and Cr levels, and the use of captopril and losartan reduced tacrolimus-induced nephrotoxicity.



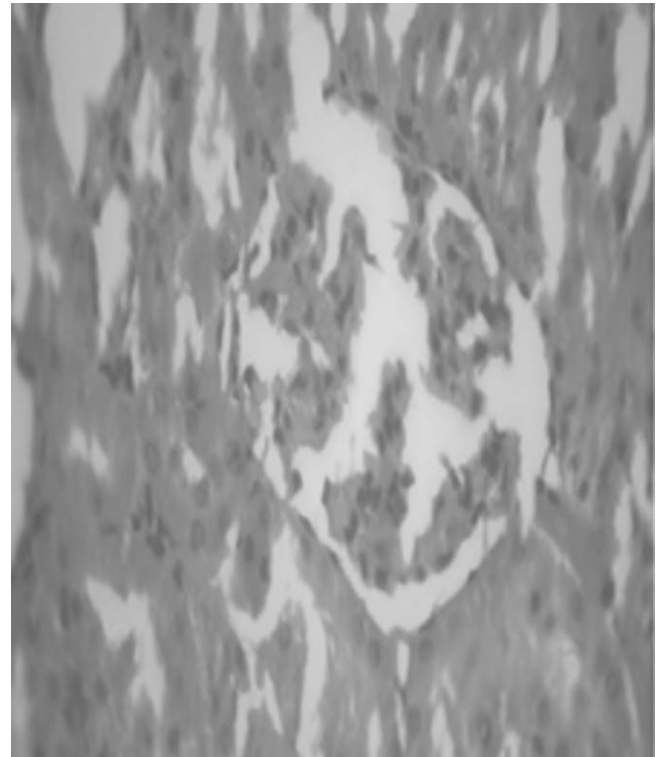
► **Fig. 3** Light photomicrographs of the kidney in tacrolimus and losartan group. (H&E, X400). The glomerulus's diameter and renal proximal tubular epithelium was higher than tacrolimus group.

In a research by Deniz et al., RAS inhibition regulated the expression of fibrogenic cytokines in rats, thereby showing a decrease in tacrolimus-induced nephrotoxicity [22], which is congruent with our findings. In the current research, RAS inhibition through the prescription of captopril and losartan reduced tacrolimus-induced nephrotoxicity even though the changes were insignificant. In a research in 2014, Hořková et al. evaluated the effect of hypertension and tacrolimus-induced nephrotoxicity in rats mediated with RAS inhibition. According to the results, the long-term use of tacrolimus led to hypertension and renal damage in rats and chronic renal failure, especially due to increased renal RAS activity. Dual inhibition of RAS by ACEI and ARB drugs during four months of treatment with tacrolimus had antihypertensive and anti-nephrotoxic properties not only in rats with hypertension but also in samples with normal blood pressure [23]. In this respect, our findings are in accordance with the mentioned results, supporting the hypothesis that RAS inhibitors had proper protective properties against nephrotoxicity during treatment with a calcineurin inhibitor [24]. In the current study, the level of ACE2 was significantly lower in the group treated with tacrolimus, while an insignificant increase was observed in the groups administered with a combination of tacrolimus and captopril and losartan, compared to the group treated with tacrolimus alone.

In a research, Kidokoro et al. (2012) marked that the tacrolimus-induced glomerular injuries were due to oxidative stress caused by



► **Fig. 4** Light photomicrographs of the kidney in tacrolimus and captopril group. (H&E, X400). The glomerulus's diameter and renal proximal tubular epithelium was higher than tacrolimus group.



► **Fig. 5** Light photomicrographs of the kidney in tacrolimus and losartan group. (H&E, X400). Tubular necrosis and glomerular hemorrhage was lower than tacrolimus group.

the activation of NADPH oxidase, and RAS inhibitors exerted a protective impact through their antioxidant activity [4]. According to the results of the mentioned study and the present research, the glomerulus diameter decreased in rats treated with tacrolimus. Therefore, the tacrolimus-induced glomerulus injuries seemed to be due to oxidative stress caused by the activation of NADPH oxidase. Given the fact that the glomerulus diameter was higher in the groups treated with a combination of tacrolimus and captopril and losartan, compared to the group administered with tacrolimus alone, our findings are consistent with the results obtained by Kidokoro et al., and it could be concluded that the antioxidant activities of RAS inhibitors could be a cause of tacrolimus-induced nephrotoxicity [5].

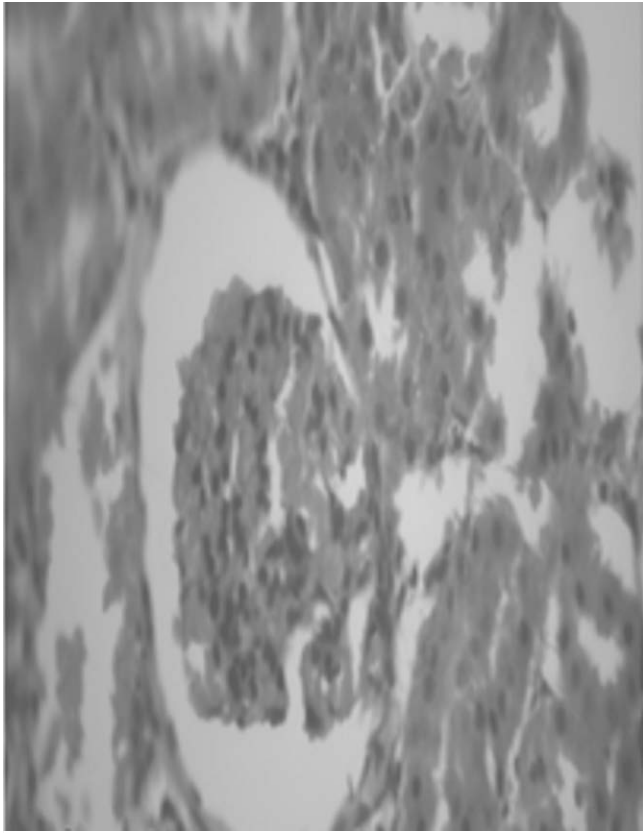
In 1994, Takashi et al. performed a study to evaluate the effect of tacrolimus on glomeruli, reporting that tacrolimus-induced nephrotoxicity occurred as a result of impairment of glomerular function related to the contraction of renal arteries [25]. In this respect, our findings are in line with the results of the mentioned study. According to the results of the present research, the thickness of the renal proximal tubular epithelial cells was significantly lower in the group treated with tacrolimus alone, compared to the control group. On the other hand, the mentioned variable was significantly higher in the groups treated with a combination of tacrolimus and captopril and losartan, compared to the group administered

with tacrolimus alone. Nonetheless, it was still significantly lower than the control group. In a research by Han SY et al. (2006), cyclosporine and tacrolimus caused renal damage by free radicals [26], which is consistent with our findings regarding tacrolimus-induced renal damage. In 2006, Liptak & Ivanyi pointed out that cyclosporine and tacrolimus-induced chronic nephrotoxicity was detected based on the necrosis of smooth muscles of afferent vessels and formation of proximal tube vacuoles [27]. In this regard, our findings are in line with the results of the aforementioned research.

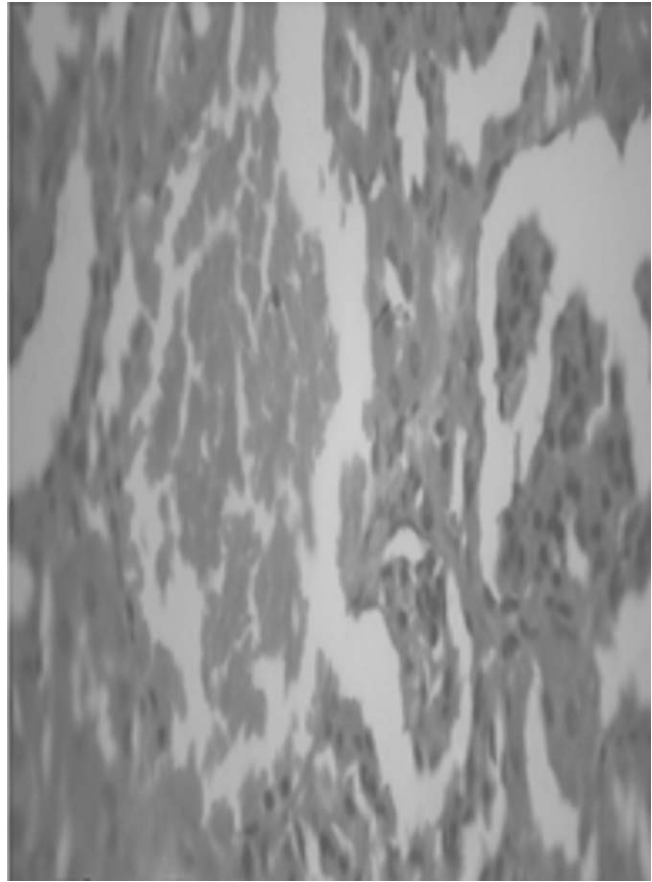
In another, Naesens et al. (2009) evaluated the effect of tacrolimus on glomerulus and renal tubules, and the results were indicative of a relationship between the consumption of calcineurin inhibitors and reversible and irreversible changes and damage to the renal parts, including glomeruli, arteries, and tubules [28]. In line with the results of the mentioned study, our histopathological results demonstrated that treatment with tacrolimus alone caused glomerular and renal proximal tubular destruction.

Conclusion

According to the results of the current research, tacrolimus consumption increased BUN and Cr levels while decreasing the ACE2 level in the samples, thereby causing renal damage and nephrotoxicity. However, concomitant use of tacrolimus and captopril and losartan repaired the tacrolimus-induced renal damage through



► **Fig. 6** Light photomicrographs of the kidney in tacrolimus and captopril group. (H&E, X400). Tubular necrosis and glomerular hemorrhage was lower than tacrolimus group.



► **Fig. 7** Light photomicrographs of the kidney in tacrolimus group. (H&E, X400). Tubular necrosis and glomerular hemorrhage was shown.

the reduction of BUN and Cr levels and increase of ACE2, which was clearly observed in kidney tissue sections.

Author's Contribution

S.M.P, M.A.B., H.A.; Contributed to conception and design. S.M.P.; Contributed to all experimental work, data and statistical analysis, and interpretation of data. M.A.B., H.A., E.S.; were responsible for overall supervision. S.M.P.; Drafted the manuscript, which was revised by H.A. and M.A.B. All authors read and approved the final manuscript.

Funding

The authors would like to acknowledge Dezfoul University for financially supported.

Conflict of Interest

The authors declare that they have no conflict of interest.

References

- [1] Scott LJ, McKeage K, Keam SJ et al. Tacrolimus. *Drugs* 2003; 63: 1247–1297
- [2] Taylor AL, Watson CJ, Bradley JA. Immunosuppressive agents in solid organ transplantation: Mechanisms of action and therapeutic efficacy. *Critical Reviews in Oncology/Hematology* 2005; 56: 23–46
- [3] Tao X, Wang W, Jing F et al. Long-term efficacy and side effects of low-dose tacrolimus for the treatment of myasthenia gravis. *Neurological Sciences* 2017; 38: 325–330
- [4] Kidokoro K, Satoh M, Nagasu H et al. Tacrolimus induces glomerular injury via endothelial dysfunction caused by reactive oxygen species and inflammatory change. *Kidney and Blood Pressure Research* 2012; 35: 549–557
- [5] Nankivell BJ, Chapman JR, Bonovas G et al. Oral cyclosporine but not tacrolimus reduces renal transplant blood flow. *Transplantation* 2004; 77: 1457–1459
- [6] Reid IA, Morris BJ, Ganong WF. The renin-angiotensin system. *Annual Review of Physiology* 1978; 40: 377–410
- [7] Stroth U, Unger T. The renin-angiotensin system and its receptors. *Journal of Cardiovascular Pharmacology* 1999; 33: S21–S28
- [8] Leung P, Sernia C. The renin-angiotensin system and male reproduction: new functions for old hormones. *Journal of Molecular Endocrinology* 2003; 30: 263–270
- [9] Sher Y, Maldonado JR. *Psychosocial Care of End-Stage Organ Disease and Transplant Patients*. Springer; 2019

- [10] Khanna AK, Pieper GM. NADPH oxidase subunits (NOX-1, p22phox, Rac-1) and tacrolimus-induced nephrotoxicity in a rat renal transplant model. *Nephrology Dialysis Transplantation* 2007; 22: 376–385
- [11] Ruggenti P, Perna A, Gherardi G et al. Renoprotective properties of ACE-inhibition in non-diabetic nephropathies with non-nephrotic proteinuria. *The Lancet* 1999; 354: 359–364
- [12] Collaboration BPLTT. Effects of different blood-pressure-lowering regimens on major cardiovascular events: Results of prospectively-designed overviews of randomised trials. *The Lancet* 2003; 362: 1527–1535
- [13] Martin ST, Roberts KL, Malek SK et al. Induction treatment with rabbit antithymocyte globulin versus basiliximab in renal transplant recipients with planned early steroid withdrawal. *Pharmacotherapy: The Journal of Human Pharmacology and Drug Therapy* 2011; 31: 566–573
- [14] Meier-Kriesche HU, Li S, Gruessner RW et al. Immunosuppression: evolution in practice and trends, 1994–2004. *American Journal of Transplantation* 2006; 6: 1111–1131
- [15] Agirbasli M, Papila-Topal N, Ogutmen B et al. The blockade of the renin-angiotensin system reverses tacrolimus related cardiovascular toxicity at the histopathological level. *Journal of the Renin-Angiotensin-Aldosterone System* 2007; 8: 54–58
- [16] Haynes R, Baigent C, Harden P et al. Campath, calcineurin inhibitor reduction and chronic allograft nephropathy (3C) study: background, rationale, and study protocol. *Transplantation Research* 2013; 2: 7
- [17] Fawcett J, Scott J. A rapid and precise method for the determination of urea. *Journal of Clinical Pathology* 1960; 13: 156–159
- [18] Peters JH. The determination of creatinine and creatine in blood and urine with the photoelectric colorimeter. *J Biol Chem* 1942; 146: 11
- [19] Randhawa PS, Saad RS, Jordan M et al. Clinical significance of renal biopsies showing concurrent acute rejection and tacrolimus-associated tubular vacuolization. *Transplantation* 1999; 67: 85–89
- [20] Dunn FG, Oigman W, Ventura HO et al. Enalapril improves systemic and renal hemodynamics and allows regression of left ventricular mass in essential hypertension. *The American Journal of Cardiology* 1984; 53: 105–108
- [21] Nakatani T, Uchida J, Iwai T et al. Renin mRNA expression and renal dysfunction in tacrolimus-induced acute nephrotoxicity. *International Journal of Molecular Medicine* 2003; 11: 75–78
- [22] Deniz H, Öğütmen B, Cakalağaoğlu F et al. editors. Inhibition of the renin angiotensin system decreases fibrogenic cytokine expression in tacrolimus nephrotoxicity in rats. *Transplantation Proceedings*. 2006 Elsevier
- [23] Hošková L, Málek I, Kautzner J et al. Tacrolimus-induced hypertension and nephrotoxicity in Fawn-Hooded rats are attenuated by dual inhibition of renin-angiotensin system. *Hypertension Research* 2014; 37: 724–732
- [24] Jantz AS, Patel SJ, Suki WN, et al. Treatment of acute tacrolimus toxicity with phenytoin in solid organ transplant recipients. *Case Reports in Transplantation*. 2013;2013
- [25] Mitamura T, Yamada A, Ishida H et al. Tacrolimus (FK506)-induced nephrotoxicity in spontaneous hypertensive rats. *The Journal of Toxicological Sciences* 1994; 19: 219–226
- [26] Han S, Mun K, Choi H et al. editors. Effects of Cyclosporine and Tacrolimus on the oxidative stress in Cultured Mesangial Cells. *Transplantation Proceedings*. 2006; Elsevier
- [27] Liptak P, Ivanyi B. Primer: Histopathology of calcineurin-inhibitor toxicity in renal allografts. *Nature clinical practice Nephrology* 2006; 2: 398–404
- [28] Naesens M, Kuypers DR, Sarwal M. Calcineurin inhibitor nephrotoxicity. *Clinical Journal of the American Society of Nephrology* 2009; 4: 481–508