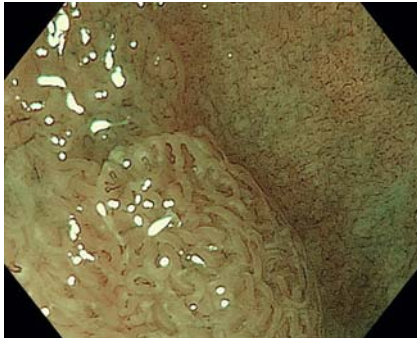
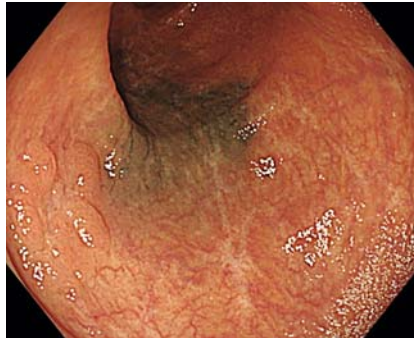

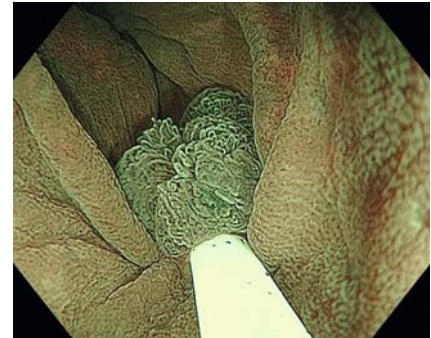
Underwater endoscopic mucosal resection for a sporadic adenoma located at severe longitudinal ulcer scars in ulcerative colitis



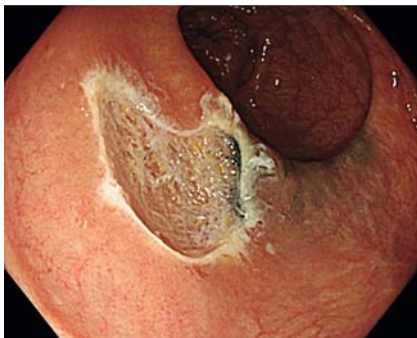► **Fig. 1** Magnifying colonoscopy with narrow band imaging (NBI) showed Japan NBI Expert Team classification type 2A with no flat dysplasia lesion in the periphery.



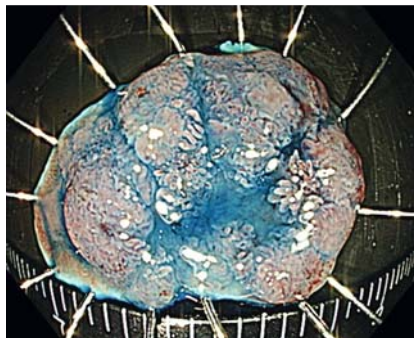
► **Fig. 2** Colonoscopy revealed a 15-mm, flat elevated lesion in the middle-transverse colon. There were obvious longitudinal ulcer scars from ulcerative colitis inflammation and an endoscopic tattooing scar adjacent to the lesion.



► **Fig. 3** The lesion was fully immersed in natural saline, captured with a 20-mm snare, and removed under narrow-band imaging observation.



► **Fig. 4** Underwater endoscopic mucosal resection was completed without any visible neoplastic tissue on the margin of the mucosal defect.



► **Fig. 5** Resected specimen after indigo carmine spraying with negative resection margins.

A 52-year-old woman diagnosed with ulcerative colitis (UC) and a history of repeated flare-ups and remissions was referred to our hospital. Colonoscopy revealed a 15-mm, flat elevated lesion in the transverse colon. Magnifying colonoscopy with narrow-band imaging (NBI) showed Japan NBI Expert Team classification type 2A and no flat dysplasia lesion in the periphery. Pathological findings of the biopsy specimen revealed a partial expression of p53. Based on these findings, we suspected sporadic adenoma (► **Fig. 1**) rather than ulcerative colitis-associated neoplasia. There were

obvious longitudinal ulcer scars as a result of UC inflammation and an endoscopic tattooing scar adjacent to the lesion (► **Fig. 2**).

We decided to carry out underwater endoscopic mucosal resection (UEMR) for this lesion. After full immersion of the target lesion in natural saline, we captured it under NBI observation using a 20-mm snare (Snare Master; Olympus, Tokyo, Japan) (► **Fig. 3**) and removed it. The procedure was completed without any visible neoplastic tissue on the margin of the mucosal defect (► **Fig. 4**). En bloc resection without complications

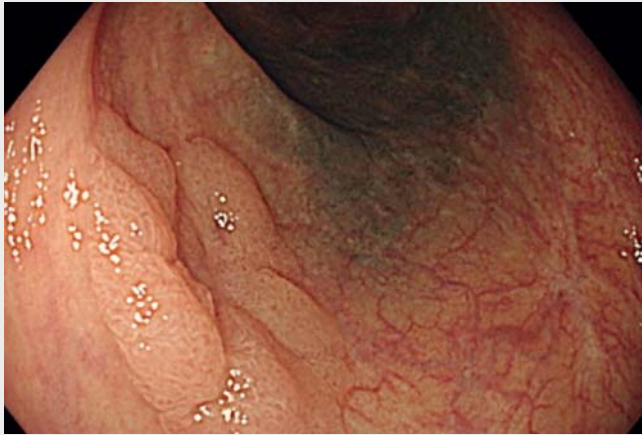was achieved (► **Fig. 5**, ► **Video 1**). Histopathological examination revealed a low-grade tubular adenoma without tumor involvement on the horizontal and vertical margins.

Conventional endoscopic mucosal resection (EMR) of polyps on severe scars due to UC is technically challenging [1] because submucosal fibrosis from background inflammation makes it difficult to lift the lesion during submucosal injection and to snare the entire tumor. UEMR has been reported to be an effective technique in cases of severe submucosal fibrosis [2–5], but it has not been performed in patients with UC after healing from inflammation. This report presents the first case of successful UEMR of a lesion associated with fibrosis secondary to UC remission and tattooing. UEMR may also be effective in resecting polyps on the fibrous mucosa within the area affected by UC.

Endoscopy_UCTN_Code_TTT_1AQ_2AD

Competing interests

The authors declare that they have no conflict of interest.



Video 1 Underwater endoscopic mucosal resection for a sporadic adenoma located at severe longitudinal ulcer scars in ulcerative colitis.

Bibliography

Endoscopy 2022; 54: E30–E31
DOI 10.1055/a-1368-3796
ISSN 0013-726X
published online 22.2.2021
© 2021. Thieme. All rights reserved.
Georg Thieme Verlag KG, Rüdigerstraße 14,
70469 Stuttgart, Germany

ENDOSCOPY E-VIDEOS

<https://eref.thieme.de/e-videos>



Endoscopy E-Videos is a free access online section, reporting on interesting cases and new techniques in gastroenterological endoscopy. All papers include a high quality video and all contributions are freely accessible online.

This section has its own submission website at
<https://mc.manuscriptcentral.com/e-videos>

The authors

**Kaoru Takabayashi¹, Motohiko Kato^{2,3},
Motoki Sasaki², Yasushi Iwao³, Haruhiko
Ogata¹, Takanori Kanai³, Naohisa Yahagi²**

- 1 Center for Diagnostic and Therapeutic Endoscopy, School of Medicine, Keio University, Tokyo, Japan
- 2 Research and Development for Minimally Invasive Treatment, Cancer Center, School of Medicine, Keio University, Tokyo, Japan
- 3 Division of Gastroenterology and Hepatology Department of Internal Medicine, School of Medicine, Keio University, Tokyo, Japan

Corresponding author

Kaoru Takabayashi, MD, PhD

Center for Diagnostic and Therapeutic Endoscopy, School of Medicine, Keio University, 35 Shinanomachi, Shinjuku-ku, Tokyo 160-8582, Japan
kaoru0902@yahoo.co.jp

References

- [1] Nishio M, Hirasawa K, Ozeki Y et al. An endoscopic treatment strategy for superficial tumors in patients with ulcerative colitis. *J Gastroenterol Hepatol* 2020. doi:10.1111/jgh.15207
- [2] Hosotani K, Imai K, Hotta K et al. Underwater endoscopic mucosal resection for complete R0 removal of a residual adenoma at a perforated scar in a patient with colostomy. *Endoscopy* 2017; 49: E121–E122
- [3] Takeuchi Y, Tonai Y, Ikeda K. Underwater endoscopic mucosal resection for a superficial polyp located at the anastomosis after surgical colectomy. *Dig Endosc* 2017; 29: 67–68
- [4] Rodrigues JP, Pinho R, Sousa M et al. Underwater endoscopic mucosal resection of a laterally spreading tumor overlying a previous endoscopic carbon tattoo. *Endoscopy* 2018; 50: E231–E232
- [5] Kim HG, Thosani N, Banerjee S et al. Underwater endoscopic mucosal resection for recurrences after previous piecemeal resection of colorectal polyps (with video). *Gastrointest Endosc* 2014; 80: 1094–1102