

Embryology, Malformations, and Rare Diseases of the Cochlea



Authors

Athanasia Warnecke^{1,2}, Anja Giesemann³

Affiliations

- 1 Department of Oto-Rhino-Laryngology, Head and Neck Surgery, Hannover Medical School, Hannover, Germany
- 2 Deutsche Forschungsgemeinschaft Exzellenzcluster "Hearing4all" – EXC 2177/1 – Project ID 390895286, Germany
- 3 Institute of Diagnostic and Interventional Neuroradiology, Hannover Medical School, Hannover, Germany

Key words

rare diseases, cochlea, embryology of the inner ear, cochlear malformations

Bibliography

Laryngo-Rhino-Otol 2021; 100: S1–S43

DOI 10.1055/s-0041-1726678

ISSN 0935-8943

© 2021. The Author(s).

This is an open access article published by Thieme under the terms of the Creative Commons Attribution-NonDerivative-NonCommercial-License, permitting copying and reproduction so long as the original work is given appropriate credit. Contents may not be used for commercial purposes, or adapted, remixed, transformed or built upon. (<https://creativecommons.org/licenses/by-nc-nd/4.0/>)

© Georg Thieme Verlag KG, Rüdigerstraße 14, 70469 Stuttgart, Germany

Correspondence

Prof. Dr. med. Athanasia Warnecke
Department of Oto-Rhino-Laryngology
Head and Neck Surgery
Medical University of Hannover
Carl-Neuberg-Str. 1
D-30625 Hannover
Tel.: +49 511 532 8809
Germany
warnecke.athanasia@mh-hannover.de

ABSTRACT

Despite the low overall prevalence of individual rare diseases, rare diseases involving the cochlea causing hearing loss occur quite often. The aim of this work was to provide a clear overview of rare cochlear diseases, taking into account the embryonic development of the cochlea and presenting a systematic overview of the different disorders. Although rapid biotechnological and bioinformatic advances may facilitate the diagnosis of a rare disease, a rare disease is often suspected only after an interdisciplinary work up of the patient. Despite the same genetic variance as underlying cause of hearing loss, the phenotype of a rare inner ear disease can vary greatly not only in non-syndromic but also in syndromic hearing disorders. Thus, it becomes clear that the phenotype of the individual rare disease cannot be determined exclusively by classical genetics even in monogenetic disorders.

Contents

Abstract	S1
Introduction	S2
1 Embryonic development and morphology of the cochlea	S2
1.1 Morphogenesis of the inner ear	S3
1.2 Molecular biology of the embryonic development	S4
1.3 Development of sensory hair cells	S5
1.4 Development of spiral ganglion cells	S6
1.5 Regenerative factors	S25
1.6 Embryonic development principles – correlation with other organ systems	S26
2 Non-syndromic Hearing Disorders	S26
3 Malformations of the Cochlea	S27
3.1 X-linked deafness DFN3, Gusher-associated	S27
3.2 Complete aplasia of the semicircular canals and CHARGE syndrome	S28
3.3 Cochlear implantation in cases of cochlear malformations	S29
4 Susac's Syndrome	S31
5 Hearing Loss and Microcirculation	S32
6 Rare Diseases of the Cochlea: Outlook and Conclusion	S33
Conflict of Interest	S34
References	S34

Introduction

The cochlea is a highly complex microsystem. In its completely developed stage, it consists of the spiral ganglion (neuronal tissue supported by satellite cells), the organ of Corti (neuroepithelium for sensory perception), the stria vascularis (highly vascularized epithelium that is responsible for ion transportation), and the otic capsule (specialized bony tissue). Although the cochlea was initially considered an immune privileged organ, the immune system (endolymphatic sac) also contributes to the hearing process. Subsets of tissues in the cochlea are also found in other organ systems. For example, the brain, as well as cranial and peripheral nerves have a comparable network structure of neurons and glial cells; a complex and highly structured sensory epithelium such as the organ of Corti is also found in the retina; the stria vascularis and the renal corpuscles are both metabolically highly active tissues that maintain ionic balance. These structural similarities of the cochlea and other tissues are reflected in the clinical observation that many diseases of the inner ear may also affect other organ systems.

Diseases of the cochlea are usually associated with hearing loss. Even if the degree of hearing loss can be well assessed subjectively and objectively, the actual cause of hearing loss remains unknown in most cases. Frequently, rare diseases that affect cochlea are often undiagnosed and represent a particular challenge because many are unknown to most general practitioners and specialists.

Amongst diseases affecting the cochlea, Many diseases of the cochlea are classified as rare (see Table). In recent years, modern molecular biological procedures could define the cause and pathophysiology of most rare diseases. Investigating rare diseases on a molecular level led to the identification of novel mechanisms underlying the pathophysiology of cochlear dysfunction and leading to the discovery of new therapeutic interventions.

The present article summarizes all rare diseases to the authors known where primary involvement of the cochlea resulting in sensorineural hearing loss is present (summarized in ► **Table 1**). Further rare diseases occurring primarily in other organ systems of the field of oto-rhino-laryngology that may also affect the cochlea are described in other articles of this publication (Weiss NM, Rare diseases of the middle ear and the lateral skull base; Scherl C, Rare diseases of the head and neck part III: salivary glands and facial nerve; Dlugaiczyk J, Rare diseases of the vestibular labyrinth: of zebras, chameleons, and wolves in sheep's clothing). The table organizes the diseases based on their pathophysiology or pathogenesis and gives a systematic overview.

In depth knowledge of the embryonic development of the cochlea allows for a better characterization of rare cochlear diseases. This is important especially for malformations and syndromic hearing loss. Common molecular principles the embryonic development of the cochlea are shared with other organs such as the heart, kidneys, and eyes. These common principles are revealed especially in syndromic cases.

We illustrate the complexity of the evaluation of rare diseases with clinical examples. For example, the role of interdisciplinary and even international collaborations for the diagnosis of the rare vascular disease called Susac's syndrome is emphasized. It further becomes obvious how difficult and long the way may be for patients to get a definite diagnostic assessment. Further examples (CHARGE syndrome, X-linked deafness) also illustrate the importance of interdisciplinary approaches, in particular with regard to imaging in the context of hearing restoration with cochlear implants.

The majority of the rare diseases show a high variability of their phenotype despite having the same genetic defect. This makes the classic approach of symptom-based diagnostics difficult. On the other hand, overlapping phenotypic patterns can be found for certain diseases even if different genetic defects are present. These observations emphasize the importance of electrophysiology, imaging, and in particular modern molecular diagnostics including proteome analysis that might be the basis for advances in oto-rhino-laryngology.

1 Embryonic Development and Morphology of the Cochlea

Accruing knowledge about the molecular evolution of its phenotypic development is a fundamental component of understanding an organ system. Knowing the molecular mechanisms leading to the development of the inner ear may contribute to better characterization and classification of rare diseases and malformations. In the following paragraphs, the embryonic development of the inner ear will be described.

Different tissue layers lead to the development of different portions of the inner ear. The membranous labyrinth is derived from the otic vesicle, which invaginates from the ectoderm whereas the bony labyrinth derives from the mesenchyme.

Beside morphogenesis, the formation of the inner ear also requires the specification of cellular fate. Morphogenesis of the inner ear is initiated from a flat thickening of the ectoderm leading to the

development of the fluid filled spaces of the labyrinth and the cochlea. Specification of the cellular fate means the development of neurons, sensory cells as well as numerous non-sensory cells of the inner ear. A multitude of genes and thus induced biochemical processes contribute to the development that have a highly complex spatiotemporal expression pattern. The exact mechanisms playing a role in this context are only incompletely understood until now.

1.1 Morphogenesis of the inner ear

Most cell types forming the inner ear of adults have their developmental origin in the otic placode. The otic placode is the first step of inner ear development (► Fig. 1; 3rd week, on the left). It is a thickening of the ectoderm, lateral to the rhombencephalon, that by invagination into the underlying mesenchyme forms a vesicular structure (► Fig. 1; 3rd week), the otocyst (also known as the otic vesicle) [1] (► Fig. 1; 3rd week, on the right). The otocyst is divided into a vestibular and a cochlear part (► Fig. 1; 4th week). The vestibular compartment of the membranous labyrinth develops from the dorso-lateral part of the otic vesicle and the cochlear structures including the saccule develops from the ventromedial part [2].

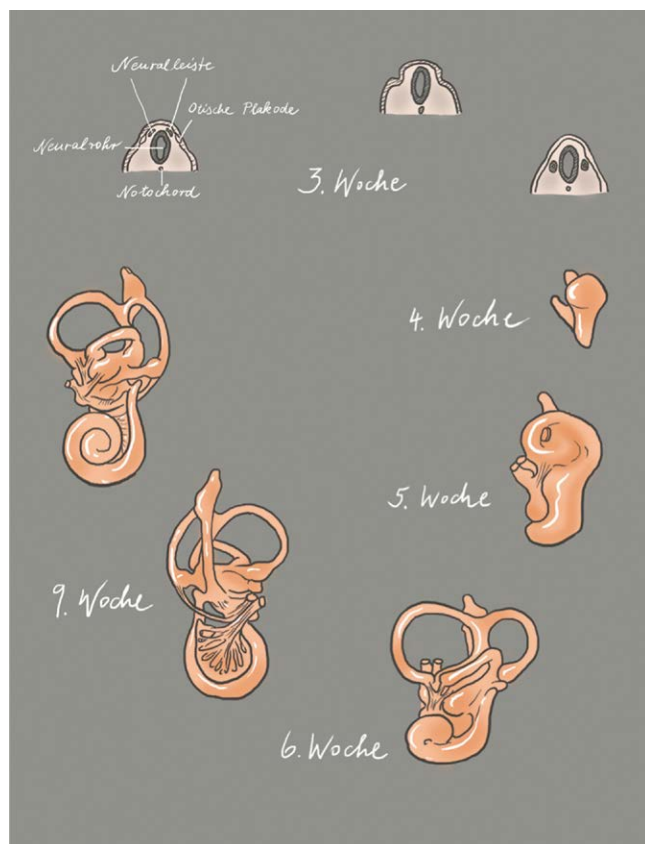
The developing cochlear part extends to a tubular structure, called cochlear duct (► Fig. 1; 5th week). During growth, the cochlear duct forms a spiral and in the 8th week of embryonic development, the 2.5 turns are complete (► Fig. 1; 6th and 9th week). In the 9th embryonic week, the organ of Corti develops. At the beginning, it appears as an arrangement of polygonal cells equipped with a

nocilium and numerous microvilli on their surface [3]. The microvilli disappear within the next weeks and are replaced by stereocilia [4] that develop first on the inner and later on the outer sensory hair cells. The formation of stereocilia runs from the cochlear base to the apical area. It is the first morphological sign of sensory hair cell differentiation. Next, the arrangement of the inner and outer sensory hair cells becomes obvious. While one single row of inner sensory hair cells develops, the number of rows of outer sensory hair cells may vary between 3 and 4. In parallel, i. e., between the 9th and 13th embryonic week, the tectorial membrane develops that covers the organ of Corti. The binding of the tectorial membrane to the stereocilia seems to develop from an initially immature stage, characterized by loose binding, to a more mature stage where a firm connection between the outer sensory hair cells and the stereocilia is formed. Up to the 15th week, the organ of Corti appears as a solid cell mass that is covered by a thin tectorial membrane.

All sensory hair cells develop a row of stereocilia, however, the inner sensory hair cells seem to be more mature than the outer ones with a characteristic U-shape in the configuration of the stereocilia. At the 22nd week, this process is completed, the stereocilia have matured and show the same distribution pattern as in adults.

At the end of the 11th embryonic week, the cochlear duct is surrounded by cartilage and fluid-filled spaces develop that form the scalae tympani and vestibuli by the 15th week. In the 18th week, the tunnel of Corti (also known as internal tunnel, cuniculus internus) has already developed from the solid cell mass of the organ of Corti (named after the Italian anatomist Alfonso Giacomo Gaspare Corti, 1822–1876). Also, Nuel's space (also known as middle tunnel, cuniculus medius; named after the Belgian physician Jean Pierre Nuel, 1847–1920) is fully developed and due to regression of Kölliker's organ (named after the German anatomist and physiologist Rudolf Albert von Kölliker, 1817–1905), the tectorial membrane is freed. Kölliker's organ is a structure (greater epithelial ridge) that transiently develops in the cochlea [5]. It consists of pillar like supporting cells releasing ATP. This binds to the ionotropic purinergic receptors (P2X receptors) of the inner sensory hair cells and leads to depolarization and calcium inflow. This process imitates the effect of depolarization by sound and leads to periodic excitation of the spiral ganglion cells during development. In addition, other trials could show that Ca²⁺ spikes in neonatal inner sensory hair cells induce excitatory postsynaptic currents in the afferent dendrites of the spiral ganglia cells [6]. After maturation of the cochlea and onset of the hearing capacity, this ATP induced intrinsic activity of the inner sensory hair cells disappears. It is assumed that this spontaneous activity of the inner sensory hair cells and fibers of the auditory nerve is crucial for the neuronal survival of the cochlear nucleus in humans before hearing onset, for the correct interconnection of the auditory pathway, and for the formation/refining of the tonotopy in the auditory nuclei. In other words, this means that peripheral, non-sensory cells that are in Kölliker's organ are responsible for the maturation of the auditory pathway [7].

Between the 20th and 22nd fetal week, the cochlear duct is already manifestly longer with a larger diameter; the stria vascularis has developed its characteristic 3 cell layers, and the tectorial membrane is well developed. Afterwards, the outer pillar cells and the



► Fig. 1 Illustration of the morphogenesis of the inner ear; modified according to Gray's Anatomy, 41st edition, 2016 [8], and according to Cummings, 7th Edition, 2020 [9]; copyright Elsevier.

outer sensory hair cells extend step by step, and Deiters' and Hensen's supporting cells develop. At the end of the 2nd trimester, the cochlea already has a mature appearance while the synapses of the efferent brainstem fibers are not yet fully developed.

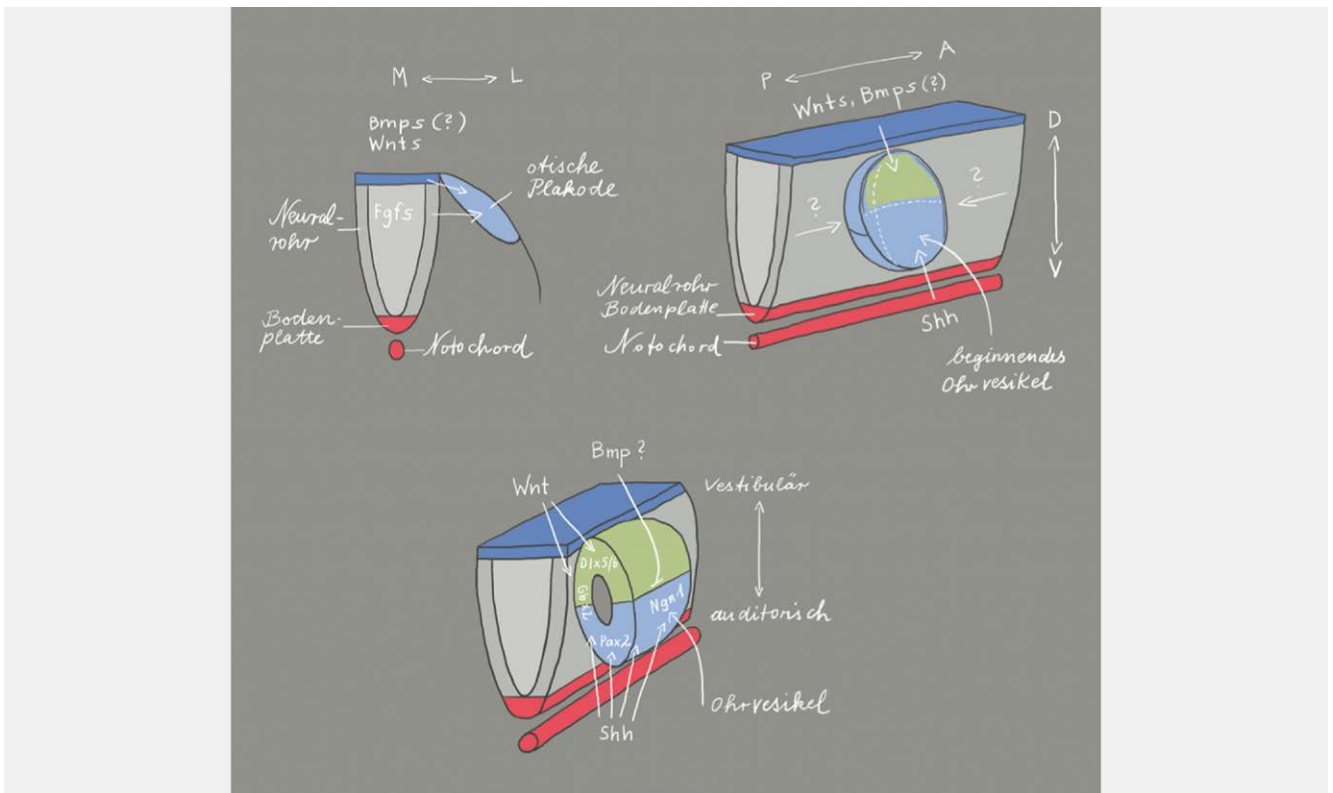
The cochlear nerve develops from a group of cells (neuroblasts) that derive from the medial part of the ear epithelium and pass into the underlying mesenchyme. They form the VIIIth (vestibulocochlear) ganglion leading to the development of the 8th cranial nerve [10]. The ganglion cells, out of which the auditory part of the VIIIth nerve will develop, organize around the modiolus to form the spiral ganglion. Axons that develop from these ganglion cells migrate centrally to the brain and peripherally to the organ of Corti. During the 5th/6th week of gestation, the axons first form synapses with the brainstem neurons. The dendrites only reach the basal turn of the cochlea at the end of the 9th embryonic week and form contacts with the developing sensory hair cells between the 10th and 12th embryonic week [11]. By the end of the 12th week of gestation, the development of the classic afferent synapses between neurons and sensory hair cells is initiated. Presynaptic bodies surrounded with vesicles can first be observed at the base of the inner sensory hair cell, with similar findings in the outer hair cells by the 13th week. By the 14th fetal week, basal to apical synapse formation is fully completed while the myelin-forming Schwann cells cannot be detected until the 15th fetal week. At this early stage, the outer sensory hair cells are exclusively innervated by afferent neurons. In humans, the formation of axo-somatic synapses with the efferent system only takes place with the onset of the cochlear function, i. e., around the 20th week. This observation seems to reflect an evolutionary process. At the beginning of synapse formation, the outer hair cells only function to transmit auditory signals to the brain. With the efferent interconnection at the end of maturation of the organ of Corti, the outer hair cells begin to function in their role as cochlear amplifiers. This process is more pronounced in the basal and middle regions of the cochlea compared to the apical areas leaving the apical outer hair cells innervated by mainly afferent rather than efferent neurons. Looking at ciliogenesis during this time period, it becomes obvious that the apical area of the cochlea remains in an immature stage so that the cochlea should be correctly subdivided into a basal and an apical part based on the embryonic development. As of the 22nd fetal week, myelination within the cochlea and thin myelin sheaths are already visible [12]. In the 24th fetal week, the extension of the myelin sheaths to the exit of the nerve from the temporal bone is revealed. After this time, myelination is performed by oligodendrocytes that have already settled at the nerve. Central myelination, however, has not occurred at this point [13].

Between the 7th and 8th embryonic week, the auditory nuclei and pathways are already fully developed. The neurons of the brainstem containing information of the immature axons of the hearing nerve can be identified at the border of the brainstem as cochlear nuclei. A subset of these crosses in the brainstem and projects its extensions more centrally into the contralateral superior olivary nucleus [14]. The remaining neurons extend to the lateral lemniscus and from there into the inferior colliculus. The medial geniculate body can be identified in the 8th embryonic week and is innervated by the axons from the inferior colliculus. Between the

9th and 13th week, only growth rather than structural change is observed in the brainstem. However, the neurons of the brainstem are still very small and immature even if the nuclei are relatively well developed. In the course of the second trimester, not only the neurons increase in size but also develop cytoplasm and cell organelles. By the end of the 24th fetal week, more and more cytofilaments are present in the auditory neurons. Also, in the axons of the brainstem neurons, accelerated maturation is observed in the second trimester. Neurofilament that can only be detected in few neurons of the cochlear nerve at the end of the 16th week is clearly visible at the end of the second trimester as bundled fascicles in the within the cochlear nerve and the brainstem.

1.2 Molecular biology of the embryonic development

The otic placode is one of the craniofacial placodes from which several structures develop (e.g., inner ear, the olfactory epithelium, neurons of different cranial sensory ganglia, eye lens). All these placodes develop in the pre-placodal region that is characterized by the expression of a common set of transcription factors (Six1, Eya2, and Foxi3) [15]. The otic vesicle (otocyst) develops from the pre-placodal region at the level of rhombomeres 5 and 6, influenced by the FGF signaling pathway [15]. The transcription factors Pax2 and Pax8 are markers of the otic vesicle. Gene expression profiles within the otic vesicle, in the adjacent tissue of the developing otic vesicle, within the borders between otic and adjacent tissue as well as within the borders of the compartments into which the developing otic vesicle may be divided schematically seem to be responsible for the orientation of the inner ear (► **Figs. 2** and ► **3**). The rhombencephalon is arranged in segments that are called rhombomeres. Each rhombomere is able to express specific genes. The otic placode is adjacent to rhombomeres 5 and 6 so that this area seems to play a crucial role in the axial organization as well as specification of the fate of inner ear cells. Mouse mutants with defects of the rhombencephalon in the area of the rhombomeres 5 and 6, where the border between these rhombomeres is maintained, show normal formation of the inner ear. The border between both rhombomeres corresponds nearly exactly to the midline of the otic vesicle and is possibly responsible for the specification of the otocyst cells into the anterior and posterior compartments. Since both rhombomeres develop very early, they may influence the development of the anterior and posterior otocyst by means of different signals [16]. Signal transmission between the cells of the otocyst and the cells of the rhombencephalon, is enabled by the Eph/ephrin system [17]. While the cells of the rhombomere 6 express high concentrations of the ligands of ephrin B2 and B3, a high density of the receptors EphA4, A7, B2, and B3 are found in rhombomere 5 [18, 19]. This means that the postero-medial cells of the otocyst that are in direct contact with rhombomere 6 receive ephrin-mediated signals, whereas cells adjacent to rhombomere 5 do not. Probably these signals are directly transmitted to the dorsal pole of the otic vesicle where the cells of the otic placode are in direct contact with the cells from the neural tube because no delimitation by a basal lamina is present. This would mean right from the beginning that distinct compartments form in the developing otocyst, i.e., the antero-medial and the postero-medial compartment [16]. These

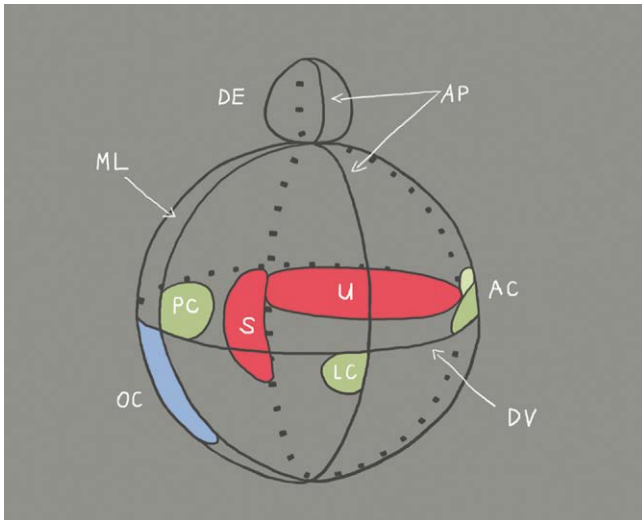


► **Fig. 2** The location of formation of the otic placode along the body axis is defined via the expression of fibroblast growth factors (FGF) from the neural tube [20]. The release of FGF in the periotic mesoderm shortly before the development of the otic placode [21] leads to the expression of several transcription factors that are necessary for the development of the inner ear [22, 23]. The orientation of the antero-posterior axis starts with the expression of FGF10, lunatic fringe (Lfng), delta 1, neurogenin1 (Ngn1), and neuronal differentiation factor (NeuroD1) in the anterior region of the invaginating otic placode. This gene expression pattern is limited to the anterior region of the otocyst. This limitation is mediated by Tbx1 that is exclusively expressed in the posterior part of the otocyst. The dorso-ventral axis depends on the **WNT** and **SHH** expression in the rhomb encephalon. WNT is expressed in the dorsal area and leads to upregulation of Dlx5, Dlx6, Hmx2, and Gbx2. These genes are responsible for the development of vestibular structures in the dorsal region of the otocyst. On the other hand, there is the expression of SHH from the notochord that determines the fate (auditory) of the cells in the ventral part of the otocyst by regulating the expression of the transcription factors Pax2, Ngn1, Lfng, NeuroD1, Sox2, and Six1. BMP (bone morphogenetic protein) and SHH inhibit each other so that BMP assumes a significant role in the morphogenesis of the inner ear. Illustration modified according to [24, 25].

compartments are responsible for the organization of the cells and the inner ear specific development and orientation of the organ. They are characterized by a specific gene expression profile, and define and delineate the cell fate. This means that on one hand the cells in the respective compartments define the location and structure of the cochlea and the semicircular canals, the utricle, saccule as well as endolymphatic duct, on the other hand the mixing of the cells of different lines is not possible (► **Fig. 3**). Furthermore, probably the gene expression within the compartment decides which sensory organ (organ of Corti, crista or macula) develops. Soluble factors and cell surface molecules could then influence the cells along the border between the compartments, but only those that are directly adjacent to the border. Their diffusion seems to be possible but only in a radius of very few hundred micrometers. These factors may be for example morphogens, which would mean that elongating structures are induced along the border zone between two compartments while morphologically localized organs such as the crista may only develop at the border between three compartments. Thus, an exact location may be specified.

1.3 Development of sensory hair cells

Different soluble factors are necessary for the induction of the otic placode: FGF from the mesoderm and the neuroectoderm, SHH from the notochord and the base plate of the neural tube, WNT from the rhombencephalon as well as BMP from the ectoderm. The anterior area of the otocyst where the neurosensory cells of the inner ear develop is characterized by the expression of Lfng, Sox2, and Eya1 [31] while Tbx1 and Lmx1a are expressed in the dorsal part in the non-sensory region. Within the prosensory region, the proneuronal transcription factor Neurog1 is upregulated at an early stage. It is not only necessary for the formation of neurons but it also contributes essentially to the development of the sensory epithelium including the sensory hair cells [32]. It belongs to the basic helix-loop-helix (bHLH) transcription factors and is expressed together with Neurod1 by proliferating progenitor cells. The bHLH gene Atoh1 (atonal-homolog-1)/Math1 (murine atonal homolog 1)/Hath1 (human atonal homolog 1) is necessary for the development of sensory hair cells [33, 34]. Furthermore, the POU domain transcription factor POU4f3, the zinc finger transcription factor Gfi1, and the homeodomain factor Barhl1 are needed for the main-



► **Fig. 3** Illustration of the compartments of the developing inner ear and location of the different organs (organ of Corti: OC; sacculus: S; utricle: U; endolymphatic duct: ED; cristae of the semicircular canals: AC, PC and LC) as well as the axes (AP: antero-posterior; DV: dorso-ventral; ML: medio-lateral). The orientation in the antero-posterior axis takes place before the orientation in dorso-ventral direction [26]. The dorso-ventral axis is not defined until the formation of the otocyst [27]. The axial specification already starts with formation of the otic placode and depends on factors (► Fig. 2) that are expressed by rhombomeres 5 and 6 of the rhombencephalon. As soon as a rhombomere is rotated in ovo along the dorso-ventral axis, the expression of the ventral genes *Lfng*, *NeuroD1*, and *Six1* (see Table, BOR syndrome) is shifted into the dorsal regional of the otocyst, whereas the expression of dorsal genes like *Gbx2* is inhibited. This means that by rotation of the rhombomeres ventral areas of the rhombencephalon may transform ventral areas of the otocyst into dorsal otic tissue [26]. The formation of organs of the inner ear after the stage of otocyst depends on the expression of *Gata3* (see table, Bakarar-HDR syndrome), *Eya1* (see table, BOR syndrome), and *FGF3/8* (see table, Kallmann syndrome, which was shown in investigations of *Gata3*, *Eya1*, and *FGF3/8* deficient mice [28–30]). *SHH* (see Table, incomplete partition and Carpenter syndrome) as well as *Pax2* are cochlear genes because mutations in these genes allow only the formation of a short, straight cochlear duct. *Gbx2*, *Hmx2*, *Hmx3*, and *WNT* are considered as vestibular genes because a defect of one of these genes leads to morphological defects of the sacculus, utricle, or the semicircular canals (illustration modified according to Brigande et al., 2000 [16]).

tenance and formation of sensory hair cells [32]. The singular and highly specific pattern of cell alignment in the sensory epithelium of the inner ear where sensory hair cells and supporting cells are arranged alternately allows the assumption that local cell communication mechanisms override predetermined cell specification. The notch-signaling pathway regulates the determination of the cellular fate in numerous organ systems [35]. During the development of the inner ear, notch (see Table; Hajdu-Cheney syndrome) is initially distributed in the entire epithelium. With the differentiation of the sensory hair cells, however, its expression is limited to the supporting cells. Delta 1 and Jagged2, however, are synthesized by the sensory hair cells of the murine cochlea about one day after the onset of *Math1* expression [36]. Hereby, the cells that are sup-

posed to develop into sensory hair cells express *Jagged1*, which increases the notch activity in the neighboring cells and thus forces them to adopt another cell type (the one of supporting cell). This process is called lateral inhibition.

The formation of the apical mechanosensory region (the site where the stereocilia are located) plays a vital role for the function of the sensory hair cells. The stereocilia of the sensory hair cells are packed with actin and other cytoskeletal proteins. They are organized in V-shaped ascending rows. The organization is uniform throughout the entire organ of Corti while the tip of the V always points into the periphery of the cochlear duct and is essential for correct function [37]. In the context of orientation of the sensory hair cell bundles, the WNT/planar cell polarity-signaling pathway plays a crucial role. The asymmetric distribution of the planar cell polarity proteins of frizzled (*Fzd*), disheveled (*Dvl*), Van Gogh (*Vangl*), and prickle (*Pk*) leads to polarization of the sensory hair cells. It could be shown that *Fzd* and *Dvl* proteins form a complex on one side of the cell whereas *Vangl* and *Pk* arrange at the contralateral side [38]. It is assumed that the subunit of the kinesin II motor complex, *Kif3a*, regulates the organization of the sensory hair cells. In *Kif3a* mouse mutants, the kinocilium is missing, the cochlear duct is shortened, and the shape of the sensory hair cell bundles seems to be flattened [39]. Disorders of the cilia, so-called ciliopathies, are characteristic for Bardet-Biedl and Senior-Løken syndrome (► Table 1).

1.4 Development of spiral ganglion cells

During the development of the central nervous system, basic helix-loop-helix (bHLH) transcription factors are responsible for the specification of cells, whereas lateral inhibition by the delta/notch system inhibits neuronal differentiation in neighboring cells by activating the inhibitory effector genes *Hes* and *Hey* [40]. Several soluble factors such as WNT (wingless), FGF, BMP, and SHH (sonic hedgehog) induce neuronal progenitor cells [41] expressing proneuronal genes and allow the change of fate to glia formation via activation of the COUP-TF/II transcription factor [42]. These basal patterns of embryonic development of the nervous system can also be observed in the context of ontogenesis of the inner ear. It can be assumed that the entire otocyst is able to form neuroblasts. Already shortly after invagination of the otic placode, a delamination of neuroblasts occurs from the anterior and ventral region, that is called neurosensory domain, and out of which the VIII. cranial ganglion (also known as cochleovestibular ganglion) develops [15]. For differentiation of spiral ganglia cells, the proneuronal bHLH transcription factor neurogenin1 (*Ngn1*) is needed. After an initial overexpression of *Ngn1*, an upregulation of *Neurod1* as well as delta and notch genes occurs within the developing spiral ganglion cells while *Ngn1* itself is downregulated [43]. The expression of *Gata3* also seems to play a crucial role for the formation of neurons, in particular in the context of central connection. However, this process could not be fully clarified up to now because *Gata3* contributes to the development of the inner ear already at an early stage in embryonic development and a systemic deletion of *Gata3* leads to impaired formation of the inner ear [44]. The development of neurons further depends on the expression of *POU4f1* (formerly called *Brn3a*) [45]. During their development, the spiral ganglion cells migrate from the cochlear duct to the spiral canal of the mo-

► **Table 1** Rare diseases of the cochlea.

Name	Cause	Gene	Inheritance	Incidence	Therapy	Symptoms	Annotations
Autoimmune-mediated inner ear diseases							
Cogan syndrome	Autoantibody-mediated (?) vasculitis with systemic manifestation [127]	-	-	About 300 cases worldwide [127]	Corticosteroids, cyclophosphamide, methotrexate, mycophenolate mofetil, azathioprine, infliximab [127]	Non-syphilitic interstitial keratitis (IK) with audiovestibular Menière-like symptoms [127]; typical and atypical types are described: in atypical types, the eye involvement manifests with non-IK inflammatory ocular symptoms	Max. 2 years between the affection of both organs (eye and inner ear) [127]; is considered as vasculitis [117]
Muckle-Wells syndrome	Excessive release of IL1beta [128]	NLRP3 [128]	aut. dom. [128]	1–3:1.000.000	Anakinra [128]	Fever, skin rash, musculo-skeletal symptoms and conjunctivitis. Progressive sensorineural hearing loss and kidney failure [128]	Belongs to the group of CAPS (cryopyrin-associated periodic syndrome); Muckle-Wells syndrome, FCAS (familial cold auto-inflammatory syndrome) and NOMID (neonatal onset multisystem inflammatory disorder) have a common causative gene defect (NLRP3)
Neonatal onset multisystem inflammatory disease (NOMID)	Excessive release of IL1beta [129]	CIAS1/NLRP3 [129]	aut. dom. [129]	Very rare, 100 cases have been described worldwide [129]	Anakinra [129]	Skin rash, chronic meningitis, fever, joint inflammation [129]	
Relapsing polychondritis	Autoimmune-mediated inflammation of cartilage [130]		Multifactorial etiology [130]	1:285.000 [130]	Glucocorticoids [130]	Cartilage inflammation, uveitis, vasculitis, hearing loss in 50%, vertigo [130]	
Vogt-Koyanagi-Harada disease	T cell mediated destruction of melanin-containing tissue [131]	-	-	1:400.000 [131]	Glucocorticoids [131]	Uveitis, alopecia, meningism [131]	
Vascular							
Behçet's syndrome	Vasculitis, HLA-B51-associated (?)	-	-	Regional differences, 1:100.000 in Germany	Symptom-based, steroids, non-steroidal antiinflammatories [132]	Recurrent oral aphthae, genital ulcers, eye and skin lesions [132]	Kidneys and peripheral nerve system are very rarely affected

► Table 1 Continued.

Name	Cause	Gene	Inheritance	Incidence	Therapy	Symptoms	Annotations
Eosinophilic granulomatosis with polyangiitis (EGPA; formerly: Churg-Strauss syndrome)	Allergic granulomatosis with polyangiitis, antinuclear cytoplasmic antibody-associated vasculitis [133–134]	-	-	2.4–1,000,000	High-dose glucocorticoids, cyclophosphamide, zafirlukast (leukotriene antagonist) [134, 135], mepolizumab (anti-interleukin-5 antibody) [136]	Blood eosinophilia, heart failure, allergic rhinitis, asthma, vasculitis with involvement of the skin, heart, lung, gastrointestinal tract, neural system [133, 134, 136]	Triphasic disease, manifestation in the inner ear in the 3 rd phase is rarely observed [133], EGPA is classified as ANCA-associated vasculitis among minor vessel vasculitis
Generalized arterial calcification in infants	Calcium deposits in the arteries [137]	ENPP1, ABCC6 [137]	Aut. rec. [137]	1:391,000 [137]	Bisphosphonates [137]	Heart failure, stroke, pseudoxanthoma elasticum [137]	Also conductive hearing loss [137]
Hereditary hemorrhagic telangiectasia (Weber-Osler-Rendu disease)	Vascular dysplasia, arterio-venous fistulas/ malformations [138]	Chromosomes 9q and 12q [138]	Aut. dom [138]	1–2:100,000 [138]		Vascular malformation of multiple organs (kidney, gastrointestinal tract, liver, lung, brain), recurrent epistaxis as most frequent symptom	
Kawasaki disease	Necrotizing vasculitis [139–140]	Unknown, corona virus (?)		>300,000 cases have been described worldwide [139]	Intravenous application of immunoglobulins, aspirin	Fever, skin rash, conjunctivitis, cardiac complications	Appears nearly exclusively in children
Norrie disease	Disorder of the angiogenesis of eye and inner ear [141]	NDP [141]	X-linked	More than 400 cases have been described worldwide		Retinal detachment and progressive hearing loss [141]	
Susac's syndrome	CD8 T cell-mediated autoimmune-microangiopathic endotheliopathy [142]	-	-	Slightly more than 300 cases have been described worldwide [142]	Anti-platelet medicine, anti-coagulants, immunosuppressive treatment with e.g., cyclophosphamide, intravenous immunoglobulins, mycophenolate mofetil, azathioprine, methotrexate, natalizumab [142]	Visual field loss, visual loss, neurological symptoms, cephalgia [142]	

▶ Table 1 Continued.									
Name	Cause	Gene	Inheritance	Incidence	Therapy	Symptoms	Annotations		
Granulomatosis with polyangiitis (GPA; formerly: Wegener's granulomatosis)	Autoimmune vasculitis [143]	-	-	1:6,400 [143]	Glucocorticoids, rituximab [143]	Sinusitis, tracheal stenosis, kidney failure, pneumonia, mastoiditis [143]	ANCA + [143]		
Malformations									
Labyrinthine aplasia	Complete aplasia, when the development is disturbed before or at the beginning of the 3 rd week of gestation; may also be thalidomide-induced [144–145]		Increased risk in cases of consanguine parents [146]	2% of all inner ear malformations	ABI	Facial nerve paresis or weakness [146]	Synonym: Michel deformity, Michel aplasia, bony canal of the internal carotid artery may be missing [146]		
Otocyst deformity	Developmental arrest in the 3 rd week of gestation [146]		Increased risk in cases of consanguine parents	1% of all inner ear malformations	ABI	Congenital deafness, possible facial nerve palsy or weakness [146]	Synonym: common cavity (according to Jackler)		
Cochlear aplasia				5% of all inner ear malformations [100]	CI, ABI [100]	Congenital deafness	Speech understanding with CI is possible [100]		
Cochlear hypoplasia (isolated)	Frequently occurs in BOR syndrome [108]			13% of all inner ear malformations [108]	CI	Deafness, high-grade hearing loss	Broad spectrum, nearly normal form up to a small basal cyst [108]		
Complete aplasia of the semicircular canals	(includes hypoplastic cochlea and small vestibule with saccule) [147]	Often associated with CHARGE; single case reports with e.g., Wildervanck, Noonan, Goldenhar, or VACTERL * [148]		16% of all inner ear malformations	CI	Deafness, high-grade hearing loss [147]	Main criterion of CHARGE		
Incomplete partition type 2 (IPT2)				21% of all inner ear malformations [149]	CI	Deafness, high-grade hearing loss	Mondini malformation in the actual sense [149]		
Incomplete partition type 1 (IPT1)		FOXP2 [150]		9% of all inner ear malformations [149]	CI	Deafness, high-grade hearing loss	Synonym: common cavity (E. Cock); cystic cochleovestibular malformation, figure-8 deformity		

► **Table 1** Continued.

Name	Cause	Gene	Inheritance	Incidence	Therapy	Symptoms	Annotations
X-linked deafness (inner ear malformation called IPT3)	Different mutations of POU3F4 [89]	POU3F4		3% of all inner ear malformations	Hearing aids, CI [151]	Variable hearing loss	Synonym: gusher, IPT3 – even if it is not in line with other incomplete partitions; often associated with hamartoma of the tuber cinereum [92]
Modiolus aplasia				1% of all inner ear malformations [110]			
Hypoplasia or aplasia of the vestibulocochlear nerve or isolated of the cochlear nerve							Mostly combined with severe inner ear malformations [110]
* VACTERL describes an association of congenital malformations that has at least three of these symptoms: esophageal atresia, kidney malformation, heart defect, vertebral defects, anorectal malformations, and radial extremity malformations							
Chromosomal							
3p deletion syndrome	Deletion of the short arm of chromosome 3 [152–153]	Chromosome 3 [152–153]	De novo [152–153]	Very rare		Microcephaly, triangular shape of the face, flat occiput, hypertelorism, polydactyly, cryptorchidism, renal and cardiac defects [152–153]	
10p deletion syndrome	Deletion of the short arm of chromosome 10 [154]	Chromosome 10 [154]		Very rare, about 50 cases are known [135]		Craniofacial malformations, growth disorders, congenital heart defects, hypoparathyroidism, immunodeficiency, mental retardation [154]	Haploinsufficiency 10p15 causes also HDR1 syndrome [155]
Cri-du-chat syndrome, 5p deletion syndrome	Deletion of the short arm of chromosome 5 [156]	Haploinsufficiency of various genes, e.g., TERT, MARCH6, CTNND2, and SLC6A3 on chromosome 5 [156]	De novo [156]	1:15,000–1:50,000 [156]		High-frequency cry (cri-du-chat), microcephaly, facial dysmorphism, delayed speech acquisition, mental disability [156]	Most frequent chromosomal defect [156], neural hearing loss [157]
DiGeorge anomaly [154], chromosome 22q11.2 deletion	Haploinsufficiency of DiGeorge syndrome critical region gene 2 (DGCR2) [155]	DGCR2, centromere deletion of chromosome 10, 22q11.2 deletion [154, 158]		1:4,000 [158]	Allogenic thymus tissue transplantation [159]	Thymus aplasia, congenital developmental disorder, T cell deficiency, hypocalcaemia, cardiovascular malformation, facial dysmorphism [154]	

▶ Table 1 Continued.									
Name	Cause	Gene	Inheritance	Incidence	Therapy	Symptoms	Annotations		
Cat eye syndrome, Schmid-Fraccaro syndrome	Anomaly of chromosome 22, 22 [160–161]	Chromosome 22 [160–161]	Aut. dom. (160, 161)	1:100,000 [160–161]	Symptom-based, experimental: GNE-886, selective inhibitor of the cat eye syndrome chromosome region candidate 2 bromodomain [162]	Coloboma, anal atresia, heard defects, preauricular tags [160–161]			
Mosaic trisomy 9	Partial trisomy [163–165]	Chromosome 9 [163–165]				Growth retardation, muscular weakness, mental disability, microcephaly, micrognathia, characteristic palpebral fissures, skeletal anomalies, microphthalmia, cleft palate, hydrocephalus [163–165]	Partly very mild courses that remain undiagnosed [163]		
Mosaic trisomy 22	Partial trisomy [166–167]	Chromosome 22 [166–167]				Mental disability, growth disorders, failure to thrive, craniofacial asymmetry, microcephaly, brachycephaly, hypoplasia of the midface, preauricular tags, flat nose, micrognathia, cleft palate [166–167]	Overlapping with cat eye syndrome?		
Pallister-Killian mosaic syndrome	Chromosome duplication (12p) [168]			150 cases worldwide [168]		Muscular hypotonia and telecanthus [168]			
Smith-Magenis syndrome [169]	17p11.2 deletion [169]	RAI1 [169]		1:15,000 [169]		Brachycephaly, broad square-shaped face, hypotonia, sleep disorder, self-injury [169]	Initially conductive hearing loss, the progressive sensorineural hearing loss at the age of 10 years		
Trichorhinophalangeal syndrome type II	Chromothripsis, chromosome deletion (q8) [170]	TRPS1, EXT1 [170]		<60 worldwide [170]		Thin hair, short stature [170]	Langer-Giedion syndrome [170]		
Metabolic diseases									
Acyl-Co-A dehydrogenase deficiency (Schindler syndrome)	Lactate acidosis, mitochondrial disease of the complex I concerning the respiratory chain [171]	ACAD9 [171–172]	Aut. rec. [171]	Very rare, 24 patient from 12 families have been described up to 2016 [172]	Riboflavin substitution is effective in some patients [171–172]	Neurological, muscular, hepatic, and cardiac manifestation [171–172]			
Alpha galactosidase deficiency (Fabry's disease)	Lysosomal storage disease, glycol-sphingolipid catabolism [173]		X-chromosomal	1:40,000–1:117,000	Agalsidase beta (enzyme substitution) [174]	Progressive kidney disease, cardiomyopathy, cerebrovascular complications, neuropathic pains, apoplexy [173]	Atrophy of the organ of Corti, stria vascularis, and the spiral ligament in 2 post-mortem analyses [173]		

▶ Table 1 Continued.

Name	Cause	Gene	Inheritance	Incidence	Therapy	Symptoms	Annotations
Alpha mannosidosis	Deficiency of the lysosomal alpha D mannosidase	MAN2B1	Aut. rec.	1:500,000 [135]	Velmanase alpha (Lamzed®) by Chiesi [175–176]	Recurrent infections, muscular weakness, skeletal and facial deformities, ataxia, hepatosplenomegaly, hydrocephalus, macroglucosuria, prognatism, strabismus, hyperopia or myopia; immune deficiency, hypersomnia, psychiatric diseases, mental disability [135, 177]	Lysosomal storage disease; different subtypes, severity and age at disease onset [135, 177]
Biotinidase deficiency	Disorder of all mitochondrial coxylases [178]	BTD [178]	Aut. rec. [178]	1:50,000 [178]	Biotin substitution	Seizures, muscular weakness, ataxia, developmental delay, visual loss, alopecia, skin rash [178]	Neuromyelitis optica spectrum disorders (NMOSDs) Holocarboxylase synthetase (HCLS) deficiency; incidence of 1:200,000
Brown-Vialetto-van-Laere syndrome (riboflavin transporter deficiency)	Deficiency of riboflavin transporter proteins	SLC52A2, SLC52A3 [179]	Aut. rec. [179]	Less than 100 cases are known [179]	Riboflavin substitution [180]	Progressive pontobulbar paralysis, respiratory insufficiency, muscular weakness, facial nerve palsy, ptosis, dysphagia, and ataxia [179]	
Camurri-Engelmann syndrome, diaphyseal hyperostosis or sclerosis	Permanent activity of the transforming growth factor beta 1 causing increased bone density and reduced fat and muscle tissue [181–184]	TGFB1 [181–184]	Aut. dom. [181–184]	>300 cases are described worldwide [185]	Experimental approaches with TGF beta receptor antagonists [185]	Hyperostosis of the long bones, diffuse thickening of the skull base, ophthalmopathy, cephalgia, vasculopathy, pains, muscular weakness [181–184]	Craniofacial bone disease, progressive stenosis of the internal auditory canal [183, 186]
Chanarin-Dorman syndrome	Abhydrolase deficiency and lacking activation of fat triglyceride lipase [187]	ABHD5 [187]	Aut. rec.	More than 128 known cases	Symptom-based, fat-free diet	Congenital ichthyosiform erythroderma, hypothyroidism, neurological symptoms, liver function disorder, cataract, ectropion [187]	Neutral lipid storage disease with ichthyosis
Craniofacial dysplasia	Inhibition of the regulated bone remodeling by extracellular phosphate accumulation [188]	ANKH, GJA1	Aut. rec. or aut. dom.	Very rare	Symptom-based	Hypertelorism, dolichocephaly, proptosis, prominent mandible, thickening of the skull bone, retarded dentition [188–190]	
Familial hypophosphatemia	Phosphate loss due to increased secretion of the phosphaturic hormone fibroblast growth factor 23 [191]		X-chrom., more rarely aut. rec., aut. dom. [191–192]	3:100,000 for X-linked	Symptom-based, phosphate and vitamin D	Rickets, abnormal gait, deformity of the lower extremities, retarded growth, dental abscesses [191]	

Name	Cause	Gene	Inheritance	Incidence	Therapy	Symptoms	Annotations
Farber lipogranulomatosis	Lysosomal storage disease, acid ceramidase deficiency [193–194]	ASAH1 [193–194]	Aut. rec. [193–194]	201 cases were known in 2018	Symptom-based	Subcutaneous nodes, deformed joints, progressive hoarseness, special types of muscle atrophy and progressive myoclonal epilepsy [193–194]	
Fibrodysplasia ossificans progressive	Heterotopic ossifications [195–196]	ACVR1/ALK2 [195–196]	Aut. dom. [195–196]	1:2,000,000 [195–196]	Symptom-based [195–196]	Missing nails, progressive heterotopic ossification, hypoplasia of the brainstem, cognitive and motor developmental disorders	
Fibrous dysplasia (Jaffe-Lichtenstein syndrome)	Disorder of the osteogenesis due to overproduction of cAMP, phosphorylation CREB and activation of cAMP-dependent protein kinase (PKA) [135]	GNAS	Non-hereditary	Unknown	Bisphosphonates	Exchange of normal bone and bone marrow with fibrous connective tissue and immature trabecular bone [135]	Often conductive but sometimes also sensorineural hearing loss [135]
Kernicterus	Deposit of unconjugated bilirubin [135]		Sporadic	Often occurs in premature births		Hyperbilirubinemia [135]	Neural and central hearing loss [135]
Congenital disease of the glycosylation	Defect biosynthesis of glycans	Several genes [197]	Aut. rec., rarely x-linked	Less than 100 cases per type [198]	Symptom-based, mannose or D galactose supplementation [198]	Multisystem manifestation, neurological symptoms, mental disability, cardiomyopathy, edema, facial deformities [198]	More than 130 types are described [198], defect N, O, and combined N and O glycosylation as well as lipid glycosylation [199]
Leigh syndrome (infantile necrotizing encephalopathy)	Congenital lactate acidosis, pyruvate dehydrogenase deficiency	PDHA, pyruvate dehydrogenase (E1) a subunit [200–201]	X-linked [200–201]	1:40,000–70,000	High-dose thiamine substitution [200–201]	Peripheral neuropathies, chorea, Parkinson-like symptoms, cognitive deficits, necrotic lesions in the brain, hypertrophic cardiomyopathy [200–201]	
Mucopolysaccharidosis type I (formerly: Hurler or Scheie syndrome)	Lysosomal storage disease [202]	NEU1 [202]	Aut. rec. [202]	1:42,000,000 [202]		Ataxia, myoclonus, progressive visual loss [202]	
Mucopolysaccharidosis type II (Hunter)		IDS [203]	X-linked, recessive [203]	0.5–1:100,000 [203]	Symptom-based, enzyme substitution therapy	Coarse facial features, skeletal deformities and stiff joints, growth retardation with hyposomia, impairment of respiration and heart including diffuse valvulopathy, inguinal and umbilical hernia, hepatosplenomegaly, neurological involvement in at least two third of the cases, adeno-tonsillar hypertrophy, obstructive sleep apnea, retinal degeneration [203]	Lysosomal storage disease

► Table 1 Continued.

Name	Cause	Gene	Inheritance	Incidence	Therapy	Symptoms	Annotations
Niemann-Pick-C syndrome [204]	Lysosomal storage disease; disturbed cholesterol and fatty acid transport [204]	NPC 1; NPC 2 [204]	Aut. rec.	1:100,000–250,000 [204]		Progressive neurodegeneration, hepatomegaly [204]	Mild to high-grade hearing loss, also neuropathy
NGLY1 deficiency	Inability to remove N-glycan [205]	NGLY1 [205]	Aut. rec.	<63 patients worldwide	-	Neuropathy, corneal ulcerations, dystonia	
Oculo-auriculo-vertebral dysplasia (Goldenhar syndrome) [206]	Unknown	-	-	1:30,000–1:40,000 [206]		Unilateral malformation of cheekbones, jaw, mouth, ears, eyes, and/or vertebrae [206]	Part of Goldenhar syndrome, aural atresia, internal auditory canal may be malformed [206]
Primary distal renal tubular acidosis (distal RTA, type)	Proton pump subunit B1 is also expressed in the stria vascularis [207]; some patients also have an enlarged vestibular aqueduct	ATP6V1B1; ATP6V0A4 [207]	Aut. rec.	-	Correction of metabolic deficits [207]	Metabolic acidosis and osteomalacia [207]	Hearing loss is variable and is often not regressive under alkali therapy
Pompe disease (glycogenosis type 2)	Glycogen deposits in muscles [208]	GAA [208]	Aut. rec. [208]	1:40,000 [208]		Congenital or progressive muscular weakness, respiratory insufficiency [208]	Mild hearing loss, possible stapedius muscle weakness [208]
Reifsum disease	Failure of metabolism of phytanic acid [209–211]	PHXH; PEX7 [209–211]	Aut. rec.	1:1,000,000 [209–211]		Retinitis pigmentosa, ichthyosis, anosmia [209–211]	Onset of the symptoms at an age of 10–20 years; mild to high-grade hearing loss, also neuropathy [209–211], Bamiou et al.
Rogers syndrome; thiamin responsive megaloblastic anemia	Thiamin pyrophosphokinase deficiency [212, 213]; highly-affine thiamin transporter	SLC19A2 [212–213]	Aut. rec. [212–213]	Less than 80 cases are known [175]	Thiamin substitution [212–213]	Diabetes mellitus, megaloblastic anemia [212–213]	Thiamin pyrophosphokinase = highly affine thiamin transporter
Schindler syndrome	Lysosomal storage disease [214]	NAGA [214]	Aut. rec. [214]	<1:200,000 [214]		Progressive neurodegeneration with hypotonia and telangiectasias in the adult type [214]	
Keratoses and ichthyoses							
Autosomal recessive congenital ichthyosis	Non-syndromic keratin disorder due to mutation of genes that regulate the keratinocyte differentiation	Different, e.g., TGM1, ALOXE3, ALOXI2B, PNPLA1, and CERS2 [215]	Aut. rec.	1:100,000	Symptom-based	Heat intolerance, pruritus, growth disorders, visual disorders [215]	Different types, syndromic types are e.g., KID

► **Table 1** Continued.

Name	Cause	Gene	Inheritance	Incidence	Therapy	Symptoms	Annotations
De Sanctis-Cacchione syndrome	Xeroderma pigmentosum, severe DNA repair disorder (defective nucleotide excision repair)	XPA or ERCC2/XSD [216]	Aut. rec. [216–217]	About 200 cases are known	Symptom-based	Cutaneous photosensitivity, microcephaly, mental disability, hyposomia, hypogonadism, spasm, peripheral neuropathy [216–217]	
Harlequin ichthyosis	Hyperkeratosis with defective keratinocyte transmembranous lipid transporter protein and disorder of the lipid transport to the stratum corneum [218]	ABCA12 [218]	Aut. rec.	1:500,000 [218]	Symptom-based	Thickened yellowish skin with fissures, ectropium, eclabium, round open mouth, missing scalp hair as well as cilia and eyebrows [218]	Severest type of congenital ichthyosis
Keratosis-ichthyosis deafness syndrome (KID)	Connexin-26 disorder [219]	GJB2 [219]	Sporadic, also aut. dom. and rec. cases are known [219]	Less than 100 cases are known [219]		Erthrokeratodermic follicular hyperkeratosis, psoriasisiform or verrucous plaques, palmoplantar keratodermatosis, conjunctivitis, hypotrichosis [219]	Characteristic triad: ichthyosiform erthrodermatosis, high-grade sensorineural hearing loss, vascularizing keratitis [219]
Hereditary palmoplantar keratosis (PKK)	Connexin-26-related change of the Cx43 gap junctions (increased semicanal activity) [220]	GJB2 (Cx26-H73R, und Cx26-S183F) [220]	Aut. dom. or mitoch. [175]	Very rare, <1:1,000,000 [175]		Palmar and plantar hyperkeratosis [220]	
Trichothiodystrophy	Nucleotide excision repair	ERCC2, ERCC3, TTDA, TTDN1, GTF2E2	Aut. rec.	1:1,000,000		Dermal ichthyosis, mental and growth retardation, hypogonadism [221]	Variable manifestations, BIDS (brittle hair, impaired intelligence, decreased fertility, and short stature), IBIDS (with ichthyosis), PIBIDS (with photosensitivity), or Tay syndrome [221]
Syndromes							
Alström syndrome	Ciliopathy [222]	ALMS1 [222]	Aut rec. [222]	1–9:100,000 [222]	CI	Photoreceptor dystrophy, obesity, type-2 diabetes, hyperlipidemia, acanthosis nigricans, hypogonadism, renal, pulmonary, and hepatic dysfunction, dilatative cardiomyopathy [222]	
Arts syndrome	Deficiency of phosphoribosyl pyrophosphate synthetase 1 [223]	PRPS1 [223]	X-linked	Very rare		Ataxia, mental retardation, hypotension, optic atrophy, peripheral neuropathy [223]	
Barakat syndrome	Developmental disorder of the parathyroid, kidney, and inner ear [135]	GATA3 [224]	Aut. dom.	180 patients worldwide [224]	Symptom-based	Hypoparathyroidism, deafness, and kidney diseases; variably phenotypes are possible [224–225]	

▶ Table 1 Continued.

Name	Cause	Gene	Inheritance	Incidence	Therapy	Symptoms	Annotations
Bardet-Biedl syndrome	Cilipathy [135, 226]	21 different genes [226]	Aut. rec.	About 1:150,000 [227]	Symptom-based; experimental gene therapeutic approaches [228]	Obesity, pigmental retinopathy, kidney disease, anosmia, hypogonadism, situs inversus [226–228]	Incidence is higher in regions with frequent consanguinity [227]
Bartter and Gitelman syndrome	Channelopathy [229]	Several, e.g., KCNJ1, NKCC, NCCT, BSND, ROMK, IBS, CLCNKB, SLC12A1, SLC12A3 [229–230]	Aut. rec. [229]			Hypokaliemia, hypochloremic metabolic alkalosis, polyuria, polydipsia	Bartter type 1–4, Gitelman (SLC12A3) as mild, late onset type
Björnstad syndrome	Chaperonopathy, disorder of the ATPase and lack of mitochondrial complex III [231]	BCS1L [231]	Aut. rec. and aut. dom. [231]	Extremely rare [231]		Pili torti [231]	Disorder of the mitochondrial respirasome
Branchio-oculo-facial syndrome (BOFS)	Disorder of the retinoic acid-induced transcription factor AP-2 alpha and thus of the regulation of eye, face, skin, neural tube, and kidney morphogenesis [232]	TFAP2A [232–233]	Aut. dom. [232–233]	< 1:1,000,000 [175]	Symptom-based	Low birth weight and growth and growth retardation, branchial skin alterations (hemangioma-like manifestation at the neck and behind the ears), microphthalmia, ptosis, cataract, dacryocystitis, characteristic facial changes (wide philtrum, cleft lip and palate, flat broad nose, deformed auricles [232–233])	Hearing loss may be conductive, sensorineural or mixed; clinical overlapping with BOR syndrome [232–233]
Branchio-oto-renal syndrome (BOR)	Disorder of the renal formation and the otic placode [235, 236], mild cochlear hypoplasia, second most frequent malformation	EYA1 (40% of the patients with clinical symptoms), SIX1, SIX5 (genes of the EYA-DACH-SIX-PAX pathways) [234–236]	Aut. dom. [234, 236]	1:40,000 [234, 236]	Symptom-based	Cervical or preauricular branchial fistula, hypoplasia, dysplasia, or agenesis of the kidneys, aplasia of the 8th cranial nerve [234, 236]	Variable presentation and severity [235], radiologically cochlear hypoplasia [236]
Boudhina-Yedes-Khiari syndrome	Neuro-cutaneous disease [237]	-	Aut. rec. [237]	3 patients worldwide [237]	Symptom-based	Growth retardation, microcephaly, mental retardation, epilepsy and skin lesions [237]	
Carpenter syndrome, acrocephalopolysyndactyly type II	Mutation of the guanosin triphosphatase (GTPases) [238–240]	RAB23 [238–240]	Aut. rec. [238–240]	Extremely rare [175], about 40 cases are known	Symptom-based	Craniostenosis, craniofacial malformations, polysyndactyly, obesity, mental disability, hypogonadism [238–240]	RAB23 = Ras-associated binding protein 23; negative regulator of sonic hedgehog and fibroblast growth factor signalling pathway [238]

► **Table 1** Continued.

Name	Cause	Gene	Inheritance	Incidence	Therapy	Symptoms	Annotations
CHARGE syndrome, Hall-Hittner syndrome	Neurocristopathy, dysregulated gene expression and development of the neural crest, dysregulation of the neural crest stem cells, dysregulation of the alternative splicing (spliceosomopathy) [98, 241]	CHD7 heterozygotic mutation 8q12 [98] as well as newly identified genes: PUF60, EP300, RERE, KMT2D and KDM6A [241]	Aut. dom. (97% de novo) [98, 241]	0.1–1:10,000 [135]	Symptom-based, CI	Variable expression of the symptoms, visual loss, cardiac anomalies, skeletal, oronasal, gastrointestinal, and genitourinary malformations, growth disorders, craniofacial malformations, anosmia, facial nerve palsy, immune deficiency [241] Diagnostic criteria [98]: typical: 2 or 3 main and 2 minor criteria; main criteria: coloboma (ocular), choanal atresia/stenosis, hypo-/aplasia of the semicircular canals; minor criteria: rhomb encephalic dysfunction (brainstem and cranial nerve anomalies), hypothalamo-pituitary dysfunction, malformation of the internal and/or external auditory canal, mediastinal organs (heart, esophagus), intellectual weakness	CHARGE = Coloboma of the eye, Heart defects, Atresia of choanae, Retardation of growth, Genital abnormalities, Ear anomalies; overlapping with Kallmann, Kabuki, 22q11.2 and Nager syndromes as well as with Guion-Almeida mandibulo-facial dysostosis [241]; the missing of the semicircular canals is highly predictive for CHD7 mutation
Cockayne syndrome, Neill-Dingwall syndrome	Delayed DNA repair after UV light exposure, mitochondrial changes [242–243]	ERCC8, ERCC6 [242]	Aut. rec.	1:250,000 [242]	Symptom-based	Hyposomia, cerebral and retinal atrophy, joint contractures, photosensitivity and wrinkled skin, atherosclerosis and vasculopathy, high blood pressure, stroke and cardiac infarction, peripheral neuropathy [242]	3 types
Coffin-Lowry syndrome	Growth factor regulated serin-threonin-protein kinase [244–245]	RSK2; Locus Xp22.2 [244–245]	X-linked [244–245]	> 100 cases are known [244–245]	Symptom-based	Severe mental disability, hyposomia, hypertelorism, prominent front, anteverted nostrils, thick fingers with slim tips, kyphoscoliosis [244–245]	
Coffin-Siris syndrome	Mutations of the BRG-1 associated factor (BAF) complex, cell growth, division, replication, and differentiation as well as in DNA repair [246–247]	ARID1A, ARID1B, SMARCA4, SMARCB1, SMARCE1, SOX11 [246–247]	Aut. dom. and aut. rec. [246–247]	About 100 cases are known [246–247]	Symptom-based	Cognitive and developmental disorder, hypoplastic phalanxes and little finger nails, hirsutism, ptosis, cataract, strabism, hypospadias [246–247]	

▶ Table 1 Continued.

Name	Cause	Gene	Inheritance	Incidence	Therapy	Symptoms	Annotations
Cornelia-de-Lange syndrome	Cohesinopathy, disorder of the chromatid cohesion and thus mitosis, disorder of the regulation of the transcription [248–250]	SMC1A, SMC3, RAD21 or HDAC8 [248–250]	Aut. dom. or X-linked	More than 400 cases are known	Symptom-based	Facial dysmorphism (arched eyebrows with synophrys, long philtrum, thin lips, hairy front), prenatal and postnatal growth retardation, cognitive impairment, gastrointestinal malformations, congenital cardiac anomalies and malformed extremities [248–250]	
Curschmann-Batten-Steinert syndrome, myotonic dystrophy	Gene defect resulting in splicing defects of the pre-mRNAs of multiple genes	DMPK (type I), CNBP (type II); both loci adjacent to the DFNA18 locus [251–253]	Aut. dom.			Myotonia, muscular atrophy, insulin resistance, cardiac arrhythmia, cataract, cognition disorder and mental disability	Two types are known, also subclinically cochlear damage without hearing loss
Donnai-Barrow syndrome	Occulo-auditory syndrome [254–255]	LRP2 [254–255]	Aut. rec. [254–255]	< 50 patients worldwide [254–255]	Symptom-based	Diaphragmatic hernia, exophthalmos, missing corpus callosum, myopia, proteinuria [254–255]	
DOOR syndrome	Unknown	TBC1D24 [256], SMARCB1 [257]	Aut. rec. [256–257]	About 50 cases are known [257]	Symptom-based	Onychodystrophy, osteodystrophy, retardation, seizures [256–257]	DOOR = deafness, onychodystrophie, osteodystrophie, retardierung [256–257]
Ehlers-Danlos syndrome	Disorder of the collagen biosynthesis [258–259]	B4GALT7, B3GALT6, SLC39A13 and others [259]	Aut. rec.	1:5,000 [258]	Symptom-based	Skin and joint hyperlaxity, spondylodysplasia, kyphoscoliosis, aneurysms and ruptures of arteries, osteopenia/osteoporosis [258–259]	Different subtypes are known
Fountain syndrome	unknown	Unknown	Aut. rec.	Extremely rare	Symptom-based	Mental retardation, erythematous swelling of the face, skeletal changes [260]	
Freeman-Burian (Sheldon) syndrome	Distal arthrogryposis, multiple contractures [261]	MYH3 [261]	Sporadic, aut. dom. [261]	About 100 cases are known	Symptom-based	Microstomia, pursed lips just as for siffling, H- or V-shaped chin defect, prominent nasolabial fold and major contractures of 2 or more body regions, typically hands and feet [261]	Craniofacial syndrome
Hajdu-Cheney syndrome	Disorder of the intercellular notch signaling pathway [262]	NOTCH2 [262]	Aut. dom.	More than 80 cases are known [262]	Symptom-based	Craniofacial anomalies, cardiovascular disease, kidney cysts [262]	Craniofacial syndrome

► **Table 1** Continued.

Name	Cause	Gene	Inheritance	Incidence	Therapy	Symptoms	Annotations
HOXA1 syndrome	Developmental disorders of the head, the neural system, the inner ear, and the vestibular system [263]	HOXA1 [263]	Aut. rec. [263]	Extremely rare [263]		Bilateral duane syndrome, cerebrovascular and cardiovascular malformations, autism, variable phenotypes are possible [263]	Mixed hearing loss
Hutchinson-Gilford-Progeria syndrome	Reduced subcutaneous fat, aberrant lamin A production [264]	LMNA [264]	de novo, Aut. dom. [264]	1:4,000,000 [264]		Osteolysis, delayed eruption and loss of milk teeth, abnormal skin pigmentation, alopecia, osteoporosis, severe atherosclerosis, nightly lagophthalmos [264]	
Johanson-Blizzard syndrome	Defect of ubiquitin protein ligase E3 components N-rekognin1 (UBR1) and thus disturbed ubiquitination and degradation of ubiquitin-associated proteins, disorder of the cell proliferation, differentiation, and apoptosis [265]	UBR1 [265]	Aut. rec. [265]	Very rare, about 70 cases are known [265]		Exocrine pancreas insufficiency, hypoplasia of the nasal alae, oligodontia, skull defects, cognitive disorder, hyposomia, hypothyroidism, microcephaly, intrauterine growth disorder, congenital heart defect, urogenital and anorectal malformations kidney anomaly, late-onset diabetes mellitus [265]	
Juberg-Marsidi syndrome	Disorder of the E3 ubiquitin ligase regulating the key factors such as p53 and Mcl1 [266]	HUWE1 [266]	X-linked, rec. [266]	6 families are known [266]	Symptom-based	Mental retardation, growth disorder, hypogonadism, hypertelorism, microcephaly [266]	Hearing loss, possibly due to recurrent otitis media?
Kabuki syndrome	Disturbed histones-lysine methylation and chromatin remodeling [267]	KMT2D, sometimes also KDM6A [267]	X-linked [267]	1:32,000–86,000 [267]		Newborn hypotonia, nutritional problems in infants and toddlers, postnatal growth disorders, skeletal anomalies, disorders of the immune system, endocrine anomalies and congenital malformations of the heart, kidney, and palate [267]	
Kallmann syndrome	Defect development of gonadotropin-releasing hormone secreting neurons and absence of puberty [268]	SOX10, KAL1, FGFR1, FGF8, FGF17, CHD7 and others [268]	X-linked, aut. rec. or aut. dom.	Very rare	Hormone replacement therapy	Hypogonadotropic hypogonadism with anosmia, cleft lip and palate, renal agenesis, short metacarpal bones, synkinesis, movement disorders of the eyes, cerebellar ataxia, and scoliosis [268]	Incidence of the congenital hypogonadotropic hypogonadism syndrome: 1:50,000

► Table 1 Continued.

Name	Cause	Gene	Inheritance	Incidence	Therapy	Symptoms	Annotations
Kearns-Sayre syndrome	Mitochondriopathy, disorder of the oxidative phosphorylation [269]	Deletion of the mitochondrial DNA [269]	de novo, rarely X-linked [269]	1.6:100,000 [269]		Chronic progressive external ophthalmoplegia, retinopathy pigmentosa, disorders of stimuli conduction, endocrine involvement, weakness of non-ocular muscles, encephalopathy [269–270]	Characteristic triad: disease onset before the age of 20, chronic-progressive external ophthalmoplegia, retinopathy pigmentosa [269]
Klippel-Feil syndrome	Congenital synostosis [271]	Different, GDF6, GDF3, MEOS1	Sporadic, sometimes aut. rec. or aut. dom.	1:40,000 [271]		Congenital malformation of the spine, extraskeletal manifestation with urogenital and cardiovascular anomalies, neural tube defects and cleft palate [271–272]	
Kniest dysplasia	Type II collagenosis [273]	COL2A1 [273]	Aut. dom.	Rare, exact incidence is unknown [273]		Short torso and extremities, kyphoscoliosis and craniofacial anomalies [273]	
LADD syndrome		FGFR2, FGFR3, FGF10 [274]		Very rare, less than 30 cases are known [274]		Hypoplasia/aplasia of the lacrimal glands/duct, hypoplasia/aplasia of the salivary glands, dental anomalies, malformation of the ears and fingers [274]	
Landau-Kleffner syndrome	Acquired epileptiform aphasia [275]	Unclear, mutation of GRIN2A, RELN, BSN, EPHB2, and NID2 have been described [275]	No data in the literature [275]	About 1:1,000,000 [275]	Anticonvulsants, steroids, adrenocorticotropic hormone replacement diet, immunoglobulins [275]	Epileptic seizures, regression of speech, aggressive and hyperactive behavior [275]	Abnormal EEG, autism spectrum disorders
Noonan syndrome (formerly: LEOPARD syndrome)	RAS/MAPK disorders, developmental disorder of the neural crest due to mutations of the “non-receptor protein tyrosine phosphatase” SHP2 [276]	PTPN11, RAF, and BRAF [276]	Aut. dom.	About 200 cases are known [276]		Lentigines, abnormal ECG, ocular hypertelorism, pulmonary valve stenoses, micrognathia, growth retardation [276]	
Levy-Yeboa syndrome		KCNQ1 and KCNE3 [277]	Aut. rec.	1 family with 3 siblings has been described [277]		Congenital myopathy, recurrent secretory diarrhea, epidermolysis bullosa, microcephaly [277]	
Marshall syndrome	Disturbed ectodermal development [278]	Coll11A1 [278]	Aut. dom.	<1:1,000,000		Facial dysmorphism, hypoplasia of the nasal bone and frontal sinus, skeletal anomalies [278]	Progressive hearing loss

► **Table 1** Continued.

Name	Cause	Gene	Inheritance	Incidence	Therapy	Symptoms	Annotations
Maternally inherited Leigh Syndrome (MILS) and NARP syndrome	Mitochondrial disease [279]	MTATP6 [279]	Maternal [279]		1:12,000–1:40,000	Neuropathy, ataxia, retinitis pigmentosa [279]	MILS 90% Mt DNA mutated; NARP 70–80% Mt DNA mutated; Rawle et al.
Mayer-Rokitansky-Küster-Hauser syndrome	Inhibition malformation of Müller's ducts	-	-		1:4,000–1:5000 [280]	Ovarian and uterine agenesis, renal dysplasia [280]	
McCune-Albright syndrome	Overproduction of growth factors and hormones [281]	GNAS [281]	Mosaic [281]		1:100,000–1:1,000,000	Fibrous dysplasia, Café-au-lait stains, pituitary dysfunction [281]	
MELAS syndrome	Mitochondrial disease [282–283]	MT-TL1 and further mitochondrial DNA mutations [282–283]	Maternal			Myopathy, encephalopathy and stroke-like episodes, lactate acidosis [282–283]	Pathological changes in the stria vascularis, confirmed post mortem
MERRF	Mitochondrial disease [284]	MT-TK [284]	Maternal [284]			Myoclonus, epileptic seizures, ataxia, muscular weakness and dementia, hyposomia, degeneration of the optic nerve, peripheral neuropathy, cardiomyopathy [284]	
Moebius syndrome	Disorder of the brainstem development [285]	REV3L, PLXND1 [285]	De novo	1:250,000 [285]		Facial nerve palsy as well as paresis of other cranial nerves	Hearing loss in about 10% of the patients
Myhre syndrome	"gain of function" mutation, excessive TGF beta signaling [286]	SMAD4 [286]	Aut. dom. [286]	< 1:1,000,000		Microcephaly, midfacial hypoplasia, prognathia and blepharophimosis, hyposomia [286]	Enlarged vestibular aqueduct as most frequent radiological finding
Otosponylomegalopathy, epiphyseal dysplasia, OSMED syndrome	Collagen defect [287]	COL11A2 [287]	Aut. rec. [287]	< 1:1,000,000 [287]		Enlarged epiphyses, skeletal dysplasia with relatively short extremities, vertebral anomalies [287]	High-frequency hearing loss, Pierre Robin sequence
Pendred syndrome	Partial disorder of the pendrin, an anion exchanger	SLC26A4, FOX11, KCNJ10 [288]	Aut. rec. [288]	7:100,000 [288]		Anomalies of the temporal bone with dilated vestibular aqueduct and sometimes hypoplastic cochlea, vertigo, euthyroid goiter [288–289]	Also hypothyroid course
Pfeiffer syndrome	Prolonged FGF signaling [290]	FGFR1, FGFR2 [290]	Aut. dom. [290]	1:100,000 [290]		Craniostenoses [290]	Conductive hearing loss and sometimes also inner ear hearing loss
PIGA syndrome	Glycosyl phosphatidylinositol deficiency [291]	PIGA [291]	X-linked [291]	Rare [291]		Infantile spasms, epilepsy, mental retardation, cerebral lesions [291]	

▶ **Table 1** Continued.

Name	Cause	Gene	Inheritance	Incidence	Therapy	Symptoms	Annotations
Primary ciliary dyskinesia (Kartagener syndrome)		DNAH11, DNAH5, DNAH11, CCDC39, CCDC40 [292]	Aut. rec. [292]	1:16,000 [292]		Daily cough, chronic infection of the airways, situs inversus, asplenia, infertility [292]	Otitis media, inner ear hearing loss (30%)
Jervell-Lange-Nielsen syndrome	Ion channel mutation [293]	KCNE1 oder KCNQ1, SCN5A [293]	Aut. rec. or aut. dom.	1:2,000–1:44,500	Defibrillator, beta blocker, CI	Cardiac arrhythmia, prolonged QT interval [293]	
Rieger-Axenfeld syndrome	Irido-dental dysplasia [294]	FOXC1 8294]	Aut. dom.	1–9:1,000,000		Malformations of the face, teeth, umbilicum, and skeleton, congenital heart defect [294]	
Russel-Silver syndrome	Methylation disorder/imprinting disorder [295]	-	Aut. dom., Aut. rec. [295]	1:15,000 [295]		Developmental retardation, hyposomia, clinodactyly, hypoglycemia, scoliosis [295]	
Schinzler-Giedion syndrome	“Gain of function” mutation [296]	SETBP1 [296]	Aut. dom. [296]	<1:1,000,000 [296]		Facial dysmorphism, hydronephrosis, severe developmental delay, mental retardation as well as genital and cardiac anomalies, increased incidence of neuroepithelial dysplasia 8296]	
Senior Løken syndrome	Ciliopathy [297–298]	More than 10 genes [298]	Aut. rec. [297]	1:1,000,000 [297]	Symptom-based	Nephronophthisis, retinopathy, diabetes insipidus, cerebellar ataxia, hepatic fibrosis [297–298]	Synonym: EAST syndrome
SeSAME syndrome	Disturbed development of the brain, kidneys, and stria vascularis [299]	KCNJ10 [299]	Aut. rec. [299]	<1:100,000 [299]		Epilepsy, ataxia, and electrolyte disorder [299]	
Sotos syndrome	Mutation of the histone methyltransferase [300]	NSD1 [300]	Aut. dom. [300]	1:10,000 [300]		Long, narrow face, high front, red cheeks and small pointed chin, ADHD, hypotension, excessive growth [300]	Also conductive hearing loss [300]
STAR syndrome	Unknown [301]	FAM58A (CCNQ) [301]	X-linked [301]	Rare [301]		Telecanthus, syndactyly, renal and anogenital malformations [301]	
Tietz syndrome	Disturbed development of melanocytes [302]	MITF [302]	Aut. dom.	<50 patients worldwide	CI	Hypopigmentation and high-grade hearing loss [302]	Also in Waardenburg syndrome
Townes-Brocks syndrome	Malformation of the cilia [303]	SALL1 [303]	Aut. dom. [303]	-		Anal atresia, dysplastic ears and malformation of the thumbs [303]	

► **Table 1** Continued.

Name	Cause	Gene	Inheritance	Incidence	Therapy	Symptoms	Annotations
Usher syndrome	Degeneration of hair cells and photoreceptors [304]	Ush 1: MYOVI, CDH23, PCDH15, SANS Ush2: ADGRV1, WHRN Ush3: CLRN1 [288, 304]	Aut. rec. [304]	3:100,000 [304]	CI	Ush 1: congenital hearing and balance disorder, visual loss before puberty Ush 2: congenital hearing loss, visual loss after puberty Ush 3: progressive hearing loss, variable visual loss and balance disorder [288, 304]	10% of all hearing disorders in children
Vici syndrome	Global developmental disorder [305]	EPG5 [305]	Aut. rec. [305]	100 patients worldwide [305]	Symptom-based [305]	Agensis of the corpus callosum, cataract, oculocutaneous hypopigmentation, combined immune deficiency [305]	Disorder of autophagy
Waardenburg syndrome	Disturbed development of melanocytes	Pax 3 (type I, III) MITF, SNAI2 (type II) Sox10, EDN3, EDNRB (type IV) [288, 306]	Aut. dom. (I, III) Aut. rec. (II, IV)	1:40,000	CI [307]	Hypopigmentation and hearing loss (type II) + dystopia canthorum (type I) + malformations of the upper extremities (type III) + Hirschsprung's disease (type IV) [288, 306]	Asymmetric and variable hearing loss
Wolfram syndrome, DIDMOAD	Mitochondrial disorder due to disturbed calcium homeostasis and stress in the endoplasmatic reticulum [308–309]	WFS2, WFS2 [308–309]	Aut. rec. [308–309]	1:55,000 [308–309]	Insuline	Diabetes insipidus, diabetes mellitus, optic atrophy and deafness (DIDMOAD)	Progressive hearing loss as of childhood, neurological symptoms
Zellweger spectrum diseases	Peroxisomal functional loss [310]	Pex 1, 6, 10 [310]	Aut. rec. [310]	1:50,000 [310]	Bile acid [310]	Flat face, renal and hepatic insufficiency, retinitis pigmentosa [310]	Auditory neuropathy, infant-refsum disease
Neural/central							
Alternating hemiplegia of childhood (AHC), Weber syndrome, medial medullar syndrome	Channelopathy, alpha3 subunit of Na ⁺ /K ⁺ ATPase (exclusively expressed in neurons of the CNS)	ATP1A3	De novo mutations, rarely aut. dom.	1:1,000,000 [135]	Symptom-based	Episodes of weakness or paresis, choreoathetosis, dystonia, dyspnea, ataxia, dysfunction of the autonomous neural system, psychomotor regression, episodic nystagmus [135]	
Arnold-Chiari malformation	Syringomyelia, developmental disorder of the brainstem and the upper medulla [311]	Unknown	Unknown	Unknown	Symptom-based	Occipital cephalgia, diplopy, photophobia, spina bifida, meningocephaloceles, dysphagia, dysarthria, sleep apnea [311]	Type 0-VI

► Table 1 Continued.

Name	Cause	Gene	Inheritance	Incidence	Therapy	Symptoms	Annotations
Autosomal dominant hereditary ataxia	Spinocerebellar degeneration, different types are known [312]	Different genes	Aut. dom., X-linked	1–5:100,000	Symptom-based	Ataxia, disturbed hand-eye coordination, speech disorders, nystagmus, diplopia, cognitive impairment, optic atrophy, retinitis pigmentosa, ophthalmoplegia, diabetes, cardiac and skeletal diseases [312]	
Canavan-Van Bogaert-Bertrand	Leukodystrophia, asparto-acylase enzyme deficiency and accumulation of N-acetyl aspartate acid [313], diffuse spongiform of the white brain substance, dys- and demyelination [314]	ASPA [313–314]	Aut. rec. [313–314]	1:100,000, more frequently in Ashkenasim [175]	Symptom-based, experimental gene and cell therapy, experimental approaches tested in humans with lithium	Macrocephaly, muscular weakness, dysphagia, seizures, nasal regurgitation, optic atrophy, severe progressive psychomotor retardation	Auditory neuropathy [314], cases without auditory neuropathy and post mortem confirmation of hair cell loss [315], congenital, infantile, and juvenile types are described
CAPOS/CAOS	Channelopathy, alpha3 subunit of Na ⁺ /K ⁺ ATPase (exclusively expressed in neurons of the CNS)	ATP1A3 c.2452G>A [316]	De novo mutation and aut. dom. [316]	<1:1,000,000 [175], slightly more than 40 patients are described in the literature [317]	Symptom-based	Cerebellar ataxia, areflexia, pes cavus, optic atrophy [316, 318]	
Charco-Marie-Tooth neuropathy	CMT with hearing loss [319]	Different genes: ABDH12; AIFM1; DNMT1; PRPS1; PTRH2 [319]	Aut. rec., dom., X-linked [319]	1:3,300 [319]	Symptom-based [319]	Progressive neuropathy, muscular weakness, paralysis of the vocal folds, retinitis pigmentosa and cataracts, mental disability with dementia [319]	80 genes; classification according to the genotype; mild to severe hearing loss, “hidden hearing loss”
(Stilling-Türk-)Duane syndrome	Cranial dysinnervation [320–321]	CHN1, MAFB, HOXA1, CDH2 [320–321]	Aut. dom. and aut. rec. [320–321]	1:1,000 [320–321]	Symptom-based	Limited horizontal eye movement, abducens hypoplasia, skeletal, auricular, ocular, neural, and renal anomalies [320–321]	3 types are known, sometimes conductive hearing loss [321]
Hereditary sensory neuropathy	Axonal atrophy and degeneration of the sensory neurons, disturbed sphingo-lipid synthesis [322m 323]	SPTLC1 [322–323]	Aut. dom. [322–323]	2:1,000,000		Loss of distal sensorics, painless injuries, skin ulcer, bone infections, partly severe infections requiring amputations of toes or feet [322, 323], dementia	Extensive microglia activation that may also be classified as inflammatory or metabolic
Superficial siderosis	Hemosiderin deposit as consequence of recurrent bleeding in the subarachnoidal space	-	-	1:1,000,000 [324]	Deferiprone, CI [324]	Progressive bilateral hearing loss, ataxia, vestibular dysfunction, myelopathy with pyramidal signs [324]	

▶ Table 1 Continued.							
Name	Cause	Gene	Inheritance	Incidence	Therapy	Symptoms	Annotations
Others							
Cochlear dehiscence ("Third window" syndrome)	Dilated cochlear and vestibular aqueduct, bone dehiscence [325]				Surgery	Pseudo conductive hearing loss, vertigo (noise- or Valsalva-induced), autophonia [325]	
Intralabyrinthine schwannoma	Neoplasm			1:100,000 [326]	Surgery [327], CI [328]	Hearing loss, slowly progressive or fluctuating, vertigo, unsteady gait [327]	
Progressive myoclonal epilepsy	Group of disorders with common symptoms; comprises genetic diseases, mitochondrial diseases, and metabolic syndromes [329]				-	Myoclonus, epilepsy, neurodegeneration [329]	

diolus (Rosenthal's canal). They reach their postmitotic phase already in the cochlear duct in a baso-apical gradient, i. e., first the neurons of the basal and middle cochlear parts exit from the cell cycle, later the ones of the apical parts. The outgrowing dendrites arrange and retract in a way that the inner and outer sensory hair cells are innervated according to a certain pattern. This process seems to be regulated via the G protein RhoA-GTP and the rho-associated GTP binding proteins Rnd2 and Rnd3. It could be shown that ectopic sensory hair cells are able to form connections with spiral ganglion neurons [46] so that it may be expected that the sensory hair cells attract the dendrites of the neurons. This might be an explanation for the fact, why patients with severe malformations of the inner ear (e. g., incomplete partition) might nonetheless benefit from cochlea implantation.

Interestingly, the region developing into the organ of Corti expresses neurotropic factors before the differentiation of sensory hair cells so that developing neurites grow into the organ of Corti even if the formation of sensory hair cells does not occur [47]. However, if they reach the habenula perforata, they need a stimulus originating from the sensory hair cells so that they can continue to grow in direction of the greater epithelial ridge or the sensory hair cells [48]. These factors may be semaphorin/neurophilin1, Eph/ephrin as well as Slit/Robo. Their expression defines a path along which the dendrites may grow out [49]. Morphogens such as WNT and SHHs are expressed so that a dorso-ventral gradient is formed that is necessary for the development of the cochlea [24]. Furthermore, a significant role for direction-oriented outgrowth of the axons is attributed to WNT and SHH. In order to allow outgrowth of the neurites, WNT and SHH are required together with the growth factors FGF and BMP [48]. Type I and type II spiral ganglion neurons forward stimuli from the inner and outer sensory hair cells in a central direction. It is still unknown when this innervation pattern develops that is clearly seen in adults. However, this process seems to be closely related to the peripherin expression in type II spiral ganglia neurons [50]. Another protein, Prox 1 required for the coordination of the outgrowth of neurites of type II neurons is expressed in the spiral ganglion cells but possibly also in the supporting cells, along which the afferent fibers are expected to grow [51].

The expression of the neurotrophins BDNF and NT3 as well as their receptors NTRK2 and NTRK3 regulate the survival and the outgrowth of the developing spiral ganglion neurons. In the developing cochlea, a BDNF-NT3 gradient is formed from apical into basal direction [52]. If BDNF is deleted, a normal cochlea develops with a reduced neuronal population of about 7–15%. However, if NT3 is missing, the complete innervation of the basal cochlea is missing and is reduced in the middle turn [48]. Deletion of neurotrophin expression during development not only alters neuronal development but also results in a clearly shorter cochlear duct and disorganized rows of sensory hair cells similar to Neurod1 deficient mice [43].

1.5 Regenerative factors

Although the development of the inner ear is a highly complex process that may be influenced by multiple factors, a targeted modulation of single signaling pathways can be an approach for regenerative therapies. The REGAIN trial (**RE**generation of hair cells with a **G**amma secretase **IN**hibitor) aims at treating patients with mild to moderate hearing loss by inhibiting the notch-signaling pathway.

In this context, the notch inhibitor LY3056480 is used to stimulate the regeneration of sensory hair cells in the inner ear that are lost with increasing age [53]. Furthermore, the discovery of WNT-reactive progenitor cells in the murine cochlea being positive for LGR5 [54] has revealed that hair cell regeneration is fostered by blocking the notch signal [55] and is possible also in the adult cochlea of mammals [56]. In the context of human embryonic development of the inner ear, the expression of LGR5 increases from the 8th to 12th week of gestation [57]. During this time, also the development of the organ of Corti takes place. Interestingly, the LGR5 protein complex that was found in the apical poles of the sensory epithelium of the cochlea is limited to the sensory hair cells as of the 12th week of gestation [57]. Current studies show that in particular proteoglycans of the extracellular matrix contribute to the development of sensory hair cells and spiral ganglion neurons by up- or downregulating certain genes [58].

1.6 Embryonic development principles – correlation with other organ systems

For proper organogenesis, organ-specific genes are upregulated during embryonic development while genes that contribute to cell division and general morphogenesis are downregulated [59]. At later stages, genes that encode organ-specific functions are upregulated [59]. Multi-species and longitudinal gene expression analyses show a high overlap of the transcriptome over the entire embryonic development period and in particular of the brain, cerebellum, liver, kidney, testis, and ovaries [59].

Next generation sequencing analyses reveal that there are specific groups of genes responsible for organ development, for crosstalk and interaction between the organs (organ pattern genes) as well as house keeping genes that mainly coordinate metabolism [60]. The specific biological properties of these organ pattern genes may possibly give hints to new biomarkers or therapeutic targets for precise and effective prognosis and treatment of complex and in particular of rare diseases [60]. They might even explain how a gene defect leads to the involvement of different organ systems.

The principles of embryonic development of the cochlea and the auditory nerve show that the single developmental steps are complex and depend on multiple factors. This becomes obvious especially in the context of malformations, which, in contrast to initial assumptions, do not reflect the result of developmental arrest at certain stages. Different genes and gene families are responsible for the development of the inner ear and many of these regulate the organogenesis of other systems too. For example, forkhead box transcription factors play a role in the development of different organ systems by regulation and post-translational modification of different genes such as *Neurod* and *Sox2* [61]. *Sox2* as well as *BMP*, *WNT*, and *FGF* are involved in cardiogenesis [62], otogenesis [63], skeletogenesis [64] as well as retinal development [65]. Another group of evolutionarily conserved factors that are involved in the development of numerous organs (eyes, kidneys, heart, muscles, and inner ear) are the *Eya* (eyes absent) molecules [66]. In particular, the carboxyl domain is conserved in the *Eya* molecules that binds *Six* (*sine oculis*) proteins [66]. *Eya4* mutations are for example the cause for a rare autosomal-dominantly inherited hearing disorder that is sometimes associated with dilatative cardiomyopathy [66].

2 Non-syndromic Hearing Disorders

Non-syndromic hearing loss (NSHL) is inherited in an autosomal-recessive (about 80%) but also autosomal-dominant (about 15%), X-linked (2–5%) as well as maternal/mitochondrial (1%) fashion. Some but not all known mutations are listed in ► **Table 1**. Despite our understanding of these mutation and their inheritance patterns, a complete understanding of non-syndromic hearing disorders is a major challenge due to the extreme clinical and genetic heterogeneity [67].

Nearly 100 genes have already been identified that may lead to non-syndromic hearing disorders. A comprehensive overview of the genes that have been identified as of 2015 is found in the publication of Vona et al. [67]. A significant gain in knowledge about the function of the mature cochlea results from the study of genes that are mutated in cases of non-syndromic hearing disorders. The signaling pathways that are involved in rare as well as in non-syndromic diseases allow the identification of new pathophysiological processes that lead to hearing loss. Variations of the genotype-phenotype correlation are known in the context of mutations of single genes; and despite autosomal-dominant inheritance patterns, siblings may have hearing loss of various severities [67]. Such variations also became apparent in syndromic diseases. Sometimes entire organ systems are not affected (incomplete or reduced penetrance) even if the same gene mutation is found [68]. Secondary genetic factors or environmental factors might be responsible for the variations (epigenetics). Already in 1941, statistical methods were applied to prove the existence of modifier genes in Huntington's chorea so that the concept of dominant modifier and suppressor genes was made responsible for the high degree of variability [69]. In fact, 2 loci for modifier genes have been identified that might cause the variability of certain hearing disorders [67].

In spite of the variations (e. g., the onset of hearing loss may occur very variably even with the same gene mutation), autosomal-dominant hearing disorders often show a characteristic audio profile [70] that may be helpful for diagnosis. Despite the remarkable progress in the identification of a multitude of gene defects resulting in hearing loss, the mechanistic understanding in particular of non-syndromic hearing disorders does not suffice to allow clarification of the pathophysiology or the development of effective therapies.

The advent of modern molecular biological methods in combination with artificial intelligence and machine learning will bring about individualized precision healthcare for patients with hearing loss. In addition, preventive measures, e. g., control of structural, mutational, and epigenetic changes of the hearing disorder, are possible. This means that beside classic, meanwhile widely distributed and available omics technologies and imaging procedures for confirmation of the diagnosis, intensive diagnostics have to be developed to identify e. g., posttranslational changes, virus load or the inflammasome [71]. Screening technologies that include evaluation of protein-protein interactions [72] also integrate miRNA assessment in the perilymph [73] as well as analyses of model cells or patient cells [74] will allow real personalized medicine.

3 Malformations of the Cochlea

Before the era of CT imaging, reports about inner ear malformations were based on post-mortem examinations; and first pioneers such as Carlo Mondini (1729–1803) described changes like a missing apical turn and an enlarged vestibular aqueduct that is known as Mondini dysplasia [75]. Eugene Michel (1819–1883), the German otolaryngologist Arno Scheide (1864–1837), Gustav Alexander (1873–1932) as well as the Swiss neurologist Paul Robert Bing (1878–1956) lent their names for characteristic malformations of the inner ear [76]. In the context of post-mortem investigations, characteristic inner ear malformations of the bony (20%) and the membranous labyrinth (80%) have been assessed. In 1974, the American otologist Harold Frederick Schuknecht (1917–1996) published his standard reference work about ear pathologies by listing beside malformations all other diseases concerning the cochlea based on histological examinations of a large temporal bone collection.

Based on polytomography and sometimes CT scans, Jackler and his colleagues Luxford and House published the first classification of congenital malformations of the cochlea and the labyrinth [77] in 1987 that is still clinically used today.

Nearly 100 malformed inner ears were classified as follows:

1. Complete aplasia (Michel aplasia)
2. Common cavity
3. Cochlear aplasia with normally developed labyrinth
4. Cochlear hypoplasia
5. Incomplete partition (small cochlea with incomplete or missing interscalar septum; normal or malformed semicircular canals)

The hitherto revolutionary aspect of this classification was the concept of the embryonic developmental arrest to explain the different types of malformations [76]. However, the absence of inner ear development in different stages of embryonic development as pathomechanism of malformations can only explain some of the observed changes. Even Jackler already mentioned in his work that malformations indicate a disturbed rather than an absent development [77]. The malformations were listed according to the week of gestation when the embryonic development seemed to be disturbed. Jackler and his colleagues substantiated this assumption with the similarity of polytomographic findings and the (illustrated) developmental stages according to Streeter [78]. The series starts with the labyrinthine aplasia (Michel deformity, 3rd week of gestation), followed by the common cavity in the 4th week of gestation, cochlear aplasia in the 5th week of gestation, and severe and mild cochlear hypoplasia in the early and late 6th week of gestation. The incomplete partition, classic Mondini malformation, is the chronologically last malformation in the 7th week of gestation. The classification performed by Jackler et al. differentiates further a group A with missing or malformed cochlea (complete labyrinthine aplasia, cochlear aplasia, cochlear hypoplasia, incomplete partition, and common cavity) and a group B with normal cochlea (enlarged vestibular aqueduct, exactly defined dysplasia of the semicircular canals consisting of an enlarged vestibulum and a short but dilated lateral semicircular canal). Sennaroglu and colleagues enhanced the Jackler classification with regard to the surgical anatomy for cochlear implantation [79]. The incomplete partition type I (IPT1) describes a severe type with missing partitioning

of the entire cochlea with conspicuously enlarged vestibule and undetectable modiolus. The outer borders of the cochlea are coarse and often bloated. An accompanying malformation of the vestibule and the semicircular canals may be expected while an enlarged vestibular aqueduct is not found. Clear delimitation of the common cavity is not possible according to the used definitions. The wide transition from the cochlea to the vestibule characterizes also IPT1, which is reflected in the synonymous term of cystic cochleovestibular malformation [80–82]. The common cavity has been described as malformation with a common cavity of the cochlea and the vestibule that are connected via a wide transition. This definition that was originally coined by the histological report of Edward Cock from 1838 [83] is not sufficient for a clear delimitation against incomplete partition type I. The result is an unclear use in the literature. Similar to the enlarged vestibular aqueduct that may be found in numerous other malformations as accompanying symptom, the modiolus is regularly not defined by CT scan in its typical form in cases of X-linked deafness and IPT1. Today, the malformation originally described by Mondini is understood as the incomplete partition type 2.

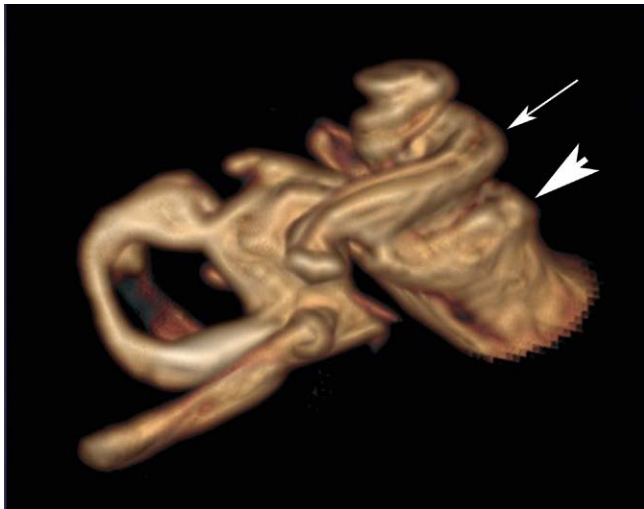
The aspect of the classification away from the developmental arrest theory to multifactorial genetic defects is illustrated in a review article about cochlear implantation in children with cochleovestibular malformations [84]. According to Papsin et al., the genetic coding of the murine otocyst (► **Figs. 2** and ► **3**) mostly excludes the hypothesis of developmental arrest of a single development pathway [84]. Instead, possible multiple distinct pathways of the inner ear development are described. The identification of the genetic signature of single malformations and the correlation with radiological findings crucially changes the understanding of the pathogenesis in this field.

3.1 X-linked deafness DFN3, Gusher-associated

The hearing loss defined as X-linked deafness shows a characteristic CT scan (incomplete partition type 3, IPT3) with a widely open connection between the cochlea and the internal auditory canal. The fundus of the internal auditory canal is dilated (► **Fig. 4**). The modiolus and the cribiform plate are missing so that a direct transition of the perilymph of the inner ear and the liquor in the subarachnoid space is found. Further characteristics are the corkscrew-like appearance of the cochlea, dilated nerve canals of the facial nerve and the posterior ampullary nerve from the inferior vestibular nerve (in the singular canal) as well as coarse protrusions at the vestibule. Also a small, mostly completely bone surrounded endolymphatic sac is observed.

Clinically, X-linked deafness presents as severe mixed conductive and sensorineural hearing loss in both ears. In 1971, Nance et al. described first a congenital fixation of the stapes footplate in X-chromosomal combined hearing loss and gusher [85]. The open connection to the cerebrospinal fluid leads to leakage during stapes mobilization, so-called gusher. Female carriers are described, however, only a low number of anatomical conspicuities are found in the CT scans and the hearing loss is clearly milder [86].

In some cases, the provision with hearing aids is sufficient, but often cochlear implantation is indicated. Surgically, the insertion of the electrode array is a particular challenge because it may easily reach into the internal auditory canal due to the open connec-



► **Fig. 4** Volume rendering from the T2 dataset of an MRI of a patient with X-linked deafness. A typical corkscrew-like picture of the cochlea (white arrow pointing to the basal turn). The fundus (arrowhead) of the internal auditory canal is dilated.

tion (► **Fig. 5**). Intraoperative cone beam computed tomography is a very useful tool in this context. Speech understanding after cochlear implantation is good and comparable to patients without inner ear malformation [87, 88].

In 1995, Kok et al. were the first to describe the location of the mutation on the gene *POU3F4* [89]. Since then, more than 63 causal mutations on the *POU3F4* gene (*DFNX2*) have been reported, among them 44 point mutations and various deletions [90]. *POU3F4* is expressed in the developing neural tube and later especially in the areas of the brain, supraoptically and paraventricularly in the hypothalamus nuclei. Already in 1982, Myhre et al. reported about a recessive X-linked disorder with congenital deafness and hypogonadism [91]. The patients of our own department have hamartomas of the hypothalamus in more than 90% of the cases that are characterized by hypogonadotrophic hypogonadism in contrast to the usual clinics in the context of hamartomas that are associated with laughing fits and precocious puberty [92]. Siddiqui et al. described hypothalamic malformations in patients with X-linked deafness and *IPT3* so that these may be classified as syndromic malformations [93].

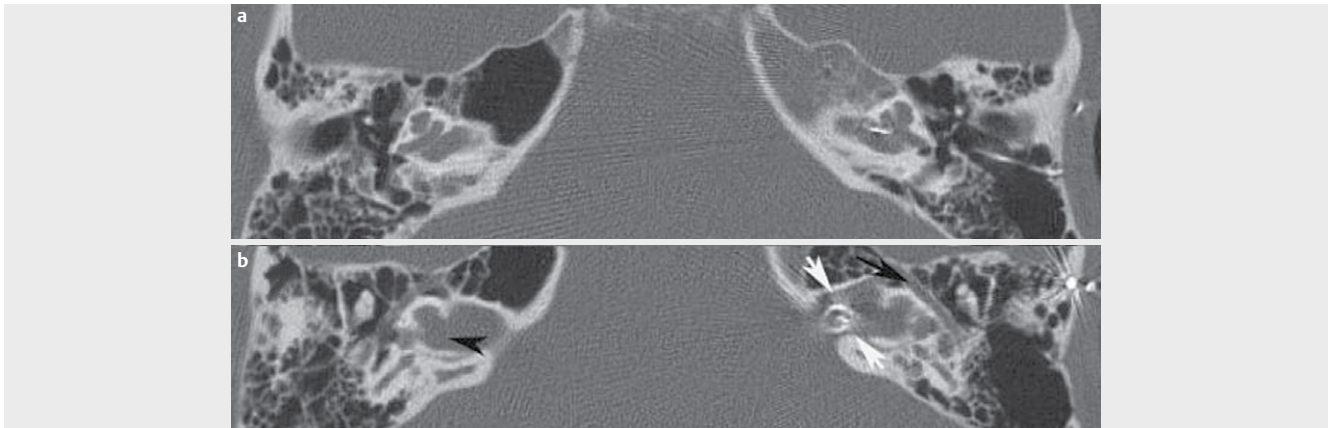
X-linked deafness with an identified gene defect in *POU3F4* is not the only hearing disorder associated with mutations identified on the X chromosome. Altogether, they make up about 1–2% of syndromic and non-syndromic hearing disorders. Up to now, 6 loci and 5 genes have been identified for non-syndromic hearing loss and at least 15 for syndromic hearing loss [94], among them Norrie syndrome, Cornelia-de-Lange syndrome, Fabry syndrome, Alport syndrome, *STAR* syndrome, *PIGA* syndrome, and X-linked adrenoleukodystrophy, just to mention a few syndromes that are all considered as rare diseases.

3.2 Complete aplasia of the semicircular canals and CHARGE syndrome

The complete aplasia of the semicircular canals is the main criterion of CHARGE syndrome, which may also occur as isolated symp-

tom. It has also been described in combination with Wildervanck, Noonan, Goldenhar, or VACTERL syndrome [95, 96]. The first description was made in 1979 independently by Hall and von Hittner so that the disease is known under the name of Hall-Hittner syndrome. The acronym CHARGE, however, was suggested by Pagon et al. in 1981 [97]: **C**oloboma, **H**eart defects, **ch**oanal **A**tresia, **R**etardation, **G**enitourinary and **E**ar abnormalities. The criteria applied today were suggested by Blake et al. in 1998 and revised by Verloes et al. in 2005 [98]. Verloes emphasized in particular the three Cs as main criteria: coloboma, choanal atresia, and hypo/aplasia of the semicircular canals. Depending on the number of the fulfilled criteria, the difference is made between typical, partial, and atypical CHARGE syndrome. However, only the presence of a few criteria is required for the diagnosis. The phenotypes in CHARGE syndrome are protean. Regarding the main criteria, ear malformation is observed in 95–100%, 90% occurring in the inner ear [99], followed by coloboma in 90% of the cases and neural malformations especially of the facial nerve in 50–90%, depending on the literature. The diagnosis of complete aplasia of the semicircular canals (SCC aplasia) is made based on imaging by means of computed tomography. Among the inner ear malformations, it represents a particularity because the phylogenetically older part of the labyrinth is missing. Accordingly, severe genetic alterations are present that become obvious due to the described multitude of associated malformations of the eye, midline structures of the facial skull, mediastinal malformations (cardiac and esophageal ones, possible thymus aplasia), and malformations of the efferent urinary pathways and genitals that all belong to different non-adjacent embryonic territories. CT scan and MRI of the temporal bone is the imaging technique of choice for existing hearing disorders in order to exclude possible inner ear malformations. CT scan of the temporal bone reveals the complete aplasia of the semicircular canals including the utricle (► **Fig. 6**). The visible vestibule is small, mostly comma-shaped, and contains only the saccule belonging to the inferior part (► **Fig. 7**). The cochlear mostly has a reduced number of turns (hypoplasia). Missing separation of the scalae may be an accompanying finding. In frequent neural hypo- or aplasias, also the internal auditory canal is narrow. In MRI, the depiction of the nerves is performed by means of high-resolution T2 sequence. The facial nerve and the vestibulocochlear nerve may be completely missing (4% of the cases); however, mostly a facial nerve is found and the hypo- and aplasia concerns more frequently a part of the vestibular nerve than of the cochlear nerve. Another accompanying malformation in the area of the temporal bone is a persisting petrosquamous sinus in up to 80% of the cases. It is a surgical challenge in the context of cochlear implantation like a missing oval or round window and a small middle ear. An aberrant course of the facial nerve in the middle ear can also be observed. In rare cases, the petrosquamous sinus may perform the venous drainage of the intracranial space from the transverse sinus. Furthermore, in a small percentage the venous exit occurs via the postglenoid foramen dorsal of the temporomandibular joint. In these cases, only a very small jugular foramen is found.

In some cases, also coloboma of the eye is directly seen in the imaging. It is another of the three Cs, the main criteria according to Verloes of 2005. Coloboma is a congenital cleft of the iris, lens, and ocular fundus. In the last mentioned case, it can be made visi-



► **Fig. 5** Patient with X-linked deafness. Axial CT scan of the temporal bone in two levels **a** A widely open connection between the internal auditory canal and the basal turn is revealed as well as a missing modiolus and missing lamina cribrosa (black arrow). **b** On the left side, the broad canal of the facial nerve is well displayed (black arrowhead). After cochlea implantation, malposition of the left-sided inserted CI electrode array in the internal auditory canal (white arrows) is observed.

ble in tomography as protrusion of the ocular bulb around or beside the optic nerve (► **Fig. 8**). Accompanying microphthalmia may be observed. The third C can also be diagnosed through CT scanning: choanal atresia, which may be present unilaterally or bilaterally as well as bony or only as fibrous closure. However, especially in cases of bilateral appearance it becomes obvious already at birth and has been treated at the time of assessing the appropriateness for cochlear implantation.

Data on the incidence of accompanying hearing disorder in CHARGE vary between 50% for severe hearing disorder and 90% for deafness. In our own patient population with exclusively patients with complete aplasia of the semicircular canals, nearly all cases have severe hearing loss or deafness. If the cochlear nerve is present, cochlear implantation is the therapy of choice. Implantation may represent a particular challenge because the accompanying malformations complicate the access to the cochlea. Therefore, careful assessment of the CT scan should be performed in order to identify the optimal access. Speech understanding after CI has a broad spectrum depending on the abilities of the patients with possible simultaneous retardation, blindness and other disabilities. Overall, a benefit is reported, independently from the severity of CHARGE. About half of the implanted children use speech as communication way one year after implantation [97].

The genetic cause of CHARGE syndrome is a mutation of the CHD7 that leads to functional loss. Patients who meet the diagnostic criteria of CHARGE syndrome have a mutation in up to 95%. Most mutations are singular and equally distributed over the coding region of CHD7. More than 500 different pathological changes have been described up to now. 75% of them are frameshift or nonsense mutations. Nearly all mutations develop de novo; but also familial accumulation has been described. In such CHARGE families, a broad spectrum of clinical manifestations is observed with parents suffering from very mild symptoms that barely meet the criteria up to the full spectrum in the children.

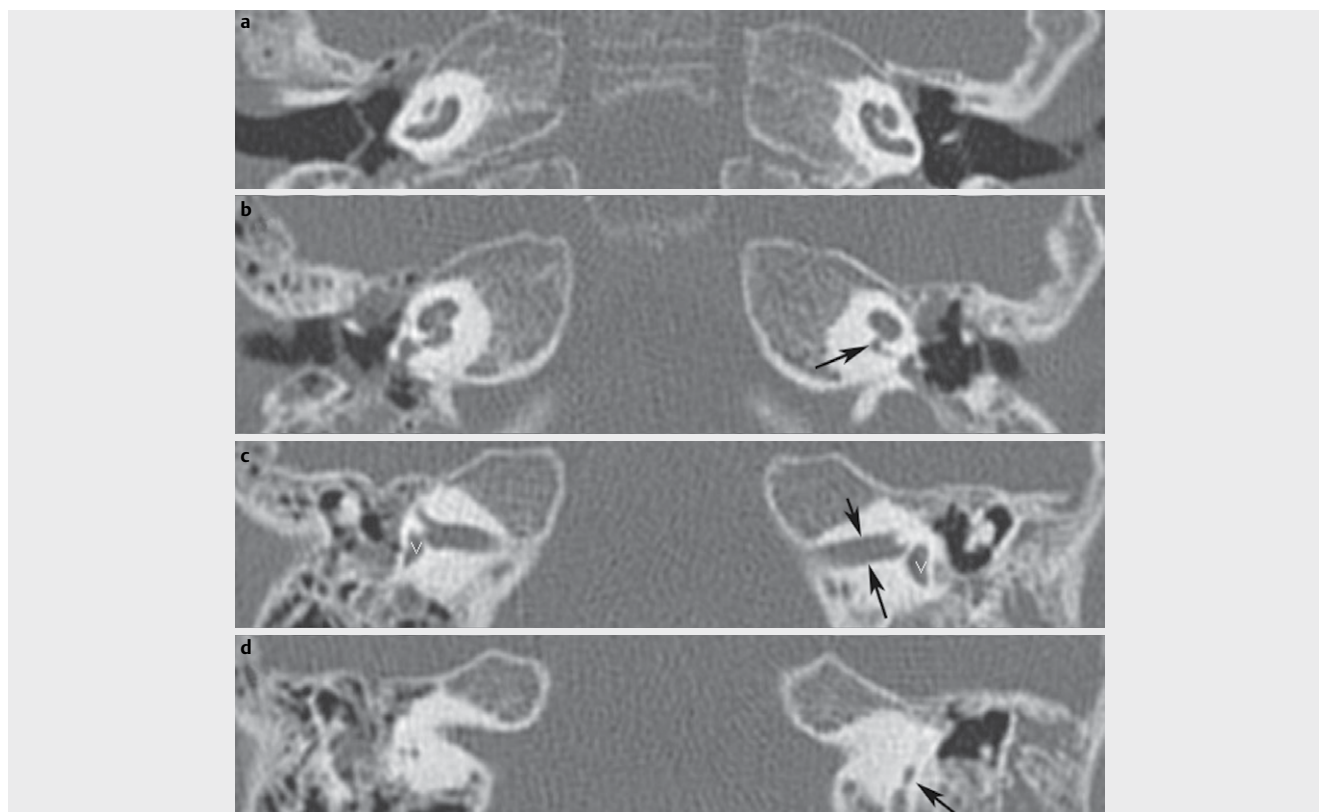
Regarding the manifestation of CHARGE syndrome, overlapping with Kallmann syndrome is found as well as 22q11.2 deletion. Anomalies of the olfactory nerve are found in Kallmann as well as in

CHARGE syndromes. Immune defects are frequent in 22q11.2 deletion, but they may also appear in CHARGE. As in 22q11.2 deletion, thymus aplasia may be observed. In cases of middle ear infections a thymus aplasia must be taken into consideration in children with CHARGE because middle ear infections are not always due only to anatomical circumstances.

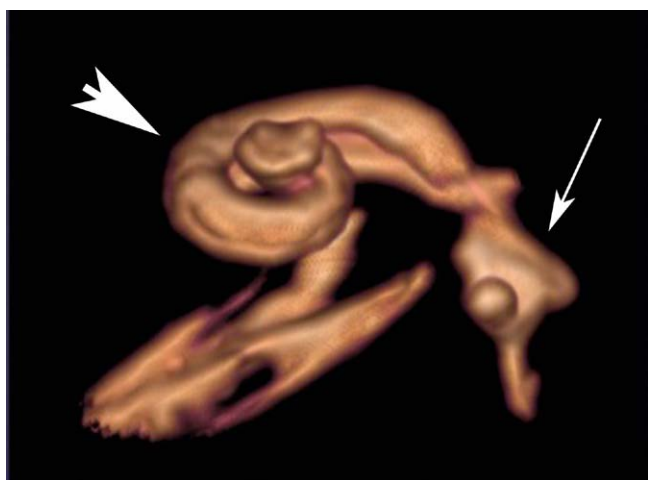
3.3 Cochlear implantation in cases of cochlear malformations

Hearing rehabilitation has a high success rate not only in patients with normally developed anatomical labyrinth displayed in CT scans but also in patients having a bone malformation revealed in the context of cochlea implant examination (about 20%) [100]. The care for these patients represents a particular challenge. Complications e. g., caused by an aberrant course of the facial nerve or the increased risk of meningitis may occur very frequently when anomalies of the cochlea are found [79, 84, 101–103]. Hence, an intensive evaluation of every cochlear implant candidate is crucial, in particular of children, in experienced centres. A series of different descriptions of inner ear malformations is found in the literature and the same term may be interpreted in quite various ways, depending on the author. Already in the 1990ies, Lenarz and colleagues and Sennaroglu et al. in 2017 requested a standardized description of malformations [79, 103] in order not only to allow comparisons and knowledge exchange, but especially to establish guidelines for patient care.

A standardization taking into account the anatomy was pursued by Jackler in the 20th century and by Sennaroglu in 2002 as well as numerous other authors. Not only the entire spectrum of malformations was described in this context but also single and partly rare subgroups. The complete partitions 1 and 2 were completed by atypical cases, e.g., IPT2 (former Mondini in the classic sense) without enlarged vestibular aqueduct [104]; or IPT1 that has exactly this enlargement [104]. The course of the facial nerve in the temporal bone has been investigated in detail [105]. Cochlear hypoplasia was classified more specifically [106–108]. All this reflects the enormous possibilities to combine genetic factors in order to



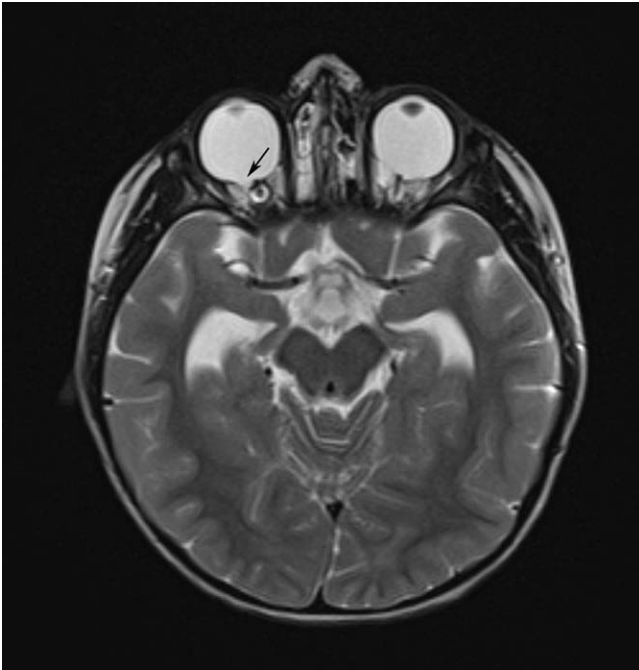
► **Fig. 6** Complete aplasia of the semicircular canals. Axial CT scan of the temporal bone with complete aplasia of the semicircular canals. **a** Bilateral hypoplastic cochlea. **b** On the right, a normal width of the cochlear aperture is found, on the left, the aperture is severely narrowed (arrow) – hypo- or aplasia of the cochlear nerve can already be assumed but MRI has to provide the evidence. **c** Narrow internal auditory canals (black arrows) are typical such as the bilateral comma-shaped vestibule (white V). **d** The semicircular canals cannot be displayed, the vestibular aqueduct (arrow) is the only narrow structure.



► **Fig. 7** Aplasia of the semicircular canals. Volume rendering from the T2 dataset of MRI of a patient with complete aplasia of the semicircular canals and CHARGE syndrome. The cochlea (arrowhead) is hypoplastic and the vestibule (arrow) contains only the sacculle. The semicircular canals are not developed.

provide this highly complex spectrum of different malformations. However, several malformations occur more frequently than others and they are worth being accurately classified.

Taking the example of the term common cavity, it becomes clear how differently the term is used and how incompletely the development of inner ear malformations is understood despite advances in genetics and imaging. In the literature, the term of “common cavity” is used for different types of malformations, at least three fundamentally different groups are included: 1) With the term of common cavity, Jackler described an otocyst that still bears the predisposition of the cochlea, the vestibule, and the semicircular canals, i. e., a malformation at a very early developmental level. 2) Other publications use the term in the sense that the cochlea and the vestibule, both coarsely developed, are non-partitioned and dilated and form a common cavity, i. e., a broad transition is found between both. At the fundus of the internal auditory canal, the cochlear and the vestibular nerve can generally not be differentiated. In the American literature, sometimes the term of cystic cochleovestibular anomaly (► **Fig. 8** deformity) is applied [109]. At the same time, the malformation has no clear delimitation criteria with regard to incomplete partition 1, where also the cochlea is dilated and non-partitioned and the vestibule is severely stumpy. An arbitrary definition could possibly be the width of the transition, which has no functional consequences for cochlea implantation. 3) Sen-



► **Fig. 8** T2 weighted axial MRI of a child with CHARGE syndrome in the context of preliminary cochlea implant examination. Coloboma is found at the right (black arrow) and left eye.

naroglu indicates that cochlear aplasia cannot always be delimited of common cavity in all cases [79]. He describes an oval malformation that is located mainly dorsal to the internal auditory canal and definitely has neural connections (in contrast to the otocyst deformities described by Jackler that does not need them). Both, cochlear aplasia as well as common cavity may have rudimentary or partly well-developed semicircular canals. Thus, the common cavity cannot be differentiated from cochlear aplasia in CT scans. Only the criterion of sclerotic areas ventral/inferior to the internal auditory canal that often exists in cases of cochlear aplasia is not applied for differentiation (► **Fig. 9**). However, based on own observations, this sclerotic area is present in nearly all cochlear aplasias. This overlapping makes differentiation rather difficult; decisions for cochlear implantation should be made based on the evidence by MRI of the internal auditory canal and the nerves. This example shows how important tomography with multiple levels of the labyrinth are to assess the respective malformations. If only one layer is shown, as it is often found in publications, the criteria that are necessary for evaluating a malformation cannot always be understood. With regard to the individual assessment and therapy, 3-dimensional reconstruction and the individual adaptation of the electrode that is possible in this way represents a logical consequence [106].

Publications are available that report about speech understanding after cochlear implantation in cases of cochlear aplasia [100]. Those cochlear aplasias are called common cavity by other authors. The presence of a spiral ganglion that can be stimulated cannot be assessed in CT scans. A combination of CT morphology and neural predisposition as it appears in MRI is more suitable to predict the possible benefit of cochlear implantation. These techniques are ap-

plied since long time in cochlear implant candidacy evaluation. Giesemann et al. have established the classification based on the severity of associated neural malformations in 2012 [110]. It becomes clear that severe malformations regularly have an entire spectrum of different nerve aplasias with certain probabilities. The resolution limit of MRI is crucial and further procedures such as the promontory test and BERA should be applied as well. It is still one of the open questions in the field of healthcare regarding malformations, up to which level hypoplasia of the cochlear nerve may lead to successful implantations.

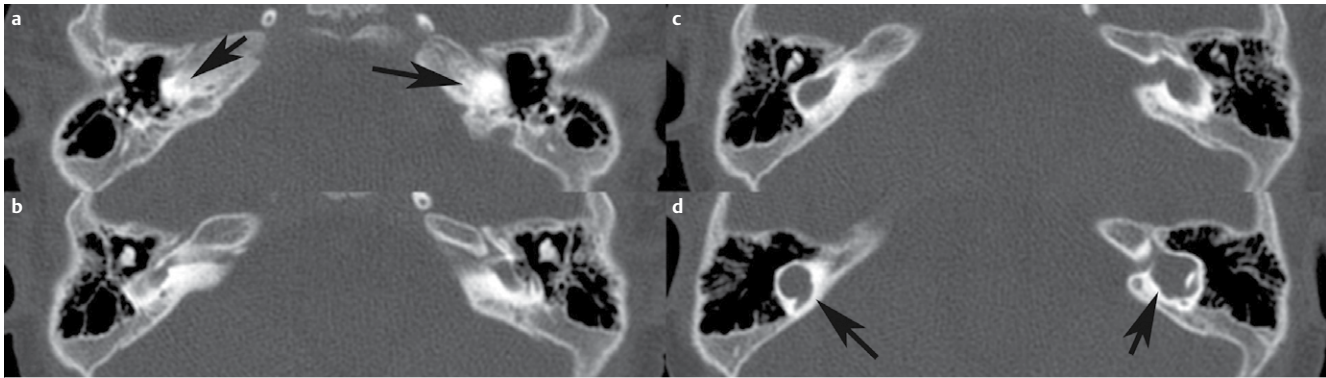
The Table summarizes examples of a classification that includes the clinically most important malformations that may be well differentiated by imaging morphology in relation to the presence of a cochlear nerve [110].

4 Susac's Syndrome

Susac's syndrome defines an autoimmune microangiopathic endotheliopathy that leads to closure of the precapillary arterioles of the brain, the retina, and the inner ear [111]. The neuroophthalmologist John O. Susac (1940–2012) lent his name for this disease. A systematic review article from 2013 summarizes the data of all cases of this rare disease that had been described until then [111] and defines criteria based on which this disease may be diagnosed that is characterized by multifaceted phenotypes [112]. The majority (nearly 80%) of the patients are females. Since autoimmune diseases are observed more frequently in women, this fact supports the possible autoimmune origin of Susac's syndrome [111]. Even if the characteristics of the disease are clearly defined, the diagnosis is often difficult and is associated with a long way for the patients. Severe neuropsychological deficits, visual field failures, and hearing loss but also unspecific symptoms like cephalgia may occur.

The majority of these patients initially develop neurological symptoms so that the disease is often misdiagnosed as multiple sclerosis. Within 2 years, about 85% of the patients develop the characteristic triad [111]. Also, non-classic symptoms have been described in patients with Susac's syndrome. A recently published paper that retrospectively investigated the hearing loss of the well-known painter Francisco Goya (1746–1828) with the background of current knowledge assumes an uncharacteristic manifestation of Susac's syndrome even if the painter fortunately had no significant disorder of his visual field [113]. An otologic manifestation of syphilis, other vasculitis diseases such as Churg-Strauss or autoimmune diseases like Cogan syndrome may cause symptoms that are similar to Susac's syndrome. One characteristic of the disease is the hearing loss of low frequencies, initially unilateral and reversible, later also bilateral and persistent [111, 114]. In rare cases, the hearing loss manifests as the first symptom, even years before the disease is diagnosed [115]. Fluorescence angiography and tone audiometry should be applied as early as possible in order to confirm the suspected diagnosis [111]. Multiple disseminated lesions, in particular snowball-like changes in the area of the corpus callosum and a leptomeningeal enhancement are characteristic cranial changes in MRI [116]. An early and aggressive treatment in particular in cases of neurological manifestation leads to a favorable prognosis.

An interdisciplinary approach and close communication between neurologists, ophthalmologists, neuroradiologists, and oto-



► **Fig. 9** Patient with cochlear aplasia. **a** The black arrows show the sclerotic area of the otic capsule where normally the cochlea is found. **b** and **c** show further dorsally located areas that comprise the dysplastic vestibule that is marked in **d** with black arrows on both sides.

laryngologists is vital and accelerates the confirmed diagnosis. The low frequency hearing loss, as it can appear as initial sign of Susac's syndrome, may also suggest Menière's disease, low frequency type of sudden sensorineural hearing loss, or intra-cochlear schwannoma [117]. With a prevalence of about 0.2%, also Menière's disease is considered as rare disease of the inner ear and is often assumed in patients presenting with low frequency hearing loss and vertigo. The symptoms of vertigo alone or in combination with low frequency hearing loss, however, may also occur in patients with Susac's syndrome. Therefore it is possible that Susac's syndrome remains unidentified and the patients are treated for Menière's disease with steroids. Patients who are initially diagnosed with low frequency type of sudden hearing loss may suffer from Susac's syndrome. With this background, an ophthalmological and neurological consultation of all patients with assumed sudden hearing loss or Menière's disease seems to be reasonable.

The pathophysiology of Susac's syndrome is caused by an occlusion of the lumen of minor vessels [114]. It is hypothesized that the underlying cause is binding by antibodies against vascular endothelial cells or T cell mediated swelling of vascular endothelial cells. Furthermore, MRI studies have revealed a disturbed microvascular blood-brain barrier in Susac's syndrome that was caused by inflammatory changes of the vascular wall [118].

5 Hearing Loss and Microcirculation

Normal inner ear function is predicated on a perfectly functioning microcirculation of the vessels of the labyrinthine artery that enters the organ via the internal auditory canal. The presence of a disturbed microcirculation in the inner ear is suspected in several diseases. The inner ear supply is based on an end artery, i. e. there are no anastomoses with other vessels that could take over the organ supply in cases of occlusion. The labyrinthine artery originates from the anterior inferior cerebellar artery and divides into 3 main branches in the inner ear: the anterior vestibular artery, the vestibulo-cochlear artery, and the cochlear artery [119]. A disorder of the microvascular blood-labyrinth barrier is also assumed in Menière's disease, based on an increased gadolinium uptake in affected inner ears in MRI trials [120]. Disturbance of the blood-labyrinth barrier is assumed to be more severe in sudden sensorineural hearing loss

[120]. Post mortem analyses of patients who had suffered from Menière's disease reveal an increased expression of inducible nitrogen monoxide synthase, damage of the vascular endothelial cells, degeneration of the perivascular basal membrane and extracellular matrix, and loss of the blood-labyrinth barrier. These changes are consistent with increased oxidative stress [120]. Even more interestingly, similar molecular processes (release of pro-inflammatory cytokines and endothelial and mitochondrial dysregulation as well as oxidative stress) have been identified as basic and common sign of multiple organ failure [121] so that these processes must rather be considered as the result of a series of insults and damages and not as causes. At the molecular level, patients suffering from Menière's disease reveal an upregulation of cochlin as well as downregulation of collagen IV and laminin-beta [122]. To date, post-mortem investigations of patients having suffering from Susac's syndrome, have not confirmed these findings. The classic vertigo attacks that are reported by patients with Menière's disease are not observed in Susac's syndrome. Nonetheless, from an otolaryngological point of view, acute or fluctuating, or (intermittently) progressive sensorineural hearing loss restricted to the apical cochlear region based on an endolymphatic cochlear hydrops is one of the most important differential diagnoses of Susac's syndrome besides Cogan syndrome.

To discover molecular markers in the blood or other body fluids for certain inner ear diseases, such as cochlin in Menière's disease, might be one of the ways to lead us into modern oto-rhino-laryngology. Initial approaches of perilymph analyses in patients performed during surgical inner ear interventions have allowed the identification of numerous proteins that could not be detected in the liquor or plasma [123]. Furthermore, inflammatory marker proteins were identified in human perilymph [71] so that establishing an inflammasome profile of the perilymph may give hints about the pathomechanisms of certain diseases. In particular, it may be a valuable method to characterize rare inner ear diseases. Even if the perilymph collection during cochlea implantation does not influence the residual hearing of the patients [123], i. e. possible additional damage of the inner ear seems to be very improbable, perilymph collection as minimally invasive intervention under local anesthesia in cases of significant residual hearing has not been proposed until now. The characterization of the perilymph of a

“normal” cochlea is rather difficult because up to now only examinations have been performed in patients who suffered from other diseases of the neural system, e. g., meningiomas [124].

Another development in the era of Big Data, artificial intelligence, and machine learning is the availability of databases ideally providing the complete data worldwide in specific consortiums of patients who suffer from a certain (rare) disease. Even as contact points for patients to retrieve information about competence centers and support groups, disease-specific consortiums are highly valuable especially in cases of rare diseases. With regard to Susac’s syndrome, such activities are coordinated via the European Susac Consortium (EuSaC; <http://www.eusac.net>).

6 Rare Diseases of the Cochlea: Outlook and Conclusion

The inner ear is anatomically and histologically a highly complex organ consisting of different tissue types. Developmental disorders and pathophysiological processes occurring during life may affect all tissue types of the inner ear and lead to hearing loss. Even if hearing loss is the most frequently observed degenerative sensorineural disease from a statistical point of view with 16 % of affected Europeans, hearing loss is also an important component of many rare diseases. In particular in pediatric patients, these diseases may be overlooked. Even if the diagnostics of many rare diseases is nowadays facilitated by accessing bioinformatics databases and analysis software, an interdisciplinary examination (e. g., neurology, cardiology, nephrology, rheumatology, ophthalmology as well as otolaryngology) is obligatory because of the highly variable phenotypes.

Due to their rare occurrence, rare diseases are often neglected in teaching and education of young physicians because the probability to encounter such cases in daily routine is rather low. However, if a combination of disorders (e. g., eye-inner ear, musculoskeletal system-inner ear, heart-kidney-inner ear, inner ear-thyroid, inner ear-gonads) is observed, it becomes clear that they may in fact occur more frequently. However, it also becomes clear how valuable the clinical discussion of the rare disease of an organ system is beside the embryonic development in order to understand the organ with its structure, its functions, and its diseases.

The human genome project and the high throughput sequencing methods that are now available as well as analyses of the proteome, transcriptome, epigenome, metabolome as well as microbiome offer the chance already today to sharpen disease profiles. Different disorders having similar symptoms (phenotypes) may be different on a molecular level and have to be treated in different ways (e. g., mitochondrial disease versus lysosomal storage diseases). It is well understood that genes controlling several signals and chromosomal anomalies that lead to the simultaneous loss of several genes cause broad-spectrum effects and severe manifestations. For example, the original classification system of the Charcot-Marie-Tooth syndrome reveals how clinical thinking about rare diseases changed during the last years. Initially based on phenotypes, the classification system was completed on the basis of progression and physiological measurements until finally the current

classification based on the genotype (currently more than 80 genes) was established. Even if it could be shown that disease-specific genes generally tend to be expressed in a limited number of tissues, it is still unclear how tissue-specific expression patterns of disease genes correlate with their pathological manifestations. Proteome analyses reveal that most gene products assume their function often in combination as complexes of several different proteins [125]. This might explain why mutations of different proteins lead to a similar phenotype. Recent approaches show that a tissue-specific overexpression of genes in the medulla, the dorsal ganglion, and the skeletal muscles coding certain protein complexes correlate with the pathological manifestation of Charcot-Marie-Tooth syndrome [125]. The cellular components that are affected are the telomere regions of the chromosomes; and the biological processes that are disturbed belong to the mechanosensory system [125]. Those classification systems also mean that several biological processes that were unknown may lead to hearing loss: basal membrane/collagen defects, overexpression of growth factors (e. g., TGF beta/interleukins) as well as disorders of the melanocytes, autophagy, and methylation. How this additional knowledge may be used in order to establish new treatment methods especially for patients who suffer from rare diseases, will have to be investigated in future trials.

The example of Susac’s syndrome shows that not only other inner ear diseases have to be considered in the differential diagnosis, but also ophthalmological or neurological diseases. It is important to think of an (possibly initial) audiological manifestation of a rare disease if sensorineural hearing loss has an unknown origin. Interdisciplinary diagnostic assessment may be helpful to detect occult symptoms and to early find a correct diagnosis. How hearing loss may already be diagnosed in these cases before it manifests, will be a prognostically relevant question. Patients with subjectively undisturbed hearing at rest may have difficulties in understanding speech in noise (also known as synaptopathy or hidden hearing loss, which may be present as early symptom of progressive neurodegeneration). Often this disorder remains undetected because the patients are not aware of it; and with routinely applied procedures, it cannot be identified. Targeted testing of speech understanding in noise can lead to a correct indication. This would allow an early introduction of therapy in diseases such as Susac’s syndrome. The identification of patients suffering from hidden hearing loss [126] is finally also relevant because currently 3 clinical trials investigate new therapies for treatment with promising results.

Numerous molecular and cell physiological processes are the basis for hearing loss especially in the context of rare diseases. The future of (also merely symptomatic) treatment of inner ear diseases, that are often rare diseases, may benefit from the early identification of molecular disorders.

Conflict of Interest

The authors declare that they have no conflict of interest.

References

- [1] O’Rahilly R. The timing and sequence of events in the development of the human eye and ear during the embryonic period proper. *Anat Embryol (Berl)* 1983; 168: 87–99. doi:10.1007/BF00305401
- [2] Som PM, Curtin HD, Liu K et al. Current Embryology of the Temporal Bone, Part II: the Middle and External Ears, the Statoacoustic and Facial Nerves, and When Things Go Developmentally Wrong. *Neurographics* 2016; 6: 332–349. doi:10.3174/ng.5160174
- [3] Lavigne-Rebillard M, Pujol R. Surface Aspects of the Developing Human Organ of Corti. *Acta Otolaryngol* 1987; 104: 43–50. doi:10.3109/00016488709124975
- [4] Dabdoub A, Donohue MJ, Brennan A et al. WNT signaling mediates reorientation of outer hair cell stereociliary bundles in the mammalian cochlea. *Development* 2003; 130: 2375–2384. doi:10.1242/dev.00448
- [5] Tritsch NX, Zhang YX, Ellis-Davies G et al. ATP-induced morphological changes in supporting cells of the developing cochlea. *Purinergic Signal* 2010; 6: 155–166. doi:10.1007/s11302-010-9189-4
- [6] Fettiplace R. Hair Cell Transduction, Tuning, and Synaptic Transmission in the Mammalian Cochlea. In: *Comprehensive Physiology*. Hoboken, NJ, USA: John Wiley & Sons, Inc; 2017: 1197–1227. doi:10.1002/cphy.c160049
- [7] Tritsch NX, Yi E, Gale JE et al. The origin of spontaneous activity in the developing auditory system. *Nature* 2007; 450: 50–55. doi:10.1038/nature06233
- [8] Standring S. *Gray’s anatomy: the anatomical basis of clinical practice*. 2016
- [9] Flint P, Haughey B, Lund V et al. *Cummings Otolaryngology Head and Neck Surgery*. 2020
- [10] Gibaja A, Aburto MR, Pulido S et al. TGFβ2-induced senescence during early inner ear development. *Sci Rep* 2019; 9: 1–13. doi:10.1038/s41598-019-42040-0
- [11] Pujol R, Lavigne-Rebillard M. Early stages of innervation and sensory cell differentiation in the human fetal organ of Corti. *Acta Otolaryngol Suppl* 1985; 423: 43–50. doi:10.3109/00016488509122911
- [12] Lavigne-Rebillard M, Pujol R. Hair Cell Innervation in the Fetal Human Cochlea. *Acta Otolaryngol* 1988; 105: 398–402. doi:10.3109/00016488809119492
- [13] Moore JK, Linthicum FH. Myelination of the Human Auditory Nerve: Different Time Courses for Schwann Cell and Glial Myelin. *Ann Otol Rhinol Laryngol* 2001; 110: 655–661. doi:10.1177/000348940111000711
- [14] Moore JK. Organization of the human superior olivary complex. *Microsc Res Tech* 2000; 51: 403–412. doi:10.1002/1097-0029(20001115)51:4<403::AID-JEMT8>3.0.CO;2-Q
- [15] Brown R, Groves AK. Hear, hear for notch: Control of cell fates in the inner ear by notch signaling. *Biomolecules* 2020; 10: 1–18. doi:10.3390/biom10030370
- [16] Brigande JV, Kiernan A E, Gao X et al. Molecular genetics of pattern formation in the inner ear: do compartment boundaries play a role? *Proc Natl Acad Sci U S A* 2000; 97: 11700–11706. doi:10.1073/pnas.97.22.11700
- [17] Xu Q, Mellitzer G, Robinson V et al. In vivo cell sorting in complementary segmental domains mediated by Eph receptors and ephrins. *Nature* 1999; 399: 267–271. doi:10.1038/20452
- [18] Bergemann AD, Zhang L, Chiang MK et al. Ephrin-B3, a ligand for the receptor EphB3, expressed at the midline of the developing neural tube. *Oncogene* 1998; 16: 471–480. doi:10.1038/sj.onc.1201557
- [19] Gale NW, Flenniken A, Compton DC et al. Elk-L3, a novel transmembrane ligand for the Eph family of receptor tyrosine kinases, expressed in embryonic floor plate, roof plate and hindbrain segments. *Oncogene* 1996; 13: 1343–1352. Im Internet: <http://www.ncbi.nlm.nih.gov/pubmed/8808709>
- [20] Wright TJ, Hatch EP, Karabagli H et al. Expression of mouse fibroblast growth factor and fibroblast growth factor receptor genes during early inner ear development. *Dev Dyn* 2003; 228: 267–272. doi:10.1002/dvdy.10362
- [21] Sai X, Ladhur RK. Early steps in inner ear development: Induction and morphogenesis of the otic placode. *Front Pharmacol* 2015; 6: 1–8. doi:10.3389/fphar.2015.00019
- [22] Bouchard M, de Caprona D, Busslinger M et al. Pax2 and Pax8 cooperate in mouse inner ear morphogenesis and innervation. *BMC Dev Biol* 2010; 10: 89. doi:10.1186/1471-213X-10-89
- [23] Chatterjee S, Kraus P, Lufkin T. A symphony of inner ear developmental control genes. *BMC Genet* 2010; 11: 68. doi:10.1186/1471-2156-11-68
- [24] Riccomagno MM. WNT-dependent regulation of inner ear morphogenesis is balanced by the opposing and supporting roles of SHH. *Genes Dev* 2005; 19: 1612–1623. doi:10.1101/gad.1303905
- [25] Bok J, Brunet LJ, Howard O et al. Role of hindbrain in inner ear morphogenesis: analysis of Noggin knockout mice. *Dev Biol* 2007; 311: 69–78. doi:10.1016/j.ydbio.2007.08.013
- [26] Bok J, Chang W, Wu DK. Patterning and morphogenesis of the vertebrate inner ear. *Int J Dev Biol* 2007; 51: 521–533. doi:10.1387/ijdb.072381jb
- [27] Wu DK, Nunes FD, Choo D. Axial specification for sensory organs versus non-sensory structures of the chicken inner ear. *Development* 1998; 125: 11–20. Im Internet: <http://www.ncbi.nlm.nih.gov/pubmed/9389659>
- [28] Duncan JS, Lim K-C, Engel JD et al. Limited inner ear morphogenesis and neurosensory development are possible in the absence of GATA3. *Int J Dev Biol* 2011; 55: 297–303. doi:10.1387/ijdb.103178jd
- [29] Zou D, Silviu D, Rodrigo-Blomqvist S et al. Eya1 regulates the growth of otic epithelium and interacts with Pax2 during the development of all sensory areas in the inner ear. *Dev Biol* 2006; 298: 430–441. doi:10.1016/j.ydbio.2006.06.049
- [30] Maroon H, Walshe J, Mahmood R et al. Fgf3 and Fgf8 are required together for formation of the otic placode and vesicle. *Development* 2002; 129: 2099–2108. Im Internet: <http://www.ncbi.nlm.nih.gov/pubmed/11959820>
- [31] Kiernan AE, Pelling AL, Leung KKH et al. Sox2 is required for sensory organ development in the mammalian inner ear. *Nature* 2005; 434: 1031–1035
- [32] Fritzsche B, Beisel KWK, Hansen L a.. The molecular basis of neurosensory cell formation in ear development: a blueprint for hair cell and sensory neuron regeneration? *Bioessays* 2006; 28: 1181–1193. doi:10.1002/bies.20502
- [33] Fritzsche B, Matei V a, Nichols DH et al. Atoh1 null mice show directed afferent fiber growth to undifferentiated ear sensory epithelia followed by incomplete fiber retention. *Dev Dyn* 2005; 233: 570–583. doi:10.1002/dvdy.20370
- [34] Bermingham N a, Hassan B a, Price SD et al. Math1: an essential gene for the generation of inner ear hair cells. *Science* 1999; 284: 1837–1841. doi:10.1126/science.284.5421.1837
- [35] Artavanis-Tsakonas S, Muskavitch MAT. Notch: the past, the present, and the future. *Curr Top Dev Biol* 2010; 92: 1–29. doi:10.1016/S0070-2153(10)92001-2
- [36] Bryant J, Goodyear RJ, Richardson GP. Sensory organ development in the inner ear: molecular and cellular mechanisms. *Br Med Bull* 2002; 63: 39–57. Im Internet: <http://www.ncbi.nlm.nih.gov/pubmed/12324383>
- [37] Petit C, Richardson GP. Linking genes underlying deafness to hair-bundle development and function. *Nat Neurosci* 2009; 12: 703–710. doi:10.1038/nn.2330
- [38] Yin H, Copley CO, Goodrich LV et al. Comparison of phenotypes between different vangl2 mutants demonstrates dominant effects of the Looptail mutation during hair cell development. *PLoS One* 2012; 7: e31988. doi:10.1371/journal.pone.0031988

- [39] Sipe CW, Lu X. Kif3a regulates planar polarization of auditory hair cells through both ciliary and non-ciliary mechanisms. *Development* 2011; 138: 3441–3449. doi:10.1242/dev.065961
- [40] García-Bellido A, De Celis JF. The complex tale of the achaete-scute complex: A paradigmatic case in the analysis of gene organization and function during development. *Genetics* 2009; 182: 631–639. doi:10.1534/genetics.109.104083
- [41] Gaspard N, Vanderhaeghen P. Mechanisms of neural specification from embryonic stem cells. *Curr Opin Neurobiol* 2010; 20: 37–43. doi:10.1016/j.conb.2009.12.001
- [42] Naka H, Nakamura S, Shimazaki T et al. Requirement for COUP-TFI and II in the temporal specification of neural stem cells in CNS development. *Nat Neurosci* 2008; 11: 1014–1023. doi:10.1038/nn.2168
- [43] Jahan I, Pan N, Kersigo J et al. Neurod1 suppresses hair cell differentiation in ear ganglia and regulates hair cell subtype development in the cochlea. *PLoS One* 2010; 5: e11661. doi:10.1371/journal.pone.0011661
- [44] Karis A, Pata I, van Doorninck JH et al. Transcription factor GATA-3 alters pathway selection of olivocochlear neurons and affects morphogenesis of the ear. *J Comp Neurol* 2001; 429: 615–630. doi:10.1002/1096-9861(20010122)429:4<615::aid-cne8>3.0.co;2-f
- [45] Huang EJ, Liu W, Fritsch B et al. Brn3a is a transcriptional regulator of soma size, target field innervation and axon pathfinding of inner ear sensory neurons. *Development* 2001; 128: 2421–2432. Im Internet: <http://www.pubmedcentral.nih.gov/articlerender.fcgi?artid=2710107&tool=pmcentrez&rendertype=abstract>
- [46] Jahan I, Pan N, Elliott KL et al. The quest for restoring hearing: Understanding ear development more completely. *BioEssays* 2015; 37: 1016–1027. doi:10.1002/bies.201500044
- [47] Pan N, Jahan I, Kersigo J et al. Conditional deletion of Atoh1 using Pax2-Cre results in viable mice without differentiated cochlear hair cells that have lost most of the organ of Corti. *Hear Res* 2011; 275: 66–80. doi:10.1016/j.heares.2010.12.002
- [48] Yang T, Kersigo J, Jahan I et al. The molecular basis of making spiral ganglion neurons and connecting them to hair cells of the organ of Corti. *Hear Res* 2011; 278: 21–33. doi:10.1016/j.heares.2011.03.002
- [49] Fekete DM, Campero AM. Axon guidance in the inner ear. *Int J Dev Biol* 2007; 51: 549–556. doi:10.1387/ijdb.072341df
- [50] Barclay M, Julien J-P, Ryan AF et al. Type III intermediate filament peripherin inhibits neurogenesis in type II spiral ganglion neurons in vitro. *Neurosci Lett* 2010; 478: 51–55. doi:10.1016/j.neulet.2010.01.063
- [51] Fritsch B, Dillard M, Lavado A et al. Canal cristae growth and fiber extension to the outer hair cells of the mouse ear require Prox1 activity. *PLoS One* 2010; 5: 1–12. doi:10.1371/journal.pone.0009377
- [52] Fariñas I, Jones KR, Tessarollo L et al. Spatial shaping of cochlear innervation by temporally regulated neurotrophin expression. *J Neurosci* 2001; 21: 6170–6180. <http://www.pubmedcentral.nih.gov/articlerender.fcgi?artid=2710117&tool=pmcentrez&rendertype=abstract>
- [53] Samarajeewa A, Jacques BE, Dabdoub A. Therapeutic Potential of WNT and Notch Signaling and Epigenetic Regulation in Mammalian Sensory Hair Cell Regeneration. *Mol Ther* 2019; 27: 904–911. doi:10.1016/j.yymthe.2019.03.017
- [54] Chai R, Kuo B, Wang T et al. WNT signaling induces proliferation of sensory precursors in the postnatal mouse cochlea. *Proc Natl Acad Sci U S A* 2012; 109: 8167–8172. doi:10.1073/pnas.1202774109
- [55] Bramhall NF, Shi F, Arnold K et al. Lgr5-positive supporting cells generate new hair cells in the postnatal cochlea. *Stem Cell Reports* 2014; 2: 311–322. doi:10.1016/j.stemcr.2014.01.008
- [56] McLean WJ, Yin X, Lu L et al. Clonal Expansion of Lgr5-Positive Cells from Mammalian Cochlea and High-Purity Generation of Sensory Hair Cells. *Cell Rep* 2017; 18: 1917–1929. doi:10.1016/j.celrep.2017.01.066
- [57] Johnson Chacko L, Sergi C, Eberharther T et al. Early appearance of key transcription factors influence the spatiotemporal development of the human inner ear. *Cell Tissue Res* 2020; 379: 459–471. doi:10.1007/s00441-019-03115-6
- [58] Miwa T, Ohta K, Ito N et al. Tsukushi is essential for the development of the inner ear. *Mol Brain* 2020; 13: 1–11. doi:10.1186/s13041-020-00570-z
- [59] Cardoso-Moreira M, Halbert J, Valloton D et al. Gene expression across mammalian organ development. *Nature* 2019; 571: 505–509. doi:10.1038/s41586-019-1338-5
- [60] Qin Y, Pan J, Cai M et al. Pattern Genes Suggest Functional Connectivity of Organs. *Sci Rep* 2016; 6: 1–7. doi:10.1038/srep26501
- [61] Lam EWF, Brosens JJ, Gomes AR et al. Forkhead box proteins: Tuning forks for transcriptional harmony. *Nat Rev Cancer* 2013; 13: 482–495. doi:10.1038/nrc3539
- [62] Stefanovic S, Abboud N, Désilets S et al. Interplay of Oct4 with Sox2 and Sox17: A molecular switch from stem cell pluripotency to specifying a cardiac fate. *J Cell Biol* 2009; 186: 665–673. doi:10.1083/jcb.200901040
- [63] Som PM, Curtin HD, Liu K et al. Current Embryology of the Temporal Bone, Part I: the Inner Ear. *Neurographics* 2016; 6: 250–265. doi:10.3174/ng.4160166
- [64] Lefebvre V. Roles and regulation of SOX transcription factors in skeletogenesis. *Curr Top Dev Biol* 2019; 133: 171–193. doi:10.1016/bs.ctdb.2019.01.007
- [65] Heavner WE, Andoniadou CL, Pevny LH. Establishment of the neurogenic boundary of the mouse retina requires cooperation of SOX2 and WNT signaling. *Neural Dev* 2014; 9. doi:10.1186/1749-8104-9-27
- [66] Wang L, Sewell WF, Kim SD et al. Eya4 regulation of Na⁺/K⁺-ATPase in required for sensory system. development in zebrafish. *Development* 2008; 135: 3425–3434. doi:10.1242/dev.012237
- [67] Vona B, Nanda I, Hofrichter MAH et al. Non-syndromic hearing loss gene identification: A brief history and glimpse into the future. *Mol Cell Probes* 2015; 29: 260–270. doi:10.1016/j.mcp.2015.03.008
- [68] Girirajan S, Eichler EE. Phenotypic variability and genetic susceptibility to genomic disorders. *Hum Mol Genet* 2010; 19: R176–R187. doi:10.1093/hmg/ddq366
- [69] Génin E, Feingold J, Clerget-Darpoux F. Identifying modifier genes of monogenic disease: strategies and difficulties. *Hum Genet* 2008; 124: 357–368. doi:10.1007/s00439-008-0560-2
- [70] Hildebrand MS, DeLuca AP, Taylor KR et al. A contemporary review of AudioGene audioprofiling: A machine-based candidate gene prediction tool for autosomal dominant nonsyndromic hearing loss. *Laryngoscope* 2009; 119: 2211–2215. doi:10.1002/lary.20664
- [71] Warnecke A, Prenzler NK, Schmitt H et al. Defining the Inflammatory Microenvironment in the Human Cochlea by Perilymph Analysis: Toward Liquid Biopsy of the Cochlea. *Front Neurol* 2019; 10: 1–10. doi:10.3389/fneur.2019.00665
- [72] Yue Q, Stahl F, Plettenburg O et al. The Noncompetitive Effect of Gambogic Acid Displaces Fluorescence-Labeled ATP but Requires ATP for Binding to Hsp90/HtpG. *Biochemistry* 2018; 57: 2601–2605. doi:10.1021/acs.biochem.8b00155
- [73] Shew M, Warnecke A, Lenarz T et al. Feasibility of microRNA profiling in human inner ear perilymph. *Neuroreport* 2018; 29: 894–901. doi:10.1097/WNR.0000000000001049
- [74] Wang H, Stahl F, Scheper T et al. Microarray-based screening system identifies temperature-controlled activity of Connexin 26 that is distorted by mutations. *Sci Rep* 2019; 9: 13543. doi:10.1038/s41598-019-49423-3

- [75] Mondini C. Minor works of Carlo Mondini: the anatomical section of a boy born deaf. *Am J Otol* 1997; 18: 288–293
- [76] Brotto D, Uberti A, Manara R. From Mondini to the latest inner ear malformations' classifications: an historical and critical review. *Hear Balanc Commun* 2019; 17: 241–248. doi:10.1080/21695717.2019.1663041
- [77] Jackler RK, Luxford WM, House WF. Congenital malformations of the inner ear: A classification based on embryo genesis. *Laryngoscope* 1987; 97: 2–14. doi:10.1002/lary.5540971301
- [78] Streeter GL. Developmental horizons in human embryos; a review of the histogenesis of cartilage and bone. *Contrib Embryol* 1949; 33: 149–168. Im Internet: <http://www.ncbi.nlm.nih.gov/pubmed/18144445>
- [79] Sennaroglu L, Bajin MD. Classification and current management of inner ear malformations. *Balkan Med J* 2017; 34: 397–411. doi:10.4274/balkanmedj.2017.0367
- [80] Sennaroglu L, Saatci I. Unpartitioned Versus Incompletely Partitioned Cochleae: Radiologic Differentiation. *Otol Neurotol* 2004; 25: 520–529. doi:10.1097/00129492-200407000-00020
- [81] Giesemann A, Götz F, Lanfermann H. Fehlbildungen des Innenohrs - Diagnostik und Einteilung in CT und MRT. *Radiol up2date* 2013; 13: 201–218. doi:10.1055/s-0033-1344189
- [82] Phelps PD, Michaels L. The Common Cavity Congenital Deformity of the Inner Ear. *ORL* 1995; 57: 228–231. doi:10.1159/000276746
- [83] Cock E. A contribution to the pathology of congenital deafness. *Guys Hosp Rep* 1838; 7
- [84] Papsin BC. Cochlear implantation in children with anomalous cochleovestibular anatomy. *Laryngoscope* 2005; 115: 1–26. doi:10.1097/00005537-200501001-00001
- [85] Nance WE, Settleff R, McLeod A et al. X-linked mixed deafness with congenital fixation of the stapedial footplate and perilymphatic gusher. *Birth Defects Orig Artic Ser* 1971; 07: 64–69. Im Internet: <http://www.ncbi.nlm.nih.gov/pubmed/5173351>
- [86] Phelps PD, Reardon W, Pembrey M et al. X-linked deafness, stapes gushers and a distinctive defect of the inner ear. *Neuroradiology* 1991; 33: 326–330. doi:10.1007/BF00587816
- [87] Kang WS, Shim BS, Lee KS. Audiologic performance after cochlear implantation in children with X-linked deafness: Comparison with deaf children with a normal inner ear structure. *Otol Neurotol* 2013; 34: 544–548. doi:10.1097/MAO.0b013e3182839864
- [88] Smith JD, El-Kashlan N, Darr OAF et al. Systematic Review of Outcomes After Cochlear Implantation in Children With X-Linked Deafness-2. *Otolaryngol – Head Neck Surg (United States)* 2020; 1–8. doi:10.1177/0194599820932138
- [89] de Kok YJ, van der Maarel SM, Bitner-Glindzicz M et al. Association between X-linked mixed deafness and mutations in the POU domain gene POU3F4. *Science* 1995; 267: 685–688. doi:10.1126/science.7839145
- [90] Pollak A, Lechowicz U, Kędra A et al. Novel and De Novo mutations extend association of POU3F4 with distinct clinical and radiological phenotype of hearing loss. *PLoS One* 2016; 11: 1–13. doi:10.1371/journal.pone.0166618
- [91] Myhre SA, Ruvalcaba RHA, Kelley VC. Congenital deafness and hypogonadism: a new X-linked recessive disorder. *Clin Genet* 2008; 22: 299–307. doi:10.1111/j.1399-0004.1982.tb01843.x
- [92] Giesemann A, Hartmann H, Franke D et al. Hamartome in Kombination mit X-chromosomaler Taubheit zeigen keine Epilepsie und keine Pubertas praecox. In: *Clinical Neuroaudiology* 2013; 0177
- [93] Siddiqui A, D'Amico A, Colafati GS et al. Hypothalamic malformations in patients with X-linked deafness and incomplete partition type 3. *Neuroradiology* 2019; 61: 949–952. doi:10.1007/s00234-019-02230-z
- [94] Corvino V, Apisa P, Malesci R et al. X-Linked Sensorineural Hearing Loss: A Literature Review. *Curr Genomics* 2017; 19: 327–338. doi:10.2174/1389202919666171218163046
- [95] Satar B, Mukherji SK, Telian SA. Congenital Aplasia of the Semicircular Canals. *Otol Neurotol* 2003; 24: 437–446. doi:10.1097/00129492-200305000-00014
- [96] Lanson BG, Green JE, Roland JT et al. Cochlear implantation in Children with CHARGE syndrome: therapeutic decisions and outcomes. *Laryngoscope* 2007; 117: 1260–1266. doi:10.1097/MLG.0b013e31806009c9
- [97] Pagon RA, Graham JM, Zonana J et al. Coloboma, congenital heart disease, and choanal atresia with multiple anomalies: CHARGE association. *J Pediatr* 1981; 99: 223–227. doi:10.1016/s0022-3476(81)80454-4
- [98] Verloes A. Updated diagnostic criteria for CHARGE syndrome: a proposal. *Am J Med Genet A* 2005; 133A: 306–308. doi:10.1002/ajmg.a.30559
- [99] Hsu P, Ma A, Wilson M et al. CHARGE syndrome: A review. *J Paediatr Child Health* 2014; 50: 504–511. doi:10.1111/jpc.12497
- [100] Kontorinis G, Goetz F, Giourgias A et al. Aplasia of the cochlea: Radiologic assessment and options for hearing rehabilitation. *Otol Neurotol* 2013; 34: 1253–1260. doi:10.1097/MAO.0b013e318291c48f
- [101] Phelps PD. Cochlear Implants For Congenital Deformities. *J Laryngol Otol* 1992; 106: 967–970. doi:10.1017/S0022215100121486
- [102] Dahm MC, Weber BP, Lenarz T. Cochlear implantation in a Mondini malformation of the inner ear and the management of perilymphatic gusher. *Adv Otorhinolaryngol* 1995; 50: 66–71. doi:10.1159/000424437
- [103] Weber BP, Lenarz T, Hartrampf R et al. Cochlear implantation in children with malformation of the cochlea. *Adv Otorhinolaryngol* 1995; 50: 59–65. doi:10.1159/000424436
- [104] Kontorinis G, Goetz F, Giourgias A et al. Radiological diagnosis of incomplete partition type I versus type II: significance for cochlear implantation. *Eur Radiol* 2012; 22: 525–532. doi:10.1007/s00330-011-2301-5
- [105] Sennaroglu L, Tahir E. A Novel Classification: Anomalous Routes of the Facial Nerve in Relation to Inner Ear Malformations. *Laryngoscope* 2020; 1–8. doi:10.1002/lary.28596
- [106] Halawani RT, Dhanasingh A. New Classification of Cochlear Hypoplasia Type Malformation: Relevance in Cochlear Implantation. *J Int Adv Otol* 2020; 16: 153–157. doi:10.5152/jiao.2020.7690
- [107] Cinar BC, Batuk MO, Tahir E et al. Audiologic and radiologic findings in cochlear hypoplasia. *Auris Nasus Larynx* 2017; 44: 655–663. doi:10.1016/j.anl.2016.12.002
- [108] Giesemann AM, Goetz F, Neuburger J et al. Appearance of hypoplastic cochleae in CT and MRI: A new subclassification. *Neuroradiology* 2011; 53: 49–61. doi:10.1007/s00234-010-0777-3
- [109] Harnsberger HR. *Diagnostic Imaging Head and Neck*. 2004
- [110] Giesemann AM, Kontorinis G, Jan Z et al. The vestibulocochlear nerve: Aplasia and hypoplasia in combination with inner ear malformations. *Eur Radiol* 2012; 22: 519–524. doi:10.1007/s00330-011-2287-z
- [111] Dörr J, Krautwald S, Wildemann B et al. Characteristics of Susac syndrome: A review of all reported cases. *Nat Rev Neurol* 2013; 9: 307–316. doi:10.1038/nrneurol.2013.82
- [112] Kleffner I, Dörr J, Ringelstein M et al. Diagnostic criteria for Susac syndrome. *J Neurol Neurosurg Psychiatry* 2016; 87: 1287–1295. doi:10.1136/jnnp-2016-314295
- [113] Hertzano R, Tomlinson JA, Mackowiak PA. Goya's Lost Hearing: A Twenty-First Century Perspective on Its Cause, Effects and Possible Treatment. *Am J Med Sci* 2019; 357: 275–279. doi:10.1016/j.amjms.2018.12.009

- [114] Schelenz D, Kleffner I, Tsiampalis N et al. Susac syndrome – interdisciplinary tracking of the chameleon: two different case reports. *Ophthalmology* 2020; 117: 369–375. doi:10.1007/s00347-019-0926-y
- [115] Wang Y, Burkholder B, Newsome SD. Progressive sensorineural hearing loss many years preceding completion of Susac's syndrome triad: A case report. *Mult Scler Relat Disord* 2020; 37: 101436. doi:10.1016/j.msard.2019.101436
- [116] Kleffner I, Duning T, Lohmann H et al. A brief review of Susac syndrome. *J Neurol Sci* 2012; 322: 35–40. doi:10.1016/j.jns.2012.05.021
- [117] Plontke SK, Caye-Thomasen P, Strauss C et al. Management of transmodiolar and transmacular cochleovestibular schwannomas with and without cochlear implantation. *HNO* 2020; doi:10.1007/s00106-020-00919-9
- [118] Baskin J, Hardy TA, Law LY et al. Black blood MRI: endotheliopathy of Susac syndrome unmasked. *Neurol Sci* 2020; 8–10. doi:10.1007/s10072-020-04562-8
- [119] Mei X, Glueckert R, Schrott-Fischer A et al. Vascular Supply of the Human Spiral Ganglion: Novel Three-Dimensional Analysis Using Synchrotron Phase-Contrast Imaging and Histology. *Sci Rep* 2020; 10: 5877. doi:10.1038/s41598-020-62653-0
- [120] Ishiyama G, Wester J, Lopez IA et al. Oxidative stress in the blood labyrinthine barrier in the macula utricule of Meniere's disease patients. *Front Physiol* 2018; 9: 1–16. doi:10.3389/fphys.2018.01068
- [121] Gu C, Qiao W, Wang L et al. Identification of genes and pathways associated with multiple organ dysfunction syndrome by microarray analysis. *Mol Med Rep* 2018; 18: 31–40. doi:10.3892/mmr.2018.8973
- [122] Ishiyama G, Lopez IA, Acuna D et al. Investigations of the Microvasculature of the Human Macula Utricule in Meniere's Disease. *Front Cell Neurosci* 2019; 13: 1–11. doi:10.3389/fncel.2019.00445
- [123] Schmitt HA, Pich A, Schröder A et al. Proteome Analysis of Human Perilymph using an Intraoperative Sampling Method. *J Proteome Res* 2017; doi:10.1021/acs.jproteome.6b00986
- [124] Lin HC, Ren Y, Lysaght AC et al. Proteome of normal human perilymph and perilymph from people with disabling vertigo. *PLoS One* 2019; 14: 1–21. doi:10.1371/journal.pone.0218292
- [125] Lage K, Hansena NT, Karlberg EO et al. A large-scale analysis of tissue-specific pathology and gene expression of human disease genes and complexes. *Proc Natl Acad Sci U S A* 2008; 105: 20870–20875. doi:10.1073/pnas.0810772105
- [126] Knipper M, Hofmeier B, Singer W et al. Differentiating cochlear synaptopathies into different hearing disorders. *HNO* 2019; 67: 406–416. doi:10.1007/s00106-019-0660-4
- [127] Espinoza GM, Wheeler J, Temprano KK et al. Cogan's Syndrome: Clinical Presentations and Update on Treatment. *Curr Allergy Asthma Rep* 2020; 20: 2–7. doi:10.1007/s11882-020-00945-1
- [128] Kuemmerle-Deschner JB, Koitschev A, Ummenhofer K et al. Hearing loss in Muckle-Wells syndrome. *Arthritis Rheum* 2013; 65: 824–831. doi:10.1002/art.37810
- [129] Goldbach-Mansky R, Dailey NJ, Canna SW et al. Neonatal-Onset Multisystem Inflammatory Disease Responsive to Interleukin-1 β Inhibition. *N Engl J Med* 2006; 355: 581–592. doi:10.1056/NEJMoa055137
- [130] Bachor E, Blevins NH, Karmody C et al. Otologic manifestations of relapsing polychondritis. *Auris Nasus Larynx* 2006; 33: 135–141. doi:10.1016/j.anl.2005.11.020
- [131] Noguchi Y, Nishio A, Takase H et al. Audiovestibular findings in patients with Vogt-Koyanagi-Harada disease. *Acta Otolaryngol* 2014; 134: 339–344. doi:10.3109/00016489.2013.868604
- [132] Kemal O, Anadolu Y, Boyvat A et al. Behçet Disease as a Cause of Hearing Loss: A Prospective, Placebo-Controlled Study of 29 Patients. *Ear, Nose Throat J* 2013; 92: 112–120. doi:10.1177/014556131309200309
- [133] Ovadia S, Dror I, Zubkov T et al. Churg-Strauss syndrome: A rare presentation with otological and pericardial manifestations: Case report and review of the literature. *Clin Rheumatol* 2009; 28: 35–38. doi:10.1007/s10067-009-1119-x
- [134] Moosig F, Holle J. Current treatment of eosinophilic granulomatosis with polyangiitis (Churg-Strauss syndrome). *Z Rheumatol* 2019; 78: 333–338. doi:10.1007/s00393-018-0580-9
- [135] rare-diseases.org. Im Internet: <https://rare-diseases.org/rare-diseases/alpha-mannosidosis/>; Stand: 16.08.2020
- [136] Faverio P, Bonaiti G, Bini F et al. Mepolizumab as the first targeted treatment for eosinophilic granulomatosis with polyangiitis: A review of current evidence and potential place in therapy. *Ther Clin Risk Manag* 2018; 14: 2385–2396. doi:10.2147/TCRM.S159949
- [137] Brachet C, Mansbach AL, Clerckx A et al. Hearing Loss Is Part of the Clinical Picture of ENPP1 Loss of Function Mutation. *Horm Res Paediatr* 2014; 81: 63–66. doi:10.1159/000354661
- [138] Maher CO, Piepgras DG, Brown RD et al. Cerebrovascular manifestations in 321 cases of hereditary hemorrhagic telangiectasia. *Stroke* 2001; 32: 877–882. doi:10.1161/01.STR.32.4.877
- [139] Kim GB. Reality of Kawasaki disease epidemiology. *Korean J Pediatr* 2019; 62: 292–296. doi:10.3345/kjp.2019.00157
- [140] Rahne T, Plontke S, Keyßer G. Vasculitis and the ear: A literature review. *Curr Opin Rheumatol* 2020; 32: 47–52. doi:10.1097/BOR.0000000000000665
- [141] Nadol JB, Eavey RD, Liberfarb RM et al. Histopathology of the ears, eyes, and brain in norrie's disease (oculoacousticocerebral degeneration). *Am J Otolaryngol* 1990; 11: 112–124. doi:10.1016/0196-0709(90)90007-1
- [142] Gross CC, Meyer C, Bhatia U et al. CD8 + T cell-mediated endotheliopathy is a targetable mechanism of neuro-inflammation in Susac syndrome. *Nat Commun* 2019; 10. doi:10.1038/s41467-019-13593-5
- [143] Naini AS, Ghorbani J, Elahi SML et al. Otologic manifestations in patients with Wegener's granulomatosis: A survey in 55 patients. *Iran J Otorhinolaryngol* 2017; 29: 327–331. doi:10.22038/ijorl.2017.25253.1822
- [144] Marsot-Dupuch K, Dominguez-Brito A, Ghasli K et al. CT and MR findings of Michel anomaly: Inner ear aplasia. *Am J Neuroradiol* 1999; 20: 281–284
- [145] Daneshi A, Farhadi M, Asghari A et al. Three familial cases of Michel's aplasia. *Otol Neurotol* 2002; 23: 346–348. doi:10.1097/00129492-200205000-00020
- [146] Giesemann AM, Goetz F, Neuburger J et al. From labyrinthine aplasia to otocyst deformity. *Neuroradiology* 2010; 52: 147–154. doi:10.1007/s00234-009-0601-0
- [147] Vesseur AC, Verbist BM, Westerlaan HE et al. CT findings of the temporal bone in CHARGE syndrome: aspects of importance in cochlear implant surgery. *Eur Arch Oto-Rhino-Laryngology* 2016; 273: 4225–4240. doi:10.1007/s00405-016-4141-z
- [148] Giesemann AM, Goetz GF, Neuburger J et al. Persistent petrosquamosal sinus: High incidence in cases of complete aplasia of the semicircular canals. *Radiology* 2011; 259: 825–833. doi:10.1148/radiol.11101466
- [149] Sennaroglu L, Saatci I. A New Classification for Cochleovestibular Malformations. *Laryngoscope* 2002; 112: 2230–2241. doi:10.1097/00005537-200212000-00019
- [150] Bademci G, Abad C, Incesulu A et al. FOXF2 is required for cochlear development in humans and mice. *Hum Mol Genet* 2019; 28: 1286–1297. doi:10.1093/hmg/ddy431

- [151] Alballaa A, Aschendorff A, Arndt S et al. Incomplete partition type III* – Langzeitergebnisse nach Cochleaimplantation. *HNO* 2019; 67: 760–768. doi:10.1007/s00106-019-00733-y
- [152] Kaur A, Khetarpal S. 3P Deletion Syndrome. *Indian Pediatr* 2013; 50: 795–796
- [153] Țuțulan-Cuniță AC, Papuc SM, Arghir A et al. 3p interstitial deletion: Novel case report and review. *J Child Neurol* 2012; 27: 1062–1066. doi:10.1177/0883073811431016
- [154] Lindstrand A, Malmgren H, Verri A et al. Molecular and clinical characterization of patients with overlapping 10p deletions. *Am J Med Genet Part A* 2010; 152: 1233–1243. doi:10.1002/ajmg.a.33366
- [155] Ohta S, Isojima T, Mizuno Y et al. Partial monosomy of 10p and duplication of another chromosome in two patients. *Pediatr Int* 2017; 59: 99–102. doi:10.1111/ped.13181
- [156] Corrêa T, Feltes BC, Riegel M. Integrated analysis of the critical region 5p15.3–p15.2 associated with cri-du-chat syndrome. *Genet Mol Biol* 2019; 42: 186–196. doi:10.1590/1678-4685-gmb-2018-0173
- [157] Swanepoel D. Auditory pathology in cri-du-chat (5p-) syndrome: Phenotypic evidence for auditory neuropathy. *Clin Genet* 2007; 72: 369–373. doi:10.1111/j.1399-0004.2007.00870.x
- [158] Du Q, de la Morena MT, van Oers NSC. The Genetics and Epigenetics of 22q11.2 Deletion Syndrome. *Front Genet* 2020; 10: 1–16. doi:10.3389/fgene.2019.01365
- [159] Bhalla P, Wysocki CA, van Oers NSC. Molecular Insights Into the Causes of Human Thymic Hypoplasia With Animal Models. *Front Immunol* 2020; 11. doi:10.3389/fimmu.2020.00830
- [160] Romagna ES, Appel da Silva MC, Zanetti Ballardin PA. Schmid-Fracarro Syndrome: Severe Neurologic Features. *Pediatr Neurol* 2010; 42: 151–153. doi:10.1016/j.pediatrneurol.2009.07.020
- [161] Alamer L, Bassant S, Alhazmi R et al. Rare otologic presentation of cat eye syndrome. *Ann Saudi Med* 2019; 39: 441–443. doi:10.5144/0256-4947.2019.441
- [162] Crawford TD, Audia JE, Bellon S et al. GNE-886: A Potent and Selective Inhibitor of the Cat Eye Syndrome Chromosome Region Candidate 2 Bromodomain (CECR2). *ACS Med Chem Lett* 2017; 8: 737–741. doi:10.1021/acsmchemlett.7b00132
- [163] Pejčić L, Stanković T, Ratković-Janković M et al. Clinical manifestations in trisomy 9 mosaicism. *Turk J Pediatr* 2018; 60: 729–734. doi:10.24953/turkjped.2018.06.015
- [164] Dhangar S, Korgaonkar S, Vundinti BR. Partial trisomy 9 (9pter->9q22.1) and partial monosomy 14 (14pter->14q11.2) due to paternal translocation t(9(q22.1;q11.2) in a case of Dysmorphic features. *Intractable Rare Dis Res* 2019; 8: 72–77. doi:10.5582/irdr.2019.01000
- [165] Lee CY, Su HJ, Cheng YT et al. Detection of fetal trisomy 9 mosaicism by noninvasive prenatal testing through maternal plasma DNA sequencing. *Taiwan J Obstet Gynecol* 2018; 57: 594–597. doi:10.1016/j.tjog.2018.06.021
- [166] Thomas S, Parker M, Tan J et al. Ocular manifestations of mosaic trisomy 22: A case report and review of the literature. *Ophthalmic Genet* 2004; 25: 53–56. doi:10.1076/opge.25.1.53.29004
- [167] Abdelgadir D, Nowaczyk MJM, Li C. Trisomy 22 Mosaicism and Normal Developmental Outcome: Report of Two Patients and Review of the Literature. *Am J Med Genet Part A* 2013; 161: 1126–1131. doi:10.1002/ajmg.a.35812
- [168] Schuster M, Hoppe U, Eysoldt U et al. Severe Hearing Loss in Pallister-Killian Syndrome. *ORL* 2002; 64: 343–345. doi:10.1159/000066080
- [169] Brendal MA, King KA, Zalewski CK et al. Auditory Phenotype of Smith–Magenis Syndrome. *J Speech, Lang Hear Res* 2017; 60: 1076–1087. doi:10.1044/2016_JSLHR-H-16-0024
- [170] Lei M, Liang D, Yang Y et al. Long-read DNA sequencing fully characterized chromothripsis in a patient with Langer–Giedion syndrome and Cornelia de Lange syndrome-4. *J Hum Genet* 2020; 65: 667–674. doi:10.1038/s10038-020-0754-6
- [171] Nouws J, Wibrand F, van den Brand M et al. A Patient with Complex I Deficiency Caused by a Novel ACAD9 Mutation Not Responding to Riboflavin Treatment. In: *JIMD Reports* 2013; 37–45. doi:10.1007/8904_2013_242
- [172] Dewulf JP, Barrea C, Vincent MF et al. Evidence of a wide spectrum of cardiac involvement due to ACAD9 mutations: Report on nine patients. *Mol Genet Metab* 2016; 118: 185–189. doi:10.1016/j.ymgme.2016.05.005
- [173] Yazdanfard PD, Madsen CV, Nielsen LH et al. Significant hearing loss in Fabry disease: Study of the Danish nationwide cohort prior to treatment. *PLoS One* 2019; 14: e0225071. doi:10.1371/journal.pone.0225071
- [174] Syed Haneef SA, George Priya Doss C. Personalized Pharmacoperones for Lysosomal Storage Disorder: Approach for Next-Generation Treatment. *Adv Protein Chem Struct Biol* 2016; 102: 225–265. doi:10.1016/bs.apcsb.2015.10.001
- [175] orpha.net
- [176] Ärztezeitung.de. Im Internet: <https://www.aerztezeitung.de/Specials/Lamzede-erste-Enzymersatztherapie-fuer-Patienten-mit-Alpha-Mannosidose-255697.html>; Stand: 16.08.2020
- [177] Lehalle D, Colombo R, O'Grady M et al. Hearing impairment as an early sign of alpha-mannosidosis in children with a mild phenotype: Report of seven new cases. *Am J Med Genet Part A* 2019; 179: 1756–1763. doi:10.1002/ajmg.a.61273
- [178] Canda E, Kalkan Uçar S, Çoker M. Biotinidase Deficiency: Prevalence, Impact And Management Strategies. *Pediatr Heal Med Ther* 2020; 11: 127–133. doi:10.2147/PHMT.S198656
- [179] Jaeger B, Bosch AM. Clinical presentation and outcome of riboflavin transporter deficiency: mini review after five years of experience. *J Inher Metab Dis* 2016; 39: 559–564. doi:10.1007/s10545-016-9924-2
- [180] Garg M, Kulkarni S, Hegde A et al. Riboflavin treatment in genetically proven Brown–Vialletto–Van Laere syndrome. *J Pediatr Neurosci* 2018; 13: 471. doi:10.4103/JPN.JPN_131_17
- [181] Dhar SU, Taylor T, Trinh C et al. Cranio-meta-diaphyseal dysplasia: 25 Year follow-up and review of literature. *Am J Med Genet Part A* 2010; 152: 2335–2338. doi:10.1002/ajmg.a.33582
- [182] Huygen PLM, Cremers CWRJ, Verhagen WIM et al. Camurati-Engelmann disease presenting as „juvenile otosclerosis“. *Int J Pediatr Otorhinolaryngol* 1996; 37: 129–141. doi:10.1016/0165-5876(96)01392-4
- [183] Carlson ML, Beatty CW, Neff BA et al. Skull base manifestations of Camurati-Engelmann disease. *Arch Otolaryngol - Head Neck Surg* 2010; 136: 566–575. doi:10.1001/archoto.2010.68
- [184] Kim YM, Kang E, Choi JH et al. Clinical characteristics and treatment outcomes in Camurati-Engelmann disease. *Med (United States)* 2018; 97: 1–6. doi:10.1097/MD.00000000000010309
- [185] Qin Y, Tang S, Zhen G et al. Bone-targeted delivery of TGF- β type 1 receptor inhibitor rescues uncoupled bone remodeling in Camurati-Engelmann disease. *Ann N Y Acad Sci* 2018; 1433: 29–40. doi:10.1111/nyas.13941
- [186] Lenarz TJG. Neuro-otologic early symptoms of Camurati-Engelmann disease. *Laryngol Rhinol Otol (Stuttg)* 1983; 62: 463–467
- [187] Louhichi N, Bahloul E, Marrakchi S et al. Thyroid involvement in Chanarin-Dorfman syndrome in adults in the largest series of patients carrying the same founder mutation in ABHD5 gene. *Orphanet J Rare Dis* 2019; 14: 1–8. doi:10.1186/s13023-019-1095-4

- [188] Faruqi T, Dhawan N, Bahl J et al. Molecular, phenotypic aspects and therapeutic horizons of rare genetic bone disorders. *Biomed Res Int* 2014; 2014. doi:10.1155/2014/670842
- [189] Sun GH, Samy RN, Tinkle BT et al. Imaging Case of the Month Craniometaphyseal Dysplasia-Induced Hearing Loss 2011; 9–10
- [190] Vasu CK, Rajendran VR, Regi George AN et al. Progressive facial disfigurement and deafness in craniometaphyseal dysplasia. *Indian J Pediatr* 2006; 73: 1105 doi:10.1007/bf02763055
- [191] Haffner D, Emma F, Eastwood DM et al. Clinical practice recommendations for the diagnosis and management of X-linked hypophosphataemia. *Nat Rev Nephrol* 2019; 15: 435–455. doi:10.1038/s41581-019-0152-5
- [192] Morava E, Kühnisch J, Drijvers JM et al. Autosomal recessive mental retardation, deafness, ankylosis, and mild hypophosphatemia associated with a novel ANKH mutation in a consanguineous family. *J Clin Endocrinol Metab* 2011; 96: 189–198. doi:10.1210/jc.2010-1539
- [193] Kyriakou K, Lederer CW, Kleanthous M et al. Acid ceramidase depletion impairs neuronal survival and induces morphological defects in neurites associated with altered gene transcription and sphingolipid content. *Int J Mol Sci* 2020; 21: 1–24. doi:10.3390/ijms21051607
- [194] Yu FPS, Amintas S, Levade T et al. Acid ceramidase deficiency: Farber disease and SMA-PME. *Orphanet J Rare Dis* 2018; 13: 1–19. doi:10.1186/s13023-018-0845-z
- [195] Pignolo RJ, Wang H, Kaplan FS. Fibrodysplasia Ossificans Progressiva (FOP): A Segmental Progeroid Syndrome. *Front Endocrinol (Lausanne)* 2020; 10: 1–8. doi:10.3389/fendo.2019.00908
- [196] Kaplan FS, Kobori JA, Orellana C et al. Multi-system involvement in a severe variant of fibrodysplasia ossificans progressiva (ACVR1 c.772G>A; R258G): A report of two patients. *Am J Med Genet Part A* 2015; 167: 2265–2271. doi:10.1002/ajmg.a.37205
- [197] Jaeken J, Vleugels W, Régál L et al. RFT1-CDG: Deafness as a novel feature of congenital disorders of glycosylation. *J Inher Metab Dis* 2009; 32: 335–338. doi:10.1007/s10545-009-1297-3
- [198] Kościelak J. Congenital disorders of glycosylation. *Handb Carbohydr Eng* 2005; 6: 99–140. doi:10.21037/atm.2018.10.45
- [199] Mohamed M, Guillard M, Wortmann SB et al. Clinical and diagnostic approach in unsolved CDG patients with a type 2 transferrin pattern. *Biochim Biophys Acta - Mol Basis Dis* 2011; 1812: 691–698. doi:10.1016/j.bbadis.2011.02.011
- [200] Sedel F, Challe G, Mayer JM et al. Thiamine responsive pyruvate dehydrogenase deficiency in an adult with peripheral neuropathy and optic neuropathy. *J Neurol Neurosurg Psychiatry* 2008; 79: 846–847. doi:10.1136/jnnp.2007.136630
- [201] Naito E, Ito M, Yokota I et al. Thiamine-responsive pyruvate dehydrogenase deficiency in two patients caused by a point mutation (F205L and L216F) within the thiamine pyrophosphate binding region. *Biochim Biophys Acta - Mol Basis Dis* 2002; 1588: 79–84. doi:10.1016/S0925-4439(02)00142-4
- [202] Sun A. Lysosomal storage disease overview. *Ann Transl Med* 2018; 6: 476. doi:10.21037/atm.2018.11.39
- [203] D'Avanzo F, Rigon L, Zanetti A et al. Mucopolysaccharidosis type II: One hundred years of research, diagnosis, and treatment. *Int J Mol Sci* 2020; 21. doi:10.3390/ijms21041258
- [204] King KA, Gordon-Salant S, Yanjanin N et al. Auditory Phenotype of Niemann-Pick Disease, Type C1. *Ear Hear* 2014; 35: doi:10.1097/AUD.0b013e3182a362b8
- [205] Lipari Pinto P, Machado C, Janeiro P et al. Ngly1 deficiency—a rare congenital disorder of deglycosylation. *JIMD Rep* 2020; 53: 2–9. doi:10.1002/jimd.12108
- [206] Rosa RFM, da Silva AP, Goetze TB et al. Ear abnormalities in patients with oculo-auriculo-vertebral spectrum (Goldenhar syndrome). *Braz J Otorhinolaryngol* 2011; 77: 455–460. doi:10.1590/S1808-86942011000400008
- [207] Vargas-Poussou R, Houillier P, Le Pottier N et al. Genetic Investigation of Autosomal Recessive Distal Renal Tubular Acidosis: Evidence for Early Sensorineural Hearing Loss Associated with Mutations in the ATP6V0A4 Gene. *J Am Soc Nephrol* 2006; 17: 1437–1443. doi:10.1681/ASN.2005121305
- [208] Hanisch F, Rahne T, Plontke SK. Prevalence of hearing loss in patients with late-onset Pompe disease: Audiological and otological consequences. *Int J Audiol* 2013; 52: 816–823. doi:10.3109/14992027.2013.840932
- [209] Oysu C, Aslan I, Basaran B et al. The site of the hearing loss in Refsum's disease. *Int J Pediatr Otorhinolaryngol* 2001; 61: 129–134. doi:10.1016/S0165-5876(01)00559-6
- [210] Vandana VP, Bindu PS, Nagappa M et al. Audiological findings in Infantile Refsum disease. *Int J Pediatr Otorhinolaryngol* 2015; 79: 1366–1369. doi:10.1016/j.ijporl.2015.05.023
- [211] Bamiou D-E, Spraggs PRD, Gibberd FB et al. Hearing loss in adult Refsum's disease. *Clin Otolaryngol Allied Sci* 2003; 28: 227–230. doi:10.1046/j.1365-2273.2003.00694.x
- [212] Liberman MC, Tartaglino E, Fleming JC et al. Deletion of SLC19A2, the high affinity thiamine transporter, causes selective inner hair cell loss and an auditory neuropathy phenotype. *JARO - J Assoc Res Otolaryngol* 2006; 7: 211–217. doi:10.1007/s10162-006-0035-x
- [213] Di Giaimo R, Riccio M, Santi S et al. Targeted disruption of Slc19a2, the gene encoding the high-affinity thiamine transporter Thtr-1, causes diabetes mellitus, sensorineural deafness and megaloblastosis in mice. *Hum Mol Genet* 2002; 11: 2951–2960. doi:10.1093/hmg/11.23.2951
- [214] Mohamed FE, Al Sorkhy M, Ghattas MA et al. A Novel Homozygous Missense Variant in the NAGA Gene with Extreme Intrafamilial Phenotypic Heterogeneity. *J Mol Neurosci* 2020; 70: 45–55. doi:10.1007/s12031-019-01398-6
- [215] Rodríguez-Pazos L, Ginarte M, Vega A et al. Autosomal recessive congenital ichthyosis. *Actas Dermosifiliogr* 2013; 104: 270–284. doi:10.1016/j.adengl.2011.11.021
- [216] Fekete R. Xeroderma pigmentosum/De Sanctis-Cacchione syndrome: Unusual cause of ataxia. *Case Rep Neurol* 2014; 6: 83–87. doi:10.1159/000362115
- [217] Rahbar Z, Naraghi M. De Sanctis-Cacchione syndrome: A case report and literature review. *Int J Women's Dermatology* 2015; 1: 136–139. doi:10.1016/j.ijwd.2015.05.003
- [218] Kale K, Ghonge N, Kaul A. Prenatal diagnosis of congenital harlequin ichthyosis with fetal MRI. *Indian J Radiol Imaging* 2019; 29: 448. doi:10.4103/ijri.IJRI_105_19
- [219] Cammarata-Scalisi F, Willoughby CE, Cárdenas Tadich A et al. Clinical, etiopathogenic, and therapeutic aspects of KID syndrome. *Dermatol Ther*. 2020; doi:10.1111/dth.13507
- [220] Shuja Z, Li L, Gupta S et al. Connexin26 mutations causing palmo-plantar keratoderma and deafness interact with connexin43, modifying gap junction and hemichannel properties. *J Invest Dermatol* 2016; 136: 225–235. doi:10.1038/JID.2015.389
- [221] Yoon HK, Sargent MA, Prendiville JS et al. Cerebellar and cerebral atrophy in trichothiodystrophy. *Pediatr Radiol* 2005; 35: 1019–1023. doi:10.1007/s00247-005-1495-6
- [222] Valverde D, Alvarez-Satta M, Castro-Sánchez S. Alström syndrome: current perspectives. *Appl Clin Genet* 2015; 171. doi:10.2147/ATCG.S56612
- [223] Mittal R, Patel K, Mittal J et al. Association of PRPS1 Mutations with Disease Phenotypes. *Dis Markers* 2015; 2015: 1–7. doi:10.1155/2015/127013
- [224] Barakat AJ, Raygada M, Rennert OM. Barakat syndrome revisited. *Am J Med Genet Part A* 2018; 176: 1341–1348. doi:10.1002/ajmg.a.38693

- [225] Sheehan-Rooney K, Swartz ME, Zhao F et al. Ahsa1 and Hsp90 activity confers more severe craniofacial phenotypes in a zebrafish model of hypoparathyroidism, sensorineural deafness and renal dysplasia (HDR). *DMM Dis Model Mech* 2013; 6: 1285–1291. doi:10.1242/dmm.011965
- [226] Husson H, Bukanov NO, Moreno S et al. Correction of cilia structure and function alleviates multi-organ pathology in Bardet-Biedl syndrome mice. *Hum Mol Genet* 2020; 00: 1–15. doi:10.1093/hmg/ddaa138
- [227] M'Hamdi O, Ouertani I, Chaabouni-Bouhamed H. Update on the genetics of bardet-biedl syndrome. *Mol Syndromol* 2014; 5: 51–56. doi:10.1159/000357054
- [228] Datta P, Ruffcorn A, Seo S. Limited time window for retinal gene therapy in a preclinical model of ciliopathy. *Hum Mol Genet* 2020; 29: 2337–2352. doi:10.1093/hmg/ddaa124
- [229] Gajendragadkar A, Bhamkar R. Antenatal Bartter's syndrome with sensorineural deafness. *Indian J Nephrol* 2009; 19: 23. doi:10.4103/0971-4065.50677
- [230] Miyamura N, Matsumoto K, Taguchi T et al. Atypical Bartter Syndrome with Sensorineural Deafness with G47R Mutation of the β -Subunit for ClC-Ka and ClC-Kb Chloride Channels, Barttin. *J Clin Endocrinol Metab* 2003; 88: 781–786. doi:10.1210/jc.2002-021398
- [231] Zhang J, Duo L, Lin Z et al. Exome sequencing reveals novel BCS1L mutations in siblings with hearing loss and hypotrichosis. *Gene* 2015; 566: 84–88. doi:10.1016/j.gene.2015.04.039
- [232] Min J, Mao B, Wang Y et al. A Heterozygous Novel Mutation in TFAP2A Gene Causes Atypical Branchio-Oculo-Facial Syndrome With Isolated Coloboma of Choroid: A Case Report. *Front Pediatr* 2020; 8: 1–6. doi:10.3389/fped.2020.00380
- [233] Milunsky JM, Maher TA, Zhao G et al. TFAP2A Mutations Result in Branchio-Oculo-Facial Syndrome. *Am J Hum Genet* 2008; 82: 1171–1177. doi:10.1016/j.ajhg.2008.03.005
- [234] Klingbeil KD, Greenland CM, Arslan S et al. Novel EYA1 variants causing Branchio-oto-renal syndrome. *Int J Pediatr Otorhinolaryngol* 2017; 98: 59–63. doi:10.1016/j.ijporl.2017.04.037
- [235] Shah AM, Krohn P, Baxi AB et al. Six1 proteins with human branchio-oto-renal mutations differentially affect cranial gene expression and otic development. *DMM Dis Model Mech* 2020; 13 doi:10.1242/dmm.043489
- [236] Hsu A, Desai N, Paldino MJ. The Unwound Cochlea: A Specific Imaging Marker of Branchio-Oto-Renal Syndrome. *AJNR Am J Neuroradiol* 2018; 39: 2345–2349. doi:10.3174/ajnr.A5856
- [237] Boudhina T, Yedes A, Khiari S et al. Familial syndrome combining short stature, microcephaly, mental deficiency, seizures, hearing loss, and skin lesions. A new syndrome. *ediatr (Paris)* 1990; 37: 399–403
- [238] Hasan MR, Takatalo M, Ma H et al. RAB23 coordinates early osteogenesis by repressing FGF10-pERK1/2 and GLI1. *Elife* 2020; 9: 1–26. doi:10.7554/eLife.55829
- [239] Tarhan E, Oğuz H, Şafak MA et al. The Carpenter syndrome phenotype. *Int J Pediatr Otorhinolaryngol* 2004; 68: 353–357. doi:10.1016/j.ijporl.2003.10.009
- [240] Twigg SRF, Lloyd D, Jenkins D et al. Mutations in multidomain protein MEGF8 identify a carpenter syndrome subtype associated with defective lateralization. *Am J Hum Genet* 2012; 91: 897–905. doi:10.1016/j.ajhg.2012.08.027
- [241] Bérubé-Simard FA, Pilon N. Molecular dissection of CHARGE syndrome highlights the vulnerability of neural crest cells to problems with alternative splicing and other transcription-related processes. *Transcription* 2019; 10: 21–28. doi:10.1080/21541264.2018.1521213
- [242] Karikkineth AC, Scheibye-Knudsen M, Fivenson E et al. Cockayne syndrome: Clinical features, model systems and pathways. *Ageing Res Rev* 2017; 33: 3–17. doi:10.1016/j.arr.2016.08.002
- [243] Morris DP, Alian W, Maessen H et al. Cochlear implantation in Cockayne syndrome: Our experience of two cases with different outcomes. *Laryngoscope* 2007; 117: 939–943. doi:10.1097/MLG.0b013e3180325106
- [244] Hanauer A, Young ID. Coffin-Lowry syndrome: Clinical and molecular features. *J Med Genet* 2002; 39: 705–713. doi:10.1136/jmg.39.10.705
- [245] Rosanowski F, Eysholdt U. Late-Onset Sensorineural Hearing Loss in Coffin-Lowry Syndrome 1998; 224–226
- [246] Vasileiou G, Vergarajauregui S, Ende S et al. Mutations in the BAF-Complex Subunit DPF2 Are Associated with Coffin-Siris Syndrome. *Am J Hum Genet* 2018; 102: 468–479. doi:10.1016/j.ajhg.2018.01.014
- [247] Schrier SA, Bodurtha JN, Burton B et al. The Coffin-Siris syndrome: A proposed diagnostic approach and assessment of 15 overlapping cases. *Am J Med Genet Part A* 2012; 158A: 1865–1876. doi:10.1002/ajmg.a.35415
- [248] Sarogni P, Pallotta MM, Musio A. Cornelia de Lange syndrome: From molecular diagnosis to therapeutic approach. *J Med Genet* 2020; 57: 289–295. doi:10.1136/jmedgenet-2019-106277
- [249] Avagliano L, Parenti I, Grazioli P et al. Chromatinopathies: A focus on Cornelia de Lange syndrome. *Clin Genet* 2020; 97: 3–11. doi:10.1111/cge.13674
- [250] Marchisio P, Selicorni A, Bianchini S et al. Audiological findings, genotype and clinical severity score in Cornelia de Lange syndrome. *Int J Pediatr Otorhinolaryngol* 2014; 78: 1045–1048. doi:10.1016/j.ijporl.2014.03.038
- [251] Kurkiewicz A, Cooper A, McIlwaine E et al. Towards development of a statistical framework to evaluate myotonic dystrophy type 1 mRNA biomarkers in the context of a clinical trial. *PLoS One* 2020; 15: 1–19. doi:10.1371/journal.pone.0231000
- [252] Van Vliet J, Tieleman AA, Van Engelen BGM et al. Hearing impairment in patients with myotonic dystrophy type 2. *Neurology* 2018; 90: e615–e622. doi:10.1212/WNL.0000000000004963
- [253] Balatsouras DG, Felekis D, Panas M et al. Inner ear dysfunction in myotonic dystrophy type 1. *Acta Neurol Scand* 2013; 127: 337–343. doi:10.1111/ane.12020
- [254] Khalifa O, Al-Sahlawi Z, Imtiaz F et al. Variable expression pattern in Donnai-Barrow syndrome: Report of two novel LRP2 mutations and review of the literature. *Eur J Med Genet* 2015; 58: 293–299. doi:10.1016/j.ejmg.2014.12.008
- [255] Kantarci S, Al-Gazali L, Hill RS et al. Mutations in LRP2, which encodes the multiligand receptor megalin, cause Donnai-Barrow and facio-otico-acoustico-renal syndromes. *Nat Genet* 2007; 39: 957–959. doi:10.1038/ng2063
- [256] Campeau PM, Kasperaviciute D, Lu JT et al. The genetic basis of DOORS syndrome: an exome-sequencing study. *Lancet Neurol* 2014; 13: 44–58. doi:10.1016/S1474-4422(13)70265-5
- [257] Campeau PM, Hennekam RC, Aftimos S et al. DOORS syndrome: Phenotype, genotype and comparison with coffin-siris syndrome. *Am J Med Genet Part C Semin Med Genet* 2014; 166: 327–332. doi:10.1002/ajmg.c.31412
- [258] Pradhan N, Shilawant J, Akkamahadevi CH et al. Ehlers-Danlos syndrome with huge bladder diverticulum in pregnancy – A rare and interesting case report. *Eur J Obstet Gynecol Reprod Biol* 2020; 250: 231–234. doi:10.1016/j.ejogrb.2020.05.001
- [259] Ritelli M, Dordoni C, Cinquina V et al. Expanding the clinical and mutational spectrum of B4GALT7-spondylodysplastic Ehlers-Danlos syndrome. *Orphanet J Rare Dis* 2017; 12: 1–7. doi:10.1186/s13023-017-0704-3
- [260] Fryns JP. Fountain's syndrome: Mental retardation, sensorineural deafness, skeletal abnormalities, and coarse face with full lips. *J Med Genet* 1989; 26: 722–724. doi:10.1136/jmg.26.11.722

- [261] Poling MI, Dufresne CR, Chamberlain RL. Findings, Phenotypes, Diagnostic Accuracy, and Treatment in Freeman-Burian Syndrome. *J Craniofac Surg* 2020; 31: 1063–1069. doi:10.1097/SCS.00000000000006299
- [262] Regev M, Pode-Shakked B, Jacobson JM et al. Phenotype variability in Hajdu-Cheney syndrome. *Eur J Med Genet* 2019; 62: 35–38. doi:10.1016/j.ejmg.2018.04.015
- [263] Abu-Amero KK, Hagr A AI, Almomani MO et al. HOXA1 mutations are not commonly associated with non-syndromic deafness. *Can J Neurol Sci* 2014; 41: 448–451. doi:10.1017/S0317167100018473
- [264] Lai WF, Wong WT. Progress and trends in the development of therapies for Hutchinson–Gilford progeria syndrome. *Aging Cell* 2020; 19: 1–17. doi:10.1111/ace.13175
- [265] Liu S, Wang Z, Jiang J et al. Severe forms of Johanson-Blizzard syndrome caused by two novel compound heterozygous variants in UBR1: Clinical manifestations, imaging findings and molecular genetics. *Pancreatol* 2020; 20: 562–568. doi:10.1016/j.pan.2020.01.007
- [266] Friez MJ, Brooks SS, Stevenson RE et al. HUWE1 mutations in Juberg-Marsidi and Brooks syndromes: The results of an X-chromosome exome sequencing study. *BMJ Open* 2016; 6: 1–9. doi:10.1136/bmjopen-2015-009537
- [267] Cuvertino S, Hartill V, Colyer A et al. A restricted spectrum of missense KMT2D variants cause a multiple malformations disorder distinct from Kabuki syndrome. *Genet Med* 2020; 22: 867–877. doi:10.1038/s41436-019-0743-3
- [268] Stamou MI, Georgopoulos NA. Kallmann syndrome: phenotype and genotype of hypogonadotropic hypogonadism. *Metabolism* 2018; 86: 124–134. doi:10.1016/j.metabol.2017.10.012
- [269] Finsterer J, Winklehner M, Stöllberger C et al. Unusual Phenotype and Disease Trajectory in Kearns–Sayre Syndrome. *Case Rep Neurol Med* 2020; 2020: 1–6. doi:10.1155/2020/7368527
- [270] Weidauer H, Lenarz T. Kearns-Sayre syndrome from the otorhinolaryngologic viewpoint. *Laryngol Rhinol Otol (Stuttg)* 1984; 63: 141–146
- [271] Frikha R. Klippel-Feil syndrome: a review of the literature. *Clin Dysmorphol* 2020; 29: 35–37. doi:10.1097/MCD.0000000000000301
- [272] Mayer B, Lenarz T, Haels J. Cervically-induced symptoms of the Klippel-Feil syndrome. *Laryngol Rhinol Otol (Stuttg)* 1984; 63: 364–370
- [273] Husain Q, Cho J, Neugarten J et al. Surgery of the head and neck in patient with Kniest dysplasia: Is wound healing an issue? *Int J Pediatr Otorhinolaryngol* 2017; 93: 97–99. doi:10.1016/j.ijporl.2016.12.025
- [274] Hey Ryu Y, Kyun Chae J, Kim JW et al. Lacrimo-auriculo-dento-digital syndrome: A novel mutation in a Korean family and review of literature. *Mol Genet Genomic Med* 2020; 1–11. doi:10.1002/mgg3.1412
- [275] Muzio MR, Cascella M, Al Khalili Y. Landau Kleffner Syndrome. 2020; Im Internet: <http://www.ncbi.nlm.nih.gov/pubmed/31613525>
- [276] Kim J, Kim MR, Kim HJ et al. LEOPARD syndrome with PTPN11 gene mutation showing six cardinal symptoms of LEOPARD. *Ann Dermatol* 2011; 23: 232–235. doi:10.5021/ad.2011.23.2.232
- [277] Levy J, Chung W, Garzon M et al. Congenital myopathy, recurrent secretory diarrhea, bullous eruption of skin, microcephaly, and deafness: A new genetic syndrome? *Am J Med Genet* 2003; 116: 20–25. doi:10.1002/ajmg.a.10072
- [278] Griffith AJ, Sprunger LK, Sirko-Osadsa DA et al. Marshall Syndrome Associated with a Splicing Defect at the COL11A1 Locus. *Am J Hum Genet* 1998; 62: 816–823. doi:10.1086/301789
- [279] Rawle M, Larner A. NARP Syndrome: A 20-Year Follow-Up. *Case Rep Neurol* 2013; 5: 204–207. doi:10.1159/000357518
- [280] Strubbe EH, Cremers CWRJ, Dikkers FG et al. Hearing loss and the Mayer-Rokitansky-Kuster-Hauser syndrome. *Am J Otol* 1994; 15: 431–436
- [281] Boyce AM, Collins MT. Fibrous Dysplasia/McCune-Albright Syndrome: A Rare, Mosaic Disease of Gαs Activation. *Endocr Rev* 2020; 41: 345–370. doi:10.1210/edrv/bnz011
- [282] Di Stadio A, Pegoraro V, Giarretta L et al. Hearing impairment in MELAS: New prospective in clinical use of microRNA, a systematic review. *Orphanet J Rare Dis* 2018; 13: 1–9. doi:10.1186/s13023-018-0770-1
- [283] Handzel O, Ungar OJ, Lee DJ et al. Temporal bone histopathology in MELAS syndrome. *Laryngoscope Invest Otolaryngol* 2020; 5: 152–156. doi:10.1002/liv.2.344
- [284] Tsutsumi T, Nishida H, Noguchi Y et al. Audiological findings in patients with myoclonic epilepsy associated with ragged-red fibres. *J Laryngol Otol* 2001; 115. doi:10.1258/0022215011909224
- [285] Picciolini O, Porro M, Cattaneo E et al. Moebius syndrome: clinical features, diagnosis, management and early intervention. *Ital J Pediatr* 2016; 42: 56. doi:10.1186/s13052-016-0256-5
- [286] Gürsoy S, Hazan F, Öztürk T et al. Novel Ocular and Inner Ear Anomalies in a Patient with Myhre Syndrome. *Mol Syndromol* 2020; 10: 339–343. doi:10.1159/000504829
- [287] Melkonieni M, Brunner HG, Manouvrier S et al. Autosomal recessive disorder otospondylomegalapiphyseal dysplasia is associated with loss-of-function mutations in the COL11A2 gene. *Am J Hum Genet* 2000; 66: 368–377. doi:10.1086/302750
- [288] Koffler T, Ushakov K, Avraham KB. Genetics of Hearing Loss. *Otolaryngol Clin North Am* 2015; 48: 1041–1061. doi:10.1016/j.otc.2015.07.007
- [289] Gettelfinger J, Dahl J. Syndromic Hearing Loss: A Brief Review of Common Presentations and Genetics. *J Pediatr Genet* 2018; 07: 001–008. doi:10.1055/s-0037-1617454
- [290] Desai U, Rosen H, Mulliken JB et al. Audiologic Findings in Pfeiffer Syndrome. *J Craniofac Surg* 2010; 21: 1411–1418. doi:10.1097/SCS.0b013e3181ebcf58
- [291] Tarailo-Graovac M, Sinclair G, Stockler-Ipsiroglu S et al. The genotypic and phenotypic spectrum of PIGA deficiency. *Orphanet J Rare Dis* 2015; 10. doi:10.1186/s13023-015-0243-8
- [292] Knowles MR, Zariwala M, Leigh M. Primary Ciliary Dyskinesia. *Clin Chest Med* 2016; 37: 449–461. doi:10.1016/j.ccm.2016.04.008
- [293] Chang Q, Wang J, Li Q et al. Virally mediated Kcnq1 gene replacement therapy in the immature scala media restores hearing in a mouse model of human Jervell and Lange-Nielsen deafness syndrome. *EMBO Mol Med* 2015; 7: 1077–1086. doi:10.15252/emmm.201404929
- [294] Zhang Q, Liang D, Yue Y et al. Axenfeld-Rieger syndrome-associated mutants of the transcription factor FOXC1 abnormally regulate NKX2-5 in model zebrafish embryos. *J Biol Chem* 2020; 2: jbc.RA120.013287. doi:10.1074/jbc.RA120.013287
- [295] Wakeling EL, Brioude F, Lokulo-Sodipe O et al. Diagnosis and management of Silver–Russell syndrome: first international consensus statement. *Nat Rev Endocrinol* 2017; 13: 105–124. doi:10.1038/nrendo.2016.138
- [296] Hoischen A, Van Bon BWM, Gilissen C et al. De novo mutations of SETBP1 cause Schinzel-Giedion syndrome. *Nat Genet* 2010; 42: 483–485. doi:10.1038/ng.581
- [297] Tsang SH, Aycinena ARP, Sharma T. Ciliopathy: Senior-Løken Syndrome 2018; 175–178. doi:10.1007/978-3-319-95046-4_34
- [298] Kaur A, Dhir SK, Goyal G et al. Senior loken syndrome. *J Clin Diagnostic Res* 2016; 10: SD03–SD04. doi:10.7860/JCDR/2016/21832.8816

- [299] Abdelhadi O, Iancu D, Stanescu H et al. EAST syndrome: Clinical, pathophysiological, and genetic aspects of mutations in KCNJ10. *Rare Dis (Austin, Tex)* 2016; 4: e1195043 doi:10.1080/21675511.2016.1195043
- [300] Gaudreau P, Zizak V, Gallagher TQ. The otolaryngologic manifestations of Sotos syndrome. *Int J Pediatr Otorhinolaryngol* 2013; 77: 1861–1863. doi:10.1016/j.ijporl.2013.08.029
- [301] Boczek NJ, Kruisselbrink T, Cousin MA et al. Multigenerational pedigree with STAR syndrome: A novel FAM58A variant and expansion of the phenotype. *Am J Med Genet Part A* 2017; 173: 1328–1333. doi:10.1002/ajmg.a.38113
- [302] Smith SD, Kelley PM, Kenyon JB et al. Tietz syndrome (hypopigmentation/deafness) caused by mutation of MITF. *J Med Genet* 2000; 37: 446–448. doi:10.1136/jmg.37.6.446
- [303] Liang Y, Shen D, Cai W. Two coding single nucleotide polymorphisms in the SALL1 gene in Townes-Brocks syndrome: a case report and review of the literature. *J Pediatr Surg* 2008; 43: 391–393. doi:10.1016/j.jpedsurg.2007.09.079
- [304] Géléoc GCS, El-Amraoui A. Disease mechanisms and gene therapy for Usher syndrome. *Hear Res* 2020; 394: 107932 doi:10.1016/j.heares.2020.107932
- [305] Hedberg-Oldfors C, Darin N, Oldfors A. Muscle pathology in Vici syndrome-A case study with a novel mutation in EPG5 and a summary of the literature. *Neuromuscul Disord* 2017; 27: 771–776. doi:10.1016/j.nmd.2017.05.005
- [306] Song J, Feng Y, Acke FR et al. Hearing loss in Waardenburg syndrome: a systematic review. *Clin Genet* 2016; 89: 416–425. doi:10.1111/cge.12631
- [307] Kontorinis G, Lenarz T, Giourgas A et al. Outcomes and Special Considerations of Cochlear Implantation in Waardenburg Syndrome. *Otol Neurotol* 2011; 32: 951–955. doi:10.1097/MAO.0b013e31821b3ae3
- [308] La Morgia C, Maresca A, Amore G et al. Calcium mishandling in absence of primary mitochondrial dysfunction drives cellular pathology in Wolfram Syndrome. *Sci Rep* 2020; 10: 1–15. doi:10.1038/s41598-020-61735-3
- [309] Samara A, Rahn R, Neyman O et al. Developmental hypomyelination in Wolfram syndrome: New insights from neuroimaging and gene expression analyses. *Orphanet J Rare Dis* 2019; 14: 1–14. doi:10.1186/s13023-019-1260-9
- [310] Elumalai V, Pasrija D. Zellweger Syndrome. 2020; Im Internet: <http://www.ncbi.nlm.nih.gov/pubmed/32809511>
- [311] Sclafani AP, DeDio RM, Hendrix RA. The Chiari-I malformation. *Ear Nose Throat J* 1991; 70: 208–212. Im Internet: <http://www.ncbi.nlm.nih.gov/pubmed/1874153>
- [312] Barsottini OG, Pedrosa JL, Martins CR et al. Deafness and Vestibulopathy in Cerebellar Diseases: a Practical Approach. *Cerebellum* 2019; 18: 1011–1016. doi:10.1007/s12311-019-01042-4
- [313] Bokhari MR, Samanta D, Bokhari SRA. Canavan Disease. 2020; Im Internet: <http://www.ncbi.nlm.nih.gov/pubmed/28613566>
- [314] Roscoe RB, Elliott C, Zarros A et al. Non-genetic therapeutic approaches to Canavan disease. *J Neurol Sci* 2016; 366: 116–124. doi:10.1016/j.jns.2016.05.012
- [315] Ishiyama G, Lopez I, Baloh RW et al. Canavan's leukodystrophy is associated with defects in cochlear neurodevelopment and deafness. *Neurology* 2003; 60: 1702–1704. doi:10.1212/01.WNL.00000065893.60879.D3
- [316] Demos MK, Van Karnebeek CDM, Ross CJD et al. A novel recurrent mutation in ATP1A3 causes CAPOS syndrome. *Orphanet J Rare Dis* 2014; 9: 1–9. doi:10.1186/1750-1172-9-15
- [317] Stenshorne I, Rasmussen M, Salvanos P et al. Fever-related ataxia: A case report of CAPOS syndrome. *Cerebellum and Ataxias* 2019; 6: 3–7. doi:10.1186/s40673-019-0096-3
- [318] Rosewich H, Weise D, Ohlenbusch A et al. Phenotypic overlap of alternating hemiplegia of childhood and CAPOS syndrome. *Neurology* 2014; 83: 861–863. doi:10.1212/WNL.0000000000000735
- [319] Choi JE, Seok JM, Ahn J et al. Hidden hearing loss in patients with Charcot-Marie-Tooth disease type 1A. *Sci Rep* 2018; 8: 10335 doi:10.1038/s41598-018-28501-y
- [320] Park JG, Tischfield MA, Nugent AA et al. Loss of MAFB Function in Humans and Mice Causes Duane Syndrome, Aberrant Extraocular Muscle Innervation, and Inner-Ear Defects. *Am J Hum Genet* 2016; 98: 1220–1227. doi:10.1016/j.ajhg.2016.03.023
- [321] Weir FW, Kreicher KL, Hatch JL et al. Audiologic and otologic phenotype in children with Duane's Retraction Syndrome: A rare ophthalmologic disorder. *Int J Pediatr Otorhinolaryngol* 2016; 89: 154–158. doi:10.1016/j.ijporl.2016.08.014
- [322] Auer-Grumbach M, Bode H, Pieber TR et al. Mutations at Ser331 in the HSN type I gene SPTLC1 are associated with a distinct syndromic phenotype. *Eur J Med Genet* 2013; 56: 266–269. doi:10.1016/j.ejmg.2013.02.002
- [323] Hojo K, Kawamata T, Tanaka C et al. Inflammatory glial activation in the brain of a patient with hereditary sensory neuropathy type 1 with deafness and dementia. *Neurosci Lett* 2004; 367: 340–343. doi:10.1016/j.neulet.2004.06.030
- [324] Tyler GK, Martin TPC, Baguley DM. Systematic review of outcome of cochlear implantation in superficial siderosis. *Otol Neurotol* 2012; 33: 976–982. doi:10.1097/MAO.0b013e3182565a46
- [325] Iversen MM, Rabbitt RD. Biomechanics of Third Window Syndrome. *Front Neurol* 2020; 11 doi:10.3389/fneur.2020.00891
- [326] Marinelli JP, Lohse CM, Carlson ML. Incidence of Intralabyrinthine Schwannoma. *Otol Neurotol* 2018; 39: 1191–1194. doi:10.1097/MAO.0000000000001875
- [327] Plontke SK, Rahne T, Pfister M et al. Intralabyrinthine schwannomas: Surgical management and hearing rehabilitation with cochlear implants. *HNO* 2017; 65: 136–148. doi:10.1007/s00106-017-0364-6
- [328] Plontke SK, Fröhlich L, Wagner L et al. How Much Cochlea Do You Need for Cochlear Implantation? *Otol Neurotol* 2020; 41: 694–703. doi:10.1097/MAO.0000000000002614
- [329] Orsini A, Valetto A, Bertini V et al. The best evidence for progressive myoclonic epilepsy: A pathway to precision therapy. *Seizure* 2019; 71: 247–257. doi:10.1016/j.seizure.2019.08.012

