

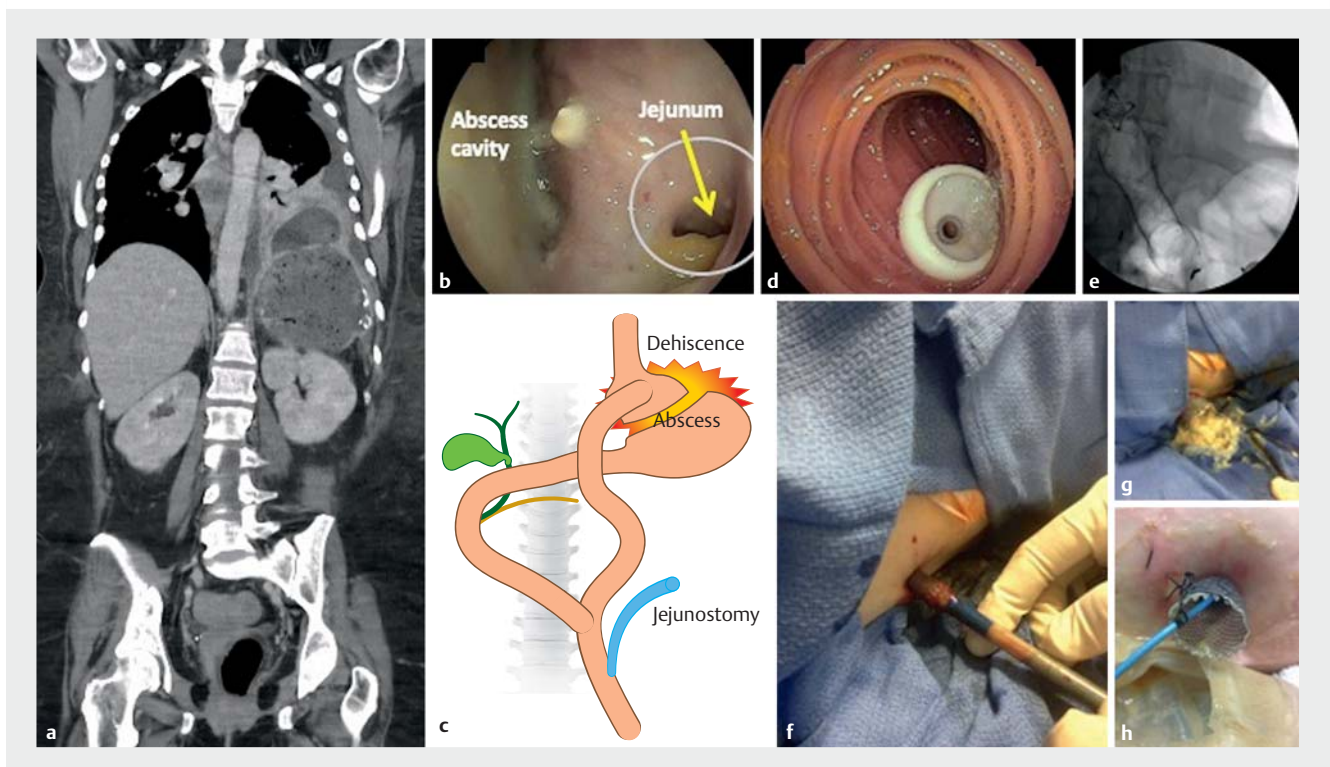
Extreme endoscopy: direct jejunostomy, re-anastomosis of bowel, percutaneous assisted transprosthetic endoscopic drainage in Roux-en-Y gastric bypass

A 52-year-old female with history of Roux-en-Y gastric bypass underwent resection of a huge cystic tumor of the pancreas. Postoperatively an amylase-rich retroperitoneal fluid collection was noted. The patient was referred for double-balloon endoscopic retrograde cholangiopancreatography (ERCP) for a suspected pancreatic duct leak. The patient had anemia, anasarca, and severe malnutrition (albumin level of 1.8g/dl – normal range 3.5 to 4.6g/dl; hemoglobin 9g/dl – normal range 11.5 to 14.5). During endoscopy performed under general anes-

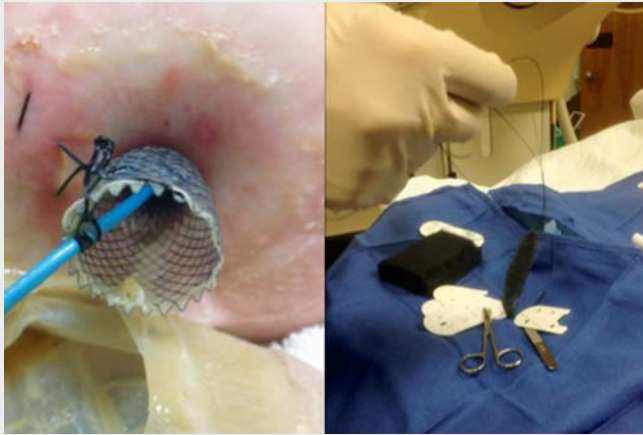thesia, it became evident that the jejunal esophageal anastomosis was disrupted, communicating with a large pleuroperitoneal abscess. At this time a change in plans became mandatory.

First, a direct, double-balloon enteroscopy (DPE) jejunostomy was performed to secure nutritional support (► Fig. 1, ► Video 1). Second, a Guardus overtube (STERIS Endoscopy, Mentor, Ohio, USA) was inserted per-orally into the abscess cavity and the therapeutic gastroscope was passed numerous times to remove copious amounts of pus and food using

extraction devices. Third, the disrupted bowel was re-anastomosed endoscopically using a fully covered self-expanding metal stent (FCSEMS) (Cook Medical, Bloomington, Indiana, USA). In order to prevent stent migration, an over-the-scope clip was used to anchor the FCSEMS in the esophagus. And finally, percutaneous assisted transprosthetic endoscopic therapy with sponge insertion was used to drain the abscessed cavity (► Fig. 1, ► Video 1). Several sponge exchanges were performed through the stent to finally collapse the cavity. The



► **Fig. 1** Disrupted gastrojejunal anastomosis communicating with a retroperitoneal cavity after resection of large mucinous cystic tumor of the pancreas. **a** Large retroperitoneal and pleural abscess. **b** Dehiscence of esophagojejunal anastomosis and remaining jejunal lumen (circle and arrow). **c** Schematic of post-surgical Roux-en-Y anatomy, dehiscence of the esophagojejunal anastomosis, abscess and direct double-balloon enteroscopy jejunostomy. **d** Jejunostomy using double balloon enteroscopy technique. **e** Re-anastomosis of esophagus and jejunum using esophageal fully covered self-expanding metal stent (FCSEMS), then anchored with an 11/6t over-the-scope-clip. **f** Percutaneous assisted transprosthetic endoscopic therapy to drain huge cavity. First step was to dilate the tract with an esophageal dilation balloon up to 15 mm, and then insert an esophageal FCSEMS. **g** Upon expansion of the FCSEMS, a large amount of debris and pus exited the pleura and peritoneum. **h** After percutaneous assisted transprosthetic endoscopic therapy, a Ligoury nasobiliary drain was advanced over a wire into the necrotic cavity across the FCSEMS. A sponge had been attached to the drain to perform endosponge vacuum therapy.



Video 1 Direct jejunostomy, re-anastomosis of bowel, and percutaneous assisted transprosthetic endoscopic therapy in patient with Roux-en-Y gastric bypass with retroperitoneal abscess.

stent used to perform the percutaneous assisted transprosthetic endoscopic therapy was removed after 4 weeks. At 2 months the esophagojejunal re-anastomosis FCSEMS was removed and the small remnant entero-pleural fistula was closed using an over-the-scope clip (12/6t, Ovesco, USA).

This case is an example of extreme endoscopy, where multiple endoscopes (enteroscopy, therapeutic gastroscope, slim gastroscope), instruments, skills and techniques such as DPE jejunostomy [1], anchoring of FCSEMS [2], and percutaneous assisted transprosthetic endoscopic therapy [3] became mandatory to solve various complex post-operative adverse events in a poor surgical candidate, leading to complete resolution of the all life-threatening complications, including disrupted esophagojejunostomy, pleuro-peritoneal abscess, abdominal sepsis, malnutrition and esophagopleural fistula.

Endoscopy_UCTN_Code_TTT_1AO_2AI

Competing interests

Klaus Mönkemüller has received honoraria from Cook Medical, USA and Ovesco, Tübingen, Germany, for giving academic lectures.

The authors

Álvaro Martínez-Alcalá García^{1,2}, Ivan Jovanovic^{2,3}, Ali M. Ahmed², Marco D'Assuncao⁴, Thomas Kröner⁵, Klaus Mönkemüller^{2,3,6}

- 1 Department of Gastroenterology, Hospital Universitario Infanta Leonor, Madrid, Spain
- 2 Basil I. Hirschowitz Endoscopic Center of Excellence, University of Alabama at Birmingham, Alabama, USA
- 3 University of Belgrade, Belgrade, Serbia
- 4 Department of Surgery, Hospital Sirio Libanes, Sao Paulo, Brasil
- 5 Division of Gastroenterology, Mayo Clinic, Jacksonville, USA
- 6 Department of Gastroenterology, Ameos Teaching University Hospital (Otto-von-Guericke University – Magdeburg), Halberstadt, Germany

Corresponding author

Klaus Mönkemüller, MD

Director of Endoscopy, Division of Gastroenterology, University Teaching Hospital – Ameos Klinikum Halberstadt, Gleimstraße 5, 38820 Halberstadt, Germany
moenkemuller@yahoo.com

References

- [1] Velázquez-Aviña J, Beyer R, Díaz-Tobar CP et al. New method of direct percutaneous endoscopic jejunostomy tube placement using balloon-assisted enteroscopy with fluoroscopy. *Dig Endosc* 2015; 27: 317–322
- [2] Mudumbi S, Velázquez-Aviña J, Neumann H et al. Anchoring of self-expanding metal stents using the over-the-scope clip, and a technique for subsequent removal. *Endoscopy* 2014; 46: 1106–1109
- [3] Law R, Wong Kee Song LM et al. Single-session ERCP in patients with previous Roux-en-Y gastric bypass using percutaneous-assisted transprosthetic endoscopic therapy: a case series. *Endoscopy* 2013; 45: 671–675

Bibliography

Endoscopy 2022; 54: E13–E14
DOI 10.1055/a-1346-7877
ISSN 0013-726X
published online 16.2.2021
 © 2021. Thieme. All rights reserved.
 Georg Thieme Verlag KG, Rüdigerstraße 14,
 70469 Stuttgart, Germany

ENDOSCOPY E-VIDEOS

<https://eref.thieme.de/e-videos>



Endoscopy E-Videos is a free access online section, reporting on interesting cases and new

techniques in gastroenterological endoscopy. All papers include a high quality video and all contributions are freely accessible online.

This section has its own submission website at

<https://mc.manuscriptcentral.com/e-videos>