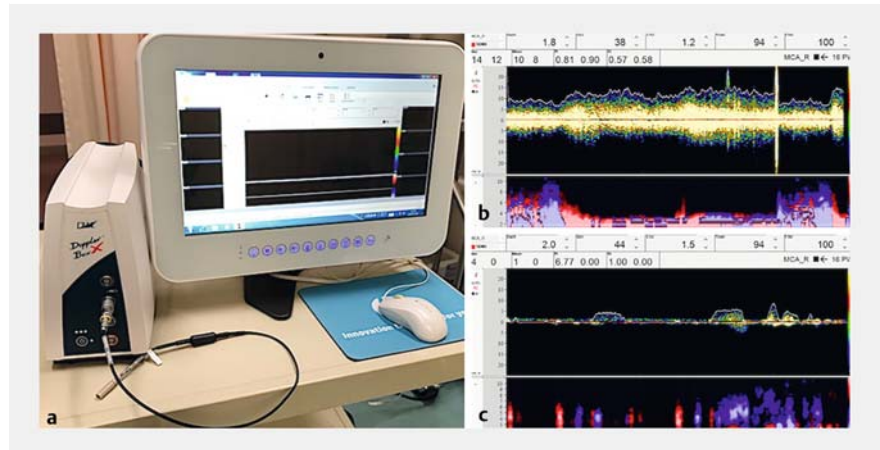


Esophageal variceal treatment using a novel Doppler probe method

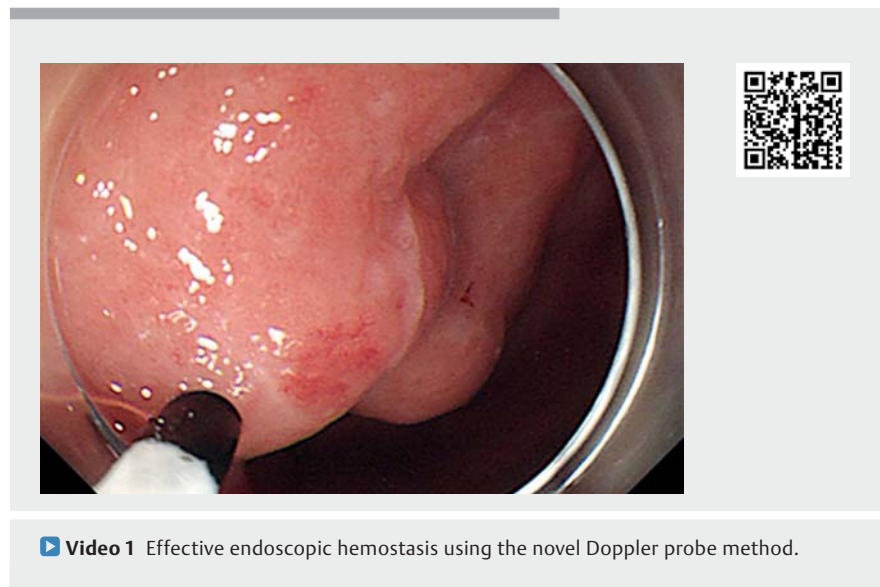
Esophageal variceal recurrence after endoscopic treatment is a frequent event [1–4]. Some studies have reported that endoscopic treatment assisted by endoscopic ultrasonography (EUS) that can evaluate variceal size and hemodynamics is effective in preventing variceal recurrence [3,4]. Additionally, color Doppler evaluation by EUS is less invasive and enables endoscopists to identify the varices to be treated [4]. However, the Doppler-EUS method has issues related to its use: it is time-consuming, it is complicated to use convex transducers, and it requires scope replacement for additional treatment. The latest method, Doppler probe ultrasonography, uses a through-the-scope Doppler probe (Compumedics, DWL, Singen, Germany) (► **Fig. 1 a**) that can evaluate the direction, waveform (that helps distinguish between arteries and veins), and the amount of blood flow (► **Fig. 1 b,c**) [5]. Moreover, Doppler probe ultrasonography is simple, noninvasive, and requires no scope replacement for additional treatment. The procedure involves 1) identification of more risky varices, 2) detection of penetrating varices, 3) assisting appropriate hemostasis, and 4) evaluation after hemostatic treatment. Here we demonstrate two variceal treatments using this novel approach (► **Video 1**).

Case 1 involved a patient with a history of esophageal variceal rupture. Although he had undergone repeated endoscopic variceal ligations, recurrence of varices was observed (► **Fig. 2 a**). We evaluated high-risk varices using Doppler probe ultrasonography (► **Fig. 2 b**). Because varices previously treated with endoscopic variceal ligation had a penetrating vein and massive blood flow, we performed an additional ligation at the site of vein penetration (► **Fig. 2 c**). Varices were evaluated afterwards and the effectiveness of hemostasis was confirmed (► **Fig. 2 d**).

Case 2 had a history of hemostasis for gastric variceal rupture (► **Fig. 3 a**). Sub-



► **Fig. 1 a** The image of the Doppler system with a reusable Doppler probe (diameter of 2 mm, 16 MHz). The Doppler system has audio and visual output signals. (Reproduced with permission from Compumedics.) **b** The visual graphic display reveals Doppler flow corresponding to the esophageal varix. **c** The Doppler flow disappeared after additional endoscopic variceal ligation.



► **Video 1** Effective endoscopic hemostasis using the novel Doppler probe method.

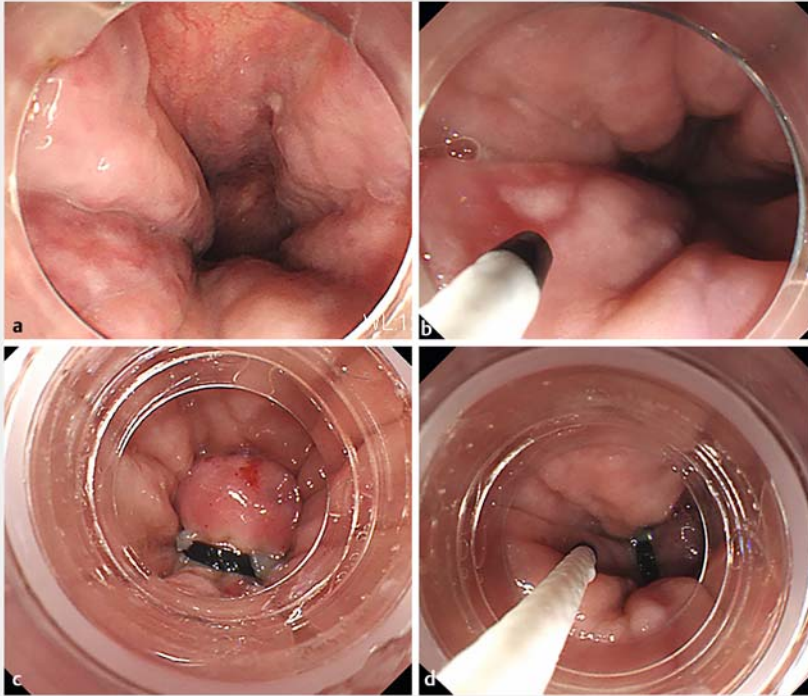
sequently, esophageal varices developed. Esophageal varices continuous with the stomach were identified, and endoscopic variceal ligation was performed (► **Fig. 3 b**).

Both cases were treated effectively with endoscopic variceal ligation assisted by our novel Doppler probe ultrasonography.

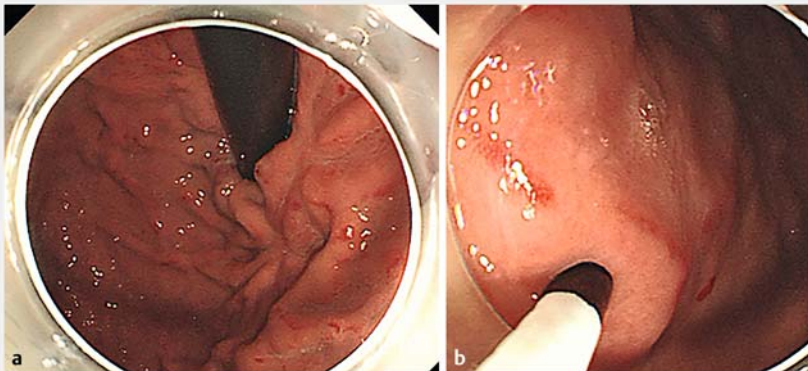
Endoscopy_UCTN_Code_TTT_1AO_2AD

Competing interests

The authors declare that they have no conflict of interest.



► **Fig. 2** **a** Endoscopic view of the patient with esophageal variceal recurrence. **b** Evaluation of esophageal varices using the Doppler probe. The Doppler probe was maneuvered while observing the blood flow. **c** Additional band ligation was performed at a site where there was massive blood flow that we considered to have penetrating veins. **d** Confirmation by Doppler probe after band ligation was performed. If the blood flow had remained, additional variceal ligation would have been considered.



► **Fig. 3** **a** Endoscopic view of gastric varices with scar formation due to previous variceal ligation. **b** Esophageal varices continuous with gastric varices were identified by the novel Doppler probe method; thereafter, esophageal varices were effectively treated by variceal ligation.

References

- [1] Lv Y, Qi X, He C et al. Covered TIPS versus endoscopic band ligation plus propranolol for the prevention of variceal rebleeding in cirrhotic patients with portal vein thrombosis: a randomised controlled trial. *Gut* 2018; 67: 2156–2168
- [2] Mansour L, El-Kalla F, El-Bassat H et al. Randomized controlled trial of scleroligation versus band ligation alone for eradication of gastroesophageal varices. *Gastrointest Endosc* 2017; 86: 307–315
- [3] Carneiro FO, Retes FA, Matuguma SE et al. Role of EUS evaluation after endoscopic eradication of esophageal varices with band ligation. *Gastrointest Endosc* 2016; 84: 400–407
- [4] Hino S, Kakutani H, Ikeda K et al. Hemodynamic analysis of esophageal varices using color Doppler endoscopic ultrasonography to predict recurrence after endoscopic treatment. *Endoscopy* 2001; 33: 869–872
- [5] Shiratori Y, Ikeya T, Oguri N et al. Endoscopic Doppler probe ultrasonography for detecting blood flow at post-endoscopic submucosal dissection ulcers of the stomach. *Endosc Int Open* 2020; 8: E1086–E1090

Bibliography

Endoscopy 2021; 53: E419–E420

DOI 10.1055/a-1324-2591

ISSN 0013-726X

published online 27.1.2021

© 2021. Thieme. All rights reserved.

Georg Thieme Verlag KG, Rüdigerstraße 14, 70469 Stuttgart, Germany

ENDOSCOPY E-VIDEOS

<https://eref.thieme.de/e-videos>



Endoscopy E-Videos is a free access online section, reporting on interesting cases and new

techniques in gastroenterological endoscopy. All papers include a high quality video and all contributions are freely accessible online.

This section has its own submission website at

<https://mc.manuscriptcentral.com/e-videos>

The authors

Yasutoshi Shiratori, Takaaki Yoshimoto,
Kazuki Yamamoto

Division of Gastroenterology, St. Luke's
International Hospital, Tokyo, Japan

Corresponding author

Yasutoshi Shiratori, MD

9-1 Akashi-cho Chuo-ku, Tokyo 104-8340,
Japan
shiraya@luke.ac.jp