

## Testicular Metastatic Sarcomatoid Carcinoma of Unknown Primary: A Case Report



### Introduction

Approximately 90–95% of testicular cancers are divided into two main categories: seminomas and non-seminomas. Tumors often contain more than one type of tumor cell and are called mixed germ cell tumors. The main types of non-seminoma are embryonal carcinoma, yolk sac carcinoma, choriocarcinoma, and teratoma. Other types are stromal tumors, Leydig cell tumors and Sertoli cell tumors. Secondary testicular cancers are lymphoma, leukemia, and metastases. Sarcomatoid carcinoma tumors in the testicles are very rare. Other case reports have described rare types of testicular cancer, e. g. testicular fusocellular rhabdomyosarcoma, paratesticular liposarcoma, testicular carcinoid, testicular sarcomatoidosis, testicular clear cell carcinoma, testicular chloroma, cutaneous mucinous carcinoma, and sarcomatoid yolk sac.

When treating testicular tumors, surgery is the primary treatment and adjuvant chemotherapy and radiotherapy may be required. Owing to the aggressive nature of sarcomatoid carcinomas and the high probability of distant metastasis, the prognosis may not be favorable. No other cases of this entity have been reported in the English literature. We hereby present a case of a 62-year-old male patient diagnosed with a testicular metastatic sarcomatoid carcinoma of unknown primary.

### Case

A 62-year-old-male patient was referred by his general practitioner to ultrasonography

of the scrotum. During the last three weeks the patient had discovered a small lump in the right testis. There was no history of testicular trauma, no family history of germ cell tumor, and no reported history of sexually transmitted infection. Ultrasonography revealed normal left and right testicles. Two small benign spermatoceles were present in the right testicle, both measuring 6 mm in diameter. Varicocele was seen in both testicles. The kidneys were also investigated, and bilaterally two benign cysts were present. The diameter in the right and left kidney was 33 mm and 13, respectively.

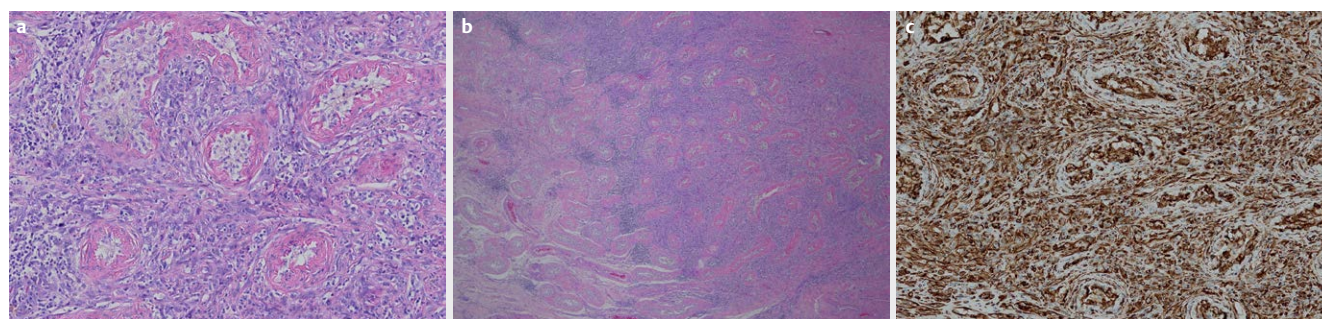
Around three years previously, the patient was diagnosed with prostate adenocarcinoma and underwent prostatectomy. The Gleason score was 3+4, and the prostate tumor stage was pT2c. The patient recovered well, but two years later presented with elevating PSA levels and received radio-chemotherapy under the suspicion of relapse.

One year later the patient consulted the urological department for scrotal swelling with months of increasing volume and moderate pain. There was no indication of hematuria, urinary incontinence, or weight loss. The prostate-specific antigen was not elevated (PSA < 0.01). Ultrasonography showed a left atrophic testicle with no tumor suspicion. The right testicle and epididymis were substantially enlarged with a uniform parenchyma. There was no definable tumor limit in the right testicle. There was no increased testicular hyperemia. The Doppler signal in both testicles was normal. The ultrasonography diagnosis suspected tumor

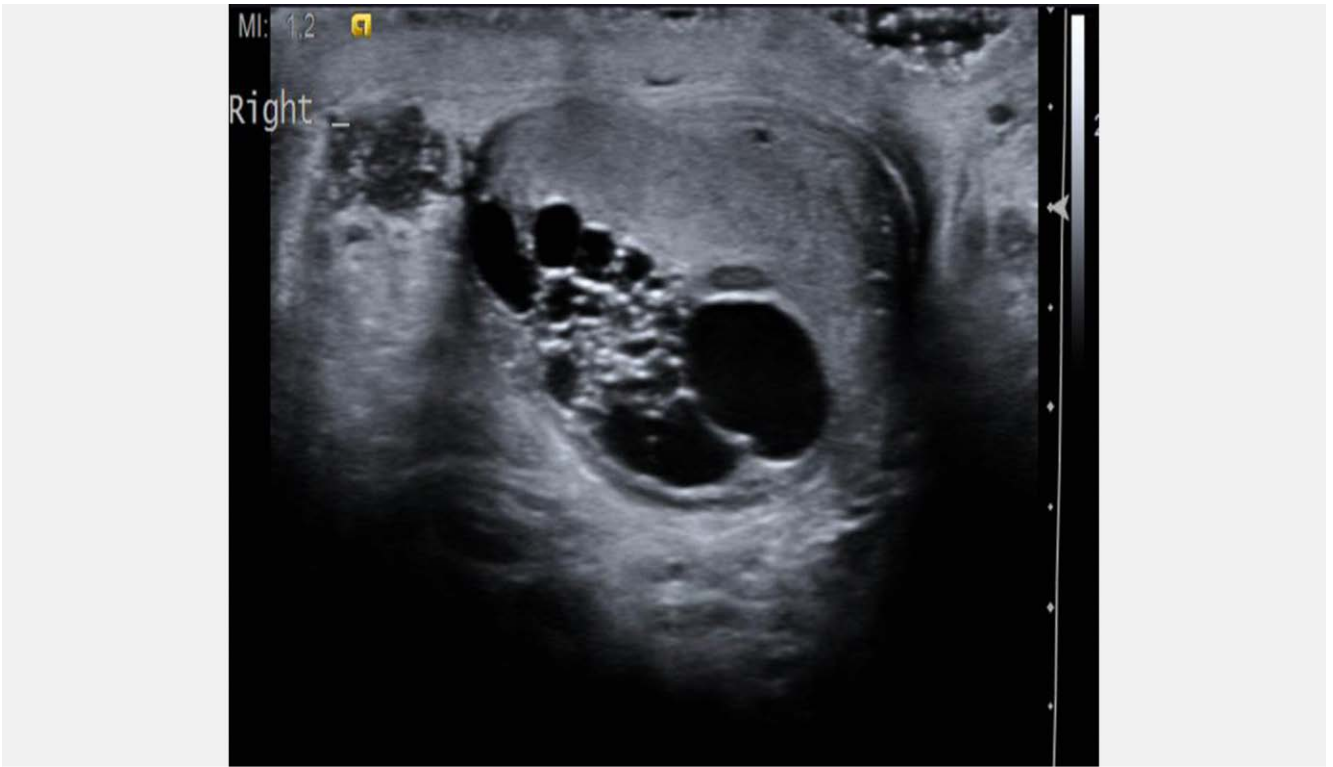
formation of the entire right testicle, but orchitis could not be ruled out.

The urologist referred the patient to a control follow-up of the scrotum before possible initiation of surgery. The patient had undergone a 2-week antibiotic treatment without any significant change in symptoms. The follow-up ultrasonographic examination showed a heterogeneous right testicle with a homogeneous and hypoechoic tumor. Doppler showed vague signals and testicular edema was seen. The ultrasonography diagnosis was right-sided intraparenchymal lipomatous tumor.

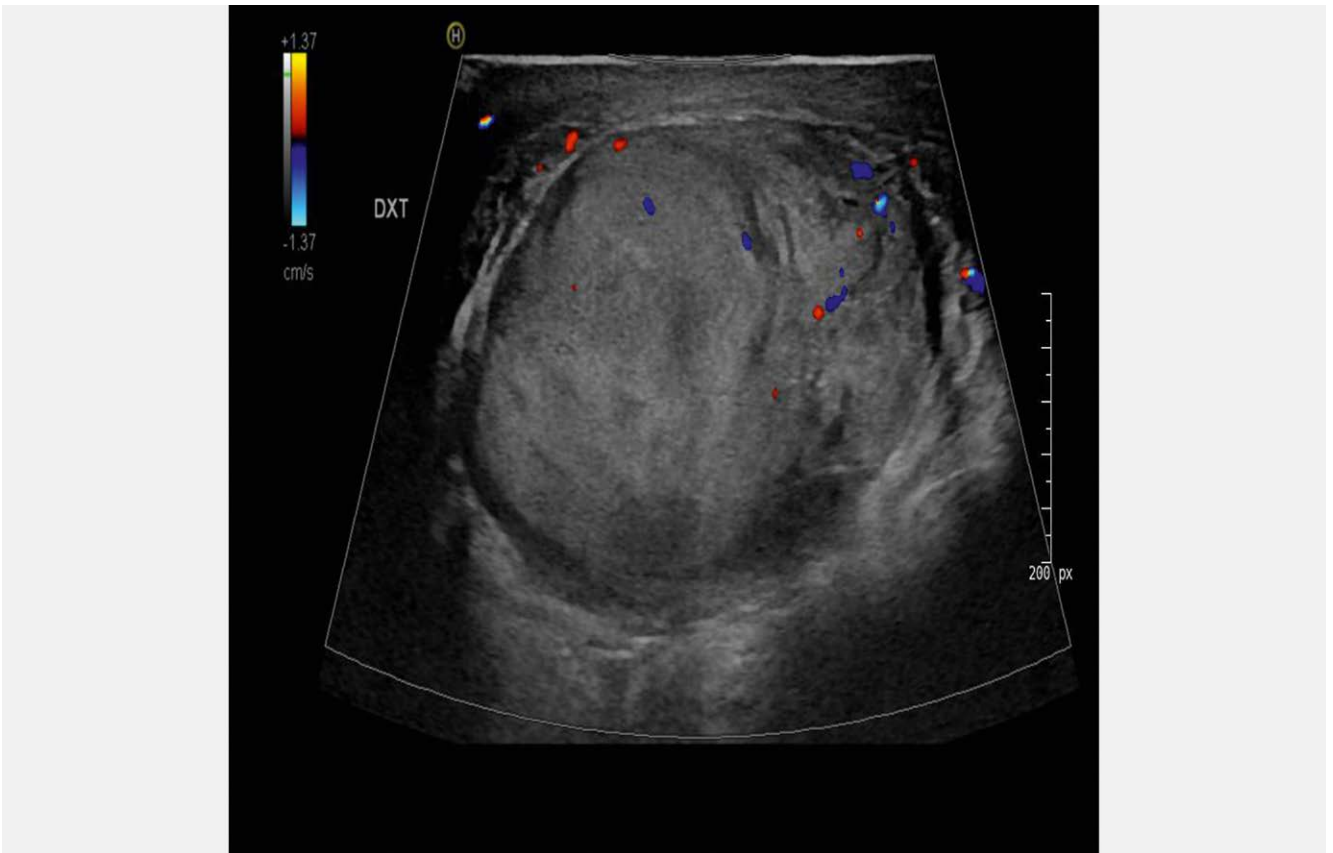
The patient had the right testicle surgically removed, and according to standard procedure, the left testicle was biopsied. Macroscopy showed a yellowish testicle with blurred boundaries including solid whitish-looking areas from peri-testicular adipose tissue. The testicle included a tumor measuring 7 × 5 × 3 cm. The tumor measured 5 × 3.3 × 3 cm. Microscopy revealed a diffusely infiltrating poorly differentiated tumor without any recognizable organoid differentiation. Immunohistochemistry was negative for germinal cell and prostate markers. The tumor cells were positive for the general mesenchymal marker vimentin, but negative for more tissue-specific markers. The tumor cells were also positive for the epithelial markers AE1/AE3, CK7, and CK8/18 (► Fig. 1). Based on the appearance of the tumor cells and the immunohistochemical findings, the tumor was classified as a sarcomatoid carcinoma. ► Figs. 2, 3, and ► 4 show ultrasonography of the tumor development.



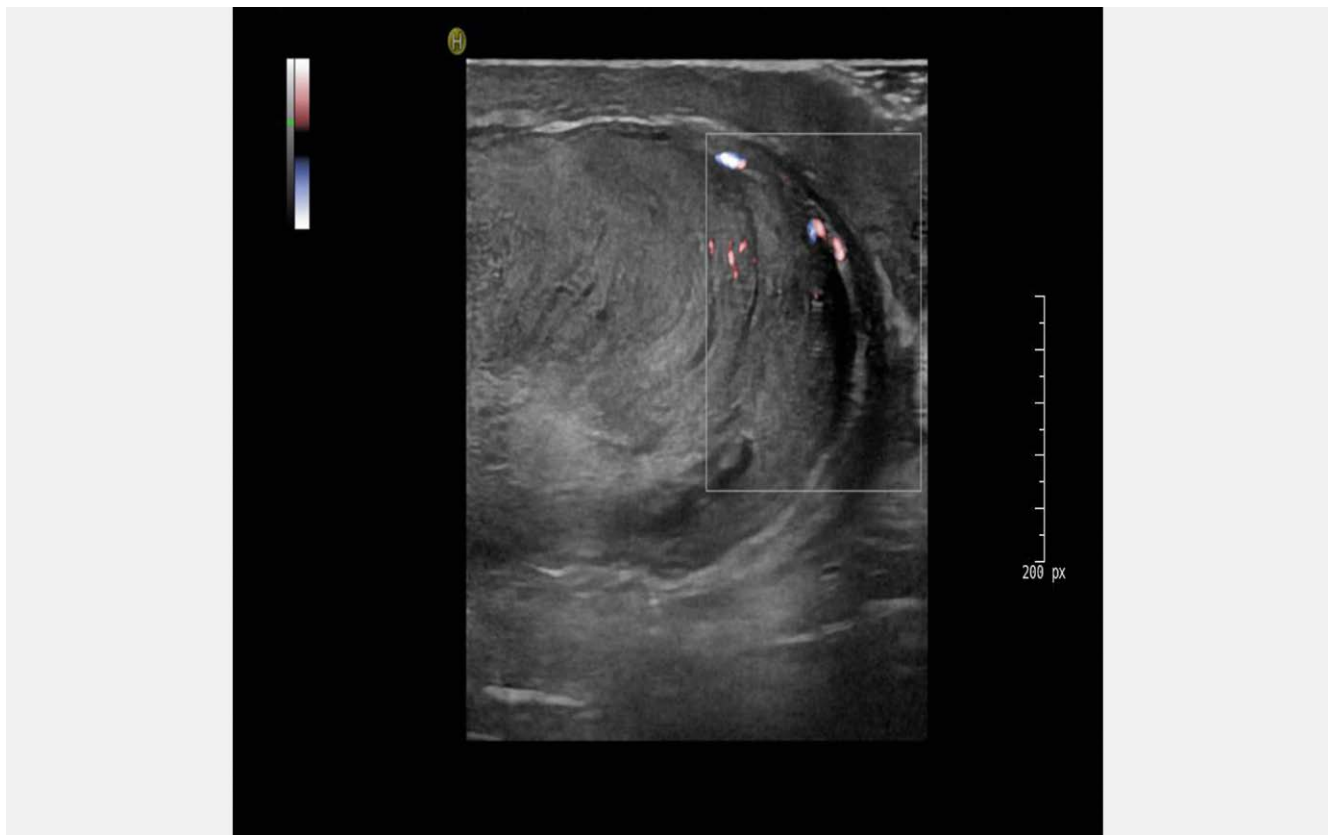
► Fig. 1 a H&E section of the tumour. 100x magnification. b Positive immunohistochemical staining for epithelium (AE1/AE3). 100X magnification. c Positive immunohistochemical staining for mesenchymal marker Vimentin. 100x magnification.



► **Fig. 2** Ultrasonography of the right testicle showing intratesticular cysts on the first scan.



► **Fig. 3** Testicular tumor suspicion on the second ultrasonography scan.



► Fig. 4 Continued testicular tumor suspicion on the final ultrasonography scan.

Based on focal immunohistochemical expression of PAX8, spread from a sarcomatoid carcinoma of the kidney was suggested.

The biopsy of the left testicle showed signs of atrophy likely due to increasing age.

Computed tomography (CT) showed evidence of metastasis in both lungs and a solid mass along the right iliac artery. A lung biopsy was performed with no complications and showed no pathology. A biopsy of the abdominal mass also presented as sarcomatoid carcinoma and was thought to be a metastasis. The patient received treatment with immunotherapy.

## Discussion

Primary sarcomatoid carcinoma of the testis has not been reported in the literature. In this case the testicular tumor was classified as a sarcomatoid carcinoma metastasis with unknown primary. It is important through workup to identify possible primary sites. Some of the common primary tumor sites that may metastasize to the scrotum include the colon, rectum, pros-

tate, urothelial, and lungs (Dutt N et al. *Histopathology* 2000; 37: 323–331). Also, cutaneous scrotal metastasis has been found (Hoyt BS et al. *Int J Dermatol* 2013; 52: 398–405). Still, metastatic testicular cancers are rare possibly due to the strong capsule tunica albuginea surrounding the testicles and lower temperature in the scrotum. One study found metastasis in 0.68% of patients undergoing autopsies for solid neoplasms (García-González R et al. *Ann Diagn Pathol* 2000; 4: 59–64), and another study found metastatic testicular cancer in 3.6% (Patel SR et al. *J Urol* 1989; 142: 1003–1005). Testicular neoplasm accounts for approximately 1% of all malignancies and often in young males. However, there are no specific characteristics of testicular metastasis on ultrasonography findings. Metastasis imaging may present as solitary unilateral nodules that typically have the same sonographic appearance as a primary testicular neoplasm (Ulbricht T et al. *Am J Surg Pathol* 2008; 32: 1683–1693). Hence the medical history together with scrotal findings and pathology diagnosis are essential for differential diagnosis. Distinguishing

testicular metastasis from primary tumors based on ultrasonography can be difficult, and testicular biopsy is recommended.

It is important to distinguish between benign and malignant intratesticular cystic masses. A cystic appearance in testicles is often diagnosed as an incidental finding and will typically not require any further monitoring. Malignant testicular tumors with a cystic appearance may typically be mature teratoma, carcinomas, and metastasis. Mahlkecht et al. have described tubular ectasia of the rete testis (TERT) as an intra-testicular area within the testicular hilum containing numerous cystic lesions and its differential diagnosis (Mahlkecht A et al. *Arch Ital Urol Androl* 2015; 87: 5–7). Scrotal follow-up is essential. No other cases in the literature have described the malignant transformation from intra-cystic appearance to testicular metastatic sarcomatoid carcinoma of unknown primary. However, it is possible that a very close scrotal ultrasound follow-up setup would have found the intra-cyst and the metastasis reconstituted in the same testis occurred independently.

Some cases found testicular carcinoma to be associated with prostate cancer (Bonetta A et al. *Am J Case Rep* 2017; 18: 887–889), (Gohji K et al. *Int J Urol* 2001; 8: 719–721). In our case the histology indicated that it was unlikely that the metastasis was associated with the patient's earlier prostate carcinoma and the patient had undergone radiotherapy treatment. Radiation-induced sarcoma was ruled out because of the strong positive immunohistochemical tumor markers for EMA and cytokeratins. Therefore, metastasis of prostate carcinoma is very unlikely.

In conclusion, metastatic sarcomatoid carcinoma in the testis is very rare. Patients with a previous cancer, symptoms of orchitis, and a testicular mass should be suspected for testicular metastasis and testicular biopsy should be recommended as standard procedure. The diagnosis is based on the immunohistochemical diagnosis. Radical orchiectomy is the treatment of choice. The patient is alive and well and continues to participate in ultrasound and CT follow-up regularly.

## Availability of Data and Materials

All data analyzed or generated during this study are included.

## Consent for Publication

Written and oral informed consent was obtained from the patient. The hospital Review Board approved this study. The study was approved by the local Danish data authorities.

## Conflict of Interest

The authors declare that they have no conflict of interest.

## Authors

Leo Nygaard<sup>1</sup>, Søren Rafael Rafaelsen<sup>2, 3</sup>, Jan Lindebjerg<sup>3, 4</sup>, Malene Roland Vils Pedersen<sup>2, 3</sup>

## Affiliations

- 1 Department of Radiology, Lillebælt Hospital, Kolding, Denmark
- 2 Department of Radiology, Lillebælt Hospital, Vejle, Denmark
- 3 Faculty of Health Sciences, Institute of Regional Health, University of Southern Denmark, Odense, Denmark
- 4 Department of Pathology, Lillebælt Hospital, Vejle, Denmark

## Correspondence

Malene Roland Vils Pedersen  
Department of Radiology, Vejle Hospital  
– Part of Sygehus Lillebælt,  
Beriderbakken 4  
7100 Vejle  
Denmark  
Tel.: 79406187  
malene.roland.vils.pedersen@rsyd.dk

## Bibliography

*Ultrasound Int Open* 2020; 6: E62–E65  
DOI 10.1055/a-1304-5731  
ISSN 2199-7152

© 2021. The Author(s).

This is an open access article published by Thieme under the terms of the Creative Commons Attribution-NonDerivative-NonCommercial-License, permitting copying and reproduction so long as the original work is given appropriate credit. Contents may not be used for commercial purposes, or adapted, remixed, transformed or built upon. (<https://creativecommons.org/licenses/by-nc-nd/4.0/>)

Georg Thieme Verlag KG, Rüdigerstraße 14,  
70469 Stuttgart, Germany

