Article published online: 2020-11-19

Combination of endoscopic-ultrasound guided choledochoduodenostomy and gastrojejunostomy resolving combined distal biliary and duodenal obstruction

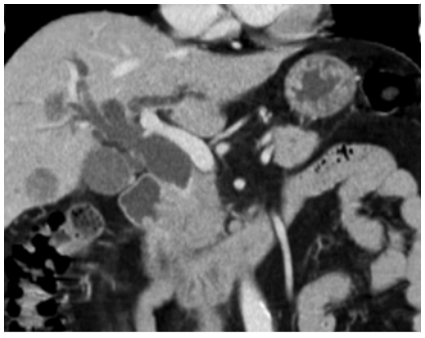

▶ **Fig. 1** Computed tomography revealed a 3.5 × 3.5 × 3.2-cm heterogeneous enhancing periampullary mass with adjacent bowel wall invasion at the second part duodenum, causing luminal narrowing of the second part duodenum and upstream dilatation of the common bile duct.

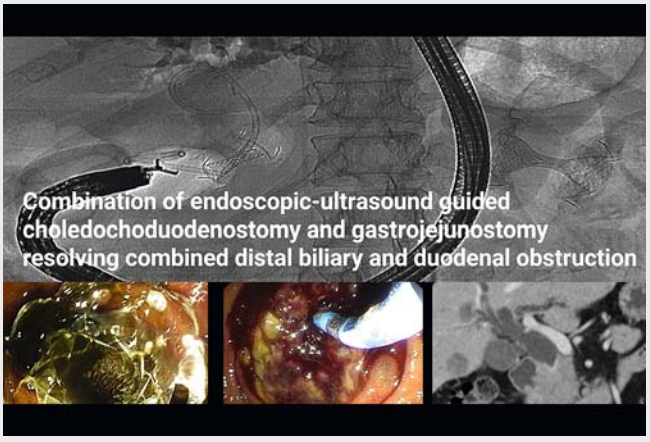

▶ **Video 1** Endoscopic-ultrasound guided choledochoduodenostomy and gastrojejunostomy resolving combined distal biliary and duodenal obstruction in patient with periampullary cancer.

▶ **Fig. 2** A large friable ampullary mass causing supra-ampullary duodenal obstruction.

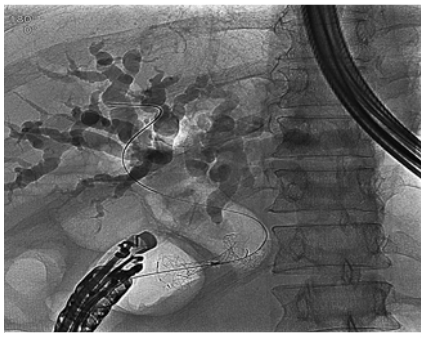

▶ **Fig. 4** An 8 × 12-mm lumen-apposing metal stent (LAMS) was successfully placed transduodenally into the distal common bile duct.

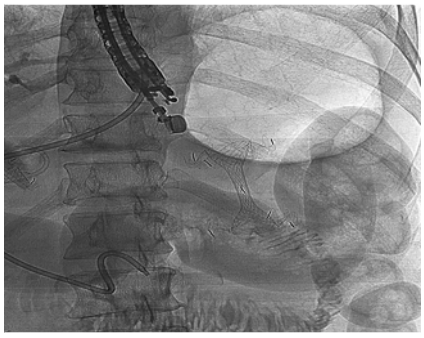

▶ **Fig. 5** A 16 × 20-mm lumen-apposing metal stent (LAMS) was successfully placed transgastrically into the lumen of the jejunum.

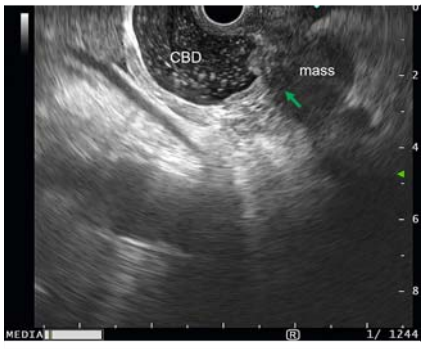

▶ **Fig. 3** Endoscopic ultrasound revealed a periampullary mass (mass) with a dilated common bile duct (CBD).

A 68-year-old man presented with abdominal pain, jaundice, and weight loss for 1 month. Abdominal computed tomography revealed a periampullary mass measuring 3.5 × 3.5 × 3.2 cm with dilated bile duct (▶ **Fig. 1**).

An endoscopic retrograde cholangiopancreatography (ERCP) procedure was not possible owing to a large friable ampullary mass causing supra-ampullary duodenal obstruction (▶ **Fig. 2**). An endoscopic ultrasound-guided choledochoduodenostomy (EUS-CDS) was consequently performed (▶ **Video 1**) with a linear echoendoscope (GF-UCT180; Olympus, Aizu, Japan). A dilated distal common bile duct (CBD) from an ampullary was shown (▶ **Fig. 3**). A 19-gauge endoscopic ultrasound-guided fine-needle aspiration (EUS-FNA) needle (Echotip Ultra; Cook Medical Ltd., Limerick, Ireland) with an angled 0.025-inch guide-

wire (Visiglide 2, Olympus) was used for puncturing. A 6-Fr cystotome (Endo-Flex, Voerde, Germany) and a 4-mm balloon dilatation catheter (Hurricane RX; Boston Scientific, Cork, Ireland) were used for dilation. An 8×12-mm lumen-apposing metal stent (LAMS) (Niti-S Spaxus; Taewoong Medical Co., Ilsan, Korea) was successfully placed transduodenally into the distal CBD (▶ **Fig. 4**). Subsequently, an EUS-guided gastrojejunostomy was performed. A 10-Fr nasobiliary catheter (Flexima; Boston Scientific, Marlborough, Massachusetts, USA) was placed into the jejunum to flush a mix of diluted contrast, saline, and methylene blue into the lumen of the jejunum in order to distend the small bowel loop. A 16×20-mm LAMS with an electrocautery delivery system (Niti-S Spaxus; Taewoong Medical Co.) was successfully placed transgastrically into the lumen of the jejunum (▶ **Fig. 5**). The patient resumed diet with a decline of bilirubin level at 48 hours after the procedure without adverse events.

This case reported the feasibility of a combination of EUS-guided choledochoduodenostomy and EUS-guided gastrojejunostomy to resolve a problem of bile duct and duodenal obstruction type II [1]. Previously, most literature used a combination of EUS-guided biliary drainage and duodenal stents with a technical and clinical success rate of 71.4% to 100% and 94.1% to 100%, respectively [2]. Future study to compare the efficacy of a combined EUS-guided biliary drainage with EUS-guided gastrojejunostomy versus EUS-guided biliary drainage with a duodenal stent is warranted.

Endoscopy_UCTN_Code_TTT_1AS_2AD

Competing interests

The authors declare that they have no conflict of interest.

The authors

Pradermchai Kongkam[1,2], Thanawat Luangsukrerk[1], Kamin Harinwan[3], Kunvadee Vanduangden[1], Suppawatsa Plaidum[1], Rungsun Rerknimitr[1], Pinit Kullavanijaya[1]

1 Gastrointestinal Endoscopy Excellence Center, Department of Medicine, Faculty of Medicine, Chulalongkorn University and King Chulalongkorn Memorial Hospital, Thai Red Cross Society, Bangkok, Thailand
2 Pancreas Research Unit, Department of Medicine, Faculty of Medicine, Chulalongkorn University, Bangkok, Thailand
3 Division of Gastroenterology, Department of Medicine, Faculty of Medicine, Phramongkutklao Hospital, Phramongkutklao College of Medicine, Bangkok, Thailand

Corresponding author

Thanawat Luangsukrerk, MD
Gastrointestinal Endoscopy Excellence Center, Chulalongkorn University and King Chulalongkorn Memorial Hospital, Thai Red Cross Society, 1873, Rama 4 Road, Patumwan, Bangkok, Thailand 10500
Fax: +66-2-652-4219
drthanawatl@gmail.com

References

[1] Mutignani M, Tringali A, Shah SG et al. Combined endoscopic stent insertion in malignant biliary and duodenal obstruction. Endoscopy 2007; 39: 440–447
[2] Mangiavillano B, Khashab MA, Tarantino I et al. Success and safety of endoscopic treatments for concomitant biliary and duodenal malignant stenosis: a review of the literature. World J Gastrointest Surg 2019; 11: 53–611

Bibliography

Endoscopy 2021; 53: E355–E356
DOI 10.1055/a-1294-9399
ISSN 0013-726X
published online 19.11.2020

Georg Thieme Verlag KG, Rüdigerstraße 14, 70469 Stuttgart, Germany