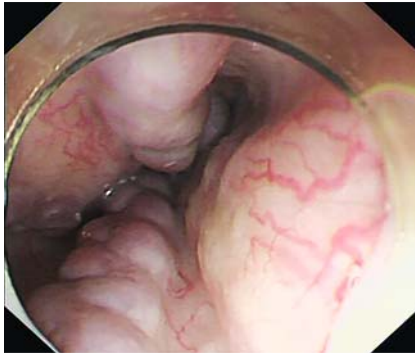


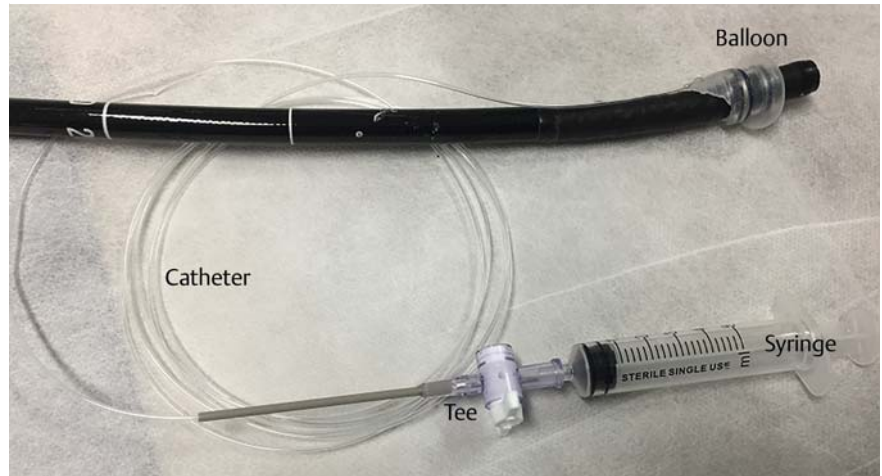
## Balloon-assisted endoscopic sclerotherapy: a novel technology



► **Fig. 1** Endoscopy revealed the presence of four varices in the esophagus, with a maximum diameter of 1.0 cm.

Endoscopic injection sclerotherapy is an effective method for treating esophageal variceal hemorrhage [1, 2]. However, owing to the rapid loss of the sclerosing agent, the overall effect of sclerotherapy is weakened. Therefore, increasing the residence time of the sclerosing agent remains a focal point of current investigations. The present study reported a case treated with a novel technology termed balloon-assisted endoscopic sclerotherapy.

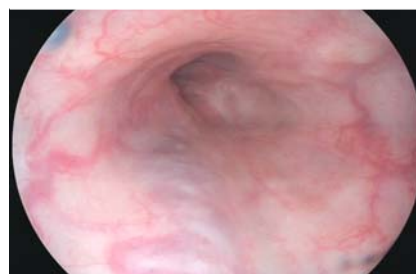
A 48-year-old man was admitted to our department following a diagnosis of esophageal varices. An endoscopy revealed the presence of four varices in the esophagus, with a maximum diameter of 1.0 cm (► **Fig. 1**). Therefore, endoscopic balloon-assisted sclerotherapy was immediately performed. The balloon was inserted on the front end of the gastroscope and fixed at a distance of 3 to 5 cm from the tip (► **Fig. 2**). The inner diameter of the balloon was 1.1 cm, and the outer diameter before and after inflation was 1.3 cm and 1.8 cm, respectively. The endoscope was then used to enter the vicinity of the treated blood vessel, and the balloon was opened up and inflated with 2 ml of air (► **Fig. 3**). Following this procedure, the selected blood vessel was subsequently treated with sclerotherapy.



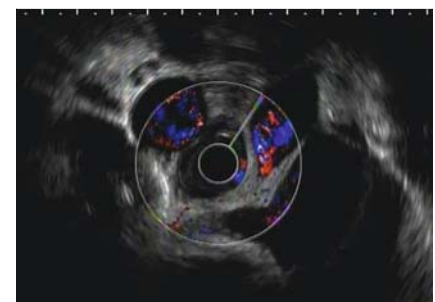
► **Fig. 2** Components of the device include the balloon, catheter, and tee. The balloon was inserted from the front end of the gastroscope and fixed at a distance of 3 to 5 cm from the tip.



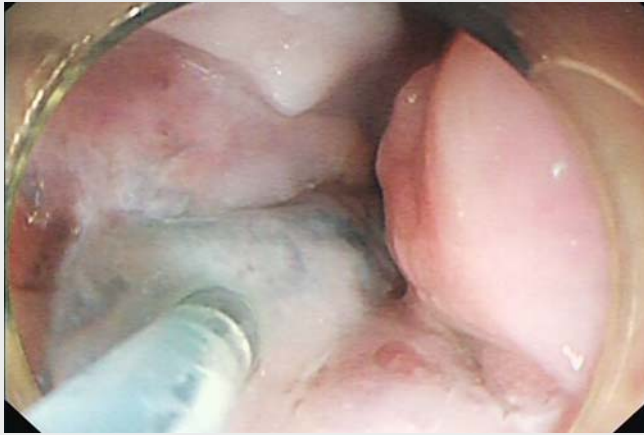► **Fig. 3** The balloon was filled with 2 ml of air.



► **Fig. 4** On follow-up 1 month later, the patient's varicose veins were significantly atrophied.



► **Fig. 5** Endoscopic ultrasonography showed no obvious blood flow signal under the varicose vein.



**▶ Video 1** A case treated with a novel technology termed balloon-assisted endoscopic sclerotherapy.

Briefly, the sclerosing agent (10 ml polycinnamyl alcohol + 0.1 ml meilan) was injected into the blood vessel and the balloon was used to continuously compress the blood vessel for 10 minutes (▶ **Video 1**). The tee was closed after the air in the balloon was completely deflated. On follow-up 1 month later, the patient's varicose veins were significantly atrophied (▶ **Fig. 4**), and endoscopic ultrasonography showed no obvious blood flow signal under the varicose vein (▶ **Fig. 5**).

In conclusion, balloon-assisted sclerotherapy under endoscopy was discovered to improve the therapeutic efficacy of the sclerosing agent. Compared with Tatsuyuki Kawano's balloon method [3], the present method was also simpler and more practical.

Endoscopy\_UCTN\_Code\_TTT\_1AO\_2AD

### Competing interests

The authors declare that they have no conflict of interest.

### The authors

Xuecan Mei<sup>1,\*</sup>, Xi Wang<sup>1,\*</sup>, Wenyue Wu<sup>1</sup>, Yi Xiang<sup>1</sup>, Yi Han<sup>2</sup>, Derun Kong<sup>1,2</sup>

- 1 Department of Gastroenterology, the First Affiliated Hospital of Anhui Medical University, Hefei, Anhui, China
- 2 Department of Gastroenterology, Fuyang Hospital of Anhui Medical University, Fuyang, Anhui, China

### Corresponding author

#### Derun Kong, MD

Department of Gastroenterology, First Affiliated Hospital of Anhui Medical University, 218 Jixi Road, Shushan District, Hefei 230022, Anhui Province, China  
 Fax: +86-551-63633742  
 kongderun168@163.com

\* Joint first authors

### References

- [1] Ali SM, Wu S, Xu H et al. A prospective study of endoscopic injection sclerotherapy and endoscopic variceal ligation in the treatment of esophageal varices. *J Laparosc Adv Surg Tech A* 2017; 27: 333–341
- [2] Kumar S, Asrani SK, Kamath PS. Epidemiology, diagnosis and early patient management of esophagogastric hemorrhage. *Gastroenterol Clin North Am* 2014; 43: 765–782
- [3] Kawano T, Nakamura H, Inoue H et al. Endoscopic injection sclerotherapy using a transparent overtube with intraluminal negative pressure (np-EIS) for esophageal varices. *Surg Endosc* 1990; 4: 15–17

### Bibliography

Endoscopy 2021; 53: E343–E344

DOI 10.1055/a-1290-7001

ISSN 0013-726X

published online 11.11.2020

© 2020, Thieme. All rights reserved.

Georg Thieme Verlag KG, Rüdigerstraße 14, 70469 Stuttgart, Germany

### ENDOSCOPY E-VIDEOS

<https://eref.thieme.de/e-videos>



Endoscopy E-Videos is a free access online section, reporting on interesting cases and new

techniques in gastroenterological endoscopy. All papers include a high quality video and all contributions are freely accessible online.

This section has its own submission website at

<https://mc.manuscriptcentral.com/e-videos>