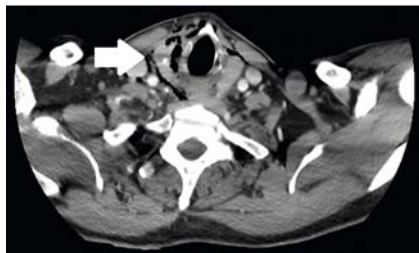


Cap-and-suction hemoclip closure of an iatrogenic cricopharyngeal perforation

Over-the-scope (OTS) clips have revolutionized the management of gastrointestinal (GI) perforations and leaks [1–4]. However, the dimensions of the OTS clip and its delivery device can make deployment challenging or even undesirable [5], especially in regions of the GI tract where maneuverability may be limited. A 68-year-old patient was transferred to our tertiary center following a presumptive diagnosis of a proximal esophageal perforation. The patient had suffered a transmural myocardial infarction days before the current admission, for which



► **Fig. 1** Chest computed tomography (CT) image showing signs of a suspected esophageal perforation, with significant amounts of free air surrounding the soft tissues of the pharyngeal region, infiltrating the submandibular salivary gland and even the right lobe of the thyroid (arrow).

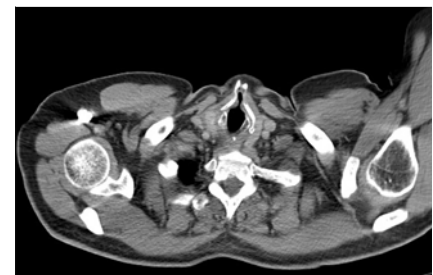a transesophageal cardiac ultrasound had been attempted. The day after, the patient complained of fever, and progressive pharyngeal and thoracic pain, as well as hematemesis. Chest computed tomography (CT) subsequently revealed signs of perforation (► **Fig. 1**).

At our center, cap-assisted upper GI endoscopy was performed with the patient under general anesthesia and showed a longitudinal laceration of the cricopharyngeal muscle, extending into the proximal esophagus (► **Fig. 2a**). The deployment of an OTS clip was deemed unfeasible owing to the limited maneuverability and location of the perforation. Unfortunately, classic clip closure was also challenging and only a limited amount of mucosa was captured, which was deemed insufficient to guarantee a robust closure. Therefore, we decided to apply the cap-and-suction hemoclip closure (CASH) technique (► **Video 1**). With the CASH technique, the hemoclip is opened to its maximum diameter directly in the cap (► **Fig. 2b**) and the targeted mucosal edges are aspirated into the cap. When a sufficient amount of mucosa has been captured, the hemoclip is deployed (► **Fig. 2c**). During follow-up, no residual

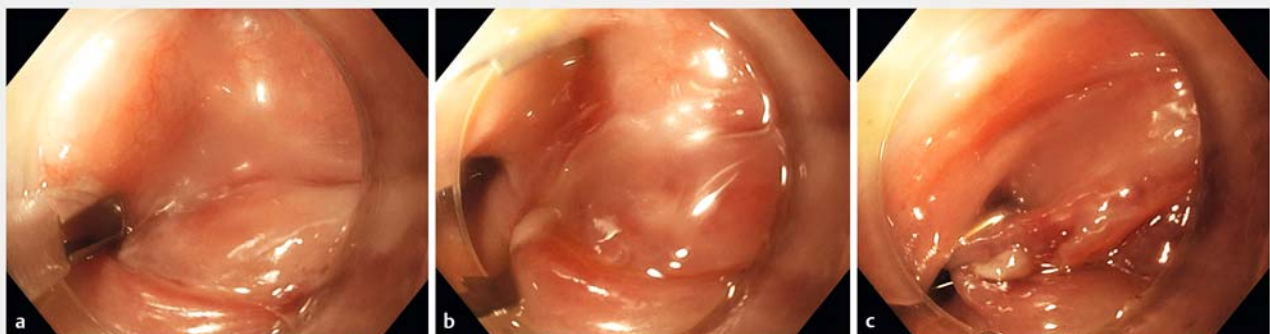
perforation was detected on an upper GI series, or on CT scanning (► **Fig. 3**), after which a soft-solid diet was initiated and the patient resumed his cardiac rehabilitation.

With the CASH approach, only limited scope movement is required and a substantial amount of mucosa can be captured, providing a robust mucosal closure. Our case suggests that this simple, yet effective, technique can be considered in patients ineligible for the application of OTS clips.

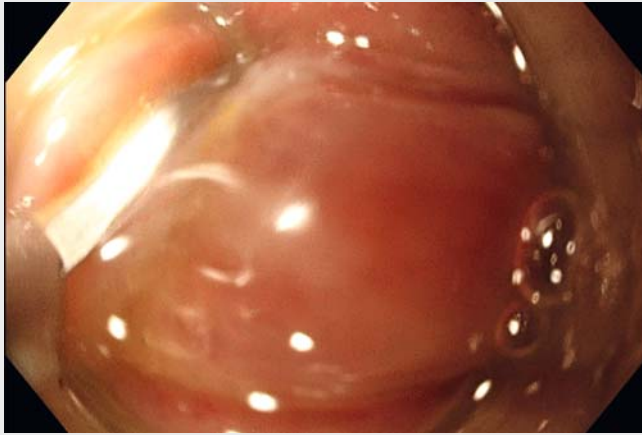
Endoscopy_UCTN_Code_CPL_1AH_2AG



► **Fig. 3** Computed tomography (CT) image of the thorax showing a favorable outcome after cap-and-suction hemoclip closure, without any residual signs of perforation.



► **Fig. 2** Endoscopic images showing: **a** at the upper esophageal sphincter, a right-sided, longitudinal laceration of the cricopharyngeal muscle, extending into the proximal esophagus; **b** maximum clip opening inside the short, transparent cap; **c** the hemoclip deployed after a sufficient amount of mucosal tissue has been captured.



Video 1 Cap-and-suction hemoclip closure of a cricopharyngeal perforation.

Competing interests

M. Bronswijk received travel grants from Prion Medical, Taewoong, and Takeda. P. Roelandt is supported by a Clinical Mandate from the Belgian Foundation against Cancer (Stichting tegen Kanker) and receives speaking and consultancy fees from MSD Belgium.

The authors

Michiel Bronswijk, Philip Roelandt

Department of Gastroenterology and Hepatology, University Hospitals Leuven, Leuven, Belgium

Corresponding author

Michiel Bronswijk, MD

Herestraat 49, 3000 Leuven, Belgium
mjh.bronswijk@gmail.com

References

- [1] von Renteln D, Schmidt A, Vassiliou MC et al. Endoscopic closure of large colonic perforations using an over-the-scope clip: a randomized controlled porcine study. *Endoscopy* 2009; 41: 481–486
- [2] Pohl J, Borgulya M, Lorenz D et al. Endoscopic closure of postoperative esophageal leaks with a novel over-the-scope clip system. *Endoscopy* 2010; 42: 757–759
- [3] Raithel M, Albrecht H, Scheppach W et al. Outcome, comorbidity, hospitalization and 30-day mortality after closure of acute perforations and postoperative anastomotic leaks by the over-the-scope clip (OTSC) in an unselected cohort of patients. *Surg Endosc* 2017; 31: 2411–2425
- [4] Manta R, Manno M, Bertani H et al. Endoscopic treatment of gastrointestinal fistulas using an over-the-scope clip (OTSC) device: case series from a tertiary referral center. *Endoscopy* 2011; 43: 545–548
- [5] Mangiavillano B, Auriemma F, Bianchetti M et al. Complete colonic closure with an over-the-scope clip placed for a colorectal anastomotic fistula: a big mistake. *Endoscopy* 2020; 52: 521–522

Bibliography

Endoscopy 2021; 53: E332–E333

DOI 10.1055/a-1283-5523

ISSN 0013-726X

published online 3.11.2020

© 2020. Thieme. All rights reserved.

Georg Thieme Verlag KG, Rüdigerstraße 14, 70469 Stuttgart, Germany

ENDOSCOPY E-VIDEOS

<https://eref.thieme.de/e-videos>



Endoscopy E-Videos is a free access online section, reporting on interesting cases and new techniques in gastroenterological endoscopy. All papers include a high quality video and all contributions are freely accessible online.

This section has its own submission website at

<https://mc.manuscriptcentral.com/e-videos>