

Endoscopic ischemic polypectomy for small-bowel polyps in patients with Peutz–Jeghers syndrome

Authors

Tsevelnorov Khurelbaatar^{1,2}, Hirotsugu Sakamoto¹, Tomonori Yano¹, Yuichi Sagara¹, Ulzii Dashnyam^{1,3}, Satoshi Shinozaki^{1,4}, Keijiro Sunada¹, Alan Kawarai Lefor⁵, Hironori Yamamoto¹

Institutions

- 1 Department of Medicine, Division of Gastroenterology, Jichi Medical University, Tochigi, Japan
- 2 Department of Gastroenterology, Mongolian National University of Medical Sciences, Ulaanbaatar, Mongolia
- 3 Department of Pediatrics, Mongolian National University of Medical Sciences, Ulaanbaatar, Mongolia
- 4 Shinozaki Medical Clinic, Utsunomiya, Japan
- 5 Department of Surgery, Jichi Medical University, Tochigi, Japan

submitted 9.9.2020

accepted after revision 1.10.2020

published online 1.10.2020

Bibliography

Endoscopy 2021; 53: 744–748

DOI 10.1055/a-1276-6452

ISSN 0013-726X

© 2020. Thieme. All rights reserved.

Georg Thieme Verlag KG, Rüdigerstraße 14, 70469 Stuttgart, Germany

 Scan this QR-Code for the author commentary.



Corresponding author

Hironori Yamamoto, MD, PhD, Department of Medicine, Division of Gastroenterology, Jichi Medical University, 3311-1 Yakushiji, Shimotsuke, Tochigi 329-0498, Japan
Fax: +81-285-406598
ireef@jichi.ac.jp

ABSTRACT

Background To decrease the risk of bleeding or perforation, ischemic polypectomy is performed using a detachable snare or endoclip with double-balloon endoscopy (DBE) for small-bowel polyps in patients with Peutz–Jeghers syndrome. The aim of this study was to determine the effectiveness and feasibility of ischemic polypectomy.

Methods We retrospectively reviewed patients who underwent two or more sessions of ischemic polypectomy using DBE from July 2004 to August 2017.

Results 67 therapeutic DBEs were performed in nine patients during the study period and 352 polyps were treated. The median observation period was 34 months (range 12–66). There was a declining trend over time in the median number of polyps > 15 mm treated per patient first DBE session 6, second 2, third 1.5, fourth 0.5, fifth 0.5; $P=0.11$, Friedman test). No patient required laparotomy due to intussusception during the study period. One patient developed mild acute pancreatitis after the procedure.

Conclusions Ischemic polypectomy was feasible for the control of small-bowel polyps in patients with Peutz–Jeghers syndrome.

Introduction

Peutz–Jeghers syndrome (PJS) is an autosomal dominant syndrome, characterized by the development of multiple hamartomatous polyps throughout the gastrointestinal tract [1, 2]. It has been reported that by the age of 18 years, 70% of patients with PJS are at risk of intussusception requiring laparotomy associated with increasing polyp size [3]. The development of double-balloon endoscopy (DBE) has enabled endoscopic polypectomy of small-bowel polyps [4]. Repeated polypectomy of small-bowel polyps has been reported to reduce the risk of intussusception [5–7].

However, there are some concerns regarding snare polypectomy of small-bowel polyps. In order to achieve an R0 resection, polypectomy with an adequate margin is required. In difficult circumstances, snare polypectomy takes an extended period of time. Prophylactic clip application after polypectomy is often performed to reduce delayed bleeding. Although collection of the resected specimens takes time, the malignant potential of PJS polyps is very low. Peritoneal adhesions due to previous laparotomies can make endoscope maneuverability difficult. In some cases, it is impossible to accomplish polypectomy even if the lesion can be detected.

In order to overcome these problems, we have performed polyp strangulation using endoclips and/or a detachable snare

(► **Fig. 1**) [8,9]. It was confirmed that most polyps are passed naturally within a few days. We named this procedure ischemic polypectomy. In our institution, we started using the ischemic polypectomy method in 2008, and from 2011 almost all patients with PJS were treated by ischemic polypectomy. In this study, we evaluated whether ischemic polypectomy of small-bowel polyps in patients with PJS is feasible, as previously reported for conventional polypectomy [5–7].

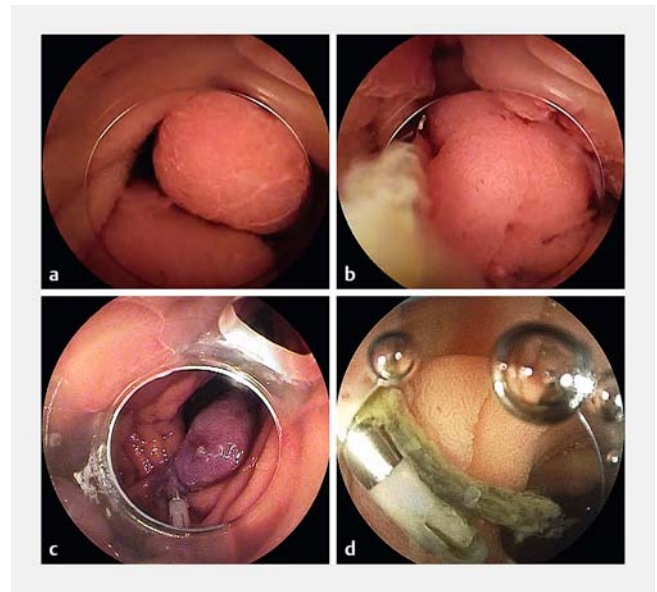
Methods

The records of 61 consecutive patients with PJS who underwent DBE at Jichi Medical University Hospital from July 2004 to August 2017 were retrospectively reviewed. Among these patients, nine who underwent multiple sessions of ischemic polypectomy and had no other treatment were included in the series. In order to evaluate the effectiveness of ischemic therapy, we excluded patients who underwent both ischemic polypectomy and conventional polypectomy. We defined one session as one hospitalization for therapeutic DBE in which one or more procedures were performed. Written informed consent was obtained from all patients before the procedure. This study was approved by the Institutional Review Board.

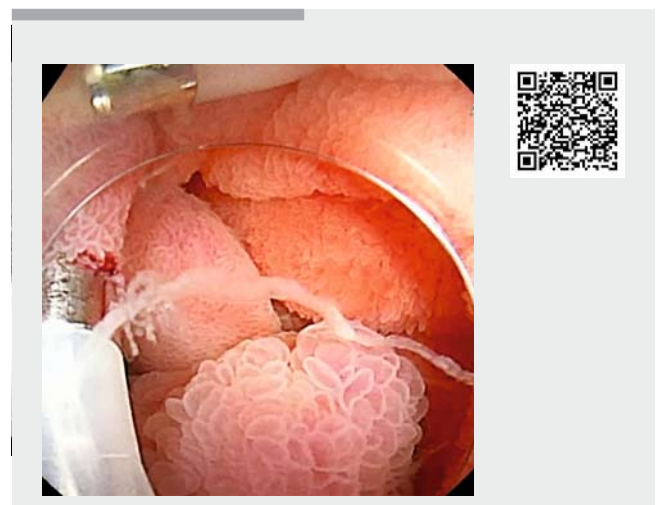All patients were admitted before DBE. A combined retrograde and antegrade approach was performed at the first session for most patients. Bowel preparation included 2L of polyethylene glycol electrolyte solution on the day of DBE using the retrograde approach. Conscious sedation with a combination of intravenous pethidine and midazolam was used for all patients. A therapeutic-type (EN-580T or EN-450T5/W with TS-13140; Fujifilm, Tokyo, Japan) or short-type (EI-580BT or EI-530B or EC-450B15 with TS-13101; Fujifilm) double-balloon endoscope with carbon dioxide insufflation, BioShield irrigator (US endoscopy, Mentor, Ohio, USA), and a 4-mm transparent cap (D-201–10704; Olympus, Tokyo, Japan) fitted to the tip of the endoscope were routinely used.

We defined ischemic polypectomy for PJS as polyp strangulation using endoclips and/or a detachable snare without using conventional polypectomy methods (► **Video 1**). Our first choice was clip strangulation as shown in ► **Fig. 1**, with application of a long-type hemoclip (HX-610–090L; Olympus) to the stalk of the polyp. For polyps with a thick stalk where it is difficult to apply clips, we used selective ligation with a detachable snare (MAJ-254 or MAJ-340; Olympus). These techniques restrict blood flow to the polyp, leading to ischemia and shedding of the polyp. Success of ischemic polypectomy could be recognized by a change in polyp color, from the typical mucosal color to dark purple (► **Fig. 1c**) in a few seconds. In cases where one clip was not sufficient, a crossed-clip strangulation method was used [8]. When performing antegrade DBE, we tried to keep the examination time within 120 minutes whenever possible to reduce the risk of adverse events.

At the first session, the priority was to use ischemic polypectomy to treat polyps > 15 mm to prevent intussusception. In patients with multiple large polyps, we repeated the DBE and treated as many of the polyps as possible during the same session. If all of the large polyps could not be removed in one ses-



► **Fig. 1** Endoscopic images of the lesion in patient 9. **a** A 0-Ip lesion 12 mm in diameter was found in the proximal jejunum. **b** A long clip was applied to the stalk. **c** The polyp was discolored after clip placement. **d** The polyp regressed by Day 5 after clip placement.



► **Video 1** Ischemic polypectomy for small-bowel polyps in a patient with Peutz–Jeghers syndrome (patient 8). Online content viewable at: <https://doi.org/10.1055/a-1276-6452>

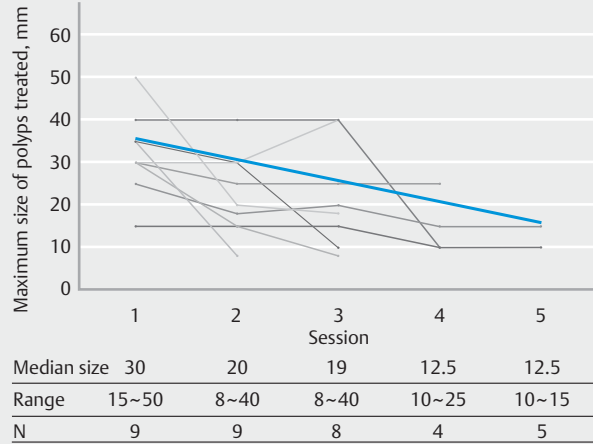
sion, we scheduled the next session after a short interval (within 6 months). In that situation, a single approach (antegrade or retrograde) was sometimes selected depending on the location of the polyps. During subsequent sessions, all polyps > 5 mm that were amenable to ischemic polypectomy were treated. The intervals between sessions were determined for each patient, taking into account the rate of polyp growth.

The following outcomes were recorded: 1) clinical characteristics (age, sex, history of abdominal surgery); 2) results (number of treated polyps, number of treated polyps > 15 mm,

▶ Table 1 Patient characteristics.

| Patient | Age, years | Sex | Age at first laparotomy, years/ no. of laparotomies | Observation period, months | Sessions, n | No. of DBEs, total/ antegrade/ retrograde | Treated polyps, total/clipping/ endoloop | Polyps treated at each session, n | Polyps > 15 mm treated at each session, n | Max. diameter of polyps treated at each session |
|---------|------------|-----|---|----------------------------|-------------|---|--|-----------------------------------|---|---|
| 1 | 45 | F | 24/1 | 66 | 5 | 12/8/4 | 59/54/5 | 29/13/8/4/5 | 15/6/3/0/0 | 40/40/40/10/10 |
| 2 | 34 | M | 0/3 | 34 | 3 | 5/3/2 | 6/3/3 | 3/2/1 | 2/1/0 | 35/30/10 |
| 3 | 62 | M | 12/4 | 36 | 4 | 8/4/4 | 36/36/0 | 15/12/7/2 | 2/2/1/0 | 15/15/15/10 |
| 4 | 60 | F | 20/4 | 39 | 5 | 11/7/4 | 96/84/12 | 46/8/14/12/16 | 2/1/4/1/1/1 | 25/18/20/15/15 |
| 5 | 15 | M | None | 24 | 4 | 6/4/2 | 7/0/7 | 1/2/2/2 | 1/2/2/2 | 30/25/25/25 |
| 6 | 45 | F | 16/1 | 36 | 3 | 6/4/2 | 17/16/1 | 6/8/3 | 6/1/0 | 30/15/8 |
| 7 | 19 | M | 19/1 | 12 | 2 | 4/2/2 | 5/4/1 | 4/1 | 2/0 | 35/8 |
| 8 | 35 | M | 15/2 | 12 | 3 | 6/3/3 | 49/42/7 | 20/20/9 | 11/4/4 | 30/30/40 |
| 9 | 26 | F | 5/2 | 15 | 3 | 9/6/3 | 67/56/11 | 40/11/16 | 21/6/5 | 50/20/18 |

DBE, double-balloon endoscopy; F, female; M, male.



▶ Fig. 2 The maximum size of polyps treated in each patient during each session: the maximum size of polyps treated in each patient decreased over subsequent sessions, although not statistically significantly ($P=0.11$, Friedman test).

maximum diameter of treated polyps); 3) adverse events (development of small-bowel cancer and the need for laparotomy after the start of ischemic polypectomy).

Statistical analysis was performed using EZR (version 1.32; Saitama Medical Center, Jichi Medical University, Saitama, Japan) [10]. Correlations between sessions for numerical variables were performed using the Friedman test. Differences were considered statistically significant with a P value of <0.05 .

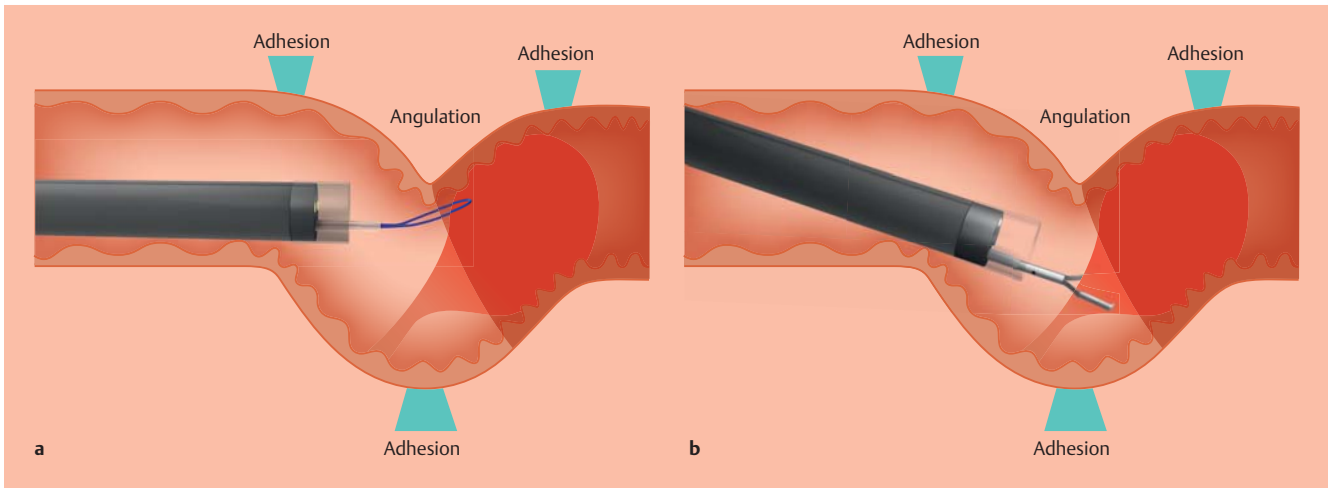
Results

Patient characteristics

Nine patients (5 male, 4 female) were enrolled in the study. Patient characteristics are summarized in ▶ Table 1. The median age of patients was 35 years (range 15–62). Eight patients had a history of previous laparotomy. The indication for most of the abdominal operations was intussusception. The median observation period between the first and last therapeutic DBEs was 34 months (range 12–66). A total of 67 therapeutic DBEs were performed in these patients during the study period.

Ischemic polypectomy

A total of 352 polyps were treated with an ischemic polypectomy, with a median of 36 polyps per patient (range 5–96). The median number of treated polyps at each session was 15 (first session), 8 (second session), 7.5 (third session), 3 (fourth session), and 10.5 (fifth session), decreasing further, though not significantly, at subsequent sessions ($P=0.27$, Friedman test). The median number of treated polyps >15 mm per patient showed a downward trend, decreasing over time (6, 2, 1.5, 0.5, 0.5; $P=0.11$). The median maximum size of treated polyps in each patient also showed a downward trend (30 mm, 20 mm, 19 mm, 12.5 mm, 12.5 mm; $P=0.11$) (▶ Fig. 2). No patient required laparotomy due to intussusception during the study period.



► **Fig. 3** Endoscopic manipulation in the presence of adhesions, which limit visibility of the entire polyp. **a** It is difficult to apply a snare to the stalk of the polyp because of poor endoscope maneuverability. **b** Clip strangulation is easy to complete even in a limited working space with less than ideal maneuverability because only the stalk of the polyp must be seen; visualization of the entire polyp is not needed.

Adverse events occurred after 1/67 procedures (1.5%). Mild acute pancreatitis developed in one patient who had history of four previous abdominal operations and was managed nonoperatively (patient 3).

Discussion

To the best of our knowledge, this is the first report to introduce ischemic polypectomy, which we have practiced and used in our institution, as a new therapeutic approach for small-bowel polyposis in patients with PJS. Routine repeated small-bowel DBE combined with ischemic polypectomy was feasible for the control of polyps during the follow-up period, and in particular, decreasing the number of large polyps over time.

A previous DBE-assisted polypectomy study showed that perforation leads to the need for additional surgery (1.3%) and that delayed bleeding is the most common adverse event, although this was infrequent (2.5%) [7]. Conventional polypectomy using electrocautery may lead to adverse events such as delayed perforation, delayed bleeding, and post-polypectomy syndrome due to degeneration of the tissue [11]. Another retrospective report including 13 patients showed no complications associated with DBE-assisted polypectomy; however, endoscopic resection of some large polyps was difficult and surgical removal was required [12]. The use of ischemic polypectomy does not lead to tissue damage at the resection margin. The procedure, especially clip strangulation, is easier to perform than conventional polypectomy, and is easy to complete even in a limited working space with less than ideal maneuverability such as in the distal small intestine or the post-operative intestinal tract (► Fig. 3). Only the stalk, rather than the entire polyp, needs to be visualized for clip strangulation. As ischemic polypectomy is easy to perform and many polyps can be treated in a short time, it may be possible that the number of adverse events is reduced because of a shorter procedure

time. It has been reported that longer procedure times are associated with a greater incidence of pancreatitis in patients undergoing peroral DBE [13].

The main disadvantage of ischemic polypectomy is the uncertainty of the final outcome. Some polyps could survive and fail to auto-amputate after a single ischemic polypectomy. We have not performed follow-up DBE to confirm whether all treated polyps underwent auto-amputation. Even if multiple DBEs are performed in the same session, a large number of polyps are treated within one DBE, so it is difficult to clearly evaluate which polyps are lost or survive. Although an absolute number is not available, it is estimated that 80%–90% of the treated polyps became necrotic. While most polyps were considered to increase in size over time without treatment, the number of polyps treated >15 mm and the maximum diameter of treated polyps tended to decrease over repeated sessions in this study, which suggests that the ischemic polypectomy was effective. Ischemic polypectomy can be repeated, which allows any polyps that did not auto-amputate to be treated at the next DBE session.

This study has some limitations. It was a single-center, retrospective study with a relatively small number of patients, as PJS is rare. There was a large variation in the number of polyps among patients, and the intervals between sessions were not standardized because the intervals were determined according to the needs of treatment.

We conclude that ischemic polypectomy is feasible for the management of PJS polyps. To confirm the safety and effectiveness of this method, future multicenter, prospective, randomized studies are needed.

Competing interests

Dr. Yamamoto is a consultant for Fujifilm Corp. and has received honoraria, grants, and royalties from the company. Drs. Sakamoto, Yano, and Sunada have received honoraria from Fujifilm Corp. Dr. Sakamoto has also received a grant from Fujifilm Medical Corporation. Other authors declare no conflicts of interest regarding this study.

References

- [1] Jeghers H, Mc KV, Katz KH. Generalized intestinal polyposis and melanin spots of the oral mucosa, lips and digits; a syndrome of diagnostic significance. *N Engl J Med* 1949; 241: 1031–1036
- [2] Beggs AD, Latchford AR, Vasen HF et al. Peutz–Jeghers syndrome: a systematic review and recommendations for management. *Gut* 2010; 59: 975–986
- [3] Hinds R, Philp C, Hyer W et al. Complications of childhood Peutz–Jeghers syndrome: implications for pediatric screening. *J Pediatr Gastroenterol Nutr* 2004; 39: 219–220
- [4] Yamamoto H. Fifteen years since the advent of double-balloon endoscopy. *Clin Gastroenterol Hepatol* 2017; 15: 1647–1650
- [5] Sakamoto H, Yamamoto H, Hayashi Y et al. Nonsurgical management of small-bowel polyps in Peutz–Jeghers syndrome with extensive polypectomy by using double-balloon endoscopy. *Gastrointest Endosc* 2011; 74: 328–333
- [6] Serrano M, Mao-de-Ferro S, Pinho R et al. Double-balloon enteroscopy in the management of patients with Peutz–Jeghers syndrome: a retrospective cohort multicenter study. *Rev Esp Enferm Dig* 2013; 105: 594–599
- [7] Wang YX, Bian J, Zhu HY et al. The role of double-balloon enteroscopy in reducing the maximum size of polyps in patients with Peutz–Jeghers syndrome: 12-year experience. *J Dig Dis* 2019; 20: 415–420
- [8] Yano T, Shinozaki S, Yamamoto H. Crossed-clip strangulation for the management of small intestinal polyps in patients with Peutz–Jeghers syndrome. *Dig Endosc* 2018; 30: 677
- [9] Takakura K, Kato T, Arihiro S et al. Selective ligation using a detachable snare for small-intestinal polyps in patients with Peutz–Jeghers syndrome. *Endoscopy* 2011; 43: (Suppl. 02): E264–265
- [10] Kanda Y. Investigation of the freely available easy-to-use software ‘EZ’ for medical statistics. *Bone Marrow Transplant* 2013; 48: 452–458
- [11] Shinozaki S, Kobayashi Y, Hayashi Y et al. Efficacy and safety of cold versus hot snare polypectomy for resecting small colorectal polyps: systematic review and meta-analysis. *Dig Endosc* 2018; 30: 592–599
- [12] Gao H, van Lier MG, Poley JW et al. Endoscopic therapy of small-bowel polyps by double-balloon enteroscopy in patients with Peutz–Jeghers syndrome. *Gastrointest endosc* 2010; 71: 768–773
- [13] Zepeda-Gomez S, Barreto-Zuniga R, Ponce-de-Leon S et al. Risk of hyperamylasemia and acute pancreatitis after double-balloon enteroscopy: a prospective study. *Endoscopy* 2011; 43: 766–770