Article published online: 2020-10-23

Perforation and bleeding during an underwater endoscopic mucosal resection of a large colonic lesion

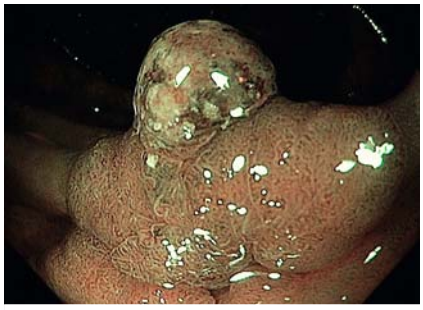

▶ **Fig. 1** A 2.0 cm-lesion (0-IIa + Is) at the transverse colon (narrow-band imaging).

▶ **Fig. 2** Underwater endoscopic mucosal resection (EMR) technique.

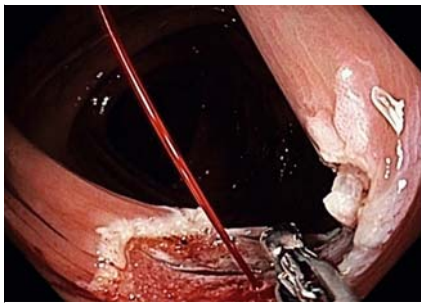

▶ **Fig. 3** Bleeding and perforation after underwater endoscopic mucosal resection (EMR).

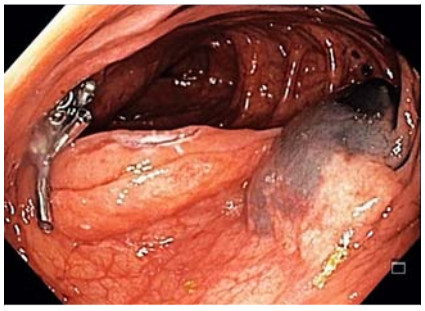

▶ **Fig. 4** Endoscopic appearance after hemostasis, through-the-scope clip closure, and endoscopic tattoo.

▶ **Fig. 5** Follow-up after 6 months.

Underwater endoscopic mucosal resection (UEMR) is a well-established endoscopic technique for the resection of colorectal lesions in general; it is known to be safe and effective [1]. Water immersion provides a "floating" effect of the mucosa and submucosa, keeping them apart from the muscularis propria and allowing a deep yet safe resection. It has been proved to be cost-effective (in comparison to the standard EMR technique) because it does not require a submucosal injection and is also extremely helpful for resecting large colorectal lesions as well as those with a prominent fibrotic component as seen in recurrent lesions.

Bleeding – either early or delayed – and perforation are the most feared complications of endoscopic resection techniques in general. UEMR has shown exceptionally low rates of complications, with no perforations described in the most recent publications and delayed bleeding in only 5 % [1 – 4]. Bleeding during endoscopic resection has been more commonly reported. However, in most cases, only small persistent bleeds, easily managed during the procedure, occurred.

A 75-year-old woman was diagnosed with a 2.0-cm neoplastic lesion (0-IIa + Is) at the transverse colon during a screening colonoscopy (▶ **Fig. 1**). An underwater EMR technique was performed (▶ **Fig. 2**). Immediately after the procedure, both active bleeding and perforation were detected (▶ **Fig. 3**). Hemostasis at the bleeding site was achieved with thermal coagulation, and the perforation was successfully treated with through-the-scope clips. An endoscopic submucosal tattoo was placed near the resection site to facilitate a future surgical procedure in case of failure of the endoscopic closure attempt (▶ **Fig. 4**).

The patient remained under clinical observation and received antibiotic therapy with ciprofloxacin and metronidazole. After 1 day she was discharged with no symptoms or signs of complication. A control colonoscopy was performed 6 months after the procedure and showed no signs of recurrence (▶ **Fig. 5**).

Endoscopy_UCTN_Code_CPL_1AJ_2AD

Competing interests

The authors declare that they have no conflict of interest.

The authors

José Luiz Paccos, Daniela Suppo de Oliveira, Fernando J. S. de Oliveira, Eduardo M. A. Pereira Junior, Fernando L. Mota, Mayara M. C. da Silva[1], Paulo Alberto F. P. Corrêa
Department of Digestive Endoscopy, Hospital Sírio-Libanês, São Paulo, Brazil

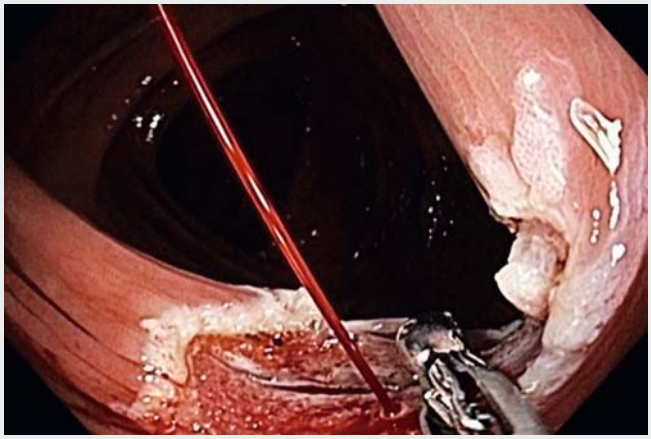

Video 1 Perforation and bleeding during an underwater endoscopic mucosal resection of a large colonic lesion.

Corresponding author

Fernando L. Mota, MD
Department of Digestive Endoscopy, Hospital Sírio-Libanês, Rua Dona Adma Jafet, 91, São Paulo, Brazil
Fax: +55-11-3394-0568
landerfernando@hotmail.com

References

[1] Binmoeller KF, Weilert F, Shah J et al. Underwater EMR without submucosal injection for large sessile colorectal polyps (with video). Gastrointestinal Endosc 2012; 75: 1086–1091
[2] Uedo N, Nemeth A, Johansson GW et al. Underwater endoscopic mucosal resection of large colorectal lesions. Endoscopy 2015; 47: 172–174
[3] Wang AY, Flynn MM, Patrie JT et al. Underwater endoscopic mucosal resection of colorectal neoplasia is easily learned, efficacious, and safe. Surg Endosc 2014; 28: 1348–1354
[4] Curcio G, Granata A, Ligresti D et al. Underwater colorectal EMR: remodeling endoscopic mucosal resection. Gastrointest Endosc 2015; 81: 1238–1242

Bibliography

Endoscopy 2021; 53: E326–E327
DOI 10.1055/a-1275-9832
ISSN 0013-726X
published online 23.10.2020

Georg Thieme Verlag KG, Rüdigerstraße 14, 70469 Stuttgart, Germany