

Analysis of droplets generated during gastrointestinal endoscopic examinations using a high speed camera

Droplets released from the mouth of a COVID-19 infected patient are an important source of infection [1]. Currently, gastrointestinal (GI) endoscopy preventative guidelines have been developed based on cough models with droplet travel distances of over 2 m [2–6]. However, the droplet-related studies reported so far have mostly focused on cough models related to respiratory disease. Thus far, no studies have been conducted on droplets generated during GI endoscopic examinations.

In this study, droplets released during GI endoscopy were analyzed using a high speed camera. In order to photograph small transparent droplets, a high speed camera (FASTCAM SA-3, Photon Limited, USA) was used with a black background and high brightness lighting, and the resulting footage was analyzed with post-processing software. A spray-bottle model and a cough model were used as control groups, and the droplets released during GI endoscopic examination were used as the experimental group. In order to change the level of released droplets, the sedative, proficiency of the endoscopist, and amount of gas injected

were each adjusted. In the control groups of the spray-bottle model and cough model, droplets were clearly photographed. However, regardless of changes in sedative, proficiency of the endoscopist, or amount of gas injected, no droplet larger than 10 μm in size was photographed during GI endoscopic examination (► **Fig. 1**).

In summary, no droplets were confirmed during GI endoscopic examination using high speed camera photography. The mouthpiece and the endoscope aided in suppressing the droplets being generated at the endoscope entry site. In colonoscopy examination, as the anus is blocked by the endoscope, intestinal fluids only trickled around the anus, and no secretions in the form of droplets were observed. These results will be helpful in the development of COVID-19 preventative measures for GI endoscopic examination.

Acknowledgment

The authors appreciate the technical support from the Institute of Construction and Environmental Engineering at Seoul National University.

Competing interests

The authors declare that they have no conflict of interest.

The authors

Dong Seok Lee, Ji Won Kim

Department of Gastroenterology, Seoul National University Boramae Medical Center, Seoul National University College of Medicine, Seoul, South Korea

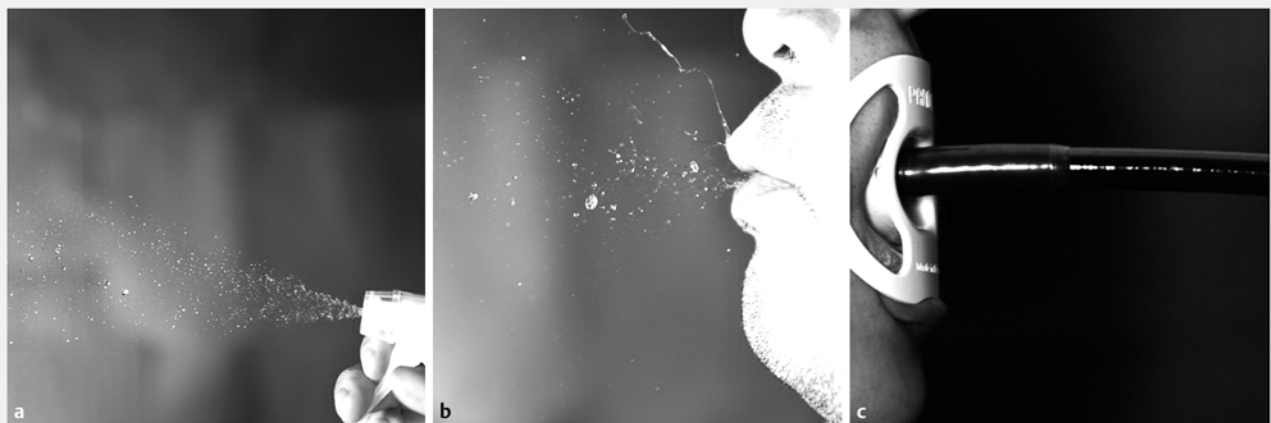
Corresponding author

Ji Won Kim, MD, PhD

Department of Gastroenterology, Seoul National University Boramae Medical Center, Seoul National University College of Medicine, Seoul, South Korea
kjwjor@snu.ac.kr

References

- [1] Phelan AL, Katz R, Gostin LO. The novel coronavirus originating in Wuhan, China: challenges for global health governance. *JAMA* 2020; 323: 709–710



► **Fig. 1** Photographic analysis of droplets using a high speed camera showing: **a** microscopic droplet release through a spray bottle; **b** droplet ejection from a normal coughing model; **c** the results of filming around the entry point of the endoscope during a procedure.

- [2] Bourouiba L. Images in clinical medicine. A sneeze. *NEJM* 2016; 375: e15
- [3] Bourouiba L, Dehandschoewercker E, Bush J. Violent expiratory events: on coughing and sneezing. *J Fluid Mech* 2014; 745: 537–563
- [4] Scharfman B, Tchet A, Bush J et al. Visualization of sneeze ejecta: steps of fluid fragmentation leading to respiratory droplets. *Exp Fluids* 2016; 57: 24
- [5] Chiu PWY, Ng SC, Inoue H et al. Practice of endoscopy during COVID-19 pandemic: position statements of the Asian Pacific Society for Digestive Endoscopy (APSDE-COVID statements). *Gut* 2020; 69: 991–996
- [6] Wong TW, Lee CK, Tam W et al. Cluster of SARS among medical students exposed to single patient, Hong Kong. *Emerg Infect Dis* 2004; 10: 269–276

Bibliography

Endoscopy 2021; 53: 207–208

DOI 10.1055/a-1272-3821

ISSN 0013-726X

published online 26.10.2020

© 2020. Thieme. All rights reserved.

Georg Thieme Verlag KG Rüdigerstraße 14,
70469 Stuttgart, Germany