

# Off-label use of 0.4% sodium hyaluronate teardrops: a safe and effective solution for submucosal injection in gastric endoscopic submucosal dissection



## Authors

Vitor Arantes<sup>1,2</sup>, Josue Aliaga Ramos<sup>3</sup>, Rafiz Abdul Rani<sup>4</sup>, Naohisa Yoshida<sup>5</sup>

## Institutions

- 1 Faculdade de Medicina da Universidade Federal de Minas Gerais – Alfa Institute of Gastroenterology, Minas Gerais, Brazil
- 2 Hospital Mater Dei Contorno – Endoscopy, Minas Gerais, Brazil
- 3 Cayetano Heredia Peruvian University, Lima, Peru
- 4 Universiti Teknologi MARA, Gastroenterology Unit, Faculty of Medicine, Selangor, Malaysia
- 5 Kyoto Prefectural University of Medicine, Molecular Gastroenterology and Hepatology, Kyoto, Japan

submitted 2.4.2020

accepted after revision 6.8.2020

## Bibliography

Endoscopy International Open 2020; 08: E1741–E1747

DOI 10.1055/a-1265-6598

ISSN 2364-3722

© 2020. The Author(s).

This is an open access article published by Thieme under the terms of the Creative Commons Attribution-NonDerivative-NonCommercial License, permitting copying and reproduction so long as the original work is given appropriate credit. Contents may not be used for commercial purposes, or adapted, remixed, transformed or built upon. (<https://creativecommons.org/licenses/by-nc-nd/4.0/>)

## Corresponding author

Vitor Arantes, MD, MSc, PhD, Endoscopy Division,  
Federal University of Minas Gerais, Belo Horizonte, Brazil  
arantesvitor@ufmg.br

## ABSTRACT

**Background and study aims** Submucosal (SM) injection is a critical step in endoscopic submucosal dissection

(ESD). In Japan, use of viscous solutions such as sodium hyaluronate are recommended; the commercially product available is MucoUp (Seikagaku Co. and Boston Scientific Japan Co., Japan). Nevertheless, MucoUp is expensive and unavailable in many Western countries. For the past 8 years, we have been using low-cost sterile teardrops solution composed of 0.4% sodium hyaluronate (Adaptis Fresh, Legend Laboratory, Brazil). This solution is readily available in drugstores with a cost of approximately US\$ 10.00 for each 10-cc bottle. The aim of this study was to present the clinical outcome with off-label sodium hyaluronate use for SM injection in gastric ESD.

**Patients and methods** A single-center retrospective study of collected data investigating consecutive patients that underwent gastric ESD between 2012 and 2019. ESD was performed using 0.4% sodium hyaluronate teardrop for SM injection and Flush Knife BT 2.5 (Fujifilm Co., Japan). The following data were analyzed: clinical-pathological features, en-bloc, R0 and curative resection rate, procedure duration, adverse events, and clinical outcome.

**Results** ESD was performed with sodium hyaluronate for submucosal injection in 78 patients. The en-bloc resection rate and R0 resection rate were 96.1% and 92.3%, respectively. The curative resection rate for epithelial lesions was 83.8%. Adverse events occurred in 5 cases (6.3%): delayed bleeding (3.8%, 3 cases) and perforation (2.5%, 2 cases); all managed successfully by clipping and thermal coagulation. The mean volume of sodium hyaluronate solution used per patient was 10 cc (SD: ± 8 cc). During follow-up (mean: 17 months; SD: ± 14.5 months), two patients developed metachronous lesions (2.5%).

**Conclusions** Off-label use of teardrops with 0.4% sodium hyaluronate for submucosal injection was demonstrated to be safe and able to provide an effective submucosal cushion that facilitates SM dissection in gastric ESD procedures.

## Introduction

Submucosal (SM) injection is a critical step during endoscopic submucosal dissection (ESD). In Japan, use of viscous solutions such as sodium hyaluronate (MucoUp, Seikagaku Co. Japan and

Boston Scientific Japan Co., Japan) is recommended due to its excellent ability to facilitate a good lift and create a prolonged and sustained SM cushion. However, this solution is expensive and only available in Japan [1–5]. For this reason, many Western researchers have developed solutions for SM injection with dif-

ferent substances that could replace MucoUp, facilitating ESD and reducing the rate of complications (perforation, hemorrhage) [1,6–10]. Over the last 8 years, our group has been using a sterile teardrop solution made of 0.4% sodium hyaluronate with optimal results. This solution is commercially available in standard pharmacies in Latin America at a low cost; approximately \$ 10.00 US dollars for a 10-cc bottle. The objective of this study was to present data on safety and clinical effectiveness of off-label use of the sodium hyaluronate teardrops solution for SM injection during gastric ESD.

## Patients and methods

A retrospective study was carried out of all patients who underwent ESD for gastric neoplasms using sodium hyaluronate as teardrops (Adaptis Fresh, Legrand Laboratory, Brazil) for SM injection, in an academic and tertiary level hospital in Brazil between 2012 and 2019. Patients in whom substances different than sodium hyaluronate were used as well as those with advanced tumors or presenting non-lifting sign were excluded. Moreover, we also excluded patients who declined informed consent for ESD, reported hypersensitivity to hyaluronic acid, presented with severe comorbidities or poor performance status unsuitable to undergo general anesthesia, had coagulopathy or were using anticoagulants continuously, which could not be withheld or for whom heparin-bridge therapy could not be used. For those patients using oral anticoagulants or new antiplatelet drugs, we discussed the management plan in a multidisciplinary fashion with prior classification of risk in each patient. If possible, we suspended those medications before the ESD, and when necessary, we administered low-molecular-weight heparin bridge therapy or maintained acetylsalicylic acid.

The information was collected from a database generated prospectively. The following clinicopathological data were reviewed: age, gender, histological type of the resected specimen, tumor size, procedure duration, and adverse events (AEs). Likewise, the rates of en-bloc resection, complete resection with negative margins (R0 resection) and curative resection of epithelial lesions were calculated according to current expanded criteria determined by Japanese guidelines ( $\geq 2$  cm in diameter, predominantly differentiated type pT1a without ulceration;  $< 3$  cm predominantly differentiated type pT1a with ulcer;  $< 2$  cm predominantly undifferentiated type pT1a and no ulcer;  $< 3$  cm predominantly differentiated type pT1b (SM1) and no lymphatic or vascular invasion and with negative surgical margins) [1]. En-bloc resection was defined as removal of the entire tumor in one piece. Curative resection was calculated only for epithelial lesions and it was based on the histological assessment of ESD specimen. If histology revealed compromised margins or poor prognostic features such as lymphovascular invasion, the procedure was deemed non-curative. Furthermore, if deep SM invasion  $> 500$   $\mu$ m beyond the muscularis mucosae was noted in specimens with adenocarcinoma, the resection was also considered non-curative. Patients with non-curative resection were subsequently referred for surgical consultation and consideration for gastrectomy, unless the clinical

condition was deemed unfit for surgery. The management plan for patients after curative ESD was to repeat EGD (control) at 3 months to check on the healing process or any residual lesions, and subsequent annual surveillance in search of recurrence or metachronous tumors.

All patients were treated by the same endoscopist (VA), who received formal theoretical and practical training in Japan with opportunities to assist experts in human procedures and to perform ESD under supervision on animal models. When use of the teardrop sodium hyaluronate solution was initiated, the operator had already performed over 40 ESD procedures, and thus, had enough experience to overcome the initial phase of the learning curve.

For all ESD procedures, the following devices were utilized: Flush Knife BT 2.5 (Fujifilm Co., Japan); a therapeutic gastroscopy was used with a working channel of 3.2 mm (EG-450 RD, Fujifilm Co., Japan) connected to the electrosurgical unit (ERBE VIO 200S, 200D or 300D, Tubingen, Germany), a 4-mm cap (Top Co., Japan) attached to the tip of the endoscope and a 25-gauge needle (Boston Scientific Co., United States) for SM injection. The following steps were carried out during ESD: demarcation (Marking): soft coagulation mode, effect 6, 100 watts; mucosal incision: Endocut I, effect 2, cut duration 3, cut interval 2; SM dissection: forced coagulation mode effect 3, 50 watts; blood vessel hemostasis: soft coagulation mode, effect 6, 100 watts. Blood vessels were sealed with Flush Knife or coagulation forceps (Coagrasper, Olympus Co., Japan). Teardrop sodium hyaluronate solution was used as is or, at the discretion of the endoscopist, mixed with saline solution 1/1 and a low dose of epinephrine (0.02 mg corresponding to a concentration of 1/100000). No dye was added to the solution. In addition to SM injection of sodium hyaluronate teardrop, water jet saline injection into the SM layer through the sheath of the knife during dissection was added at the discretion of the endoscopist.

## Statistical analysis

Tabulation of data was carried out using Microsoft Excel for Windows 2010 and the statistical analysis was carried out using the Stata software version 15 (Stata Corporation, College Station, Texas, United States), considering a 5% significance level. A descriptive analysis of data was performed with frequency and proportion for categorical and average variables, standard deviation, median and mean  $\pm$ SD for continuous variables.

## Ethical considerations

The authors followed the Declaration of Helsinki recommendations concerning scientific research, including data confidentiality of each of the enrolled patients. Institutional review board approval was obtained for this retrospective study. All patients received detailed information about the ESD intervention ahead of the procedure and were requested to sign a consent form. Patients who declined to sign the consent form did not proceed to ESD. Before using the product, scientific discussions were had with the pharmacy department committee that approved the off-label use of teardrop sodium hyaluronate during ESD procedures. There was no influence on this research from the company that manufactures the substance, and the authors

► **Table 1** Clinicopathological characteristics of the patients.

Types of gastric lesions with SH teardrop injection (n = 78 patients)	n (%)
Intraepithelial neoplasia	
▪ Low-grade	12 (15.3%)
▪ High-grade	22 (28.3%)
Adenocarcinoma	
▪ Differentiated adenocarcinoma	28 (96.5%)
▪ Undifferentiated adenocarcinoma	1 (3.5%)
Invasion depth (adenocarcinoma)	
▪ Intramucosal (T1a)	22 (75.8%)
▪ Submucosal invasion (T1b)	(24.2%)
▪ Superficial submucosa (SM1)	1 (14.3%)
▪ Deep submucosa (SM2)	6 (85.7%)
Other lesions	
▪ Neuroendocrine tumor	2 (2.5%)
▪ Subepithelial lesion	8 (10.2%)
▪ Polypoid lesions	5 (6.4%)
Mean procedure duration in minutes (range)	105.3 min (SD: ± 51.6 minutes)
Mean tumor size (range)	28.4 mm (SD: ± 11.2 mm)

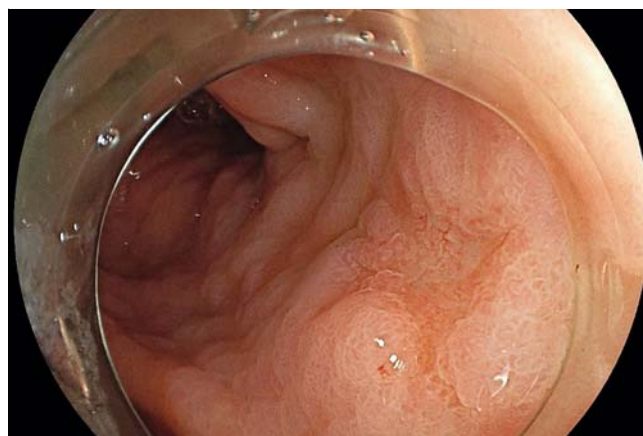SH, sodium hyaluronate; SM, submucosa.

have no commercial relationship, patent interest or conflict of interest to be declared.

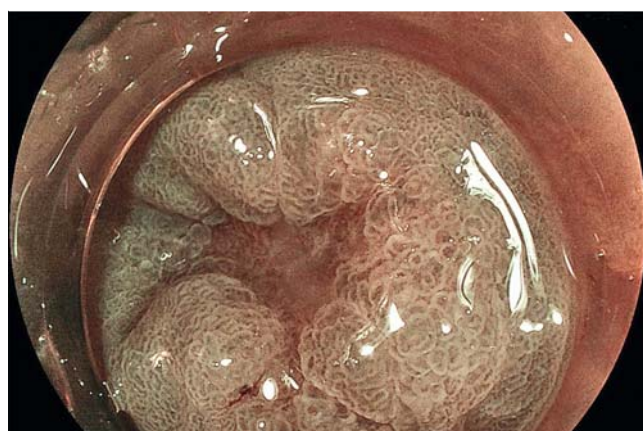## Results

During the aforementioned study period, 83 gastric ESD procedures were performed (40 males/43 females). Five patients were excluded (6%) due to the use of other solutions apart from sodium hyaluronate, such as voluven (1), hydroxypropyl methylcellulose (HPMC) (1) and saline solution (2), or due to presence of non-lifting sign (1). Thus, a total of 78 patients underwent gastric ESD with the use of sodium hyaluronate teardrop for SM injection and entered the study. The mean age was 68 years old (SD: ± 12.8 years). The mean size of the resected lesions was 28.4 mm (SD: ± 11.2 mm). The topographical distribution of the resected lesions was as follows: lower third –25 cases (32%); middle third –47 cases (60%); upper third –six cases (8%).

The mean duration of the procedure was 105.3 minutes (SD: ± 51.6 minutes) Histology of resected specimens revealed low-grade intraepithelial neoplasia: 12 patients (15.3%); high-grade intraepithelial neoplasia: 22 patients (28.3%); adenocarcinoma: 29 cases (37.2%); neuroendocrine tumors (NET): two patients (2.5%); polypoid lesions: five patients (6.4%) and subepithelial



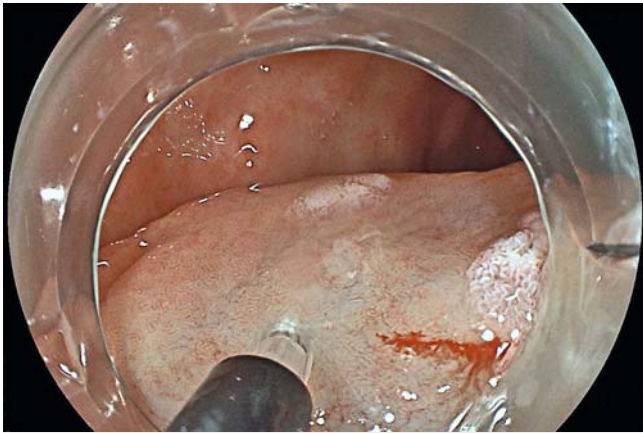► **Fig. 1** A depressed-type lesion (0IIc) in the antrum.



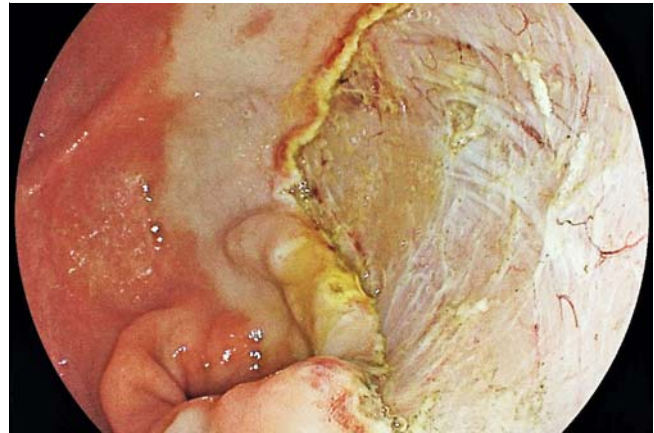► **Fig. 2** Virtual chromoendoscopy with BLI (Blue Laser Imaging, Fujifilm Co., Japan).

lesions in eight patients (10.2%). Clinicopathological characteristics of the patients are shown in ► **Table 1**. ► **Fig. 1**, ► **Fig. 2**, ► **Fig. 3**, ► **Fig. 4**, ► **Fig. 5**, and ► **Fig. 6** are illustrative of use of teardrop sodium hyaluronate solution for SM injection in a patient with superficial gastric neoplasm.

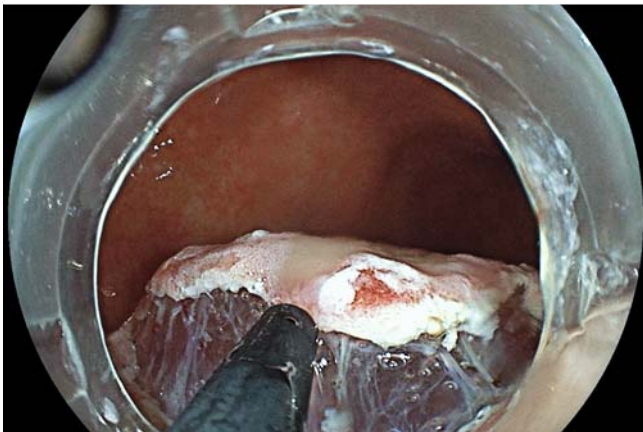
Regarding the 78 resected lesions included in this study, the en-bloc resection rate was 96.1% (75/78) and the R0 resection rate was 92.3% (72/78) (► **Table 2**). ESD was considered curative for epithelial lesions based on the expanded criteria from the latest Japanese guidelines [1] in 83.8% of the subjects (57/68). ► **Table 3** describes the list of 11 non-curative cases and subsequent clinical management. A total of six patients (54.5%) were referred to gastrectomy and a decision was made for a conservative clinical management in the other five cases. Three patients with positive lateral margins and one patient with minimal SM2 invasion (650 µm) were advised to undergo close endoscopic surveillance with no recurrence thus far. The remaining patient was elderly, had comorbidities and a tumor located in the cardia, and refused to undergo surgery. This patient has more than 7 years of follow-up without recurrence thus far.



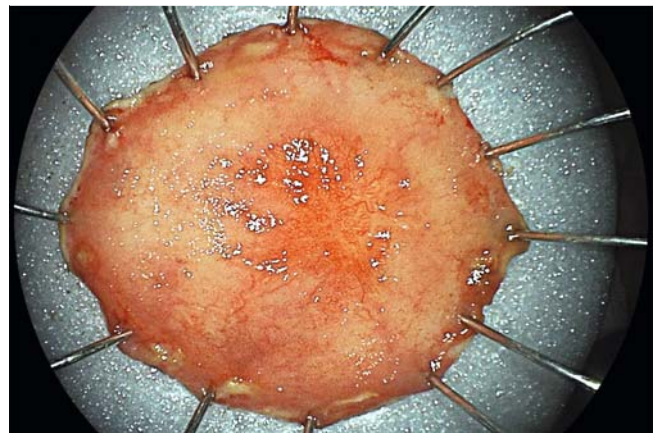
► **Fig. 3** After placement of markings submucosal injection was performed with teardrop solution with 0.4% sodium hyaluronate showing an effective lifting.



► **Fig. 5** Complete tumor resection was achieved en-bloc without injury to muscularis propria.



► **Fig. 4** After semi-circumferential mucosal incision additional submucosal injection was added demonstrating a clear view of the expanded submucosal space.



► **Fig. 6** The specimen revealed intraepithelial high-grade neoplasia limited to the epithelium (M1) with free margins and no lymphatic or vascular invasion.

A total of five patients (6.3%) had complications related to ESD: perforation occurred in two cases (2.5%) and delayed bleeding in three cases (3.8%), which were managed successfully with thermal coagulation and clipping closure of the defect. It is worth noting that there were no cases of mortality (0%) or rescue emergency surgery, nor systemic infection (bacteremia) or fever requiring antibiotics. The mean volume of teardrop sodium hyaluronate solution used per patient was 10 cc (SD:  $\pm 8$  cc). A total of 49 patients out of 78 included cases (62.8%) returned for endoscopic postoperative control, with a mean follow-up period of 17 months (SD:  $\pm 14.5$  months). At follow-up EGD, no tumor recurrence was encountered and two patients developed metachronous gastric tumors (2.5%).

## Discussion

SM injection is a critical step in the execution of a safe and effective ESD procedure. For this reason, different research groups have attempted to investigate suitable solutions for

this procedure [1,5–10]. In this study, we review our experience using an inexpensive and readily available sodium hyaluronate solution commercialized as a sterile teardrop for use in ophthalmology. The clinical outcome obtained in this study, which demonstrates a high rate of en-bloc resection (96.1%) and absolute absence of local or systemic complications related to the use of this substance, presents a new solution for SM injection during ESD operations. Teardrop sodium hyaluronate provides a long-lasting fluid cushion and the majority of gastric ESD procedures can be completed with a single bottle of the solution, without substantially increasing the cost of the intervention. Moreover, the sodium hyaluronate teardrop solution was demonstrated to be useful for a broad range of gastric lesions that may be resected by ESD, such as epithelial or subepithelial tumors, neuroendocrine tumors, and polypoid lesions [11–15].

Viscous solutions are widely used by Japanese experts for SM injection in ESD because of the excellent results with formation of a long-lasting cushion that facilitates the process of SM dissection and improves the endoscopic view of the SM space [16, 17]. One of the most representative studies demonstrating the

► **Table 2** Clinical outcomes using sodium hyaluronate teardrops for submucosal injection in 78 patients.

Outcomes	n (%)
Procedure	
▪ En-bloc resection	75/78 (96.1%)
▪ R0 resection	72/78 (92.3%)
▪ Curative resection (for epithelial lesions)	57/68 (83.8%)
Complications	
▪ Perforation	2 (2.5%)
▪ Delayed bleeding	3 (3.8%)
▪ Bacteremia/infection	0 (0.0%)
▪ Mortality	0 (0.0%)
Recurrence rate	
▪ Metachronic lesions	2 (2.5%)
▪ Tumor recurrence	0 (0%)
Mean follow-up period	17 months (SD: ± 14.5 months)

benefit of these viscous solutions compared with saline solution was the meta-analysis in which the authors reviewed five prospective studies (504 patients) and concluded that viscous solutions were superior to saline solution in terms of en-bloc resection rate (73.2% vs. 67.3%) and local recurrence rate (11.6% vs. 18.5%) [18]. Nevertheless, in another systematic review that included 54 studies (792 patients/793 lesions), use of 0.4% sodium hyaluronate for SM injection was not superior compared with saline solution, and no statistically significant differ-

ence in the rate of complete resection or complications was noted [19].

Gastric neoplasms were among the first conditions in which sodium hyaluronate was used for SM injection in ESD, mainly in Japan with very good results, subsequently having been applied successfully to other organs such as the esophagus and colorectum [20–24]. In a multicenter prospective study, an optimal elevation of gastric mucosa was achieved in 73.5% of cases (50/68 lesions) using sodium hyaluronate, facilitating endoscopic resection in 88.3% (60/69) of cases and resulting in an en-bloc resection rate of 92.8% [25]. These findings were reproduced in our investigation, but interestingly applied in a different population while using a variant of the original solution of 0.4% sodium hyaluronate – MucoUp – which is available exclusively in Japan and is costly.

Over the last several years, experience with using 0.4% sodium hyaluronate for ESD in the treatment of superficial neoplasms of the gastrointestinal tract has been extended to the esophagus, achieving excellent results in expert hands despite the higher degree of technical and operative difficulty [26, 27]. In one of the most important studies that showed the great advantages of using 0.4% sodium hyaluronate in the esophagus, the en-bloc resection rate was 99% in 86 patients with superficial squamous neoplasms of the esophagus (106/107 resected lesions) and the complete resection rate was 93% (99/107) with complications arising in only 6% (6/107) of cases [28]. This encouraged many researchers, especially Latin Americans, to reproduce this experience; albeit the main drawback of the lack of availability of MucoUp solution used in Japan; which subsequently motivates some research groups in the West to search for other alternatives [29, 30], which could result in similar rates of efficiency and safety. One of the few studies representative of the benefits of the use of 0.4% sodium hyaluronate teardrops for SM injection of esophageal ESD was recently

► **Table 3** List of patients with criteria for non-curative resection and management plan.

List of cases	Criteria for non-curative resection	Management plan
1	R0 resection with SM2 invasion (2000 µ) + lymphatic/vascular invasion	Conservative
2	R0 resection with SM2 invasion (1700 µ)	Gastrectomy
3	R0 resection undifferentiated adenocarcinoma (M3) with vascular invasion	Gastrectomy
4	SM2 invasion (700 µ) + compromise of deep margin + lymphatic/vascular invasion	Gastrectomy
5	R0 resection with SM2 invasion (1600 µ)	Gastrectomy (negative surgical specimen)
6	Focal compromise of lateral margins	Conservative
7	R0 resection with SM2 invasion (650 µ)	Conservative
8	SM2 invasion (1700 µ) + lymphatic/vascular invasion + compromised deep margin (converted to piecemeal)	Gastrectomy
9	Focal compromise of lateral margins (converted to piecemeal)	Conservative
10	R0 resection SM1 invasion (200 µ) + lymphatic/vascular invasion + tumoral budding	Gastrectomy (stomach clear, 1 positive lymph node)
11	Focal compromise of lateral margins (lesion resected in 2 pieces)	Conservative

SM, submucosal; M3, muscularis mucosae.

published by our group [31], using this same ophthalmologic compound for SM injection in 66 patients with superficial neoplasms of the esophagus (70 esophageal ESD procedures) and achieving en-bloc, R0, and curative resection rates of 97%, 90%, and 80%, respectively, with a complication rate of 4.28% (3/70). This study showed the positive experience of using sodium hyaluronate teardrops, as in gastric ESD, confirming and extending the excellent results obtained in the esophagus to other segments of the digestive tract. We have also been using sodium hyaluronate teardrop solution for colorectal ESD (almost 40 cases, unpublished results), and observed the same benefit profile experienced in the esophagus and stomach.

Recently, new solutions for SM injection have been tested with promising results regarding efficiency and safety for resection of early neoplasms of the gastrointestinal tract. In the Western Hemisphere, some innovative viscous substances for submucosal injection in ESD have been proposed such as hydroxyethyl starch (Hetastarch/Volugen), hydroxypropyl methylcellulose (Gonak) and SIC-8000 (Eleview). Few head-to-head comparisons have been done of the different substances. Recently a randomized controlled trial compared the efficacy and safety of SIC-8000 and Hetastarch in EMR for colorectal lesions [32]. In a population of 158 patients (159 adenomas) the authors reported a mean Sydney resection quotient of 9.3 for SIC-8000 and 8.1 for Hetastarch ( $P=0.001$ ), an en-bloc resection rate of 21% (18/84 lesions) for SIC-8000 and 19% (14/75 lesions) for Hetastarch ( $P=0.515$ ). The mean volume used was 14.8 mL for SIC-8000 and 20.6 mL for Hetastarch ( $P=0.038$ ). Both substances presented similar duration and elevation of the SM cushion. The authors concluded that the use of SIC-8000 (Eleview) was more effective than Hetastarch for SM injection in endoscopic resection [32].

Experimental studies also have investigated substances for SM injection for ESD in pig models. Mehta et al reported that the solutions with the best indexes of mucosa elevation (measured in mm) and the duration of the SM cushion (measured in minutes) were hydroxyethyl starch and SIC-8000 (Eleview, Boston Scientific Co., United States) enabling faster and easier dissection, both with better results than hydroxypropyl methylcellulose [33]. However, it is important to note that in the same study, the 0.4% sodium hyaluronate solution performed similarly to the aforementioned substances, which highlight that sodium hyaluronate solution seems to be ideally matched for this type of endoscopic procedure [33]. Therefore, considering that standard sodium hyaluronate solution (MucoUp) is unavailable outside Japan and is costly, the off-label use of 0.4% sodium hyaluronate teardrops for ESD, a substance easily available in standard drugstores, may be the perfect solution to bridge this gap [34].

Our study had some limitations. It was a single-center experience and all procedures were carried out by one trained operator and the results need to be reproduced in other centers. In addition, the number of SM injections of teardrop sodium hyaluronate made throughout the procedure, as well as the additional volume of saline solution injected during dissection through the knife, were not measured. Another limitation of our study was the relatively small population of patients enrol-

led in comparison with Japanese studies. However, in Latin America and also in many Western countries, the experience with gastric ESD is still limited and inferior, in terms of number of procedures, to the experience reported in Asia. Therefore, we acknowledge that large-scale prospective studies with larger cohorts of patients and a longer follow-up period are needed to extrapolate our results at a worldwide level. Hence, comparative randomized trials with other solutions are also needed to better establish the role of teardrop sodium hyaluronate in ESD.

## Conclusion

In conclusion, off-label use of 0.4% sodium hyaluronate teardrops for SM injection in gastric ESD was demonstrated to be an excellent alternative in countries where standard sodium hyaluronate is unavailable or too costly, facilitating high-quality ESD procedures with efficiency and safety while obtaining clinical outcomes similar to those achieved by Japanese experts in referral centers.

## Acknowledgments

The authors thank all members of the Endoscopy Unit and Pharmacy Department, Alfa Institute of Gastroenterology, Federal University of Minas Gerais and also of the Department of Molecular Gastroenterology and Hepatology, Kyoto Prefectural University of Medicine, for their collaboration in this study.

## Competing interests

The authors declare that they have no conflict of interest.

## References

- [1] Ono H, Yao K, Fujishiro M et al. Guidelines for endoscopic submucosal dissection and endoscopic mucosal resection for early gastric cancer. *Digest Endosc* 2016; 28: 3–15
- [2] Uemura N, Oda I, Saito Y et al. Efficacy and safety of 0.6% sodium alginate solution in endoscopic submucosal dissection for esophageal and gastric neoplastic lesion: A randomized controlled study. *Digest Endosc* 2019; 31: 396–404
- [3] Takatori Y, Uraoka T, Narita T et al. Safety and Usability of temperature-response collagen-genipin sols as a novel submucosal injection material for endoscopic resection. *Endosc Int Open* 2019; 07: E561–E567
- [4] Kim Y, Lee J, Cho J et al. Efficacy and safety of 0.4 percent sodium hyaluronate for endoscopic submucosal dissection of gastric neoplasms. *World J Gastroenterol* 2013; 19: 3069–3076
- [5] Obata D, Morita Y, Kawaguchi R et al. Endoscopic submucosal dissection using a carbon dioxide laser with submucosally injected laser absorber solution (porcine model). *Surg Endosc* 2013; 27: 4241–4249
- [6] Akagi T, Yasuda K, Tajima M et al. Sodium alginate as an ideal submucosal injection material for endoscopic submucosal resection: preliminary experimental and clinical study. *Gastrointest Endosc* 2011; 74: 1026–1032

- [7] Ishihara M, Kumano I, Hattori H et al. Application of hydrogels as submucosal fluid cushions for endoscopic mucosal resection and submucosal dissection. *J Artif Organs* 2015; 18: 191–198
- [8] Polymeros D, Kotsalidis G, Triantafyllou K et al. Comparative performance of novel solutions for submucosal injection in porcine stomachs: An ex vivo study. *Digest Liver Dis* 2010; 42: 226–229
- [9] Fujishiro M, Yahagi N, Nakamura M et al. Successful outcomes of a novel endoscopic treatment for GI tumors: endoscopic submucosal dissection with a mixture of high-molecular-weight hyaluronic acid, glycerin and sugar. *Gastrointest Endosc* 2006; 63: 243–249
- [10] Uraoka T, Kawahara Y, Ohara N et al. Carbon dioxide submucosal injection cushion: An innovative technique in endoscopic submucosal dissection. *Digest Endosc* 2011; 23: 5–9
- [11] Kang K, Min B, Lee J et al. Alginate hydrogel as a potential alternative to hyaluronic acid as submucosal injection material. *Dig Dis Sci* 2013; 58: 1491–1496
- [12] Tran R, Palmer M, Tang S et al. Injectable drug-eluting elastomeric polymer: a novel submucosal injection material. *Gastrointest Endosc* 2012; 75: 1092–1097
- [13] Liu W, Zhao M, Liu W et al. A feasibility study of a thermally sensitive elastin-like polypeptide for submucosal injection application in endoscopic resection in 3 animal models. *Gastrointest Endosc* 2015; 82: 944–952
- [14] Ishizuka T, Hayashi T, Ishihara M et al. Submucosal injection, for endoscopic mucosal resection, of photocrosslinkable chitosan hydrogel in DMEM/F12 medium. *Endoscopy* 2007; 39: 428–433
- [15] Kusano T, Etoh T, Akagi T et al. Evaluation of 0.6% sodium alginate as a submucosal injection material in endoscopic submucosal dissection for early gastric cancer. *Digest Endosc* 2014; 26: 638–645
- [16] Pioche M, Lépilliez V, Déprez P et al. High pressure jet injection of viscous solutions for endoscopic submucosal dissection (ESD): first clinical experience. *Endosc Int Open* 2015; 03: E368–E372
- [17] Wedi E, Koehler P, Hochberger J et al. Endoscopic submucosal dissection with a novel high viscosity injection solution (LiftUp) in an ex vivo model: a prospective randomized study. *Endosc Int Open* 2019; 07: E641–E646
- [18] Yandrapu H, Desai M, Siddique S et al. Normal saline solution versus other viscous solutions for submucosal injection during endoscopic mucosal resection: a systematic review and meta-analysis. *Gastrointest Endosc* 2017; 85: 693–699
- [19] Ferreira A, Moleiro J, Torres J et al. Solutions for submucosal injection in endoscopic resection: a systematic review and meta-analysis. *Endosc Int Open* 2016; 4: E1–E16
- [20] Nakamura J, Hikichi T, Watanabe K et al. Usefulness and safety of sodium carboxymethylcellulose and sodium hyaluronate as submucosal injectants for gastric endoscopic submucosal dissection: a prospective randomized comparative trial. *Gastrointest Endosc* 2018; 87: AB182–AB183
- [21] Kizu T, Uedo N, Chatanim R et al. A prospective randomized controlled trial comparing “0.4% sodium hyaluronate” versus “normal saline solution” for endoscopic submucosal dissection in gastric neoplasia by supervised residents. *Gastrointest Endosc* 2010; 71: AB104–AB105
- [22] Yoshida N, Naito Y, Kugai M et al. Efficacy of hyaluronic acid in endoscopic mucosal resection of colorectal tumors. *J Gastroenterol Hepatol* 2011; 26: 286–291
- [23] Repici A, Wallace M, Sharma P et al. A novel submucosal injection solution for endoscopic resection of large colorectal lesions: a randomized, double-blind trial. *Gastrointest Endosc* 2018; 88: 527–535
- [24] Hurlstone D, Fu K, Brown S et al. EMR using dextrose solution versus sodium hyaluronate for colorectal Paris type I and 0–II lesions: a randomized endoscopist-blinded study. *Endoscopy* 2008; 40: 110–114
- [25] Yamamoto H, Yahagi N, Oyama T et al. Usefulness and safety of 0.4% sodium hyaluronate solution as a submucosal fluid “cushion” in endoscopic resection for gastric neoplasms: a prospective multicenter trial. *Gastrointest Endosc* 2008; 67: 830–839
- [26] Nishimura M, Yamamoto H, Kita H et al. Successful en bloc resection of large superficial esophageal cancer using sodium hyaluronate and small-caliber-tip transparent hood. *Gastrointest Endosc* 2004; 59: 257
- [27] Kumano M, Ishihara M, Nakamura S et al. Endoscopic submucosal dissection for pig esophagus by using photocrosslinkable chitosan hydrogel as submucosal fluid cushion. *Gastrointest Endosc* 2012; 75: 841–848
- [28] Iwashita C, Sakamoto H, Miura Y et al. Esophageal endoscopic submucosal dissection using sodium hyaluronate is safe and effective. *Min Invasive Ther Allied Tech* 2018; 27: 171–176
- [29] Al-Taie O, Bauer Y, Dietrich C et al. Efficacy of submucosal injection of different solutions inclusive blood components on mucosa elevation for endoscopic resection. *Clin Exp Gastroenterol* 2012; 5: 43–48
- [30] Córdova H, Cuatrecasas M, García-Rodríguez A et al. Successful outcomes of a new combined solution of hyaluronic acid, chondroitin sulfate and poloxamer 407 for submucosal injection: animal survival study. *Endosc Int Open* 2019; 7: E576–E582
- [31] Arantes V, Gardone R, Pedrosa MS. Off-Label use of tears drops with sodium hyaluronate for submucosal injection in esophageal ESD: Is it safe and effective? *Gastrointest Endosc* 2019; 89: AB451–AB452
- [32] Rex D, Broadley H, Garcia J et al. SIC-8000 versus hetastarch as a submucosal injection fluid for EMR: a randomized controlled trial. *Gastrointest Endosc* 2019; 90: 807–812
- [33] Mehta N, Strong A, Franco M et al. The optimal injection solution for endoscopic submucosal dissection: a randomized controlled trial of western solutions in a porcine model. *Digest Endosc* 2018; 30: 347–353
- [34] Niimi K, Fujishiro M, Kodashima S et al. Subserosal injection of hyaluronic acid may prevent perforation after endoscopic resection. *World J Gastrointest Endosc* 2009; 1: 61–64

## CORRECTION

**Vitor Arantes, Josue Aliaga Ramos, Rafiz Abdul Rani et al. Off-label use of 0.4% sodium hyaluronate tear-drops: a safe and effective solution for submucosal injection in gastric endoscopic submucosal dissection**

*Endoscopy International Open* 2020; 08: E1741–E1747.  
DOI: 10.1055/a-1265-6598

In the above mentioned article was the order of the authors incorrect. Correct is: Vitor Arantes, Josue Aliaga Ramos et al.

The institutions were adapted to the new order.

Further the corresponding address was changed to:

Vitor Arantes, MD, MSc, PhD, Endoscopy Division,  
Federal University of Minas Gerais, Belo Horizonte, Brazil  
E-mail: arantesvitor@ufmg.br

On page E1744 “increasing” was written twice. The corrected sentence is:

Teardrop sodium hyaluronate provides a long-lasting fluid cushion and the majority of gastric ESD procedures can be completed with a single bottle of the solution, without substantially increasing the cost of the intervention.