Article published online: 2020-10-08

Endoscopic band ligation for weight loss

▶ **Fig. 1** Endoscopic view showing the band ligation cap.

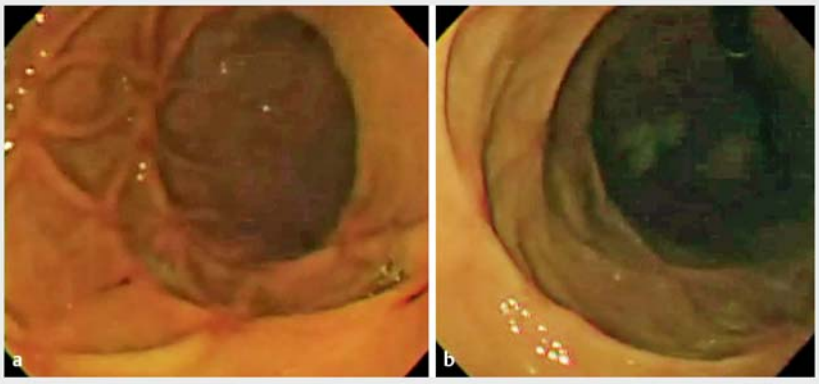

▶ **Fig. 2** Endoscopic views 1 month after the procedure showing nice linear scars of healed post-band ulcers in the body **a** on forward view; **b** on retroversion.

Video 1 Endoscopic band ligation for weight loss, with 33 bands applied in five parallel rows throughout the gastric body, producing well-healed linear scars on follow-up 1 month later.

To the best of our knowledge, this is the first study to use endoscopic band ligation for weight loss in a 30-year-old woman, who had an initial weight of 85 kg (height 155 cm; body mass index [BMI] 35.4 kg/m^2). Endoscopy was performed with the patient sedated using propofol. All ligatures were applied in the gastric body, starting at the distal body; five parallel rows were created, with the last one in the proximal body, using 33 bands (▶ **Fig. 1**). The entire procedure was completed in 30 minutes. Oxygen was used for endoscopic air insufflation. Notably, no immediate complications occurred during endoscopy (▶ **Video 1**).

The patient did well after the procedure and was discharged after 2 hours. In the first 3 days, she complained of mild nausea, vomiting, and epigastric pain, which were controlled by medications (pantoprazole 40 mg twice daily for the first month, plus antiemetics and antispasmodics on demand). For 2 weeks, she was given a fully liquid diet, followed by an 800-calorie soft diet for another 2 weeks. The patient reported early satiety following the procedure. Follow-up endoscopy after 1 month revealed nice linear scars of healed ulcers in the gastric body (▶ **Fig. 2**), causing marginal narrowing of the lumen. In addition, the patient's weight had decreased from 85 to 79 kg and her BMI from 35.4 to 32.9 kg/m^2, corresponding to a 7 % total weight loss and a 24 % excess weight loss after 1 month.

Endoscopic band ligation for weight loss is a novel technique that could assist in obesity management. The technique appears safe, repeatable, and cost-effective, with a short learning curve. Nevertheless, further large-scale studies are warranted using more bands, longer caps, and prolonged follow-up to assess the efficacy and safety of the technique as a primary and secondary endoscopic weight loss procedure [1, 2].

Endoscopy_UCTN_Code_TTT_1AO_2AN

This document was downloaded for personal use only. Unauthorized distribution is strictly prohibited.

Competing interests

The authors declare that they have no conflict of interest.

The authors

Mohamed Abeid[1,2], Tarek Kaddah[2,3]

1 Endoscopy Unit, Kasr Al Aini School of Medicine, Cairo University, Cairo, Egypt
2 El Katib Hospital, Giza, Egypt
3 Anesthesia Department, Kasr Al Aini School of Medicine, Cairo University, Cairo, Egypt

Corresponding author

Mohamed Abeid, MD
GIT Endoscopy Unit, Kasr Al Aini School of Medicine, Cairo University, El Manial, Cairo 12111, Egypt
mohamedabeid@gmail.com

References

[1] Keohane J, Berro W, Harewood GC et al. Band ligation of gastric antral vascular ectasia is a safe and effective endoscopic treatment. Dig Endosc 2013; 25: 392–396
[2] Jirapinyo P, Thompson CC. Endoscopic gastric body plication for the treatment of obesity: technical success and safety of a novel technique. Gastrointest Endosc 2020; 6: 1388–1394

Bibliography

Endoscopy 2021; 53: E287–E288
DOI 10.1055/a-1264-6360
ISSN 0013-726X
published online 8.10.2020
© 2020. Thieme. All rights reserved.
Georg Thieme Verlag KG, Rüdigerstraße 14, 70469 Stuttgart, Germany

ENDOSCOPY E-VIDEOS
https://eref.thieme.de/e-videos

Endoscopy E-Videos is a free access online section, reporting on interesting cases and new techniques in gastroenterological endoscopy. All papers include a high quality video and all contributions are freely accessible online.

This section has its own submission website at https://mc.manuscriptcentral.com/e-videos

This document was downloaded for personal use only. Unauthorized distribution is strictly prohibited.