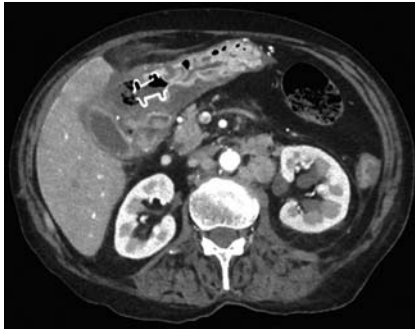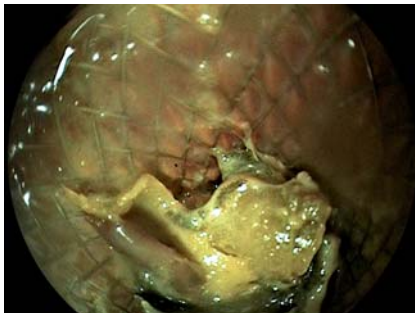


Food impaction mimicking dislodgment of a lumen-apposing metal stent in a patient undergoing endoscopic ultrasound-guided gallbladder drainage for acute cholecystitis

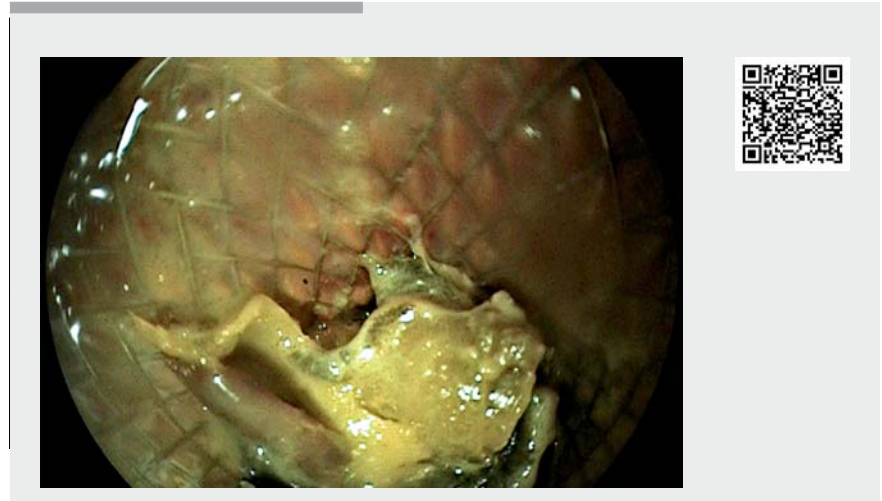


► **Fig. 1** Computed tomography scan showed the dislodged lumen-apposing metal stent in the gastric cavity and intra-peritoneal fluid collection with air bubbles between the stomach and the gallbladder.

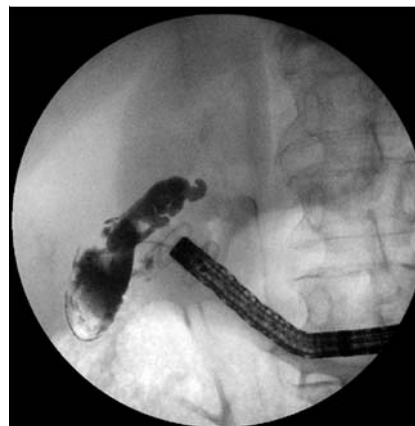

► **Fig. 2** Endoscopic ultrasound showed the lumen-apposing metal stent to be in place but obstructed by food impaction, which was removed with a snare.

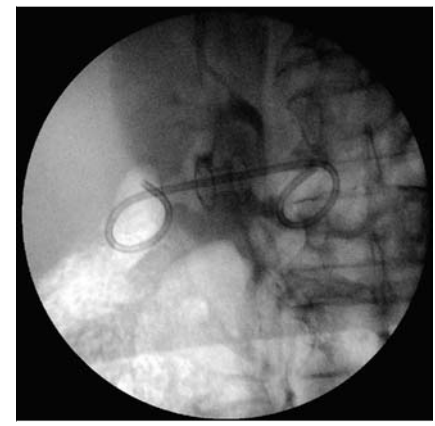
A 77-year-old woman who was unsuitable for surgery underwent endoscopic ultrasound-guided gallbladder drainage (EUS-GBD) using a lumen-apposing metal stent (LAMS) for acute cholecystitis. Her clinical history included lung adenocarcinoma and a recent development of pulmonary embolism. Chronic medication included immunotherapy and low molecular weight heparin. She was admitted again with a complaint of pain in the right hypochondrium and hyperpyrexia about 2 weeks after the procedure.



► **Video 1** Suspected dislodgment of a lumen-apposing metal stent (LAMS) was in fact an obstruction due to food impaction. After endoscopic debridement, a plastic pigtail stent was placed through the LAMS to prevent future occlusions.



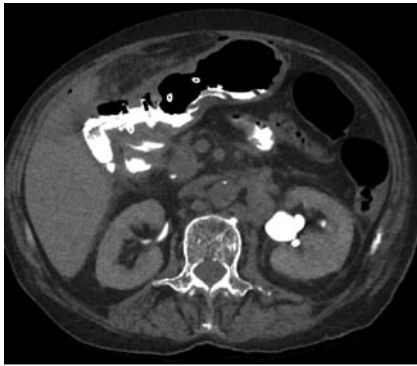
► **Fig. 3** Fluoroscopy showed no leakage of contrast medium.



► **Fig. 4** Fluoroscopic image of pigtail stent placement through the lumen-apposing metal stent.

Initially, a computed tomography (CT) scan showed that the LAMS had dislodged into the gastric cavity, and an intra-peritoneal fluid collection with air bubbles extended for about 35 cm between the stomach and the gallbladder (► **Fig. 1**). EUS showed the LAMS to be

in place but obstructed by food residue, which was removed with a snare (► **Fig. 2**, ► **Video 1**). After injection of contrast medium into the gallbladder through the stent, fluoroscopy excluded leakage (► **Fig. 3**). A



► **Fig. 5** Computed tomography scan following administration of contrast showed the lumen-apposing metal stent in place, and the distal ends of the pigtail stent in the gastric and gallbladder cavities. No leakage of contrast medium was seen.

plastic pigtail stent was placed through the LAMS to prevent future occlusions (► **Fig. 4**).

CT scan following contrast administration through the nasogastric tube showed outcomes of gallbladder drainage, with the LAMS in place and the distal ends of the pigtail stent in the gastric and gallbladder cavities, and no leakage of contrast medium (► **Fig. 5**). The patient's symptoms subsequently resolved. Stent occlusion (secondary to food bolus, gallstones, clots, or tissue overgrowth over time) is a post-procedural complication of EUS-GBD that sometimes (as in our case) can mimic more complex clinical and radiological pictures. It can be

managed with endoscopic debridement and with placement of a pigtail stent through the LAMS.

Prophylactic placement of pigtail stents at the time of the initial procedure has been proposed to prevent this complication, particularly in patients where the stent is intended to remain in situ indefinitely [1].

Endoscopy_UCTN_Code_CPL_1AL_2AD

Competing interests

The authors declare that they have no conflict of interest.

The authors

Fabio De Vincentis, Omero Triossi, Mario Brancaccio

Azienda Unità Sanitaria Locale della Romagna, Gastroenterology Unit, Santa Maria delle Croci Hospital, Ravenna, Italy

Corresponding author

Fabio De Vincentis, MD

Gastroenterology Unit, Santa Maria delle Croci Hospital, Viale Vincenzo Randi 5, 48121 Ravenna, Italy
 Fax: +39-0544-285325
 fabiodevincentis@gmail.com

Reference

- [1] de la Serna-Higuera C, Pérez-Miranda M, Gil-Simón P et al. EUS-guided transenteric gallbladder drainage with a new fistula-forming, lumen-apposing metal stent. *Gastrointest Endosc* 2013; 30: 303–308

Bibliography

Endoscopy 2021; 53: E271–E272

DOI 10.1055/a-1261-2863

ISSN 0013-726X

published online 1.10.2020

© 2020, Thieme. All rights reserved.

Georg Thieme Verlag KG, Rüdigerstraße 14, 70469 Stuttgart, Germany

ENDOSCOPY E-VIDEOS

<https://eref.thieme.de/e-videos>



Endoscopy E-Videos is a free access online section, reporting on interesting cases and new

techniques in gastroenterological endoscopy. All papers include a high quality video and all contributions are freely accessible online.

This section has its own submission website at

<https://mc.manuscriptcentral.com/e-videos>