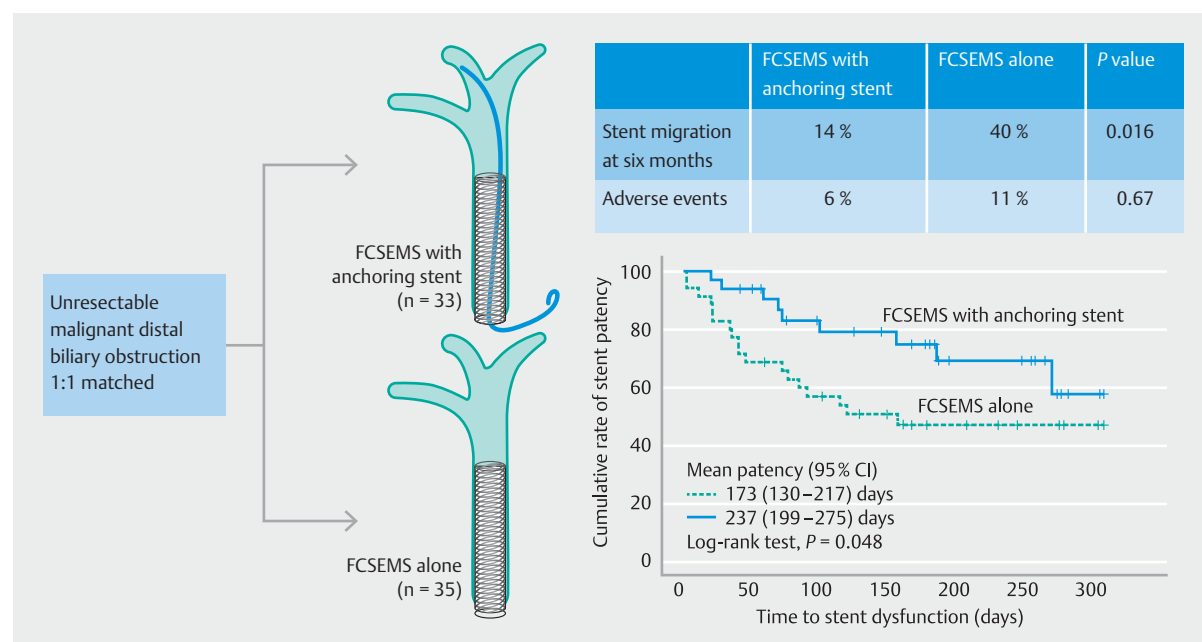


# Efficacy of an internal anchoring plastic stent to prevent migration of a fully covered metal stent in malignant distal biliary strictures: a randomized controlled study

## Authors

Woo Hyun Paik<sup>\*1</sup>, Sang Myung Woo<sup>\*2</sup>, Jung Won Chun<sup>1</sup>, Byeong Jun Song<sup>3</sup>, Woo Jin Lee<sup>2</sup>, Dong-Won Ahn<sup>4</sup>, Yoon Suk Lee<sup>5</sup>, Young Hoon Choi<sup>6</sup>, Ji Kon Ryu<sup>1</sup>, Yong-Tae Kim<sup>1</sup>, Sang Hyub Lee<sup>1</sup>

## GRAPHICAL ABSTRACT



## Institutions

- 1 Department of Internal Medicine and Liver Research Institute, Seoul National University Hospital, Seoul National University College of Medicine, Seoul, Korea
- 2 Center for Liver and Pancreatobiliary Cancer, Research Institute and Hospital, National Cancer Center, Goyang, Korea
- 3 Department of Internal Medicine, Myongji Hospital, Goyang, Korea
- 4 Department of Internal Medicine, Seoul Metropolitan Government Seoul National University Boramae Medical Center, Seoul, Republic of Korea
- 5 Department of Internal Medicine, Inje University Ilsan Paik Hospital, Goyang, Korea
- 6 Division of Gastroenterology, Department of Internal Medicine, College of Medicine, The Catholic University of Korea, Seoul, Korea

submitted 2.6.2020

accepted after revision 4.9.2020

published online 4.9.2020

## Bibliography

Endoscopy 2021; 53: 578–585

DOI 10.1055/a-1256-0571

ISSN 0013-726X

© 2020. Thieme. All rights reserved.

Georg Thieme Verlag KG, Rüdigerstraße 14, 70469 Stuttgart, Germany

Scan this QR-Code for the author commentary.



\* These authors contributed equally to this work.

### Corresponding author

Sang Hyub Lee, MD, PhD, Department of Internal Medicine and Liver Research Institute, Seoul National University Hospital, Seoul National University College of Medicine, 101 Daehak-ro, Jongno-gu, Seoul 110-744, Korea  
Fax: +82-2-7629662  
gidocor@snuh.org

### ABSTRACT

**Background** Two types of self-expandable metal stents (SEMS) are available for malignant distal biliary obstruction: fully covered SEMS (FCSEMS) and uncovered SEMS. FCSEMS can prevent stent ingrowth, but a major concern is spontaneous migration. This study aimed to determine whether the additional insertion of a double-pigtail plastic stent to anchor the FCSEMS can prevent migration.

**Methods** 68 patients with unresectable, malignant, distal, biliary obstruction were included in this multicenter, randomized, superiority trial. The patients were randomly assigned to receive either the FCSEMS plus an anchoring plas-

tic stent (n=33) or an FCSEMS alone (n=35). After placement of the FCSEMS, the anchoring stent was inserted inside the FCSEMS. The primary outcome was the rate of stent migration during the 6-month follow-up. The secondary outcomes were stent-related adverse events, stent patency, and survival rates.

**Results** The baseline characteristics were similar between the two groups. The rate of stent migration at 6 months was significantly lower in patients with the FCSEMS plus anchoring stent (15% vs. 40%;  $P=0.02$ ). The mean stent patency was significantly longer in the FCSEMS plus anchoring group (237 days [95% confidence interval [CI] 199 to 275] vs. 173 days [95%CI 130 to 217];  $P=0.048$ ). There were no significant differences in stent-related adverse events and overall survival rates at 6 months between the two groups.

**Conclusions** Our data suggest that the additional double-pigtail plastic stent anchored the FCSEMS to prevent migration and prolonged patency without any serious adverse events.

## Introduction

Endoscopic retrograde cholangiopancreatography (ERCP) has become the standard method for primary palliation of malignant biliary obstruction [1]. Endoscopic retrograde biliary drainage with a plastic stent was first introduced in the early 1980s [2] and self-expandable metal stents (SEMS) were then adapted to improve stent patency [3, 4]. However, uncovered SEMS have several disadvantages, including short patency time and difficult extraction due to tumor ingrowth and tissue hyperplasia caused by the stimulation of the surrounding tissue by the mesh of the stent [5]. Therefore, fully covered SEMS (FCSEMS) with a polymer coating were developed to overcome the problem of tumor ingrowth seen with uncovered stents [6]. However, FCSEMS carry the risk of stent migration, making them not superior to uncovered SEMS in terms of stent patency [7, 8]. Thus, several concepts to prevent stent migration have been introduced, including higher radial force, an anchoring flap, a flared end, and a partially uncovered metal stent [9, 10]. However, these stents are sometimes difficult to remove because of multiple anchoring flaps or tissue ingrowth through the mesh, which can cause ulceration and bleeding from the mucosa as the SEMS are removed [10–12]. As chemotherapy improves survival rates, the improvement of SEMS has become crucial for long-term cancer survivors. FCSEMS are preferred over partially uncovered or uncovered SEMS because they can be completely removed and replaced during stent revision.

Several studies reported a reduction in stent migration when the FCSEMS was anchored with a plastic stent [9, 13, 14]. However, there are no prospective randomized studies focused on the efficacy of an anchoring plastic stent for prevention of FCSEMS migration in malignant biliary obstruction. The aim of this study, therefore, was to demonstrate the efficacy of using

an additional plastic anchoring stent to prevent stent migration of FCSEMS compared with FCSEMS alone in patients with malignant distal biliary obstruction.

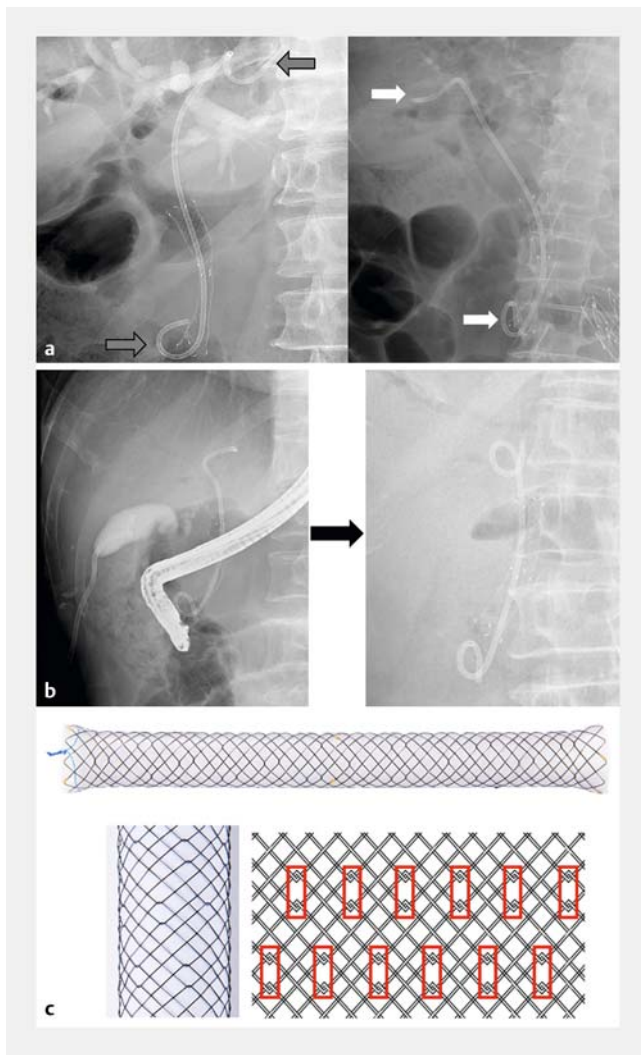
## Methods

### Patients

Patients who required endoscopic retrograde biliary drainage for palliative treatment of an unresectable malignant biliary obstruction at four tertiary institutions from February 2018 to May 2019 were prospectively enrolled in the study. The exclusion criteria were as follows: 1) a previous history of metal stent placement for malignant biliary stricture; 2) hilar cholangiocarcinoma; 3) malignant biliary stricture of the intrahepatic ducts; 4) a recurrence of malignant biliary stricture after surgery; 5) life expectancy less than 3 months; 6) pregnancy; 7) age younger than 20 years; and 8) endoscopy not appropriate for the patient, as judged by the endoscopist.

Enrolled patients were randomly allocated into two treatment groups in a 1:1 ratio without risk stratification. We obtained sequentially numbered, opaque, sealed envelopes with computer-generated random numbers using block randomization (block size of four) by a person unrelated to the study. In the experimental group, an additional 7-Fr double-pigtail plastic stent was inserted into the SEMS after placement of the FCSEMS across the stricture. The proximal tip of the plastic stent was located above the FCSEMS, and intrahepatic anchoring of the proximal tip was favored if possible (► Fig. 1a, b). In the control group, an FCSEMS alone was inserted across the stricture.

The FCSEMS were 10mm in diameter and made of nitinol wire with a silicone-covered membrane and flared ends (Aristent; Daewoong, Seoul, Korea) (► Fig. 1c). The stent was a brai-



► **Fig. 1** Stent use in the treatment of malignant distal biliary strictures. **a** Fluoroscopic images of fully covered self-expandable metal stents (FCSEMS) with an internal anchoring plastic stent (arrows). **b** Initially, the proximal tip of the anchoring stent was located in the left intrahepatic duct. However, the tip was finally located below the hilum because of curling of the proximal tip. **c** FCSEMS with a diameter of 10mm was used in this study. The stent was made of nitinol wire and had a silicone-covered membrane and flared ends. The wire construction of the cells is shown enlarged in the red rectangles.

ded type and the cells were composed of wires crossing in a hook structure. The length of the stent was determined according to the length of the biliary stricture and the proximal end of the stent was placed about 1 cm above the top of the stricture. A 7-Fr double-pigtail plastic stent (Zimmon Biliary Stent; Cook Medical, Bloomington, Indiana, USA) was used as an anchoring stent. The proximal tip of the plastic stent was anchored in the intrahepatic duct.

The study protocol was approved by the institutional review board of each participating hospital and was conducted in accordance with the provisions of the Declaration of Helsinki. All participants provided written informed consent before

enrollment. The trial was registered at ClinicalTrials.gov (NCT03439020).

## Outcomes and definitions

The primary outcome of the study was the rate of stent migration at 6 months. The secondary outcomes included procedure-related adverse events, stent patency, and survival rates at the end of the study period. Radiography of the abdomen, complete blood count, liver function, and serum pancreatic enzyme tests were obtained 4 and 24 hours after stent placement. Stent migration was investigated at 1, 3, and 6 months after stent insertion using laboratory findings, abdominal X-ray imaging, and patient examinations. Reinterventions for stent dysfunction or adverse events were not counted in the analysis of stent migration. Data on chemotherapy after stent insertion were also collected. After the 6-month planned study period was over, a further 6-month clinical follow-up was planned to calculate stent patency.

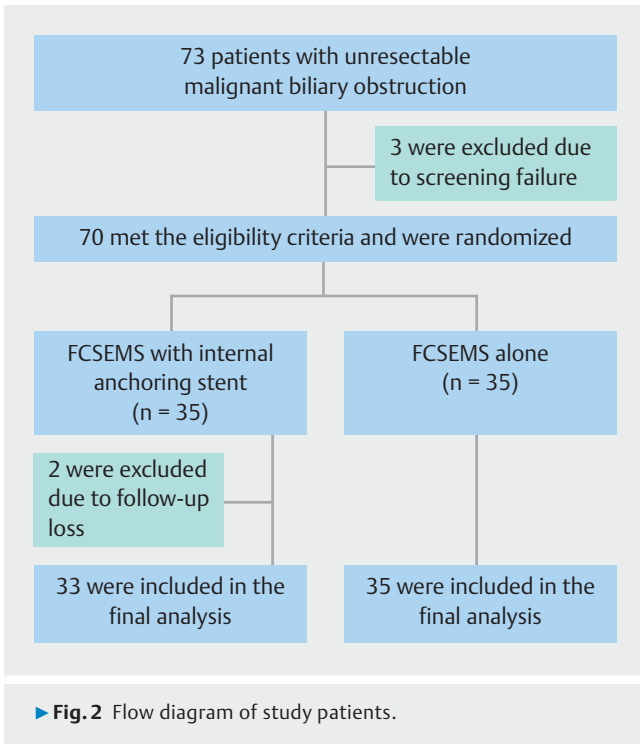
Technical success was defined as the placement of the metal and plastic stents across the stricture site with the flow of contrast medium or bile juice through the stent. Clinical success was defined as a reduction in total bilirubin levels to less than half of the pretreatment levels within 4 weeks [15]. Stent migration was classified as proximal or distal migration. Proximal stent migration was defined as any migration of the FCSEMS into the bile duct, preventing its easy removal. Distal stent migration was defined as FCSEMS migration into the duodenum or movement and lodging of the stent in the distal bile duct, below the stricture [16, 17].

Stent- and procedure-related adverse events were defined according to the lexicon for endoscopic adverse events [18]. The duration of stent patency was defined as the time from stent placement until the point of stent migration or the point at which stent revision was required.

## Statistics

A recent meta-analysis comparing covered vs. uncovered SEMS for malignant distal biliary stricture reported that stent migration was much more common with FCSEMS (odds ratio [OR] 5.11, 95% confidence interval [CI] 1.84–14.17) [7]. Therefore, the hypothesis of this study was that anchoring a plastic stent might reduce the rate of stent migration at 6 months by 80%. To achieve a statistical power of 80% with the assumption of a type I error rate of 5%, 62 patients (31 per group) were needed. Considering a 10% drop-out rate, we calculated a final sample size of 70 patients (35 per group).

The baseline characteristics between the two groups were compared using Student's *t* test for continuous variables and Pearson's chi-squared test or Fisher's exact test for categorical variables. Stent patency was calculated using the Kaplan–Meier method with a log-rank test. Logistic regression analysis was used to assess the association between stent migration and the length or location of the anchoring stent. Cox regression analysis was used to assess the independent risk factors for stent patency. All factors with a *P* value of <0.10 in the univariable model were further assessed using multivariable analysis. *P* values of <0.05 were considered statistically significant. Statistical



analyses were performed using SPSS version 25.0 (IBM Corp., Armonk, New York, USA).

## Results

### Study population

Of the 70 patients randomized, two were excluded from the analysis because of loss to follow-up within 1 month. Therefore, 33 patients in the group receiving the FCSEMS plus anchoring stent and 35 in the FCSEMS only group were analyzed (► **Fig. 2**). The baseline characteristics were similar between the two groups (► **Table 1**). The mean age was 64 years (standard deviation [SD] 12), and 47 patients (69.1%) were male. Initial presentation was jaundice in 45 patients (66.2%), abdominal pain in 22 (32.4%), weight loss in 8 (11.8%), pruritus in 4 (5.9%), and other symptoms in 6 (8.8%). Common comorbidities were hypertension (38.2%), diabetes (23.5%), and cardiovascular disease (13.2%). Pancreatic adenocarcinoma was the most common (83.8%) comorbidity in the enrolled patients. A total of 24 patients (35.3%) had metastatic disease at the time of study registration. Palliative chemotherapy was given to 52 patients (76.5%), without significant differences between the two groups (26 vs. 26;  $P=0.66$ ).

### Stent placement

Initial stent placement was successful in all enrolled patients. The length of the stents ranged from 4 to 8 cm. SEMs that were 5 cm long were mostly used for biliary drainage, and there was no difference in length between the FCSEMS alone and FCSEMS plus anchoring groups (5.3 [SD 0.7] vs. 5.5 [SD 0.8] cm, respectively;  $P=0.36$ ). The anchoring 7-Fr double-pigtail plastic stents were utilized evenly at lengths of 5, 10, and 12

► **Table 1** Baseline characteristics of study patients.

	FCSEMS (n = 35)	FCSEMS + anchoring (n = 33)
Age, mean (SD), years	64.3 (12.9)	64.4 (10.9)
Male/female, n	23/12	24/9
Initial laboratory findings, mean (SD)		
▪ WBC, / $\mu$ L	6746 (2030)	6847 (2720)
▪ Hemoglobin, g/dL	12.0 (1.5)	11.6 (1.9)
▪ Platelet, $\times 10^3$ / $\mu$ L	268 (102)	236 (95)
▪ Total bilirubin, mg/dL	3.8 (3.0)	4.8 (3.9)
▪ ALP, IU/L	289 (209)	302 (176)
▪ AST, IU/L	100 (95)	79 (64)
▪ ALT, IU/L	135 (118)	127 (124)
Cancer type, n (%)		
▪ Bile duct	1 (2.9)	1 (3.0)
▪ Pancreatic	29 (82.9)	28 (84.8)
▪ Gallbladder	1 (2.9)	1 (3.0)
▪ Ampulla of Vater	2 (5.7)	1 (3.0)
▪ Metastatic cancer of other origin	2 (5.7)	2 (6.1)
Clinical tumor stage, n (%)		
▪ Locally advanced	23 (65.7)	21 (63.6)
▪ Distant metastasis	12 (34.3)	12 (36.4)
Comorbidity, n (%)		
▪ Hypertension	12 (34.3)	14 (42.4)
▪ Diabetes	9 (25.7)	7 (21.2)
▪ Chronic liver disease	3 (8.6)	3 (9.1)
▪ Cardiovascular disease	5 (14.3)	4 (12.1)
▪ Chronic kidney disease	1 (2.9)	1 (3.0)
▪ Chemotherapy, n (%)	26 (74.3)	26 (78.8)
Chemotherapy response, n (%)		
▪ Overall response rate	4 (15.4)	6 (23.1)
▪ Disease control rate	23 (88.5)	20 (76.9)

FCSEMS, fully covered self-expandable metal stent; SD, standard deviation; WBC, white blood cell; ALP, alkaline phosphatase; AST, aspartate aminotransferase; ALT, alanine transaminase.

cm. Clinical success was achieved in 29 patients (82.9%) with FCSEMS alone and in 31 patients (93.9%) with FCSEMS plus anchoring stent ( $P=0.26$ ). Five patients, whose treatment was regarded as clinical failure with insufficient bile drainage, finally achieved clinical improvement after stent revision.

► **Table 2** Treatment outcome of endoscopic drainage and stent migration.

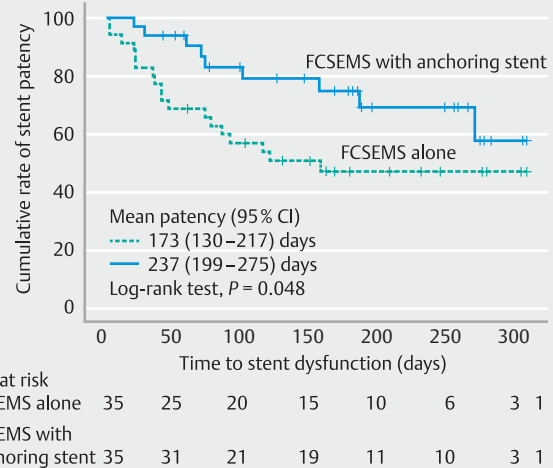
	FCSEMS (n = 35)	FCSEMS + an- choring (n = 33)	P
Technical success, n (%)	35 (100)	33 (100)	>0.99
Clinical success, n (%)	29 (82.9)	31 (93.9)	0.26
Metal stent length, mean (SD), cm	5.3 (0.7)	5.5 (0.8)	0.36
Anchoring plastic stent length, n (%)			
▪ 5 cm		12 (36.4)	
▪ 10 cm		13 (39.4)	
▪ 12 cm		8 (24.2)	
Proximal tip location of anchoring stent, n (%)			
▪ Left intrahepatic duct		15 (45.5)	
▪ Right intrahepatic duct		4 (12.1)	
▪ Below hilum		14 (42.4)	
Stent migration, n (%)			
▪ Proximal/distal	0/14	1/4	0.26
▪ 1 month	7 (20.0)	1 (3.0)	0.06
▪ 3 months	12 (34.3)	3 (9.1)	0.01
▪ 6 months	14 (40.0)	5 (15.2)	0.02
Stent occlusion, n (%)			
▪ Sludge clogging	1	2	>0.99
▪ Tumor overgrowth	1	0	

FCSEMS, fully covered self-expandable metal stent; SD, standard deviation.

## Primary and secondary outcomes

The rate of stent migration at 6 months was 27.9% and was significantly lower in the FCSEMS plus anchoring stent group (15.2% vs. 40.0%;  $P=0.02$ ) (► **Table 2**). The mean time to migration was 191 days (95%CI 172 to 185) in the FCSEMS plus anchoring stent group and 132 days (95%CI 108 to 156) in the FCSEMS alone group ( $P=0.02$ ). During the median follow-up of 6.4 months (interquartile range 4.9–9.1 months), proximal migration occurred in only one patient with anchoring, and distal migration occurred in 18 patients (26.5%) (► **Table 2**). Stent occlusion was observed in four patients (5.9%): three occlusions were due to sludge and one was due to tumor overgrowth. There was no difference in the rate of occlusion based on the presence of the internal anchoring plastic stent ( $P>0.99$ ).

During follow-up, 21 patients required reintervention for biliary drainage. The reasons for reintervention were as follows: stent migration ( $n=9$ ), stent occlusion ( $n=8$ ), and stent-related adverse events ( $n=4$ ). Reinterventions were significantly more frequent in the FCSEMS alone group than in the FCSEMS plus anchoring stent group (15 vs. 6;  $P=0.03$ ). A total of 10 patients



► **Fig. 3** Cumulative rates of stent patency between fully covered self-expandable metal stent (FCSEMS) with an internal anchoring plastic stent and FCSEMS alone.

experienced spontaneous stent migration with no symptoms related to biliary obstruction, and biliary reintervention was not required. In five patients, the underlying malignancy and biliary stricture were improved with chemotherapy, so no biliary reintervention was required.

The mean stent patency was significantly longer in the FCSEMS plus anchoring stent group compared with the FCSEMS alone group (237 days [95%CI 199 to 275] vs. 173 days [95%CI 130 to 217]; log-rank  $P=0.048$ ) (► **Fig. 3**). The risk factors affecting stent patency were evaluated by univariable and multivariable analyses. In the multivariable analysis, age and placement of the anchoring plastic stent were significant risk factors affecting stent patency (► **Table 3**). In the subgroup analysis, there were no significant associations between stent migration and the length of the anchoring stent (anchoring stent length longer than 5 cm: OR 0.33, 95%CI 0.04 to 2.49;  $P=0.28$ ) or the location of the proximal tip (proximal tip located in the intrahepatic duct: OR 0.40, 95%CI 0.06 to 3.01;  $P=0.43$ ). The overall response rates to chemotherapy also showed no significant association with stent migration (OR 1.82, 95%CI 0.43 to 7.69;  $P=0.42$ ).

There were no significant differences in stent-related adverse events between the two groups (difference 5.3%; 95%CI –9.9% to 20.5%) (► **Table 4**). Six patients developed stent-related adverse events. Three patients received conservative management because of ascending cholangitis. The other three patients (two with pancreatitis and one with cholecystitis) experienced adverse events within 1 month of the procedure and were treated with stent change to a plastic stent. A total of 14 patients died during the study period, but no procedure-related mortality was reported. The survival rates at 6 months were also similar between the two groups (FCSEMS plus anchoring stent 75.8% vs. FCSEMS alone 82.9%;  $P=0.47$ ).

► **Table 3** Risk factors associated with stent patency.

Variables	Univariable		Multivariable	
	HR (95%CI)	P	HR (95%CI)	P
Age	0.96 (0.93 to 0.99)	0.01	0.96 (0.93 to 0.99)	0.03
Female	0.60 (0.24 to 1.50)	0.28		
Size ≥ 3 cm	0.92 (0.42 to 2.04)	0.85		
Stricture length ≥ 2 cm	1.03 (0.46 to 2.30)	0.94		
Duodenal invasion	0.97 (0.44 to 2.13)	0.93		
Periampullary diverticulum	0.55 (0.08 to 4.09)	0.56		
Length of metal stent ≥ 6 cm	1.18 (0.51 to 2.70)	0.70		
Anchoring plastic stent	0.41 (0.18 to 0.94)	0.03	0.35 (0.15 to 0.80)	0.01
Prior ERBD	1.32 (0.61 to 2.84)	0.48		
Chemotherapy	1.14 (0.43 to 3.04)	0.79		
Pancreatic cancer	1.31 (0.39 to 4.37)	0.66		
Distant metastasis	2.73 (1.26 to 5.94)	0.01	2.21 (0.98 to 4.98)	0.06

HR, hazard ratio; CI, confidence interval; ERBD, endoscopic retrograde biliary drainage.

► **Table 4** Procedure-related adverse events.

	FCSEMS (n = 35)	FCSEMS + anchoring (n = 33)	P
Total adverse events, n (%)	4 (11.4)	2 (6.1)	0.67
Early (< 14 days), n (%)	2 (5.7)	0	0.49
▪ Pancreatitis	2 (5.7)	0	
Late (≥ 14 days), n (%)	2 (5.7)	(6.1)	>0.99
▪ Cholecystitis	1 (2.9)	0	
▪ Cholangitis	1 (2.9)	2 (6.1)	

FCSEMS, fully covered self-expandable metal stent.

## Discussion

This is the first prospective, multicenter, randomized clinical trial to investigate the outcomes of FCSEMS with an internal anchoring plastic stent compared with FCSEMS alone for the treatment of malignant distal biliary obstruction. The 6-month stent migration rate significantly decreased when the anchoring stent was used, without any serious adverse events. Stent patency was also significantly prolonged in the FCSEMS plus anchoring stent group. The technical success rate of FCSEMS plus anchoring stent was 100%, and the clinical success rate was comparable to FCSEMS alone.

Malignant biliary obstruction is associated with a poor prognosis [19]. However, survival is becoming longer with improved chemotherapeutic agents. Thus, the effective resolution of jaundice and the development of long-term patent stents are needed for the maintenance of chemotherapy [20]. FCSEMS have advantages over uncovered SEMS in terms of intrastent re-stenosis. Tumor ingrowth or epithelial hyperplasia through

mesh cells occurs in uncovered SEMS. Moreover, stent removal is a problem for long-standing biliary stents, and FCSEMS can be easily removed and replaced after stent clogging [21]. Nonetheless, stent migration is a problem for FCSEMS. Overall, FCSEMS would be the ideal stent for patients undergoing palliative chemotherapy if the problem of stent migration were resolved. Several methods of preventing stent migration in FCSEMS have been adopted in stent design, including higher radial force, use of partially covered stents, flaring the ends of the SEMS, and anti-migration flaps. However, these solutions were not effective in prolonging stent patency, and anti-migration flaps cause increased mucosal injury and bleeding during removal [10, 20, 22, 23]. Potentially, an uncovered portion of partially covered SEMS can work as an anchor to prevent stent migration [20], but the uncovered portion may become embedded in the bile duct, resulting in tissue hyperplasia [24]. Unlike the methods mentioned above, the placement of an additional internal anchoring stent within the SEMS appears to be a sim-

ple, safe, and effective method of preventing migration of FCSEMS.

The migration rate of FCSEMS has been reported to be 5%–37% [25]. In the present study, the migration rate of FCSEMS was 40%, which is higher than that in previous reports. The average radial force of the FCSEMS used in the present study was 252 gf, which is lower than that of other FCSEMS. The low radial force of SEMs may contribute to a higher rate of stent migration [26]. If the radial force is weak, the stent can easily slip through the stricture site [20]. In addition, the FCSEMS designed with anchoring flaps were reported to be superior to flared ends in terms of stent migration [10]. As the FCSEMS used in the present study had flared ends without anti-migration flaps, the migration rate may be higher. Chemotherapy also plays a significant role in the migration of FCSEMS, as chemotherapy can induce tumor shrinkage, which improves the biliary stricture [20]. As the majority of the patients in the current study received palliative chemotherapy, the rate of stent migration may be higher than that in previous studies. However, palliative chemotherapy did not affect the stent patency in this study (hazard ratio 1.14, 95%CI 0.43 to 3.04;  $P=0.79$ ). The average length of the FCSEMS used in this study was 5 cm, which is the shortest among the commercially available metal stents. According to our study protocol, the length of the stent was determined according to the length of the biliary stricture and the proximal end of the stent was placed about 1 cm above the top of the stricture to prevent stent-related acute cholecystitis. The use of short FCSEMS might have contributed to the higher rate of stent migration in this study. Another reason might be the increased capture of stent migration even in asymptomatic patients, as patients tend to be monitored more closely in randomized controlled clinical trials. In 10 patients, stent migration occurred without any related symptoms and these events were detected only by routine radiologic imaging.

Several previous studies have focused on plastic anchoring stents to prevent FCSEMS migration [9, 13, 14]. Park et al. were the first to demonstrate the effect of anchoring stents in a benign biliary stricture, but their study was terminated before reaching the planned sample size and was thus underpowered to identify clinically relevant differences [13]. Katsinelos et al. also described the effects of anchoring stents in 11 patients, including 1 benign and 10 malignant biliary strictures; however, this study was descriptive with no control arm [14]. Recently, Emhmed et al. retrospectively analyzed 203 patients with FCSEMS, including 65 FCSEMS with an anchoring plastic stent and 138 with FCSEMS alone [9]. Differences in stent migration did not reach statistical significance in this study (6% in the anchoring group vs. 10% in the FCSEMS alone group;  $P=0.35$ ). However, this study included heterogeneous reasons for biliary stenting, including not only biliary strictures but also bile leaks and post-sphincterotomy bleeding. Moreover, no follow-up period was mentioned in the study and the total rate of FCSEMS migration was 9.7%, which was lower than expected. This result suggests that the follow-up period of the study may not have been long enough to observe stent migration. Our study is the

first prospective, randomized, comparative, clinical trial to include malignant biliary strictures only.

In the previous studies investigating the effect of an anchoring stent inside the FCSEMS, 5-Fr or 10-Fr double-pigtail plastic stents were used [13, 14]. In a recent retrospective study, 90% of the anchoring stents were 7 Fr and 10% were 10 Fr [9]. In the present study, 7 Fr double-pigtail plastic stents were used, as a 7-Fr stent is the most widely used and is easy to insert. The length of the anchoring plastic stent may be more important than the diameter for anchoring the plastic stent within the intrahepatic ducts.

Regarding reinterventions, the internal anchoring plastic stent resulted in significantly fewer biliary reinterventions. Considering the cost of an ERCP procedure and the accompanying costs of managing the complications caused by stent malfunction, the additional anchoring stent might be a cost-effective technique, although this was not investigated in the present study.

There are several limitations to this study. Although this was a multi-institutional, prospective, randomized study, stratification by institution was not performed during patient enrollment and patients were enrolled consecutively at each institution. Although this might be a confounding factor, all institutions participating in the study were tertiary academic hospitals. In addition, all endoscopists involved in the study were experts in ERCP with more than 5000 lifetime experiences. Thus, overall, the bias due to lack of stratification by institution is expected to be small. A second limitation is the follow-up period; at 12 months after stent insertion, only 21% of patients with anchored FCSEMS experienced stent dysfunction. Thus, the follow-up period seems to be inadequate. Long-term follow-up is needed to obtain more information on the natural history of stent patency in the experimental group.

In conclusion, the addition of a double-pigtail plastic stent to anchor the FCSEMS was a simple and effective method to prevent stent migration and prolong stent patency without any serious adverse events. Further studies focused on the efficacy of the anchoring plastic stent in other types of FCSEMS are warranted.

## Clinical trial

Trial Registration: ClinicalTrials.gov | Registration number (trial ID): NCT03439020 | Type of study: prospective randomized multi-center study

## Acknowledgment

This study was funded in part by Daewoong Co., Ltd., Seoul, Korea (Grant Number 0620180250).

## Competing interests

The authors declare that they have no conflicts of interest.

## References

- [1] Smith AC, Dowsett JF, Russell RC et al. Randomised trial of endoscopic stenting versus surgical bypass in malignant low bile duct obstruction. *Lancet* 1994; 344: 1655–1660
- [2] Moy BT, Birk JW. An update to hepatobiliary stents. *J Clin Transl Hepatol* 2015; 3: 67–77
- [3] Huibregtse K, Cheng J, Coene PP et al. Endoscopic placement of expandable metal stents for biliary strictures – a preliminary report on experience with 33 patients. *Endoscopy* 1989; 21: 280–282
- [4] Davids PH, Groen AK, Rauws EA et al. Randomised trial of self-expanding metal stents versus polyethylene stents for distal malignant biliary obstruction. *Lancet* 1992; 340: 1488–1492
- [5] Pfau RR, Pleskow DK, Banerjee S et al. Pancreatic and biliary stents. *Gastrointest Endosc* 2013; 77: 319–327
- [6] Isayama H, Komatsu Y, Tsujino T et al. Polyurethane-covered metal stent for management of distal malignant biliary obstruction. *Gastrointest Endosc* 2002; 55: 366–370
- [7] Tringali A, Hassan C, Rota M et al. Covered vs. uncovered self-expandable metal stents for malignant distal biliary strictures: a systematic review and meta-analysis. *Endoscopy* 2018; 50: 631–641
- [8] Almadi MA, Barkun AN, Martel M. No benefit of covered vs uncovered self-expandable metal stents in patients with malignant distal biliary obstruction: a meta-analysis. *Clin Gastroenterol Hepatol* 2013; 11: 27–37.e21
- [9] Emhmed Alis, Frandah WM, Su L et al. Should a fully covered self-expandable biliary metal stent be anchored with a double-pigtail plastic stent? A retrospective study *World J Gastrointest Endosc* 2019; 11: 365–372
- [10] Park DH, Lee SS, Lee TH et al. Anchoring flap versus flared end, fully covered self-expandable metal stents to prevent migration in patients with benign biliary strictures: a multicenter, prospective, comparative pilot study (with videos). *Gastrointest Endosc* 2011; 73: 64–70
- [11] Mahajan A, Ho H, Sauer B et al. Temporary placement of fully covered self-expandable metal stents in benign biliary strictures: midterm evaluation (with video). *Gastrointest Endosc* 2009; 70: 303–309
- [12] Wang AY, Ellen K, Berg CL et al. Fully covered self-expandable metallic stents in the management of complex biliary leaks: preliminary data – a case series. *Endoscopy* 2009; 41: 781–786
- [13] Park JK, Moon JH, Choi HJ et al. Anchoring of a fully covered self-expandable metal stent with a 5F double-pigtail plastic stent to prevent migration in the management of benign biliary strictures. *Am J Gastroenterol* 2011; 106: 1761–1765
- [14] Katsinelos P, Lazaraki G, Gkagkalis S et al. A fully covered self-expandable metal stent anchored by a 10-Fr double pigtail plastic stent: an effective anti-migration technique. *Ann Gastroenterol* 2017; 30: 114–117
- [15] Paik WH, Lee TH, Park DH et al. EUS-guided biliary drainage versus ERCP for the primary palliation of malignant biliary obstruction: a multicenter randomized clinical trial. *Am J Gastroenterol* 2018; 113: 987–997
- [16] Kahaleh M, Sundaram V, Condron SL et al. Temporary placement of covered self-expandable metallic stents in patients with biliary leak: midterm evaluation of a pilot study. *Gastrointest Endosc* 2007; 66: 52–59
- [17] Ho H, Mahajan A, Gosain S et al. Management of complications associated with partially covered biliary metal stents. *Dig Dis Sci* 2010; 55: 516–522
- [18] Chandrasekhara V, Khashab MA. ASGE Standards of Practice Committee. Adverse events associated with ERCP. *Gastrointest Endosc* 2017; 85: 32–47
- [19] Paik WH, Park YS, Hwang JH et al. Palliative treatment with self-expandable metallic stents in patients with advanced type III or IV hilar cholangiocarcinoma: a percutaneous versus endoscopic approach. *Gastrointest Endosc* 2009; 69: 55–62
- [20] Nakai Y, Isayama H, Kogure H et al. Risk factors for covered metallic stent migration in patients with distal malignant biliary obstruction due to pancreatic cancer. *J Gastroenterol Hepatol* 2014; 29: 1744–1749
- [21] Misra SP, Dwivedi M. Reflux of duodenal contents and cholangitis in patients undergoing self-expanding metal stent placement. *Gastrointest Endosc* 2009; 70: 317–321
- [22] Isayama H, Mukai T, Itoi T et al. Comparison of partially covered nitinol stents with partially covered stainless stents as a historical control in a multicenter study of distal malignant biliary obstruction: the WATCH study. *Gastrointest Endosc* 2012; 76: 84–92
- [23] Yang MJ, Kim JH, Yoo BM et al. Partially covered versus uncovered self-expandable nitinol stents with anti-migration properties for the palliation of malignant distal biliary obstruction: a randomized controlled trial. *Scand J Gastroenterol* 2015; 50: 1490–1499
- [24] Behm B, Brock A, Clarke BW et al. Partially covered self-expandable metallic stents for benign biliary strictures due to chronic pancreatitis. *Endoscopy* 2009; 41: 547–551
- [25] Dumonceau JM, Tringali A, Blero D et al. Biliary stenting: indications, choice of stents and results: European Society of Gastrointestinal Endoscopy (ESGE) clinical guideline. *Endoscopy* 2012; 44: 277–298
- [26] Kawakubo K, Isayama H, Nakai Y et al. Risk factors for pancreatitis following transpapillary self-expandable metal stent placement. *Surg Endosc* 2012; 26: 771–776