

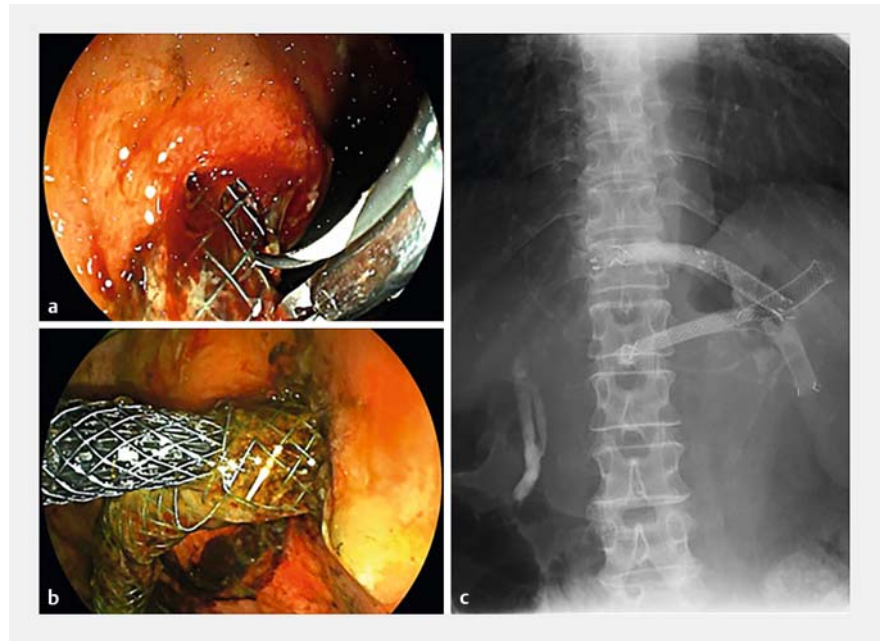
Removal of embedded partially covered self-expandable metal stents in endoscopic ultrasound-guided hepaticogastrostomy

Endoscopic ultrasound (EUS)-guided hepaticogastrostomy (HGS) is a widely used procedure. Despite high success rates, re-intervention is sometimes needed and can be complicated. Partially covered self-expandable metal stents (PCSEMS) often cause hyperplasia, which can impede stent removal [1, 2]. We used to use PCSEMS, but now use 6-mm fully covered self-expandable stents (FCSEMS) for ease of reintervention [3].

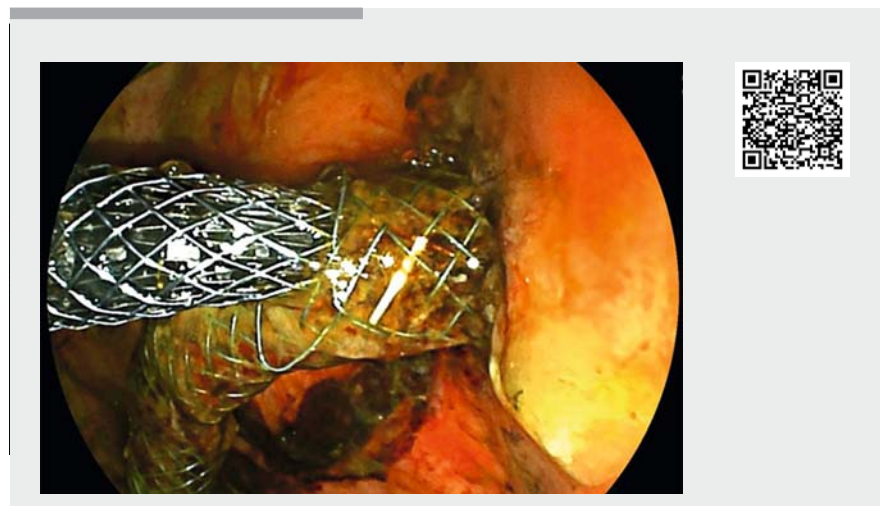
The “SEMS-in-SEMS” technique has already been successfully applied for the removal of difficult-to-remove FCSEMS in endoscopic biliary drainage [4, 5]. We report here the first evidence that the technique for removing an embedded PCSEMS after EUS-HGS, developed from the “SEMS-in-SEMS” technique, is safe and useful.

A 69-year-old woman who had undergone right hepatectomy for cholangiocellular carcinoma was referred to our hospital for treatment of recurrence. At the previous hospital, an EUS-HGS of B2 and B3 with an 8-mm, 10-cm PCSEMS had been performed 1 month earlier because of difficulties in managing endoscopic biliary drainage due to disease recurrence in the hepatic portal region. The patient showed obstructive jaundice, so we tried to revise the EUS-HGS. We attempted to remove the stents, but failed because of hyperplasia into the stents. We therefore inserted a 10-mm, 7-cm FCSEMS inside the first stent in B2. We also inserted a 10-mm, 8-cm FCSEMS through a mesh gap in the first stent in B3, as if cutting into the first stent (► **Fig. 1**; ► **Video 1**). After 4 months, the patient again experienced obstructive jaundice. We easily removed both B2 and B3 stents with alligator forceps and inserted new plastic stents into each (► **Fig. 2**).

Recently, EUS-HGS has been used not only as an alternative drainage, but also for primary drainage. Methods facilitating reintervention are thus needed. Be-



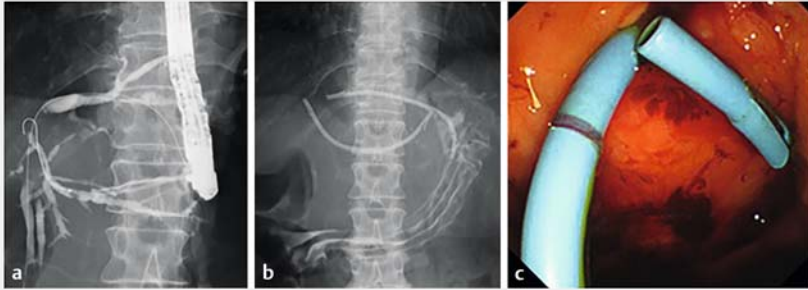
► **Fig. 1** **a** Guidewire insertion through a mesh gap in the B3 stent. **b** A fully covered metallic stent (10 mm × 8 cm) is placed through a mesh gap in the B3 stent. **c** Radiography shows the new B3 stent partially inserted within the first B3 stent.



► **Video 1** Removal of an embedded partially covered self-expandable metal stent in an endoscopic ultrasound-guided hepaticogastrostomy using a development of the “SEMS-in-SEMS” technique.

cause the stent on the stomach side is long, reintervention through the end of the stent on the stomach side is difficult.

Approaching through a mesh gap in the stent was thus useful. Our technique may make reintervention easier.



► **Fig. 2** a Radiography shows contrast through fistulas after removal of the metallic stent. New plastic stents were inserted into the fistulas: b radiographic view, c endoscopic view.

Bibliography

Endoscopy 2021; 53: E249–E250

DOI 10.1055/a-1252-2530

ISSN 0013-726X

published online 23.9.2020

© 2020, Thieme. All rights reserved.

Georg Thieme Verlag KG, Rüdigerstraße 14,

70469 Stuttgart, Germany

ENDOSCOPY E-VIDEOS

<https://eref.thieme.de/e-videos>



Endoscopy E-Videos is a free access online section, reporting on interesting cases and new

techniques in gastroenterological endoscopy. All papers include a high quality video and all contributions are freely accessible online.

This section has its own submission website at

<https://mc.manuscriptcentral.com/e-videos>

Endoscopy_UCTN_Code_CPL_1AL_2AD

Competing interests

The authors declare that they have no conflict of interest.

The authors

Nozomi Okuno, Kazuo Hara, Shin Haba, Takamichi Kuwahara, Hiroki Koda, Akira Miyano, Moaz Elshair

Department of Gastroenterology, Aichi Cancer Center Hospital, Nagoya, Aichi, Japan

Corresponding author

Kazuo Hara, MD

Department of Gastroenterology, Aichi Cancer Center Hospital, 1-1 Kanokoden, Chikusa-ku, Nagoya, Aichi 464-8681, Japan
Fax: +81-52-7642942
khara@aichi-cc.jp

References

- [1] Hara K, Yamao K, Mizuno N et al. Endoscopic ultrasonography-guided biliary drainage: who, when, which, and how? *World J Gastroenterol* 2016; 22: 1297–1303
- [2] Nakai Y, Sato T, Hakuta R et al. Long-term outcomes of a long, partially covered metal stent for EUS-guided hepaticogastrostomy in patients with malignant biliary obstruction (with video). *Gastrointest Endosc* 2020. doi:10.1016/j.gie.2020.03.3856
- [3] Okuno N, Hara K, Mizuno N et al. Efficacy of the 6-mm fully covered self-expandable metal stent during endoscopic ultrasound-guided hepaticogastrostomy as a primary biliary drainage for the cases estimated difficult endoscopic retrograde cholangiopancreatography: a prospective clinical study. *J Gastroenterol Hepatol* 2018. doi:10.1111/jgh.14112
- [4] Tringali A, Blero D, Boskoski I et al. Difficult removal of fully covered self expandable metal stents (SEMS) for benign biliary strictures: the “SEMS in SEMS” technique. *Dig Liver Dis* 2014; 46: 568–571
- [5] Marcos P, Bastos P, Patita M et al. Removal of intraductal migrated biliary fully covered self-expandable metal stents: the “SEMS in SEMS” technique. *Gastrointest Endosc* 2019; 89: 1259–1260