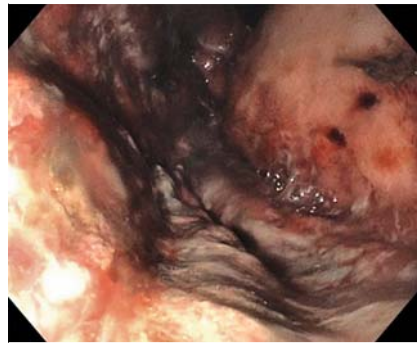


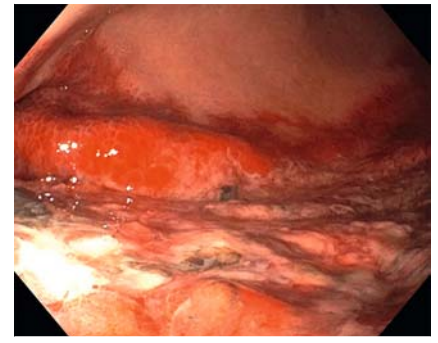
## Gastric ischemia and portal vein thrombosis in a COVID-19-infected patient

A 51-year-old man admitted with acute respiratory failure from a SARS-CoV-2 infection had large volume of bloody output via orogastric tube following initiation of heparin for a lower extremity deep vein thrombosis. Esophagogastroduodenoscopy revealed diffuse and severe mucosal ischemia involving the gastric fundus (► **Fig. 1**), greater curvature, and posterior wall of the gastric body and antrum (► **Fig. 2**) (► **Video 1**). The anterior gastric wall and duodenum appeared normal. Computed tomography (CT) angiogram of the abdomen revealed gastric pneumatosis (► **Fig. 3**), a non-occlusive thrombus in the right and left portal veins, and portal venous gas (► **Fig. 4**). The small bowel and colon appeared normal. In addition to management of the underlying COVID infection and respiratory complications, management included nasogastric decompression and intravenous heparin. A repeat abdominal CT 1 week later showed resolution of the intramural gastric and portal venous gas, and no residual portal vein thrombosis (► **Fig. 5**).

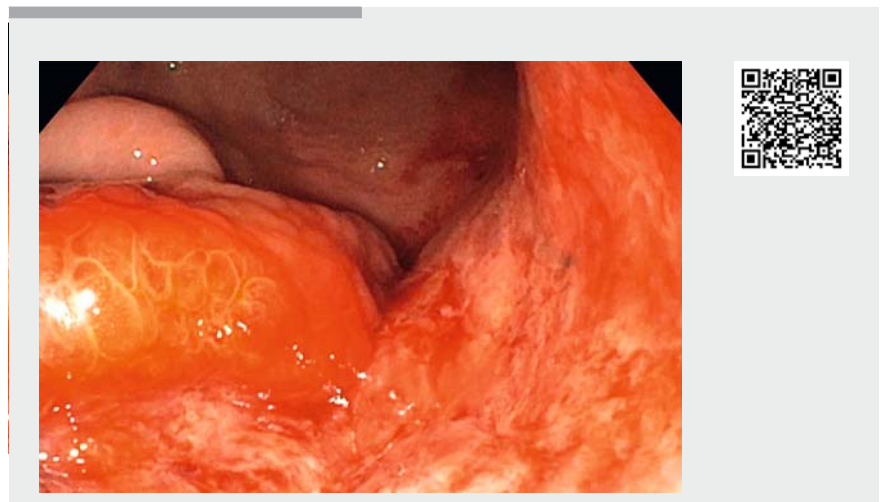
Gastrointestinal tract involvement, ranging from minor symptoms to small bowel ischemia, has been reported with the SARS-CoV-2 virus, which may be due to a high surface expression of angiotensin-converting enzyme 2 (ACE2) receptors on gastric cells and enterocytes [1, 2]. The underlying mechanism of small bowel ischemia is not known but might result from direct viral infiltration via ACE2 receptors on enterocytes and endothelial cells, complement-mediated small vessel thrombosis, non-occlusive mesenteric ischemia, or systemic coagulopathy [3, 4]. Gastric ischemia is a rare condition that results from vascular insufficiency due to local or systemic disorders and is associated with poor clinical outcomes if not recognized and treated early [5]. Our patient had gastric ischemia and portal vein thrombosis in the setting of a COVID-19 infection in the absence of other thromboembolic risk



► **Fig. 1** Mucosal changes of ischemia involving entire gastric fundus.



► **Fig. 2** Mucosal changes of ischemia involving greater curvature with sparing of anterior wall.



► **Video 1** Esophagogastroduodenoscopy findings of gastric mucosal ischemia with normal duodenum in the setting of COVID-19 infection.

factors. Based on a review of the literature, we found no reported cases of COVID-19-associated gastric ischemia. A high index of suspicion may result in early recognition of this complication and treatment with anticoagulation.

Endoscopy\_UCTN\_Code\_CCL\_1AB\_2AC\_3AZ

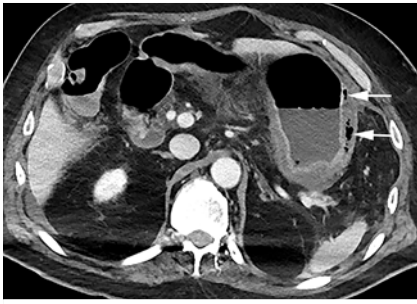### Competing interests

The authors declare that they have no conflict of interest.

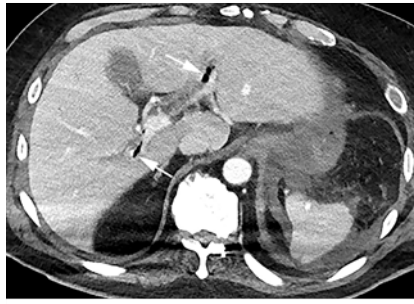
### The authors

See-Wei Low<sup>1</sup>, Karen L. Swanson<sup>1</sup>, Josiah D. McCain<sup>2</sup>, Ayan Sen<sup>3</sup>, Akira Kawashima<sup>4</sup>, Shabana F. Pasha<sup>2</sup>

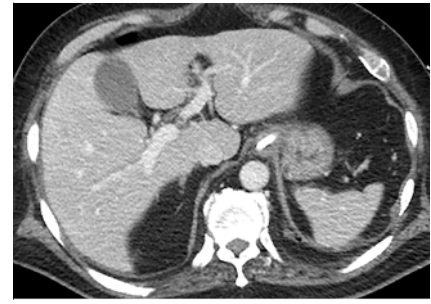- 1 Division of Pulmonary and Critical Care, Mayo Clinic Arizona
- 2 Division of Gastroenterology and Hepatology, Mayo Clinic Arizona
- 3 Department of Critical Care Medicine, Mayo Clinic Arizona
- 4 Department of Radiology, Mayo Clinic Arizona



► **Fig. 3** Gastric pneumatosis seen on computed tomography angiogram.



► **Fig. 4** Non-occlusive thrombus in the right and left portal veins, and portal venous gas on computed tomography angiogram.



► **Fig. 5** Radiologic resolution of intramural gastric and portal venous gas, and portal vein thrombosis.

## Corresponding author

### Shabana F. Pasha, MD

Division of Gastroenterology and Hepatology, Mayo Clinic Arizona, 13400 E. Shea Blvd, Scottsdale, Arizona 85259, USA  
Phone: +1-480-301-8673  
Pasha.Shabana@mayo.edu

## References

- [1] Bhayana R, Som A, Li MD et al. Abdominal imaging findings in COVID-19: preliminary observations. *Radiology* 2020. doi:10.1148/radiol.2020201908
- [2] Kumar VCS, Mukherjee S, Harne PS et al. Novelty in the gut: a systematic review and meta-analysis of the gastrointestinal manifestations of COVID-19. *BMJ Open Gastroenterol* 2020; 7: 1–9

- [3] Magro C, Mulvey JJ, Berlin D et al. Complement associated microvascular injury and thrombosis in the pathogenesis of severe COVID-19 infection: a report of five cases. *Transl Res* 2020; 220: 1–13
- [4] Zsuzsanna V, Flammer AJ, Steiger P et al. Endothelial cell infection and endotheliitis in COVID-19. *Lancet* 2020; 395: 1417–1418
- [5] Sharma A, Mukewar S, Chari ST et al. Clinical features and outcomes of gastric ischemia. *Dig Dis Sci* 2017; 62: 3550–3556

## Bibliography

*Endoscopy* 2020; 52: E465–E466  
DOI 10.1055/a-1230-3357  
ISSN 0013-726X  
published online 2.9.2020  
© 2020. Thieme. All rights reserved.  
Georg Thieme Verlag KG, Rüdigerstraße 14,  
70469 Stuttgart, Germany

## ENDOSCOPY E-VIDEOS

<https://eref.thieme.de/e-videos>



*Endoscopy E-Videos* is a free access online section, reporting on interesting cases and new

techniques in gastroenterological endoscopy. All papers include a high quality video and all contributions are freely accessible online.

This section has its own submission website at  
<https://mc.manuscriptcentral.com/e-videos>