

## Collateral Activation of the Early Temporal Branch - A Neurosonological Sign of Distal M1 Middle Cerebral Artery Occlusion



### Introduction

In most cases large vessel occlusion (LVO) in the anterior circulation causes a severe stroke syndrome with a high National Institutes of Health Stroke Scale score (NIHSS). However, there is also a smaller group of patients (up to 10% of all LVO) presenting with a minor stroke syndrome, transient or even absent neurological symptoms, who may develop early clinical deterioration. They may be candidates for thrombolysis and mechanical thrombectomy (MT).

Due to low clinical suspicion, many of these patients are not included in the diagnostic fast track of a comprehensive stroke center with immediate vessel imaging by means of CT- or MR-angiography. In this scenario neurosonography can be the first vessel imaging performed. We present such a clinical case and its neurosonographic findings of a distal M1 middle cerebral artery occlusion (MCA) with an emphasis on the early temporal branch (ETB) as an important M1-M2 collateral pathway (aside from established neurosonological signs).

### Case

A 75-year-old female patient had a short history of slurred speech, dizziness, and drowsiness for some minutes. She had to stop exercising at a fitness studio. A member of her group observed transient facial weakness and called an ambulance to take her to the hospital. At admission, she felt well and the neurological examination was normal (NIHSS score 0).

Extracranial duplex sonography was unremarkable. Transcranial color-coded duplex sonography (TCCS) (► Fig. 1a) revealed reduced flow velocity in the left proximal M1-MCA segment (flow velocity: 50/25 cm/s), a pathologic Zanjette asymmetry index of 46%, strong ipsilateral A1 anterior cerebral artery (ACA) segment (140/60 cm/s) and P1 posterior cerebral artery (PCA) segment (120/40 cm/s, spectrum not shown in ► Fig. 1b). The distal MCA main stem showed bidirectional low-frequency flow.

A prominent singular distal segment arising from the MCA main stem with uni-

formly increased velocity (110/50 cm/s), which was strongly suspected of being ETB, was also visualized. Compared to the other segments (A1, P1, ETB), the M1-MCA segment had the lowest color signal intensity (► Video, ► Fig. 1).

The sonographically suspected diagnosis of a distal M1-MCA occlusion was confirmed by means of CT-angiography (► Fig. 1). 18 h after admission, the patient developed acute clinical deterioration (NIHSS Score 4) and was successfully treated by MT. She quickly recovered and was discharged after one week without neurological deficits.

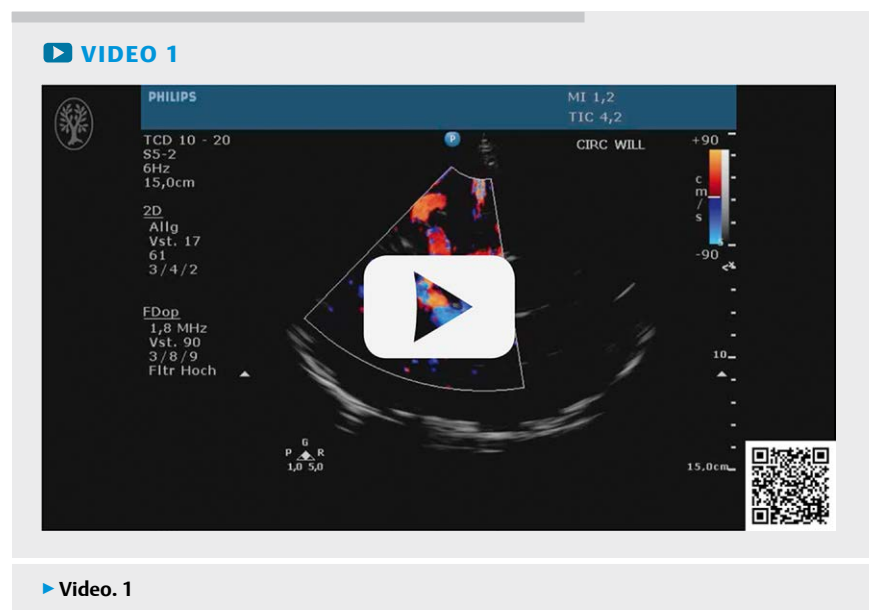
### Discussion

We have described the neurosonographic findings of a distal M1-MCA occlusion in a patient with only transient neurologic symptoms at admission. Up to 10% of all LVOs may occur with transient or only mild symptoms (S. Nagel, G. Nogueira et al. Stroke 2018; 49:2391 – 2397). Because current guidelines only recommend MT in patients with NIHSS  $\geq 6$  and due to the low clinical suspicion of a LVO, only some low NIHSS patients undergo acute vessel imaging by means of CT- or MR-angiography. Out of a diagnostic fast track procedure in a stroke

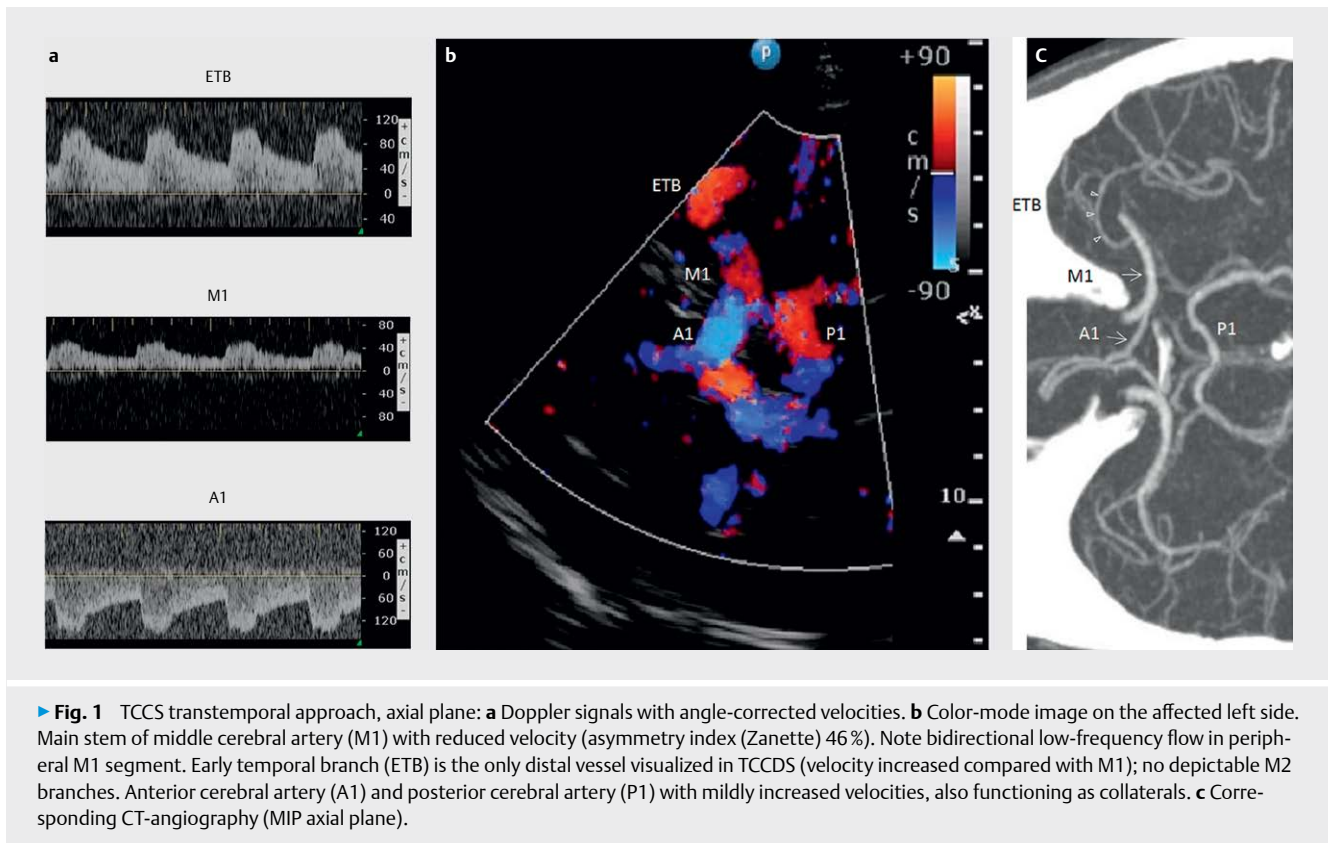
unit, TCCS may be the first examination of the intracranial arteries.

In the presented case, TCCS revealed typical and well established indirect signs of a distal M1 occlusion: reduced flow in the proximal MCA with an increased asymmetry index, absent depiction of M2 branches, mildly increased velocities in the A1-ACA and P1-PCA segments functioning as collateral routes. In addition, an early temporal MCA branch (ETB) arising proximal to the occlusion could be visualized which showed uniformly increased flow velocities along a 1-cm segment reflecting hyperperfusion in this collateral pathway. The ETB of MCA is a term used most frequently for the temporopolar artery which arises below the lenticulostriate arteries from the M1 main stem. The reported prevalence of ETB varies considerably. In recent angiographic and anatomic studies, it was much higher than previously thought (90% reported by N. Tanriover, R.A. Mericle et al. J Neurosurg 2003; 98: 1277-1290).

In normal vascular anatomy, the ETB may often not be visualized on routine TCCS examination. In cases of distal M1-MCA occlusion, its visualization becomes easier due to collateral hyperperfusion. The caudally emerging origin and more proxi-



► Video. 1



mal course of ETB can be missed using a clear midbrain plane (Valdueza JM et al. Case 22. In: Neurosonology and Neuroimaging of Stroke. Stuttgart: Georg Thieme, 2016: 269 – 278). Like in the presented case, the distal more horizontal course reaching the insula may be seen in a standard axial plane. In transcranial Doppler sonography and TCCS a prominent visualized ETB can be confused with a M2 branch of MCA, so the diagnosis of a distal M1 occlusion can be missed (R. Shahripour and V. Alexandrov. *Austin J Cerebrovasc Dis & Stroke*. 2014; 1(6): 1027). To avoid pitfalls in this scenario, ETB has to be differentiated from a M2-branch by the divergent proximal course and the missing direct link to the occluded distal M1-segment and from a peripheral MCA-stenosis by the criteria of pure hyperperfusion. To get an overview in color mode imaging, the color scale settings have to be optimized for differentiating dampened flow in M1 and criteria of hyperperfusion in ETB, A1 and P1. The absent depiction of normally perfused orthograde insular M2-branches and absent flow of the

distal M1 should be verified in lower flow settings. These TCCS findings result in a suspected diagnosis of distal M1 occlusion, which must be confirmed immediately by CT- or MR-angiography as part of the stroke imaging protocol (gold standard). This makes it possible to make decisions regarding time-dependent treatment options (thrombolysis, MT).

The presence of ETB in M1-occlusion has not only diagnostic but also prognostic relevance. It can be used as a predictor of a more favorable course in diverse clinical scenarios like acute atherosclerotic M1 occlusion (D. Liu et al. *Neuroradiology* 2014; 56: 1023–1030) and large MCA infarcts with critical edema (BK Menon et al. *J Neuroimaging* 2012; 22: 145 – 148).

In conclusion, the presented case illustrates the particular advantage of TCCS in demonstrating complex hemodynamic changes in nearly perfectly collateralized distal M1 occlusion. Besides leptomeningeal anastomoses, the activated ETB represents an important collateral pathway connecting the M1 trunk to insular M2 branch-

es of MCA. In this scenario visualization of ETB in TCCS is not only a potential pitfall to be avoided but also a valuable diagnostic and prognostic sign.

## Acknowledgements

I wish to thank the following people for their contribution to this case report: Mr. J. Sobesky for the encouragement and useful critiques, Mr. D. Meila and G. Schmid for their neuroradiological support and constructive recommendations.

## Conflict of Interest

The authors declare that they have no conflict of interest.

## Authors

Christoph Walter<sup>1</sup>, Gebhard Schmid<sup>2</sup>, Dan Meila<sup>3</sup>, Jan Sobesky<sup>1</sup>

## Affiliations

- 1 Department of Neurologie,  
Johanna-Etienne-Krankenhaus gGmbH, Neuss
- 2 Department of Radiologie,  
Johanna-Etienne-Krankenhaus gGmbH, Neuss
- 3 Department of Neuroradiologie,  
Johanna-Etienne-Krankenhaus gGmbH, Neuss

## Correspondence

Dr. Christoph Walter  
Department of Neurologie  
Johanna-Etienne-Krankenhaus gGmbH  
Am Hasenberg 46  
41462 Neuss  
Deutschland  
Tel.: 02131 529 56026  
c.walter@ak-neuss.de

## Bibliography

Ultrasound Int Open 2020; 6: e41–e43

DOI 10.1055/a-1225-4357

ISSN 2199-7152

© 2020. The Author(s).

This is an open access article published by Thieme under the terms of the Creative Commons Attribution-NonDerivative-NonCommercial-License, permitting copying and reproduction so long as the original work is given appropriate credit. Contents may not be used for commercial purposes, or adapted, remixed, transformed or built upon. (<https://creativecommons.org/licenses/by-nc-nd/4.0/>)

