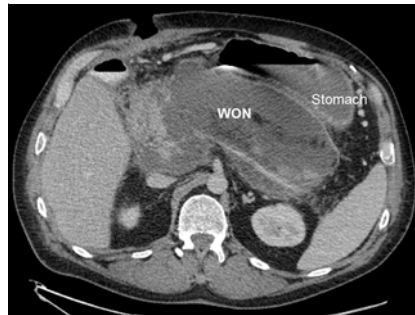

Endoscopy-guided percutaneous stapled pancreatic cystgastrostomy and necrosectomy

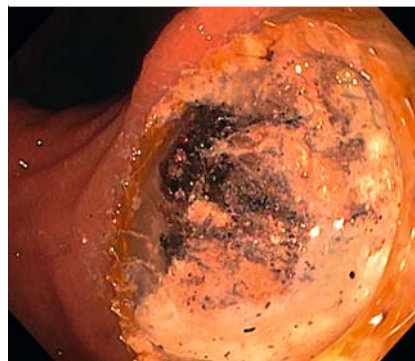
Endoscopic ultrasound (EUS)-guided transmural drainage of symptomatic pancreatic fluid collections using plastic or metal stents has become first-line therapy [1,2]. However, stents can become occluded despite direct endoscopic necrosectomy (DEN) of the walled-off necrosis (WON), and an alternative management plan is required.

A 57-year-old man with necrotizing pancreatitis developed an 18-cm WON (► Fig. 1), producing significant mass effect on the stomach and surrounding bowel. EUS-guided cystgastrostomy was performed with placement of two lumen-apposing metal stents (LAMS) in the body and the antrum of the stomach. Despite undergoing seven sessions of extensive DEN, the massive cavity could not be completely cleared of necrotic material, and the patient repeatedly presented with infection due to recurrent clogging of the LAMS (► Fig. 2). We therefore reviewed the case with our minimally invasive surgical colleagues and devised an innovative approach utilizing endoscopic and laparoscopic tools for definitive therapy.

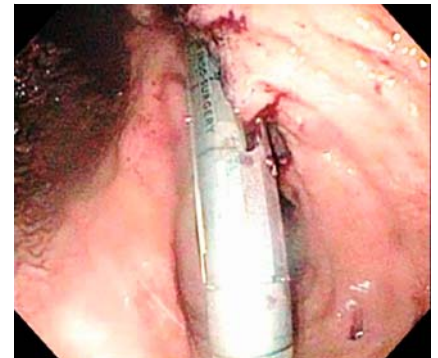
Under endoscopic guidance, we created an anchored percutaneous gastrostomy site on the anterior gastric wall, through which we placed a 12-mm port directly into the stomach. The distal LAMS was removed, and the stapler was placed via the port into the existing cystgastrostomy site. The stapler was aimed towards the proximal LAMS (► Fig. 3). Several applications of the stapler were used to create a wide opening of the cavity into the gastric lumen. This allowed extensive debridement of the cavity using laparoscopic tools under endoscopic guidance, which could not be performed with purely endoscopic techniques (► Video 1). Large pieces of necrotic material were retrieved (► Fig. 4). A percutaneous endoscopic gastrostomy tube was placed at the newly created gastrostomy site.



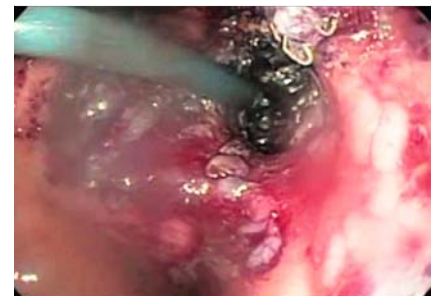
► Fig. 1 Large pancreatic walled-off necrosis collection causing gastric outlet obstruction.



► Fig. 2 Persistent infection due to recurrent stent occlusion despite multiple endoscopic necrosectomy sessions.



► Fig. 3 Percutaneous stapler used via the anterior abdominal wall gastrostomy port to extend the existing cystgastrostomy site on the posterior abdominal wall under endoscopic guidance.



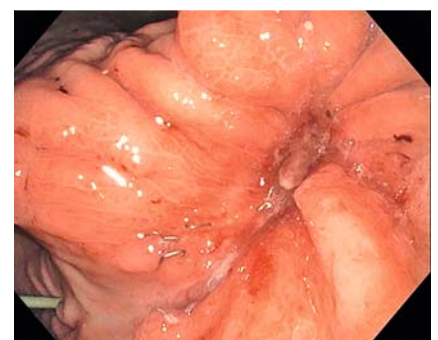
► Fig. 4 Percutaneous necrosectomy using laparoscopic tools under endoscopic guidance.

Follow-up endoscopy and computed tomography scan 3 months later showed complete resolution of the WON cavity (► Fig. 5). The combined laparoscopic and endoscopic approach created a wide cystgastrostomy and allowed for one-step debridement after repeated endoscopic necrosectomies failed.

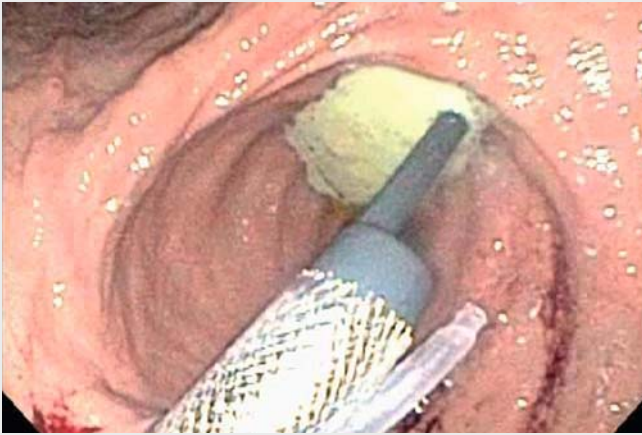
Endoscopy_UCTN_Code_TTT_1AR_2AI

Competing interests

The authors declare that they have no conflict of interest.



► Fig. 5 Complete resolution of the walled-off necrosis cavity at 3-month follow-up.



Video 1 Endoscopically guided percutaneous stapled cystgastrostomy and necrosectomy of a large walled-off pancreatic necrosis collection refractory to endoscopic debridement.

References

- [1] Patil R, Ona MA, Papafragkakis C et al. Endoscopic ultrasound-guided placement of AXIOS stent for drainage of pancreatic fluid collections. *Ann Gastroenterol* 2016; 29: 168–173
- [2] Singhal S, Rotman SR, Gaidhane M et al. Pancreatic fluid collection drainage by endoscopic ultrasound: an update. *Clin Endosc* 2013; 46: 506–514

Bibliography

Endoscopy 2021; 53: E199–E200
DOI 10.1055/a-1220-5926
ISSN 0013-726X
published online 2.9.2020
 © 2020. Thieme. All rights reserved.
 Georg Thieme Verlag KG, Rüdigerstraße 14,
 70469 Stuttgart, Germany

The authors

Harshit S. Khara¹, Jon D. Gabrielsen², David L. Diehl¹, Ryan D. Horsley²

- 1 Division of Gastroenterology and Hepatology, Geisinger Medical Center, Danville, Pennsylvania, United States
- 2 Division of Foregut and Bariatric Surgery, Geisinger Medical Center, Danville, Pennsylvania, United States

Corresponding author

Harshit S. Khara, MD, FACP, FASGE
 Center for Advanced Therapeutic Endoscopy, Division of Gastroenterology and Nutrition, Geisinger Medical Center, 100 N. Academy Avenue, 21-11, Danville, PA 17822, United States
 Fax: +1-570-271-6852
 hskhara@geisinger.edu

ENDOSCOPY E-VIDEOS

<https://eref.thieme.de/e-videos>



Endoscopy E-Videos is a free access online section, reporting on interesting cases and new techniques in gastroenterological endoscopy. All papers include a high quality video and all contributions are freely accessible online.

This section has its own submission website at
<https://mc.manuscriptcentral.com/e-videos>