Article published online: 2020-06-26

Esophageal anisakiasis observed using magnifying endoscopy with narrow-band imaging

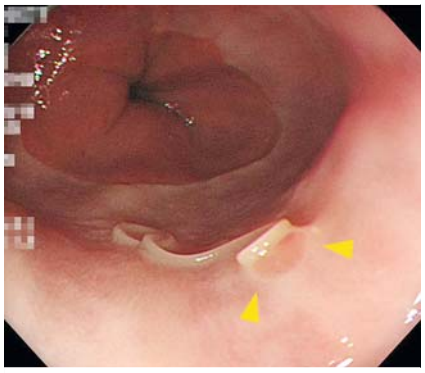

▶ **Fig. 1** Esophagogastroduodenoscopy image showing an Anisakis larva invading the mucosa of the distal esophagus. At the invading site, a granulomatous reddish nodule approximately 2 mm in diameter is observed (arrowheads).

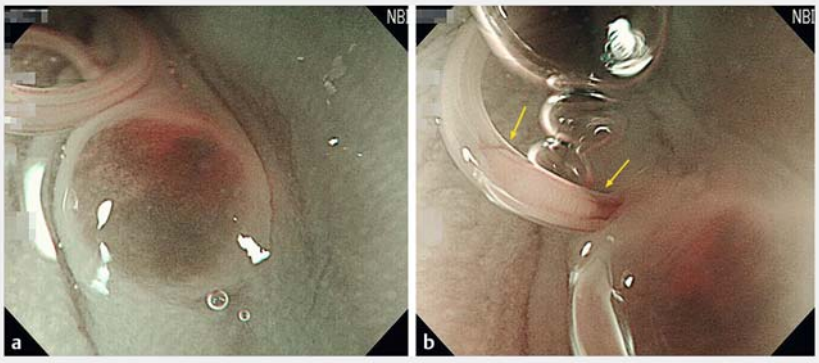

▶ **Fig. 2** Magnifying endoscopy with narrow-band imaging showing: **a** a nodule that is round, rather flattened, and smooth, with neither vascular structure nor surface pattern of the brownish lesion; **b** on closer view of the Anisakis larva, a small whitish elongated spot (arrows) that is seen more clearly than on conventional white-light endoscopic observation (the whitish spot corresponds to the ventricle that is an organ distally adjacent to the esophagus of Anisakis larva).

Video 1 Endoscopic observation of an Anisakis larva invading the esophageal mucosa using conventional white-light imaging and magnifying endoscopy with narrow-band imaging; thereafter, endoscopic removal of the larva is performed with biopsy forceps.

A 31-year-old man presented with a feeling of compression and intermittent pain in the epigastrium. He had eaten sliced raw fish (sashimi) for dinner at 10 pm on the previous night and developed epigastric symptoms 2 hours thereafter. Physical examination revealed no tenderness or rebound tenderness in the epigastrium; his vital signs and laboratory parameters were normal. He reported a history of similar epigastric symptoms when he had had gastric anisakiasis; therefore, esophagogastroduodenoscopy (EGD) was conducted. This revealed an Anisakis larva invading the mucosa of the distal esophagus, where a granulomatous reddish nodule approximately 2 mm in diameter was observed (▶ **Fig. 1**). Magnifying endoscopy with narrow-band imaging (NBI) showed a rather flattened, smooth, and brownish nodule without vascular structure or surface pattern (▶ **Fig. 2 a**). Closer view of the larva revealed a small whitish elongated spot (the ventricle, an organ distally adjacent to the esophagus of Anisakis larva), which is seen more clearly than with conventional white-light endoscopic observation (▶ **Fig. 2 b**). After removing the parasite using biopsy forceps (▶ **Video 1**), his symptoms reduced immediately. At the 1-month follow-up EGD, the nodule had disappeared.

Anisakis infection most commonly affects the stomach and the small intestine [1]. Anisakiasis confined to the esophagus is very rare; only four cases have been reported thus far in the English literature [2–5]. To our knowledge, this is the first case report that showed a nodular lesion of esophageal mucosa penetrated by an Anisakis larva, although it is well known that gastric anisakiasis may cause a tumor-like nodule or mass (also called

This document was downloaded for personal use only. Unauthorized distribution is strictly prohibited.

"vanishing tumor"). When gastrointestinal symptoms that occur after a history of consumption of raw or undercooked fish or squid suggest Anisakis infection, not only the stomach and the duodenum but also the esophagus should be thoroughly examined endoscopically. A study of further cases is needed to clarify whether the nodular lesion, as seen in our case, is common in esophageal anisakiasis.

Endoscopy_UCTN_Code_CCL_1AB_2AG_3AD

Competing interests

The authors declare that they have no conflict of interest.

The authors

Tomohiko Mannami[1], Nobukiyo Fujiwara[2], Genyo Ikeda[2], Toshiyuki Wakatsuki[1], Yasushi Fukumoto[1], Shin'ichi Furutachi[1], Shin'ichi Shimizu[1]

1 Department of Gastroenterology, National Hospital Organization Okayama Medical Center, Okayama, Japan
2 Department of Internal Medicine, Chugoku Central Hospital, Fukuyama, Japan

Corresponding author

Tomohiko Mannami, MD
Department of Gastroenterology, National Hospital Organization Okayama Medical Center, 1711-1 Tamasu, Kita-Ku, Okayama 701-1192, Japan
Fax: +81-86-2949255
tmannami-gi@umin.ac.jp

References

[1] Hochberg NS, Hamer DH. Anisakidosis: Perils of the deep. Clin Infect Dis 2010; 51: 806–812
[2] Urita Y, Nishino M, Koyama H et al. Esophageal anisakiasis accompanied by reflux esophagitis. Intern Med 1997; 36: 890–893
[3] Muguruma N, Okamura S, Okahisa T et al. Anisakis larva involving the esophageal mucosa. Gastrointest Endosc 1999; 49: 653–654
[4] Uehara A, Okumura T. Esophageal anisakiasis mimicking gastroesophageal reflux disease. Am J Gastroenterol 2017; 112: 532
[5] Ikegami K, Hirose Y, Yoneyama O. An unusual cause of severe epigastric pain. Gastroenterology 2018; 154: e7–e8

Bibliography

Endoscopy 2021; 53: E83–E84
DOI 10.1055/a-1195-2273
ISSN 0013-726X
published online 26.6.2020
© 2020. Thieme. All rights reserved.
Georg Thieme Verlag KG, Rüdigerstraße 14, 70469 Stuttgart, Germany

ENDOSCOPY E-VIDEOS
https://eref.thieme.de/e-videos

Endoscopy E-Videos is a free access online section, reporting on interesting cases and new techniques in gastroenterological endoscopy. All papers include a high quality video and all contributions are freely accessible online.

This section has its own submission website at https://mc.manuscriptcentral.com/e-videos

This document was downloaded for personal use only. Unauthorized distribution is strictly prohibited.