Article published online: 2020-05-29

Cut the weeds and dig up the roots: clip-and-snare assisted endoscopic mucosal resection of a rectal neuroendocrine tumor

Endoscopic submucosal dissection (ESD) has been the preferred treatment of small gastrointestinal neuroendocrine tumors (NETs) (≤10 mm) without muscularis propria invasion [1]; however, the requirements of special instruments and complex skills have limited its widespread application [2]. In this regard, we developed a simple clip-and-snare assisted endoscopic mucosal resection (CS-EMR) technique for complete removal of a rectal NET (▶ **Video 1**).

A 35-year-old man was referred for endoscopic treatment of a small rectal NET (6 mm). Because the NET was seen on colonoscopy to have a flat subepithelial surface (▶ **Fig. 1 a**) and was evaluated on endoscopic ultrasonography (EUS) as not showing invasion of the muscularis propria, CS-EMR was used to achieve complete resection. As the transparent cap-covered single-channel endoscope, along with a pre-anchored snare, entered the rectum to target the tumor, a clip was inserted through the working channel of the endoscope and was used to grasp the mucosa adjacent to the tumor (▶ **Fig. 1 b**). When the NET had been well lifted by the clip and transformed into a "pedicle polyp," the snare was released from the endoscope and completely enveloped the root of the NET (▶ **Fig. 1 c**). The NET was fully excised using a blended electrosurgical current (▶ **Fig. 1 d**), leaving a clean surgical wound (▶ **Fig. 1 e**). The wound was immediately closed by the lifting clip and application of a further clip (▶ **Fig. 1 f**). Histological examination of the resected specimen revealed a G1 NET with negative margins (▶ **Fig. 2**).

Unlike the previously reported grasp-and-snare EMR, which requires a dual-channel endoscope to deploy a snare and a biopsy forceps through each channel [3], this CS-EMR needs only a single-channel endoscope. Unlike with the "underwater" EMR technique, which may be affected by blind vision once bleeding occurs [4], the CS-EMR has no risk of causing bleeding before resection. Therefore, the easy and safe CS-EMR technique is a promising alternative to replace ESD in the treatment of small NETs.

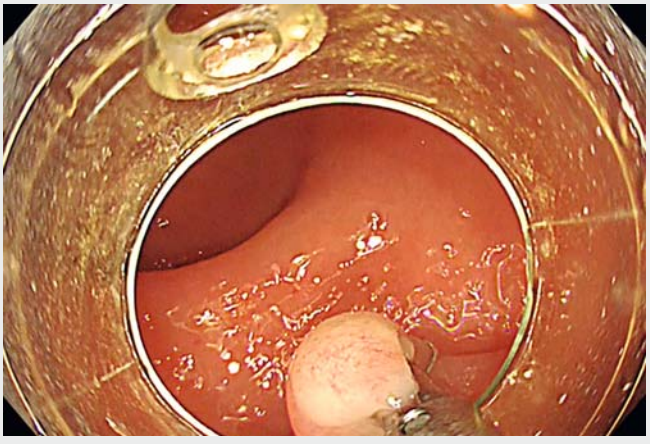

Video 1 Clip-and-snare assisted endoscopic mucosal resection of a rectal neuroendocrine tumor. A reopenable clip is used to lift the flat lesion away from the muscularis propria, allowing a preloaded snare to encircle the resulting "polyp" root below the clip and endoscopically resect it. The surgical wound is closed by clips.

Endoscopy_UCTN_Code_TTT_1AQ_2AD

Acknowledgments

This study was supported by the Natural Science Foundation of Liaoning Province (No. 2019-ZD-0932) and the Project of Department of Education, Liaoning Province (No. LZ2019019).

Competing interests

The authors declare that they have no conflict of interest.

The authors

Wei-hui Liu[1,*], Shi Liu[2,*], Ying Gong[2], Hideki Kobara[3], Shi-Bin Guo[2], Jian Gong[2]

1 Department of Gastroenterology and Hepatology, Sichuan Academy of Medical Sciences & Sichuan Provincial People's Hospital, Chengdu, Sichuan, China
2 Department of Gastroenterology, The First Affiliated Hospital, Dalian Medical University, Dalian, Liaoning, China
3 Department of Gastroenterology and Neurology, Faculty of Medicine, Kagawa University, Kita, Kagawa, Japan

* contributed equally to this paper

This document was downloaded for personal use only. Unauthorized distribution is strictly prohibited.

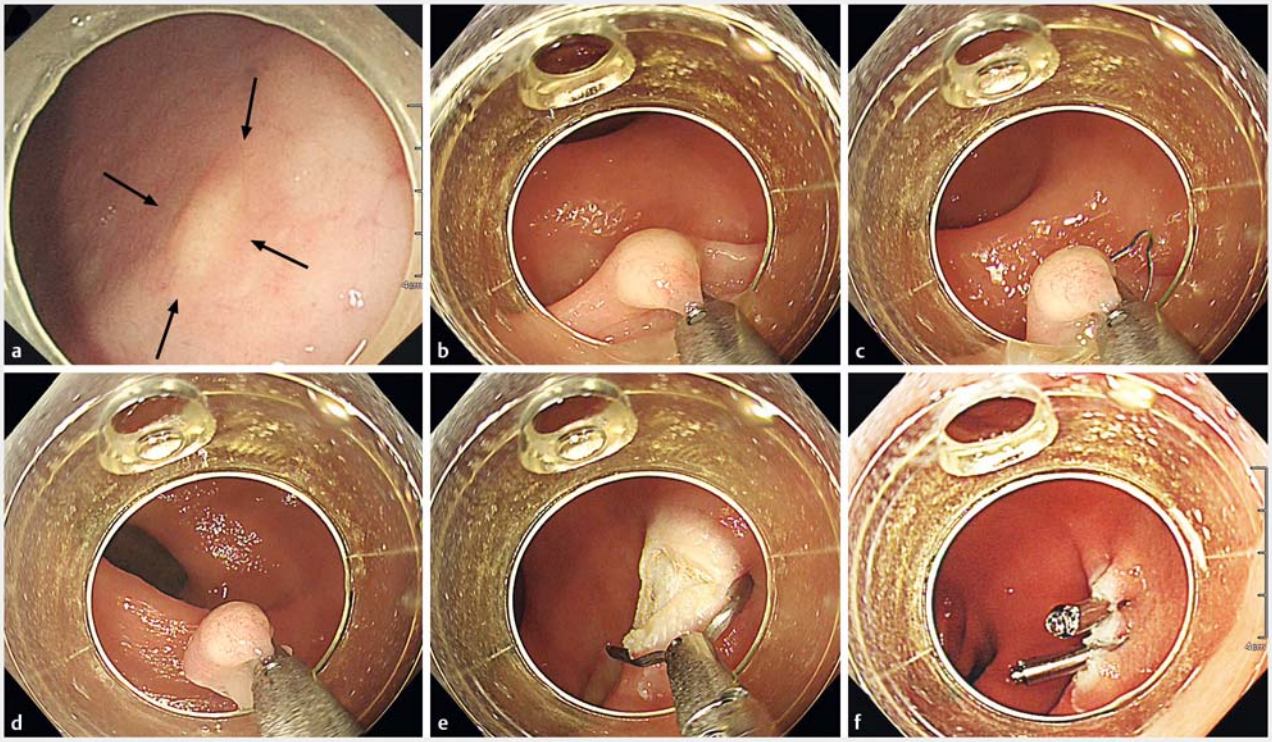

▶ **Fig. 1** Endoscopic treatment of a rectal neuroendocrine tumor (NET) using the clip-and-snare assisted endoscopic mucosal resection (CS-EMR) technique. **a** Colonoscopy showed a subepithelial lesion (arrows) with typical NET features of poorly protruded surface and superficial yellowish mucosa. **b** The clip gently clamped and pulled the lesion toward the endoscope to separate it from the muscularis propria. **c** The snare was advanced beneath the clip and tightly trapped the root of the lesion. **d** The lesion was resected with standard polypectomy settings. **e** A clean surgical wound was displayed. **f** The surgical wound was perfectly closed with only two clips.

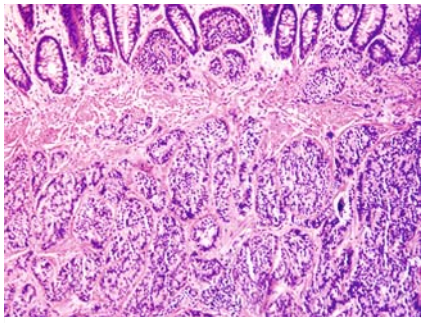

▶ **Fig. 2** Histological appearance confirming the resected specimen as a G1 neuroendocrine tumor with negative margins.

Corresponding author

Jian Gong, MD
Department of Gastroenterology, The First Affiliated Hospital, Dalian Medical University, 222 Zhongshan Road, Dalian, Liaoning 116011, P.R. China
gongjian@dmu.edu.cn

References

[1] Park SS, Han KS, Kim B et al. Comparison of underwater endoscopic mucosal resection and endoscopic submucosal dissection of rectal neuroendocrine tumors (with videos). Gastrointest Endosc 2020. doi:10.1016/j.gie.2019.12.039
[2] Oung B, Walter T, Hervieu V et al. Nonampullary duodenal subepithelial neuroendocrine tumor removed R0 by endoscopic submucosal dissection with double clips and rubber band traction. VideoGIE 2019; 4: 570–573
[3] Shetty A, Suarez AL, Dufault DL et al. Endoscopic mucosal resection with grasp-and-snare technique for challenging lesions. Gastrointest Endosc 2016; 84: 738–739
[4] Yoshii S, Hayashi Y, Matsui T et al. "Underwater" endoscopic submucosal dissection: a novel technique for complete resection of a rectal neuroendocrine tumor. Endoscopy 2016; 48 (Suppl. 01): E67–E68

Bibliography

Endoscopy 2021; 53: E13–E14
DOI 10.1055/a-1163-7140
ISSN 0013-726X
published online 29.5.2020
© 2020. Thieme. All rights reserved.
Georg Thieme Verlag KG, Rüdigerstraße 14, 70469 Stuttgart, Germany

ENDOSCOPY E-VIDEOS
https://eref.thieme.de/e-videos

Endoscopy E-Videos is a free access online section, reporting on interesting cases and new techniques in gastroenterological endoscopy. All papers include a high quality video and all contributions are freely accessible online.

This section has its own submission website at https://mc.manuscriptcentral.com/e-videos

This document was downloaded for personal use only. Unauthorized distribution is strictly prohibited.