Article published online: 2020-05-12

Rectal tonsil: a rare cause of rectal bleeding

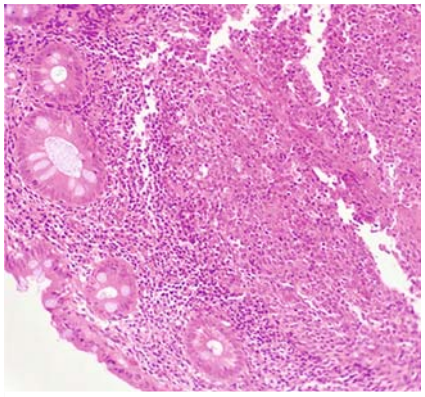

▶ **Fig. 1** Rectal mucosa of a 21-year-old patient with a 4-month history of rectal bleeding. Lymphatic follicle with a prominent germinal center containing tingible body macrophages (H&E, × 10).

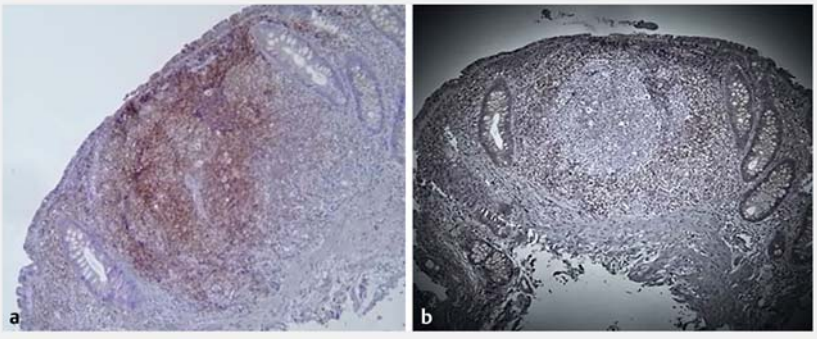

▶ **Fig. 2** Rectal mucosa of the same patient. **a** Lymphatic follicle positive for CD20 (× 10); **b** lymphatic follicle with germinal center negative for Bcl2 (× 10).

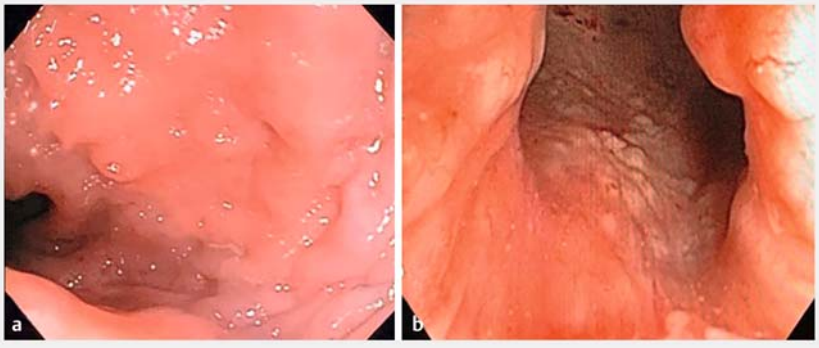

▶ **Fig. 3** Treatment with rectal mesalazine: appearance of the rectal mucosa before treatment (**a**) and after treatment (**b**).

A rectal tonsil is a lymphoid follicular hyperplasia of the rectum and a rare cause of rectal bleeding. As it is a benign lesion of uncertain etiology [1, 2], treatment is reserved for symptomatic patients [2].

We present the case of a 21-year-old woman with normal bowel movements who presented with a history of rectal bleeding over a period of 4 months. Digital rectal examination revealed a rectal mass. Colonoscopy revealed circumferential granular involvement of the rectal mucosal surface (▶ **Video 1**). Histology showed a dense lymphoid infiltrate and lymphatic follicles (▶ **Fig. 1**).

Infection [3] and lymphoma were excluded (▶ **Fig. 2**) and a diagnosis of rectal tonsil was made [4]. Excellent clinical and endoscopic response was achieved after a 1-month course of rectal mesalazine administered twice daily (▶ **Fig. 3**). Because the lesion is benign in nature, with transformation into lymphoma being the exception [4], treatment was discontinued. The patient continued asymptomatic at 3-month clinical follow-up.

Endoscopy_UCTN_Code_CCL_1AD_2AC

Acknowledgments

We acknowledge Prof. Dr. Carolina Olano (Hospital de Clínicas Uruguay) for her dedication and support in the publication of this E-Video.

Competing interests

The authors declare that they have no conflict of interest.

The authors

Ignacio Moratorio[1], M. Alejandra Arriola[1], Ximena Pazos[1], Patricia Dorfman[2], Marta Otero[2]

1 Department of Gastroenterology, Hospital de Clínicas, Facultad de Medicina, Universidad de la República, Montevideo, Uruguay

2 Department of Pathological Anatomy, Hospital de Clínicas, Facultad de Medicina, Universidad de la República, Montevideo, Uruguay

This document was downloaded for personal use only. Unauthorized distribution is strictly prohibited.

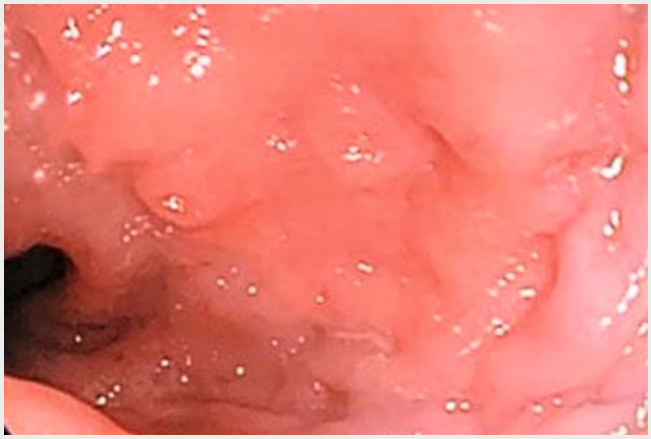

Video 1 Colonoscopic appearance of a rectal tonsil before and after treatment with mesalazine.

Corresponding author

Ignacio Moratorio, MD
Gregorio Suarez 2825/205, CP 11300
Montevideo, Uruguay
ignaciomoratorio@gmail.com

References

[1] Hong JB, Kim HW, Kang DH et al. Rectal tonsil: A case report and literature review. World J Gastroenterol 2015; 21: 2563–2567
[2] Trillo L, Arias M, Iglesias A et al. Amígdala rectal o hiperplasia folicular linfoide del recto. Radiología 2014; 56: 370–373
[3] Cramer SF, Romansky S, Hulbert B et al. The rectal tonsil: a reaction to chlamydial infection? Am J Surg Pathol 2009; 33: 483–485
[4] Farris AB, Lauwers GY, Ferry JA et al. The rectal tonsil: a reactive lymphoid proliferation that may mimic lymphoma. Am J Surg Pathol 2008; 32: 1075–1079

Bibliography

Endoscopy 2020; 52: E443–E444
DOI 10.1055/a-1158-8882
ISSN 0013-726X
published online 12.5.2020
© 2020. Thieme. All rights reserved.
Georg Thieme Verlag KG, Rüdigerstraße 14, 70469 Stuttgart, Germany

ENDOSCOPY E-VIDEOS
https://eref.thieme.de/e-videos

Endoscopy E-Videos is a free access online section, reporting on interesting cases and new techniques in gastroenterological endoscopy. All papers include a high quality video and all contributions are freely accessible online.

This section has its own submission website at https://mc.manuscriptcentral.com/e-videos

This document was downloaded for personal use only. Unauthorized distribution is strictly prohibited.