

Saphenofemoral recurrence from an anatomist's point of view

Das Krossenrezidiv der V. saphena magna aus Sicht des Anatomen

Author

Erich Brenner

Affiliation

Institute of Clinical and Functional Anatomy, Medical University of Innsbruck

Key words

great saphenous vein, varices, recurrence, accessory saphenous veins, neovascularization

Schlüsselwörter

V. saphena magna, Varizen, Rezidiv, Vv. saphenae accessoriae, Neovaskularisation

Bibliography

DOI <https://doi.org/10.1055/a-1154-9122>

Published online: May 25, 2020

Phlebologie 2020; 49: 133–138

© Georg Thieme Verlag KG, Stuttgart · New York

ISSN 0939-978X

Correspondence

Ao. Univ. Prof. Dr. Erich Brenner, MME (Bern)

Institut für Klinisch-Funktionelle Anatomie

Medizinische Universität Innsbruck, Müllerstraße 59,

6020 Innsbruck, Österreich

Tel.: ++43/5 12/9 00 3-7 11 21

Erich.Brenner@i-med.ac.at

ABSTRACT

From an anatomical point of view, recurrences at the saphenofemoral junction (SFJ) could result from various sources. For one, it could be caused by a recanalisation of an originally occluded great saphenous vein (GSV). Secondly, another vein in the junction region could take over the function of the GSV and dilate. A third variation is a – more or less successful – generation of a new vein. In the last case, a sufficient vein could be generated, an insufficient vein could arise, or an inadequate venous regeneration, so that a cluster of frail but incomplete vasculature remains (neovasculature).

ZUSAMMENFASSUNG

Rezidive im Bereich der Krosse, dem Einmündungsbereich der V. saphena magna, können aus anatomischer Sicht aus verschiedenen Quellen stammen. Einerseits kann es sich um eine Rekanalisation einer ursprünglich verschlossenen V. saphena magna handeln. Zweitens kann eine andere Vene der Krossenregion die Funktion übernehmen und dilatieren. Als dritte Variante kommt eine – mehr oder minder gelungene – Neubildung infrage. Im letzteren Fall kann es zur Neubildung einer suffizienten Vene kommen, es kann eine insuffiziente Vene entstehen oder aber es gelingt keine hinreichende Venenbildung und es bleibt bei büschelartigen, zarten, aber völlig inkompletten Gefäßchen (Neovaskularisate).

Introduction

Saphenofemoral recurrence (SFR) must first, for all further considerations, be clearly defined. It concerns a reappearance of venous vasculature in the region of the SFJ, i. e. in the region of the saphenous opening and its immediate surrounding. The question of whether this vasculature is sufficient or not, is clinically very significant, but not, however, morphologically.

An SFR can have multiple causes:

1. The great saphenous vein (GSV) recanalises, in a sense within its own original wall layers
2. A vein, usually far smaller, originally located close to the GSV takes over its function and thereby gets dilated
3. The GSV regenerates itself from its own remaining stump. This can, per se, result in a sufficient vein that, with time and persistent chronic venous insufficiency (CVI), can itself degrade

into insufficiency and varicosity. The second alternative constitutes a developmental defect in which a cluster of multiple incomplete vasculature arises that has no real resemblance to a vein.

These causes shall subsequently be taken into consideration as per morphologic criteria.

Topographic anatomy of the SFJ region

The GSV rises through its saphenous compartment on the medial side of the thigh [1] and curves to the front around the gracilis muscle. In this region the saphenous fascia rises and joins the cribriform fascia. In this larger space, mostly lateral to the GSV, exist many lymph collectors that lie superficial as well as deep to the vein. Many lymph nodes lie mostly lateral to and with direct con-

tact to the GSV at a distance of about 5 cm shortly before the junction. Their number varies individually and they are connected transversely through many lymph vessels, but not with the superficial lymph nodes that comprise the drainage of the external abdominal wall [2].

Before its junction with the femoral vein, the GSV has two parietal valves, namely, the preterminal and the terminal valve, between which the large branches of the so-called venous star usually drain into the GSV – the superficial epigastric vein, superficial circumflex iliac vein, anterior accessory saphenous vein and external pudendal vein, the latter often paired. These large branches can additionally, and in various combinations, drain into the GSV through a common stem [3]. There are also small branches of varied amount and “source” along these large branches. One of the most important “sources” of the aforementioned small branches are the efferent veins of the inguinal lymph nodes. Such efferent veins of the inguinal lymph nodes could alternatively drain past the saphenous opening into the deep, either directly into the femoral vein or into another subfascial vein. (► Fig. 1)

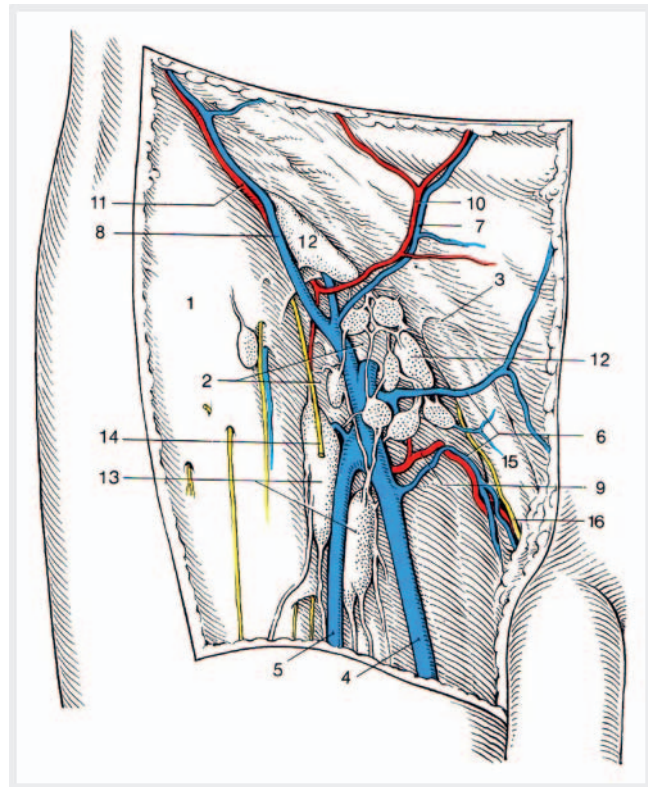
Lastly, the GSV, accompanied by efferent lymph collectors of the superficial inguinal lymph nodes of the leg, drains through the saphenous opening of the fascia lata into the femoral vein.

Recanalisation

The recanalisation of the GSV is naturally only relevant when this vein – at least rudimentarily as a cord of connective tissue – is present. Therefore endovenous therapy procedures come here into focus. In 2016, Van der Melden et al carried out an analysis of the predictors of recanalisation [4]. Significant factors that increase the risk of recanalisation are a C-value > 2 in the CEAP-Classification, a reflux in the SFJ and male sex. Justifiably, Owain Fisher hinted in his reply that in this study the recanalisation itself served as an indicator for failure of treatment [5]. Before completely evaluating the meaning of the predictors, it thus needs to be clarified, what part of recanalisation leads to a clinically significant recurrence and what part to a renewed requirement for an intervention. In contrast, Kemaloğlu described the diameter of the GSV as the singular risk factor for a recanalisation [6].

Regardless of the recanalisation rates of the individual therapeutic modalities, the fact is that a recanalisation of the original vein can occur. The mechanisms of this process are based upon the simple sequence of inflammatory reactions following an injury. These reaction stages have the task of restoring normal function, in other words – a patent vein. A dysfunctional scar is an “acceptable” result of the healing process only in absolute exceptions. From published data, we can surmise that this “absolute exception” occurs often, such that the damage was so severe that a normal restitution of function was not possible. As a counter argument, it follows that all the parameters that influence the impact of various agents on the vein wall, like the diameter of the vein itself, themselves influence possible recanalisation.

The starting point of the recanalisation can, on the one hand, lie within the process of organisation of thrombi, and on the other hand, the source for the formation of a venous lumen can also be undamaged vasa vasorum of the original GSV.



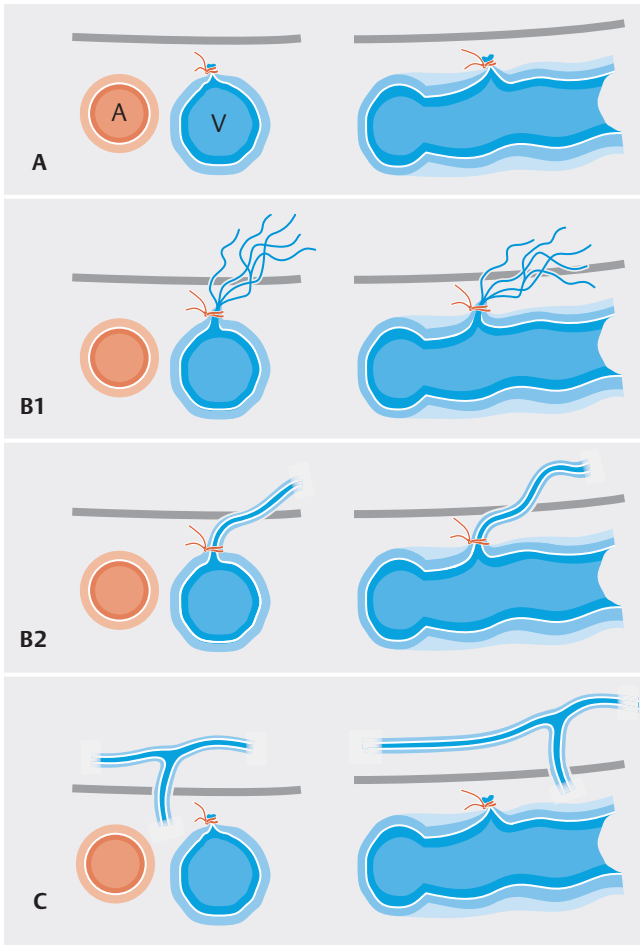
► Fig. 1 Subinguinal region after removal of the cribriform fascia. For the sake of simplification, only the exposed veins are listed here: 4. great saphenous vein, 5. anterior accessory saphenous vein, 6. external pudendal veins, 7. superficial epigastric vein, 8. superficial circumflex iliac vein. Small efferent veins from inguinal lymph nodes drain into the external pudendal as well as anterior accessory saphenous vein. Reference: Platzer W, Shiozawa T. Regio subinguinalis. In: Platzer W, Shiozawa T, Hrsg. Taschenatlas Anatomie, Band 1: Bewegungsapparat. 12., aktualisierte Auflage. Stuttgart: Thieme; 2018. doi:10.1055/b-006-149537.

Alternative Veins

The second of the possible causes of development of SFR is the taking over of the drainage function by – usually very small – venous branches along the original GSV (“Pseudorecurrence”, Type C Fischer, Linde, Duff, et al. [7]: ► Fig. 2). First and foremost, this would arise from a large branch of the venous star – the superficial epigastric vein, superficial circumflex iliac vein, anterior accessory saphenous vein and external pudendal vein (► Fig. 3) or – a small unnamed side branch of the GSV (2% as per [8]).

The superficial epigastric vein (SEV) is mostly not the real origin point, as this vein is under “strict” observation during endovenous interventions. However, the SEV drained in 78.3% (170/217) cases at an average distance of 1.2 cm from the SFJ directly into the GSV [3]; in 103 cases (47.5%) it formed a common stem with another vein of the venous star. Reichmann, Broermann and Vogt [8] blamed this vein for at least 14% of their 210 recrosssections of SFR post open surgical first surgery.

The superficial circumflex iliac vein (SCIV) is definitely another origin point for SFR. In contrast to the SEV, due to of its medio-lateral course, the SCIV is most often overlooked during sonographic



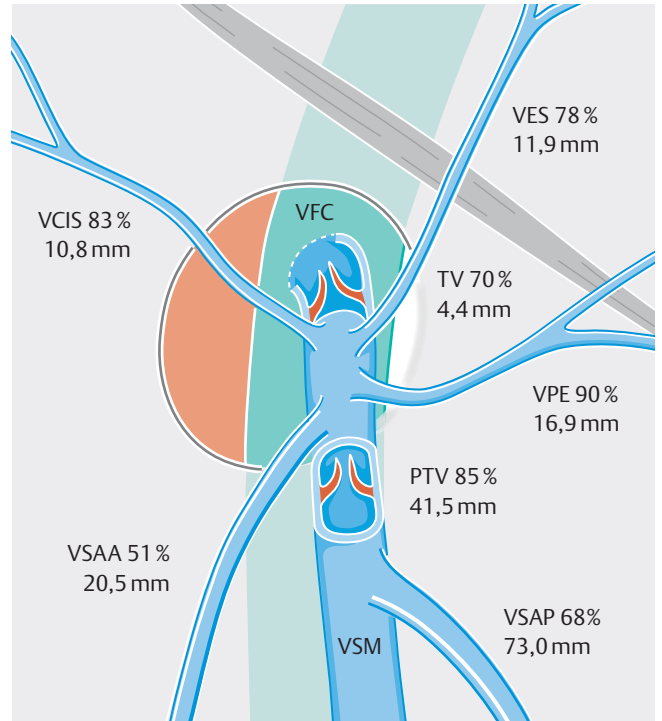
► **Fig. 2** Classification of saphenofemoral recurrence. Type A: no recurrence. Type B1: strand or wad-like true recurrence from point of previous ligation. Type B2: single vein, true recurrence from point of previous ligation. Type C: pseudorecurrence from the surrounding region of the previous saphenofemoral junction.

control in endovenous procedures. In 82.9% cases this vein drains into the GSV at an average of 1.1 cm distal to the SFJ [3]. Besides this, the SCIV occasionally forms a common drainage stem with the SEV into the GSV.

The external pudendal vein (EPV) – or veins – can likewise be an origin point for SFR (23% as per [8]). Because of its course and position, this vein is also often overlooked during sonographic control in endovenous procedures.

The anterior accessory saphenous vein (AASV) also plays a role as a source for SFR. Gerner, Heppell and Leopold [9] held a persistent AASV accountable for 61 in 141 cases (43.3%) of SFR. At 37%, even Reichmann, Broermann and Vogt [8] indicate a relatively similar high number of persistent AASV. In these cases, most (95%) drained directly into the GSV, the remaining 5% continued into the deep venous system via a subinguinal perforating vein.

Perforating inguinal veins are also a possible cause. Overall, there was a significantly higher rate of occurrence of incompetent perforating veins in patients with recurrence versus primary varicosis [10, 11]. The evidence of insufficient perforating veins (with



► **Fig. 3** Idealized saphenofemoral junction with major superficial tributary veins. VFC common femoral vein; VSM great saphenous vein; VCIS superficial circumflex iliac vein; VES superficial epigastric vein; VPE (superficial) external pudendal vein; VSAA anterior accessory saphenous vein; VSAP posterior accessory saphenous vein; TV terminal valve of the GSV; PTV preterminal valve of the GSV.

the exception of Dodd's perforating vein, the medial femoral perforating vein) significantly increases the risk of SFR [11].

Neo-saphenous vein

The development of a completely new GSV cannot, of course, be ruled out (Type B2 Fischer, Linde, Duff, et al. [7]). This “neo-saphenous vein” can absolutely resemble a completely healthy GSV, and in the case of persistence of CVI can degrade into varicose alteration.

As early as 1861 Langenbeck described that after ligation and extirpation of a section of vein, a new vessel develops in the GSV-region that can reanastomose the remaining ends of the vein [12, cit. 13].

Anecdotal descriptions report a GSV after recrossotomy, that apparently newly developed through and around the original ligation, with this ligation protruding, in the endoluminal aspect, along with endothelial coating from the venous wall into the “new” venous lumen (a corresponding figure is depicted in this edition's contribution from Achim Mumme [14]). The origin point for the neo-saphenous vein here was very probably the remaining saphenous stump.

In a haemodynamic examination of the remaining saphenous stump after invaginating vein stripping without crossotomy, four different types could be demonstrated after a month:

S1) draining and competent terminal valve (64%); S2) thrombosis and fibrosis (18%); S3) turbulence under Valsalva manoeuvre and normal antegrade flow at rest (12%); and S4) turbulence with reflux at rest: insufficient terminal valve (6%) [15]. After two years S1 was at 67%, S2 at 8%, S3 at 15% and S4 at 10%. This examination demonstrates that a functional saphenous stump is the rule in about two-thirds of cases, so that assumably less than a third of cases actually show forms of insufficiency. This gives rise to the question of whether these stumps and – extended to the question of SFR – neo-saphenous veins are encompassed in follow up studies at all.

The point of origin for the development of neo-saphenous veins could be the exposed endothelium of the GSV-stump or of a side branch, that stimulates neoangiogenesis after crosssection through contact with surrounding subcutaneous tissue. Cappelli, Molino-Lova, Giangrandi, et al. [16] described that even the ligation of side branches is associated with a significant risk of recurrence.

A study by Glass demonstrated a sprouting in of new vessels out of surrounding tissue into the coagulum between severed vessels two weeks after ligation and stripping of the GSV, which resulted in a multitude of vascular continuity through the resulting venules, seen after 64 weeks as adequate for a continuity of flow [cit. 13, 17]. Munasinghe, Smith, Kianifard, et al. [18] could demonstrate, that a year after the original Stripping procedure, four (6%) of 70 patients showed a complete recanalisation of the stripping canal and at least twelve (17%) a partial recanalisation, all with duplex confirmed reflux. The partial recanalisation pertained to the distal third of the stripping canal in six legs (9%), the distal half in five (7%), and almost the entire canal in one (1%) leg. All the patients with partial recanalisation had a significant haematoma one week after the initial surgery in the stripping canal. It thus resulted here in a development of a new GSV.

As an alternative to the development of a proper vein, it is possible that many incompletely formed, cluster-like “venules” arise, that have no real similarity to a vein (Type B1 Fischer, Linde, Duff, et al. [7]). This recurrence Type B1 appears either as a strand or a wad of more or less fine varicose veins, at the most with contact to a dysplastic-like venous network in the region of the inguinal lymph nodes [19]. The normal angio- and vasculogenesis here have not elapsed adequately, and what remains is a “developmentally defect” neovasculature, as has been examined and discussed in detail – quite controversially – by numerous authors [17, 20–44].

Discussion

The simplest anatomical variant that can lead to SFR is the taking over of the function of the surgically removed or endovenously occluded GSV by another vein. In this way, the AASV could gain continuity to the deep venous system either directly or indirectly, in the “best case” to the femoral vein itself. Alternatively, other large branches come into question, as well as small efferent veins from the inguinal lymphatic nodes. These variants correspond to Type C (pseudorecurrence) Fischer, Linde, Duff, et al. [7].

A further possibility exists in the recanalisation of the endovenously occluded GSV (Type B2 Fischer, Linde, Duff, et al. [7]). The point of origin for this recanalisation process can be the regular organisation of a left over thrombus. Alternatively tiny vasa vasorum within an incompletely destroyed wall of the GSV could lead to a recanalisation.

The third possibility is – at least the attempt of – a complete regeneration of the GSV originating from the point of ligation or the SFJ stump. A vascular regeneration on the basis of thrombosis in the stripping canal is also plausible. This possibility can itself have three courses. Firstly, a completely sufficient nova-GSV could develop. A neo-saphenous vein of this sort is seldom diagnosed, because patients in this case mostly have no complaints from CVI and therefore do not see their previous treating physician. Even in follow-up studies, a sufficient neo-saphenous vein is rarely detected, as no reflux or symptoms are present. Secondly, a neo-saphenous vein can be present in different stages of CVI. Such vessels are found in follow-up studies, mostly without a detailed morphological description. Quite a few “long SFJ stumps” are found in this group [45], the length of which mostly depends on the previous surgeon. Thirdly, the attempt of the body to create a neo-saphenous vein could end in an angiogenetic fiasco – incompletely formed, “unripe”, totally insufficient venules, i. e. so-called neovasularisation.

A “barrier” in the region of the saphenous opening, as often suggested [eg. 46, 47] could surely reduce a certain amount of regeneration and therefore recurrences in general. It is, however, also associated with a not insignificant amount of lymphologic complications [48], as here efferent lymphatic vessels of the inguinal lymph nodes, which pass through the saphenous opening along with the – original – GSV, are impaired.

Conflict of Interest

The author declares the following conflicts of interest: member of the DGP; travel grants by DGP, ÖGPDa, medi GmbH; honorarium by BERRO AG

References

- [1] Caggiati A, Ricci S. The Long Saphenous Vein Compartment. *Phlebology: The Journal of Venous Disease* 2016; 12: 107–111. doi:10.1177/026835559701200307
- [2] Brenner E. Lymphbahnen an den Beinen. *Phlebologie* 2020. submitted
- [3] Mühlberger D, Morandini L, Brenner E. Venous valves and major superficial tributary veins near the saphenofemoral junction. *J Vasc Surg* 2009; 49: 1562–1569. doi:10.1016/j.jvs.2009.02.241
- [4] Van der Velden SK, Lawaetz M, De Maeseneer MG et al. Predictors of Recanalization of the Great Saphenous Vein in Randomized Controlled Trials 1 Year After Endovenous Thermal Ablation. *Eur J Vasc Endovasc Surg* 2016; 52: 234–241. doi:10.1016/j.ejvs.2016.01.021
- [5] Fisher O. Re: ‘Predictors of Recanalization of the Great Saphenous Vein in Randomized Controlled Trials 1 Year After Endovenous Thermal Ablation’. *Eur J Vasc Endovasc Surg* 2016; 52: 268–268. doi:10.1016/j.ejvs.2016.04.021
- [6] Kemaloğlu C. Saphenous vein diameter is a single risk factor for early recanalization after endothermal ablation of incompetent great saphenous vein. *Vascular* 2019; 27: 537–541. doi:10.1177/1708538119837110

- [7] Fischer R, Linde N, Duff C et al. Das Krosserezidiv – eine Nachkontrolle nach 34 Jahren. *Phlebologie* 2000; 29: 17–22. doi:10.1055/s-0037-1617336
- [8] Reichmann F, Broermann M, Vogt K. Häufigkeit persistierender Venae saphenae accessoriae anteriores und subinguinaler Perforansvenen bei inguinalen Crossenrezidiven. *VasoMed* 2013; 25: 254–256
- [9] Garner JP, Heppell PS, Leopold PW. The lateral accessory saphenous vein—a common cause of recurrent varicose veins. *Ann R Coll Surg Engl* 2003; 85: 389–392
- [10] Rutherford EE, Kianifard B, Cook SJ et al. Incompetent perforating veins are associated with recurrent varicose veins. *Eur J Vasc Endovasc Surg* 2001; 21: 458–460. doi:10.1053/ejvs.2001.1347
- [11] Pawlaczyk K, Zielinski P, Waliszewski K et al. The role of incompetent perforators in the development of recurrences after surgery for primary lower leg varices. *Acta Angiol* 2010; 16: 158–171
- [12] Langenbeck B. Beiträge zur chirurgischen Pathologie der Venen. *Arch Klin Chir* 1861; 1: 1–80
- [13] Breuckmann K. Histomorphologische Klassifikation der Rezidivvarikosis im Bereich der saphenofemorale Junction. Bochum: Ruhr-Universität Bochum. 2005: 79
- [14] Mumme A. Das Crossenrezidiv aus der Sicht des Operateurs. *Phlebologie* 2020; 49: 139–143
- [15] Casoni P, Lefebvre-Vilardebo M, Villa F et al. Stump evolution after great saphenous vein stripping with high ligation. *Veins and Lymphatics* 2016; 5: 5573
- [16] Cappelli M, Molino-Lova R, Giangrandi I et al. Ligation of the saphenofemoral junction tributaries as risk factor for groin recurrence. *J Vasc Surg Venous Lymphat Disord* 2018; 6: 224–229. doi:10.1016/j.jvsv.2017.09.005
- [17] Glass GM. Neovascularization in Recurrence of the Varicose Great Saphenous Vein following Transection. *Phlebology: The Journal of Venous Disease* 1987; 2: 81–91. doi:10.1177/026835558700200205
- [18] Munasinghe A, Smith C, Kianifard B et al. Strip-track revascularization after stripping of the great saphenous vein. *Br J Surg* 2007; 94: 840–843. doi:10.1002/bjs.5598
- [19] Kohler A, Dirsch O, Brunner U. Veno-lymphatische Angiodysplasie als Ursache einer inguinalen Rezidivvarikose; Veno-lymphatic angiodysplasia as a possible cause of inguinal recurrent varicose veins. *VASA* 1997; 26: 52–54
- [20] Corbett CR, Prakash V. Neovascularisation is not an innocent bystander in recurrence after great saphenous vein surgery. *Ann R Coll Surg Engl* 2015; 97: 102–108. doi:10.1308/003588414X14055925061199
- [21] Creton D. Neovascularisation – What is the surgeon's responsibility? *Phlebologie* 2008; 37: 134–141
- [22] De Maeseneer M. Neovascularization: An adverse response to proper groin dissection. In: Bergan JJ, Hrsg The Vein Book. Burlington: Academic Press; 2007: 239–246
- [23] De Maeseneer MG. The role of postoperative neovascularisation in recurrence of varicose veins: from historical background to today's evidence. *Acta Chir Belg* 2004; 104: 283–289. doi:10.1080/00015458.2004.11679555
- [24] Egan B, Donnelly M, Bresnihan M et al. Neovascularization: an “innocent bystander” in recurrent varicose veins. *J Vasc Surg* 2006; 44: 1279–1284; discussion 1284. doi:10.1016/j.jvs.2006.08.017
- [25] Frings N, Tran VTP, Nelle A et al. Krossenrezidiv der Vena saphena magna trotz korrekter Krossektomie: Neoangiogenese. *Phlebologie* 1999; 28: 144–148. doi:10.1055/s-0037-1617154
- [26] Glass GM. Neovascularization in recurrence of varices of the great saphenous vein in the groin: phlebography. *Angiology* 1988; 39: 577–582. doi:10.1177/000331978803900704
- [27] Glass GM. Neovascularization in recurrent sapheno-femoral incompetence of varicose veins: Surgical anatomy and morphology. *Phlebologie* 1995; 10: 136–142
- [28] Glass GM. Prevention of sapheno-femoral and sapheno-popliteal recurrence of varicose veins by forming a partition to contain neovascularization. *Phlebologie* 1998; 13: 3–9. doi:10.1177/026835559801300102
- [29] Glass GM. Neovascularization in Recurrence of Varices of the Great Saphenous Vein in the Groin: Surgical Anatomy and Morphology. *Vasc Surg* 2016; 23: 435–442. doi:10.1177/153857448902300603
- [30] Haas E, Burkhardt T, Maile N. Rezidivhäufigkeit durch Neoangiogenese nach modifizierter Krossektomie. *Phlebologie* 2005; 34: 101–104. doi:10.1055/s-0037-1621409
- [31] Jones L, Braithwaite BD, Selwyn D et al. Neovascularisation is the principal cause of varicose vein recurrence: Results of a randomised trial of stripping the long saphenous vein. *Eur J Vasc Endovasc Surg* 1996; 12: 442–445. doi:10.1016/s1078-5884(96)80011-6
- [32] Labropoulos N, Bhatti A, Leon L et al. Neovascularization after great saphenous vein ablation. *Eur J Vasc Endovasc Surg* 2006; 31: 219–222. doi:10.1016/j.ejvs.2005.06.030
- [33] Mikusek W, Waniczek D, Arendt J et al. Neovascularization in the Region of Saphenofemoral Junction Following Babcock Excision of Great Saphenous Vein. *Polish Journal of Surgery* 2009; 81: 383–391. doi:10.2478/v10035-009-0065-2
- [34] Moreau PM. Neovascularization is not a major cause of varicose vein recurrence. *International Journal of Angiology* 2002; 11: 99–101. doi:10.1007/BF01616375
- [35] Mouton W, Heim D, Janzen J. Neovascularization of saphenous veins. *J Vasc Bras* 2019; 18: e20190030. doi:10.1590/1677-5449.190030
- [36] Nyamekye I, Shephard NA, Davies B et al. Clinicopathological evidence that neovascularisation is a cause of recurrent varicose veins. *Eur J Vasc Endovasc Surg* 1998; 15: 412–415. doi:10.1016/s1078-5884(98)80202-5
- [37] Olbrich S. Saphenofemorales Leistenrezidiv nach Stripping der Vena saphena magna: Neovaskulat oder nicht? [Doctoral thesis]. Bochum: Ruhr-Universität Bochum. 2004
- [38] Ostler AE, Holdstock JM, Harrison CC et al. Primary avalvular varicose anomalies are a naturally occurring phenomenon that might be misdiagnosed as neovascular tissue in recurrent varicose veins. *J Vasc Surg Venous Lymphat Disord* 2014; 2: 390–396. doi:10.1016/j.jvsv.2014.05.003
- [39] Reich-Schupke S, Mumme A, Altmeyer P et al. Decorin expression with stump recurrence and neovascularization after varicose vein surgery – a pilot study. *Dermatol Surg* 2011; 37: 480–485. doi:10.1111/j.1524-4725.2011.01912.x
- [40] Rewerk S, Meyer AJ, Duczek C et al. Beteiligung von VEGF-R (vascular endothelial growth factor receptor) und NGF (nerve growth factor) bei der Neovaskularisation als Ursache der Rezidivvarikosis in der Krosse. In: Deutsche Gesellschaft für Chirurgie, Hrsg. Chirurgisches Forum 2006. Berlin, Heidelberg: Springer; 2006: 429–431. doi:10.1007/3-540-34668-6_145
- [41] Rewerk S, Noppeney T, Nüllen H et al. Neoangiogenese als Rezidivursache nach Krossektomie der primären Stammvarikose. *Gefäßchirurgie* 2008; 13: 130–134. doi:10.1007/s00772-008-0598-4
- [42] Rewerk S, Noppeney T, Winkler M et al. Venoneuronale De- und Regeneration bei Varikogenese und Neovaskularisation – Einfluss von Nerve-growth-Faktor. *Phlebologie* 2007; 36: 8–16
- [43] Rewerk S, Nüllen H, Winkler M et al. Nervenfasern in Exzisten von Rezidivvarizen – Der Wert der S100-Färbung. *Phlebologie* 2005; 34: 299–304
- [44] van Rij AM, Jones GT, Hill GB et al. Neovascularization and recurrent varicose veins: more histologic and ultrasound evidence. *J Vasc Surg* 2004; 40: 296–302. doi:10.1016/j.jvs.2004.04.031

- [45] Mumme A, Burger P, Hummel T et al. Der lang belassene Saphenastumpf. *Phlebologie* 2007; 36: 256–259. doi:10.1055/s-0037-1622194
- [46] De Maeseneer MG, Philipsen TE, Vandebroek CP et al. Closure of the cribriform fascia: an efficient anatomical barrier against postoperative neovascularisation at the saphenofemoral junction? A prospective study. *Eur J Vasc Endovasc Surg* 2007; 34: 361–366. doi:10.1016/j.ejvs.2007.03.020
- [47] Schnyder S, Gabler S, Meier TO et al. Successful reduction of clinical relevant neovascularization with a modified crossectomy combined with a barrier technique after 10-year follow-up. *Phlebology* 2012; 27: 404–408. doi:10.1258/phleb.2011.011065
- [48] De Maeseneer MG, Vandebroek CP, Lauwers PR et al. Early and late complications of silicone patch saphenoplasty at the saphenofemoral junction. *J Vasc Surg* 2006; 44: 1285–1290. doi:10.1016/j.jvs.2006.08.012