Article published online: 2020-04-24

Endorotor-based endoscopic necrosectomy avoiding the superior mesenteric artery

▶ **Fig. 1** The catheter tip emerging from a therapeutic endoscope. The fixed outer cannula and the hollow inner cannula can be seen.

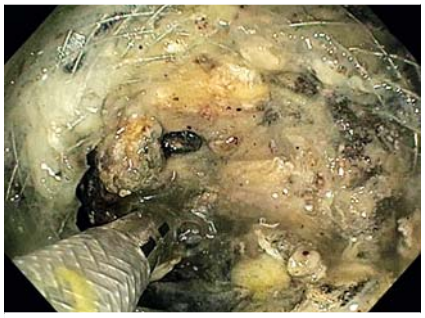

▶ **Fig. 2** The catheter inside the endoscope passing through a previously placed Axios stent (Boston Scientific, Marlborough, Massachusetts, USA) to start direct endoscopic necrosectomy.

▶ **Fig. 3** Endorotor system console (Interscope, Inc., Whitinsville, Massachusetts, USA). Connections to the catheter and vacuum system can be seen.

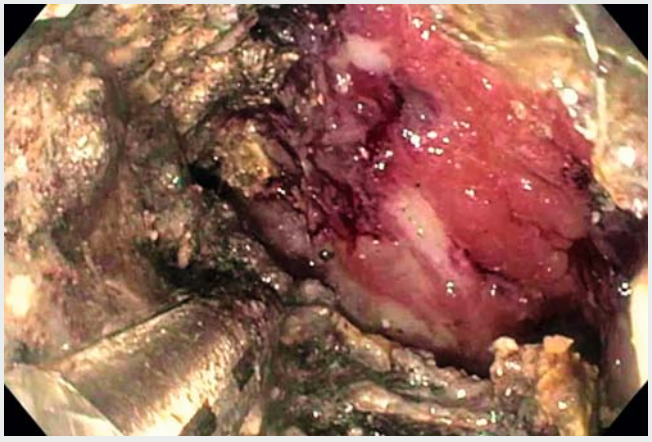

▶ **Video 1** Endoscopic necrosectomy with Endorotor (Interscope, Inc., Whitinsville, Massachusetts, USA), avoiding the superior mesenteric artery.

A 67-year-old man with a 15-cm pancreatic necrotic collection was transferred to our unit after 2 months' hospitalization for necrotizing pancreatitis. His conditions was poor, with decreased mental status, high fever, neutrophilic leukocytosis (white blood cells 27.6×10^9/L, neutrophils 93.1 %), and signs of sepsis (C-reactive protein 150.5 mg/L, procalcitonin 9.83 ng/mL).

Emergency endosonography-guided drainage using a 15 × 10 mm Axios stent (Boston Scientific, Marlborough, Massachusetts, USA) mounted onto a cautery device was successfully performed. During the procedure a major vessel was observed inside the collection. He was sent for embolization but angio-computed tomography revealed the vessel to be the superior mesenteric artery (SMA) and embolization prior to direct endoscopic necrosectomy (DEN) was aborted. A decision to pursue DEN was made and the Endorotor system (Interscope, Inc., Whitinsville, Massachusetts, USA) (▶ **Fig. 1**), which allows constant endoscopic visualization during necrosectomy (▶ **Fig. 2**), was utilized. The procedure was performed using a dedicated Endorotor XT catheter, high rotating speed (1700 rpm), and progressive increase of suction up to 60 L/min (▶ **Fig. 3**), with careful visualization of the site at which the catheter was active (▶ **Video 1**).

After two DEN sessions (40 and 120 minutes' duration, respectively), without any complications, only minimal debris remained in the area proximal to the SMA. A double-pigtail stent was placed through the Axios stent and the patient was discharged home.

At 3 weeks' follow-up, both stents were removed, and the patient remained in good clinical condition thereafter.

Endorotor is a new endoscopic rotating morcellator device, which reported successful accomplishment of DEN in two patients in whom conventional necrosectomy failed [1], and in another patient [2] with a collection containing 70 % necrotic content. In our case, the Endorotor catheter performed DEN under constant endoscopic visualization, allowing successful treatment despite the presence of the SMA inside the collection.

Endoscopy_UCTN_Code_TTT_1AR_2AI

Competing interests

Dr. Larghi has received fees for lecture and training from Pentax Medical and Boston Scientific. He has also received research grant from Medtronic.
Prof. Costamagna is a consultant for Olympus Medical, Boston Scientific Corp., Cook Medical.

The authors

Gianenrico Rizzatti[1,2], Mihai Rimbaș[3], Mariella De Riso[4], Michele Impagnatiello[5], Guido Costamagna[1,2], Alberto Larghi[1,2]

1 Digestive Endoscopy Unit, Fondazione Policlinico Universitario A. Gemelli IRCCS – Università Cattolica del Sacro Cuore, Rome, Italy
2 Center for Endoscopic Research Therapeutics and Training, Catholic University, Rome, Italy
3 Gastroenterology and Internal Medicine Departments, Colentina Clinical Hospital, Carol Davila University of Medicine, Bucharest, Romania
4 Department of Anesthesiology, Fondazione Policlinico Universitario A. Gemelli IRCCS – Università Cattolica del Sacro Cuore, Rome, Italy
5 Internal Medicine, Gastroenterology and Hepatology, Fondazione Policlinico Universitario A. Gemelli IRCCS, Rome, Italy

Corresponding author

Alberto Larghi, MD, PhD
Digestive Endoscopy Unit, Fondazione Policlinico Universitario A. Gemelli IRCCS – Università Cattolica del Sacro Cuore, Largo A. Gemelli 8, 00168, Rome, Italy
Fax: +39-06-30156581
alberto.larghi@policlinicogemelli.it

References

[1] van der Wiel SE, Poley JW, Grubben MJAL et al. The EndoRotor, a novel tool for the endoscopic management of pancreatic necrosis. Endoscopy 2018; 50: E240–E241
[2] Bazarbashi AN, Ge PS, de Moura DTH et al. A novel endoscopic morcellator device to facilitate direct necrosectomy of solid walled-off necrosis. Endoscopy 2019; 51: E396–E397

Bibliography

Endoscopy 2020; 52: E420–E421
DOI 10.1055/a-1151-4694
ISSN 0013-726X
published online 24.4.2020

Georg Thieme Verlag KG, Rüdigerstraße 14, 70469 Stuttgart, Germany