Complication risk despite preventive endoscopic measures in patients undergoing endoscopic mucosal resection of large duodenal adenomas

Authors

Andreas Probst[1], Simone Freund[1], Lukas Neuhaus[1], Alanna Ebigbo[1], Georg Braun[1], Stefan Goelder[1], Tobias Weber[1], Bruno Märkl[2], Matthias Anthuber[3], Helmut Messmann[1]

Institutions

1 Department of Gastroenterology, University Hospital Augsburg, Augsburg, Germany
2 Institute of Pathology, University Hospital Augsburg, Augsburg, Germany
3 Department of General, Visceral and Transplantation Surgery, University Hospital Augsburg, Augsburg, Germany

submitted 9.12.2019
accepted after revision 10.3.2020
published online 14.4.2020

Bibliography
Endoscopy 2020; 52: 847–855
DOI 10.1055/a-1144-2767
ISSN 0013-726X

Georg Thieme Verlag KG, Rüdigerstraße 14, 70469 Stuttgart, Germany

Corresponding author
Andreas Probst, MD, Department of Gastroenterology, University Hospital Augsburg, Stenglinstrasse 2, 86156 Augsburg, Germany
Fax: +49-821-4003331
andreas.probst@uk-augsburg.de

Supplementary material
Online content viewable at:
https://doi.org/10.1055/a-1144-2767

ABSTRACT

Background Endoscopic mucosal resection (EMR) is the standard treatment of ampullary and nonampullary duodenal adenomas. EMR of large (10–29 mm) and giant (≥30 mm) lesions carries a risk of complications such as delayed bleeding and perforation. Prospective data on duodenal EMR are scarce. This study aimed to evaluate the efficacy of endoscopic procedures (clipping and coagulation of visible vessels) to prevent complications after EMR of large and giant lesions.

Methods 110 patients with 118 adenomas (29 ampullary and 89 nonampullary) were included prospectively.

Results 15 lesions were small (12.7%), 68 were large (57.6%), and 35 were giant (29.7%). Endoscopic prevention of delayed complications was performed in 81.4% (n=96) of all lesions and 94.3% (n=33) of giant lesions. Complete resection was achieved in 111 lesions (94.1%). Complications were 22 delayed bleedings (18.6%), 3 intraprocedural perforations (2.5%), 2 delayed perforations (1.7%), and 1 stricture (0.8%). Major complications were associated with lesions size ≥30 mm (28.6% vs. 9.6%; $P=0.02$) and ampullary adenomas (27.6% vs. 11.2%; $P=0.07$). All minor bleeding and 75% of major bleeding episodes were treated endoscopically; 25% of major bleedings needed radiologic embolization. Two fatal courses were observed when delayed perforation occurred after EMR of giant lesions. Residual adenoma was detected in 20.4% at first follow-up.

Conclusions EMR of giant duodenal neoplasia carries a substantial risk of major complications and recurrences. Resection technique and prevention of delayed complications need to be improved. Further measures should be evaluated in randomized studies.

Introduction

Sporadic duodenal adenomas are diagnosed in 0.1%–0.4% of upper gastrointestinal endoscopies [1, 2]. They involve the papilla Vateri (ampullary adenomas) or arise some distance from the papilla (nonampullary adenomas). Duodenal adenomas are precancerous lesions harboring the potential for progression to duodenal adenocarcinoma; resection is therefore recommended [3, 4]. Treatment options include endoscopic resection and surgical techniques. Endoscopic resection appears potentially advantageous but complication risks have to be considered. Endoscopic mucosal resection (EMR) was shown to be effective for nonampullary adenomas, but a risk of delayed bleeding of up to 23.5% has been reported for large lesions [5, 6]. Endoscopic papillectomy for ampullary adenomas has shown a high rate of curative resection but also delayed bleeding rates of up to 16.8% and pancreatitis rates of up to 20% [7, 8].

Published studies mostly describe retrospective series with long inclusion periods [8–10]. Several attempts have been made to reduce the rate of delayed complications, including clipping or coagulation of visible vessels, various techniques for closure of the resection site, and stenting of the pancreatic duct. However, prospective data on duodenal EMR are scarce. The aim of this study was to prospectively evaluate the complication rate of duodenal EMR for nonampullary adenomas and ampullary adenomas, and to assess the efficacy of endoscopic measures that are performed widely in daily clinical practice to prevent complications.

Methods

The study was conducted as a prospective, uncontrolled, observational, open-label, single-center study in a German tertiary referral center (Department of Gastroenterology, University Hospital Augsburg, Germany). The study was approved by the Institutional Review Board of the University Hospital Augsburg, Germany (IRB number BKF-A-2019-11). Patients were included from October 2015 to September 2019.

Inclusion criteria were: endoscopic diagnosis of sporadic duodenal adenoma (ampullary and nonampullary adenomas), age ≥18 years, American Society of Anesthesiologists (ASA) Score I–III, and written informed consent after patients received detailed information about the EMR procedure (procedure, complication risks).

Exclusion criteria were: polyposis syndrome, biopsies showing adenocarcinoma, pretreated lesions, EUS showing intraductal extension exceeding 5 mm into the common bile duct or the pancreatic duct, concomitant malignant disease without curative treatment option.

In circumferential lesions, the additional risk of postinterventional stricture and the alternative of surgical resection were discussed, and the treatment strategy was based on the patient's individual decision.

Outcomes

The primary outcome parameter was the rate of complications (intraprocedural perforation, delayed bleeding, and delayed perforation for all lesions, as well as acute pancreatitis after resection of ampullary adenomas). Secondary outcome parameters were procedural characteristics (en bloc resection, complete resection, procedure time) and recurrences.

Diagnostic work-up

Endoscopy was performed with video gastroscopes (GIF-HQ190; Olympus Medical Systems, Tokyo, Japan) or video duodenoscopes (TJF-Q180V; Olympus Medical Systems). Lesion morphology was described according to the Paris classification [11]. Lesions were classified as ampullary adenomas when the papilla Vateri was involved (ampullary adenomas and laterally spreading tumors involving the papilla [LST-P]). Lesions located some distance from the papilla were classified as nonampullary adenomas. Lesion diameter was estimated by reference to a polypectomy snare of known size. In accordance with the published literature, lesions were classified as small (diameter <10 mm), large (10–29 mm) or giant (≥30 mm) [6]. In ampullary adenomas, endoscopic ultrasound was performed to rule out intraductal extension into the pancreatic duct or the common bile duct. Biopsies were taken when the macroscopic diagnosis of adenoma was doubtful or when malignancy was suspected. However, most of the patients were referred for EMR and adenoma was confirmed by previous biopsies. All patients had undergone colonoscopy during the previous 5 years, which had ruled out polyposis syndrome.

EMR procedure

A video gastroscope (GIF-HQ190 or GIF-1TH190; Olympus) with a transparent hood (D-201-11804 or D-201-12704; Olympus), a video duodenoscope (TJF-Q180V; Olympus) or a combination was used for EMR, depending on the lesion location and accessibility. EMR was performed in a standardized way (▶ **Fig. 1**). When lesion margins were unclear, narrow-band imaging or chromoendoscopy with indigo carmine was used. For nonampullary adenomas and LST-Ps, submucosal injection was performed routinely with a mixture of saline and epinephrine (1:100 000). For papillectomy, submucosal injection was performed at the endoscopist's discretion.

Resection was performed with thin-wire snares with a diameter of 10 mm (POL1-B3-10-23-220-OL; Medwork, Höchstadt, Germany), 15 mm (SD-990-15; Olympus) or 25 mm (SD-990–25; Olympus). A VIO 300 D electrosurgical generator (ERBE Elektromedizin, Tübingen, Germany) was used (Endo Cut Q mode, Effect 2 for cutting, and Forced Coag mode 60 W for coagulation). Insufflation was performed using carbon dioxide. Sedation with midazolam, pethidine, and propofol was administered by a second physician, under continuous cardiorespiratory monitoring. Five procedures (lesions >50 mm) were performed under general anesthesia. EMR was performed by six endoscopists (A.P., A.E., G.B., S.G., T.W., H.M.) who had each

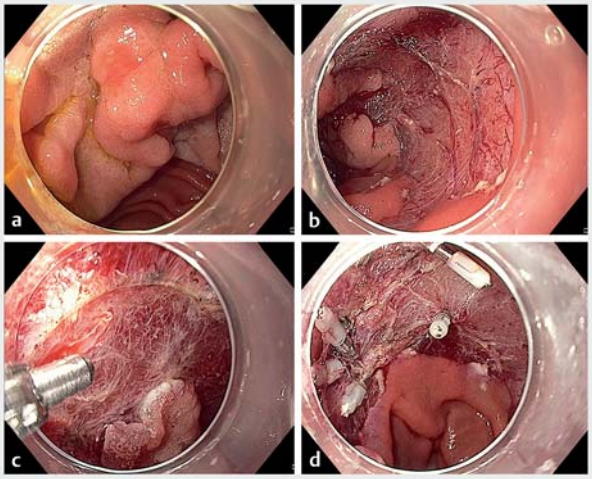

▶ **Fig. 1** Endoscopic mucosal resection procedure for a nonampullary adenoma (diameter 40 mm) in the second part of the duodenum. **a** White-light endoscopy. **b** Piecemeal resection. **c** Coagulation of visible vessels. **d** Clipping of visible vessels.

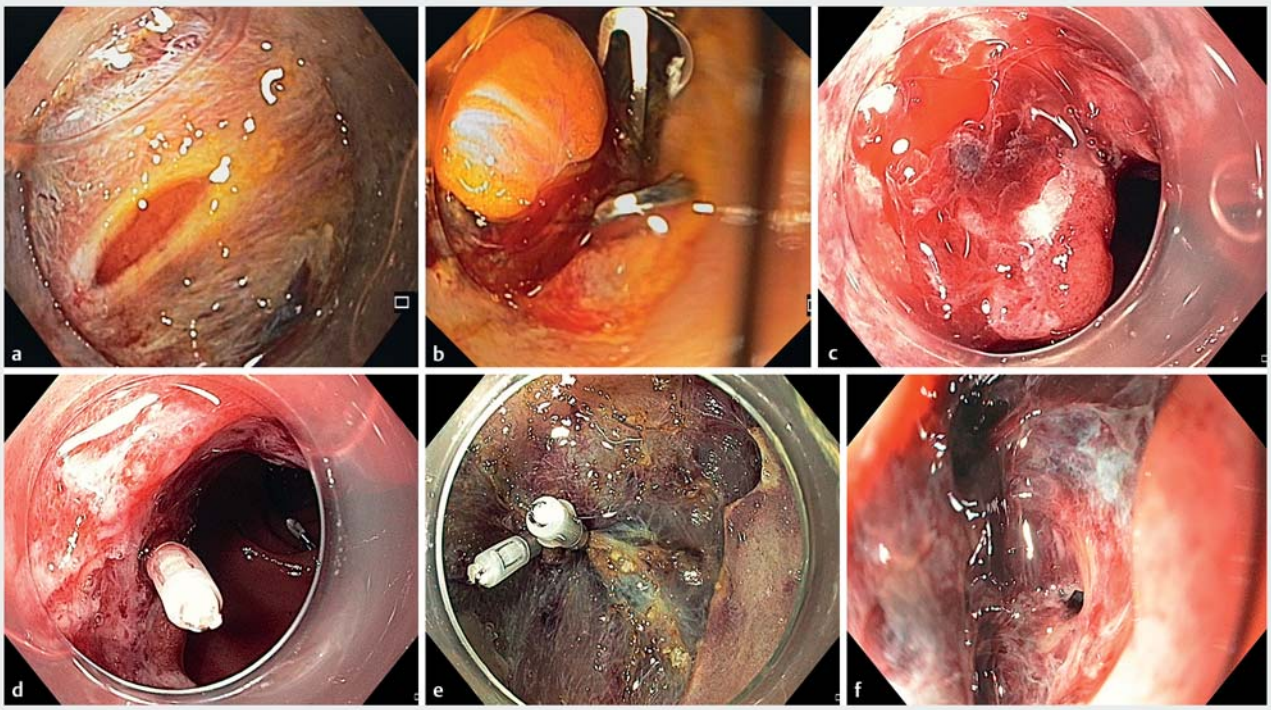

▶ **Fig. 2** Complications after duodenal endoscopic mucosal resection (EMR). **a** Intraprocedural perforation during EMR for a large nonampullary adenoma. **b** Endoscopic closure with an over-the-scope clip. **c** Delayed bleeding 24 hours after EMR of a large nonampullary adenoma. **d** Endoscopic treatment with a hemoclip. **e** Clipping of visible vessels after uncomplicated EMR of a giant nonampullary adenoma. **f** Delayed bleeding and perforation at the same area of the resection ulcer 12 hours later.

performed at least 200 colorectal and at least 20 duodenal EMRs prior to the study.

When the course was uneventful, patients stayed in hospital for 48–120 hours after EMR depending on the endoscopist's decision. Anticoagulants except aspirin were stopped before EMR and were restarted after 5–7 days, depending on the endoscopist's decision [12]. Warfarin was stopped 5 days before EMR until an international normalized ratio of <1.5 was reached; direct anticoagulants (dabigatran, rivaroxaban, edoxaban, apixaban) were stopped 48–72 hours before EMR. Postprocedure, all patients received proton pump inhibitors (pantoprazole 40 mg twice daily for 6 weeks and once daily for a further 6 weeks).

Complications

Complications were defined as bleeding, perforation, pancreatitis, stenosis or death. Intraprocedural bleeding was noted as a complication when it led to premature termination of EMR. Delayed bleeding was defined when hematemesis and/or melena were observed after EMR. Bleeding was classified as major when the hemoglobin drop exceeded 2 g/L [13]. When clinical bleeding signs occurred, endoscopy and endoscopic treatment were performed (▶ **Fig. 2**). Intraprocedural perforation was defined as an obvious defect in the muscularis propria with an endoscopic view into the periduodenal space or the peritoneal cavity. Delayed perforation was diagnosed when postinterventional imaging showed free air or extravasation of contrast medium. Pancreatitis was defined as an elevation of the serum lipase level at least threefold above the upper limit of the normal value in combination with typical clinical symptoms. Pancreatitis was judged severe when the Bedside Index of Severity in Acute Pancreatitis (BISAP) score was >2. Stenosis was considered as a complication when it was symptomatic. When follow-up endoscopy was performed in our department, patients were asked for complications occurring after discharge. Telephone calls were performed for all other patients.

Endoscopic procedures to prevent complications

All visible vessels in the resection ulcer were treated with hemoclips (HX-610-135S or HX-610-090; Olympus) or with coagulation (Coagrasper FD-410 LR, using Soft Coag mode, Effect 5, 40 W; Olympus) at the end of the procedure. Topical agents were applied at the endoscopist's discretion (Hemospray–Cook Medical, Bloomington, Indiana, USA; or Purastat–3-DMatrix Europe, Caluire-et-Cuire, France). Hemospray was used during the whole study period, whereas Purastat was used from January 2017. A scheduled second-look endoscopy on the day after EMR was performed according to the endoscopist's recommendation but not routinely. After endoscopic papillectomy, pancreatic stenting was attempted in all patients and rectal nonsteroidal anti-inflammatory drugs (indomethacin or diclofenac 100 mg) were administered [4, 14].

Follow-up

Endoscopy was scheduled 3 months and 12 months after EMR and annually thereafter for 5 years. When residual or recurrent adenoma was detected, endoscopic re-treatment was performed and 3-month surveillance intervals were recommended until the resection site was recurrence free.

Statistical analysis

Depending on the number of groups, a Mann–Whitney rank sum test or a Kruskal–Wallis one-way analysis of variance on ranks was used to compare numeric values. For the comparison of categorical data, a chi-squared or Fisher's exact test was employed, depending on the expected frequency of the observations. P values of <0.05 were considered statistically significant. Calculations were performed using the software package Sigma Plot 13.0 (Systat Software, San Jose, California, USA).

Results

Patient and lesion characteristics

Over a 4-year period, 119 patients were referred. A total of 110 patients presented with one, 8 patients with two, and 1 patient with three lesions, resulting in a total number of 129 lesions. After exclusion of four lesions with suspected cancer (two ulcerated nonampullary adenomas and two ampullary adenomas with biliary obstruction) and another three lesions with circumferential extension, EMR was performed for 122 lesions in 113 patients. Histopathological analysis did not confirm adenoma in the EMR specimen in four resection specimens (follicular lymphoma in one and non-neoplastic duodenal mucosa in three). The remaining 110 patients with 118 resected lesions were enrolled in the study. Of the 118 lesions, 89 (75.4 %) were nonampullary adenomas and 103 (87.3 %) were large or giant adenomas (▶ **Table 1**, ▶ **Fig. 3**).

▶ **Table 1** Patient and lesion characteristics.

Patient characteristics	**n = 110**
Age, median (range), years	68 (26–95)
Sex, male/female, n	57/53
ASA grade, 1/2/3, n	54/49/7
Antiplatelet medication, n (%)	21 (19.1)
Direct oral anticoagulation, n (%)	12 (10.9)
Warfarin, n (%)	2 (1.8)
Lesion characteristics	**n = 118**
Location, n (%)	
▪ First part	6 (5.1)
▪ Second part	99 (83.9)
▪ Third or fourth part	13 (11.0)
Involvement of the papilla Vateri, n (%)	29 (24.6)
▪ Ampullary adenoma	21 (17.8)
▪ Laterally spreading tumor involving the papilla	8 (6.8)
▪ No involvement	89 (75.4)
Diameter, median (range), mm	
▪ All lesions	15 (4–70)
▪ Involvement of the papilla Vateri	20 (8–60)
▪ No involvement of the papilla Vateri	15 (4–70)
Lesion size by group, n (%)	
▪ < 10 mm	15 (12.7)
▪ 10–29 mm	68 (57.6)
▪ ≥ 30 mm	35 (29.7)
Paris classification, n (%)	
▪ 0-Is	23 (19.5)
▪ 0-IIa	77 (65.3)
▪ 0-IIa + 0-Is	11 (9.3)
▪ 0-IIa + 0-IIc	7 (5.9)
Histology	
▪ LGIEN/HGIEN/invasive adenocarcinoma	94/23/1

ASA, American Society of Anesthesiologists; LGIEN, low-grade intraepithelial neoplasia; HGIEN, high-grade intraepithelial neoplasia.

Procedure characteristics

Complete resection was achieved in 94.1 % (111/118). In six lesions > 50 mm, EMR was scheduled as a two-stage procedure, and one resection was stopped because of a small perforation, which was closed using an over-the-scope clip (OTSC; Ovesco, Tübingen, Germany). Complete resection rates were comparable for small, large, and giant lesions ($P = 0.07$). The en bloc resection rate was 39.0 % for all lesions and decreased significantly in large and giant lesions ($P < 0.001$). Median procedure time was 41 minutes for all lesions. For giant lesions, resection time was 105 minutes, which was significantly longer compared with lesions < 30 mm ($P < 0.001$) (▶ **Table 2**).

Complications and mortality

Complications were analyzed according to lesion size (≥ 30 mm vs. < 30 mm) and the type of adenoma (ampullary vs. nonampullary) (▶ **Table 3**, ▶ **Table 4**). Ampullary adenomas ≥ 30 mm (n = 10) included 7 LST-Ps and 3 ampullary adenomas, whereas ampullary adenomas < 30 mm (n = 19) included 1 LST-P and 18 ampullary adenomas. Endoscopic measures to prevent delayed bleeding were performed in 96/118 (81.4 %) resections (hemoclips only n = 60, coagulation forceps only n = 11, topical agents only n = 3). In 22 lesions a combination was used (clipping + coagulation forceps n = 7, clipping + topical agent n = 5, coagulation forceps + topical agent n = 9, clipping + coagulation forceps + topical agent n = 1).

A total of 25 patients underwent a scheduled second-look endoscopy on the day after EMR. In 10 of them, visible vessels were re-treated with clips or coagulation. In three additional patients, second look had been planned but delayed bleeding

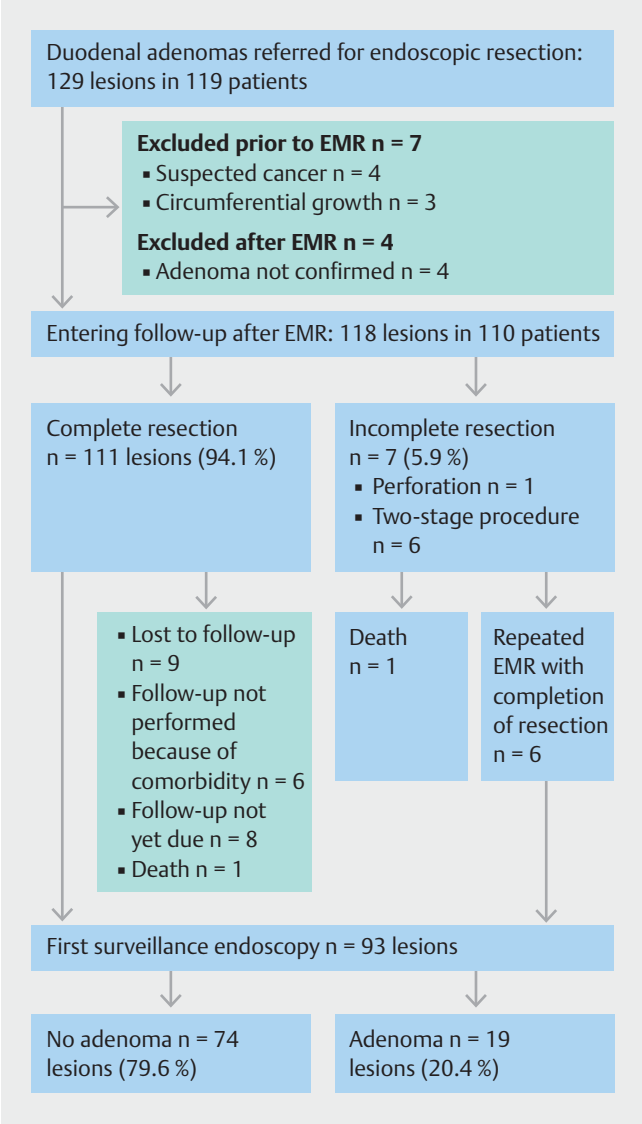

▶ **Fig. 3** Patient flow through study and follow-up.

occurred during the night after EMR. Delayed bleeding was noted in 18.6 % of lesions (22/118). A total of 16 bleedings were major (13.6 %) and 8 of them needed transfusions. Delayed bleeding was significantly associated with lesion diameter and with involvement of the papilla but was not reduced by preventive endoscopic measures (▶ **Table 3**, ▶ **Table 4**; see also **Table 5s** in the online-only supplementary material). Endoscopic treatment with hemoclips or coagulation forceps was successful in all minor bleeding episodes. Four of the 16 lesions with major bleeding needed additional embolization of the gastroduodenal artery. Clinical characteristics of the delayed bleeding cases are summarized in **Table 6s**.

Intraprocedural perforation was noted in three patients and was managed successfully with OTSC. EMR was completed at the same time in two of these patients, and the remaining patient underwent removal of the clip and completion of the resection with EMR 2 months later. Pancreatic duct stenting was possible in 18/29 patients after endoscopic papillectomy (62.1 %). Pancreatitis was diagnosed in 5/29 (17.2 %). The course was mild in all of these patients (BISAP 1 n = 1, BISAP 2 n = 4). Pancreatitis was not associated with stenting of the pancreatic duct (**Table 5s**).

Delayed perforation was seen in a 68-year-old patient who presented with major bleeding 12 hours after EMR of a 60-mm nonampullary adenoma in the third part of the duodenum. Urgent endoscopy showed massive bleeding and a 3-mm perforation in the resection ulcer (▶ **Fig. 2**). Perforation was closed with clips but bleeding could not be stopped. Surgery was discussed but not performed because of severe cardiopulmonary comorbidity. Radiologic embolization of the gastroduodenal artery was performed. However, progressive multiorgan failure developed and the patient died 2 days later.

Duodenal stricture was observed 3 weeks after circumferential EMR and endoscopic papillectomy of a 60-mm LST-P in a 72-year-old woman. Over a 4-week period, six sessions of endoscopic balloon dilation were performed. During the final dilation, perforation in the second part of the duodenum was seen. Computed tomography (CT) scan showed a small extravasation of contrast medium. Abdominal examination was unremarkable and a conservative approach with antibiotics and nil-by-mouth was started after interdisciplinary discussion. CT scan the following day showed progressive periduodenal fluid collections and the patient underwent surgery. However, she died because of intractable multiorgan failure 2 days later.

In summary, complications were noted in 22.9 % and major complications occurred in 15.3 % of all lesions. Complication rates differed significantly between ampullary and nonampullary adenomas ($P = 0.003$). Major complications increased significantly with lesion diameter ($P = 0.02$) (▶ **Table 2**, ▶ **Table 4**).

Two out of 118 resections showed a fatal outcome, resulting in a procedure-related mortality of 1.7 %.

We performed a multivariate analysis with any complication as a composite end point. Patient characteristics (sex, age, ASA score), lesion characteristics (ampullary vs. nonampullary, diameter), and procedure characteristics (en bloc vs. piecemeal, procedure time) were analyzed. Lesion diameter ($P = 0.002$) and piecemeal resection ($P < 0.001$) were shown to be statistically predictive. A further regression analysis confirmed these parameters as being independent ($P = 0.29$).

Follow-up and recurrences

First follow-up endoscopy was performed for 93/118 lesions (78.8 %). Residual or recurrent adenoma was diagnosed in 19/93 (20.4 %) and underwent endoscopic re-treatment (▶ **Fig. 3**). At first follow-up, recurrence rate for ampullary and nonampullary adenomas were 37.5 % (9/24) and 14.5 % (10/69), respectively ($P = 0.04$).

Discussion

EMR of duodenal adenomas has been shown to be effective in several studies over the past decade [5–10, 15–17]. Substantial complication rates have been described especially after resection of large and giant lesions. Fanning et al. reported a 26.3 % rate of major complications after EMR of giant nonampullary

▶ **Table 2** Procedure characteristics.

Procedure characteristics	Lesions size, n (%)				
	All lesions (n = 118)	Small < 10 mm (n = 15)	Large 10–29 mm (n = 68)	Giant ≥ 30 mm (n = 35)	*P*
Resection, n (%)					
▪ En bloc	46 (39.0)	11 (73.3)	33 (48.5)	2 (5.7)	< 0.001[1]
▪ Piecemeal	72 (61.0)	4 (26.7)	35 (51.5)	33 (94.3)	
▪ Complete resection (macroscopic)	111 (94.1)	15 (100)	66 (97.1)	30 (85.7)	0.07
Procedure time, median (range), minutes	41 (9–207)	30 (18–70)	35 (9–96)	105 (35–207)	< 0.001[1]
Major complications[2]	18 (15.3)	0	8 (11.8)	10 (28.6)	0.02[1]

[1] Significant difference between lesions –30 mm and < 30 mm.
[2] Major bleeding, perforation or pancreatitis (Bedside Index of Severity in Acute Pancreatitis score > 2).

▶ **Table 3** Complications and preventive measures.

Lesion type	All lesions (n = 118)	Nonampullary adenomas		Ampullary adenomas[1]		*P*
		< 30 mm (n = 64)	≥ 30 mm (n = 25)	< 30 mm (n = 19)	≥ 30 mm (n = 10)	
Preventive measures, n (%)						
Prevention of delayed bleeding						
▪ Hemoclips	73 (61.9)	53 (82.8)	10 (40.0)	5 (26.3)	5 (50.0)	< 0.001
▪ Number of clips, median (range)	5 (1–17)	5 (1–17)	5 (1–10)	1 (1–4)	8 (1–15)	
▪ Coagulation forceps	28 (23.7)	3 (4.7)	12 (48.0)	7 (36.8)	6 (60.0)	< 0.001
▪ Topical agent[2]	18 (15.3)	1 (1.6)	11 (44.0)	3 (15.8)	6 (60.0)	< 0.001
▪ Combination	22 (18.6)	3 (4.7)	10 (40.0)	10 (52.6)	6 (60.0)	< 0.001
▪ None	22 (18.6)	10 (15.6)	2 (8.0)	2 (10.5)	0	< 0.001
Second-look endoscopy	25 (21.2)	3 (4.7)	13 (52.0)	2 (10.5)	7 (70.0)	< 0.001
▪ Look only (Forrest IIc / III)	15	3	6	2	4	
▪ Intervention (Forrest Ib / IIa)	10	0	7	0	3	0.22
Prevention of pancreatico-biliary complications						
▪ Pancreatic stent	n.a.	n.a.	n.a.	14 (73.7)	4 (40.0)	0.11
▪ Biliary stent	n.a.	n.a.	n.a.	11 (57.9)	3 (30.0)	> 0.99
Delayed bleeding, n (%)	22 (18.6)	2 (3.1)	10 (40.0)	6 (31.6)	4 (40.0)	< 0.001
Major	16 (13.6)	1 (1.6)	7 (28.0)	6 (31.6)	2 (20.0)	
▪ Transfusion required	8 (6.8)	0	4 (16.0)	3 (15.8)	1 (10.0)	0.77
Minor	6 (5.1)	1 (1.6)	3 (12.0)	0	2 (20.0)	0.28
Perforation	5 (4.2)	1 (1.6)	2 (8.0)	0	2 (20.0)	0.02
Intraprocedural	3 (2.5)	1 (1.6)	1 (4.0)	0	1 (10.0)	
Delayed	2 (1.7)	0	1 (4.0)	0	1 (10.0)	0.10
Pancreatitis	n.a.	n.a.	n.a.	3 (15.8)	2 (20.0)	> 0.99
Duodenal stricture	1 (0.8)	0	0	0	1 (10.0)	0.01
Mortality	2 (1.7)	0	1 (4.0)	0	1 (10.0)	0.10

[1] Ampullary adenomas and laterally spreading tumors involving the papilla.
[2] Hemospray (Cook Medical, Bloomington, Indiana, USA) in 12 cases and Purastat (3-DMatrix Europe, Caluire-et-Cuire, France) in 6.

▶ **Table 4** Complications after endoscopic mucosal resection of ampullary and nonampullary adenomas.

Lesions type	All lesions (n = 118)	Nonampullary (n = 89)	Ampullary[1] (n = 29)	*P*
Delayed bleeding, n (%)	22 (18.6)	12 (13.5)	10 (34.5)	0.03
Major	16 (13.6)	8 (9.0)	8 (27.6)	0.03
▪ Transfusion required	8 (6.8)	4 (4.5)	4 (13.8)	0.19
Minor	6 (5.1)	4 (4.5)	2 (6.9)	0.98
Perforation	5 (4.2)	3 (3.4)	2 (6.9)	0.77
Intraprocedural	3 (2.5)	2 (2.2	1 (3.4)	0.75
Delayed	2 (1.7)	1 (1.1)	1 (3.4)	0.99
Pancreatitis	n.a.	n.a.	5 (17.2)	
Duodenal stricture	1 (0.8)	0	1 (3.4)	0.55
Any complication	27 (22.9)	14 (15.7)	13 (44.8)	0.003
Major complication[2]	18 (15.3)	10 (11.2)	8 (27.6)	0.07
Mortality	2 (1.7)	1 (1.1)	1 (3.4)	0.99

[1] Ampullary adenomas and laterally spreading tumors involving the papilla.
[2] Major bleeding, perforation or severe pancreatitis (Bedside Index of Severity in Acute Pancreatitis score > 2).

adenomas; the most frequent complication was delayed bleeding [16]. Another study reported delayed bleeding in 25 % when LST-Ps with a median diameter of 35 mm were resected [6]. Lepilliez et al. described a potential decrease in delayed bleeding in a retrospective and nonrandomized study when clipping and argon plasma coagulation were used after EMR; the delayed bleeding rate was 22 % in lesions without preventive measures compared with 0 % in lesions that were treated with clips or argon plasma coagulation [5].

Most of the studies on duodenal EMR are retrospective. Endoscopic measures to prevent delayed complications (especially delayed bleeding) are used widely in daily clinical practice but prospective data regarding their efficacy are lacking. Therefore, we initiated a prospective study and included all ampullary and nonampullary adenomas referred for EMR in a German tertiary referral center. Systematic endoscopic measures for bleeding prevention were performed including clipping or coagulation of visible vessels, with the additional option of applying topical agents (i. e. Hemospray or Purastat). Lesions were predominantly large or giant adenomas. EMR was highly effective regarding complete resection (94.1 %). As expected, en bloc resection decreased significantly with increasing lesion diameter. For lesions ≥ 30 mm, en bloc resection was possible in two polypoid ampullary adenomas but was impossible for nonampullary adenomas. Surprisingly, even in small lesions < 10 mm, EMR had to be performed piecemeal in 26.3 %. Retrospective series have reported R0 resections rates of 68 %–82.2 % in lesions with a mean diameter of 10 mm [10, 18].

Endoscopic measures to prevent delayed bleeding were performed in 81.4 % after EMR. In giant lesions, the rate was 94.3 % and only two lesions were not treated prophylactically. Clipping or coagulation of visible vessels was performed in 87.6 % of nonampullary adenomas and in 79.3 % of ampullary adenomas. In giant lesions clipping of all visible vessels was more difficult or even impossible compared with smaller resection ulcers. This might explain why less clipping and more coagulation was performed in giant lesions. In smaller resection ulcers, clipping was predominantly used. Despite these preventive measures, we observed delayed bleeding in 18.6 % of all resections, with a significant increase in giant lesions. For giant lesions, the total rate of delayed bleeding and the rate of major bleeding was 40.0 % and 25.7 %, respectively. Delayed bleeding after EMR of lesions < 30 mm could be controlled endoscopically in all cases, whereas 25.0 % of delayed bleeding in giant lesions required additional radiological embolization of the gastroduodenal artery. The delayed bleeding rate is similar to or even higher than that reported in the retrospective studies mentioned above [6, 16]. As the resection procedure was comparable, the preventive measures performed in our study were obviously insufficient to reduce delayed bleeding.

Delayed perforation is another hazardous and potentially fatal complication occurring in up to 1 % after duodenal EMR [6, 19]. The suspected reason for delayed perforation is intraprocedural coagulation of the muscle layer. A case report has described another potential mechanism whereby delayed perforation was caused by an endoscopic clip in the resection ulcer [20]. In our study, we observed two delayed perforations with fatal outcomes after EMR of giant duodenal adenomas.

The risk of residual or recurrent neoplasia is a known disadvantage after piecemeal resection of gastrointestinal neoplasia. In our study 20.4 % of lesions showed residual adenoma at the first follow-up endoscopy. The recurrence rate is similar to published data, which report rates ranging from 14.4 % up to 29 % [6, 8, 21, 22]. Over recent years, endoscopic submucosal dissection (ESD) has gained acceptance in the treatment of esophageal, gastric, and colorectal neoplasia; however, the role of

ESD for duodenal neoplasia remains controversial. A high perforation rate has been reported in initial studies. A small study from Korea described perforations in 5/14 patients, two of whom required surgery [23]. Hoteya et al. reported a 39 % rate of intraprocedural perforations after ESD in 41 large nonampullary adenomas (mean diameter 26 mm) [24]. Three patients required conversion to surgery. The rate of delayed bleeding was 18.4 %, which is similar to the rate for EMR. A large retrospective study on 146 EMRs (mean lesions diameter 9.8 mm) and 174 ESDs (mean lesions diameter 27.4 mm) demonstrated similar R0 resection rates (82.2 % vs. 85.1 %), but a significant increased perforation rate after ESD (15.5 % vs. 0.68 %) [18]. Data on duodenal ESD are restricted to Asian expert centers and its role for Western endoscopists is not yet defined.

New techniques for the prevention of delayed complications after duodenal endoscopic resection have been introduced recently. Covering the resection ulcer with polyglycolic acid sheets in combination with fibrin glue was reported to prevent delayed perforation [25]. Asian authors have proposed different strategies to close the resection ulcer especially after ESD. Analysis of delayed bleeding after duodenal ESD identified closure of the resection ulcer as an independent risk factor [26]. Kato et al. reported on 173 ESDs and confirmed the efficacy of endoscopic closure using different techniques (clips, endoloop/clips technique, string clip suturing technique) [27]. The rate of delayed adverse events was significantly reduced to 1.7 % after complete closure of the defect compared with 25 % after incomplete closure, and 15.6 % without closure. Another Japanese group described the use of OTSCs after duodenal ESD, and reported delayed bleeding in 6.4 %, delayed perforation in 2.4 %, and conversion to surgery in 4 % [28]. Underwater EMR and additional closure of the resection ulcer with clips or line-assisted clipping showed promising results without delayed complications in a recent small study in nonampullary adenomas; however, included lesions were small with a mean diameter of 12 mm [29]. Laparoscopic-endoscopic cooperative surgery has also been reported as another treatment option to close the resection site [30].

Endoscopic or laparoscopic closure techniques have shown promising results, but data are widely restricted to duodenal ESD. It appears obvious to transfer these techniques to EMR but a 20 % risk of residual adenoma has to be taken into account. Line-assisted closure has been reported for wide-field EMR but long-term follow-up and larger series are lacking [31]. Further limitations of the closure techniques are the reduced success rate in very large defects and the impossibility to close defects after endoscopic papillectomy. Further data are needed for endoscopic closure after duodenal EMR.

EMR is offered as a minimally invasive procedure with less morbidity and mortality compared with surgical approaches. Klein et al. described a shorter hospital stay and lower costs for endoscopic resection techniques when comparing 102 EMRs of large adenomas (ampullary and nonampullary) with alternative hypothetical surgical resections [32].

Traditionally, pancreaticoduodenectomy, with its substantial complication risk, was the surgical alternative treatment option. Over past decades, less invasive surgical techniques have been introduced, such as local ampullary resections for ampullary adenomas or pancreas-preserving partial duodenectomies (PPPD) for nonampullary adenomas [33]. A retrospective comparative study included 91 EMRs and 30 PPPDs [22]. En bloc resection was achieved in 53 % and 100 %, respectively. Early complications including five intraprocedural perforations were observed after EMR, while the surgical group showed no early but eight delayed complications, including gastroparesis, pulmonary embolism, and pancreatic fistula. Recurrence rates were 32 % after EMR and 0 % after PPPD [22].

Our study demonstrates substantial complication risks after EMR of giant duodenal adenomas despite intensive preventive measures. To our knowledge, this study is one of the largest prospective series on duodenal EMR. The data represent the efficacy and the complication risk of duodenal EMR in daily clinical practice in a tertiary referral center. Limitations of the study are the nonrandomized design and no control group, the single-center setting, and the inclusion of both ampullary and nonampullary adenomas. Another limitation is that preventive measures after EMR and recommendations on second-look endoscopy were not fully standardized.

In conclusion, EMR shows a high success rate but also a substantial complication risk especially in large and giant lesions and in lesions involving the papilla. Measures to prevent delayed major complications need to be improved urgently. ESD with closure of the resection ulcer seems to be promising in expert hands. However, widespread use outside Asia cannot be expected in the near future. The treatment of high-risk duodenal adenomas is challenging and requires endoscopic, surgical, and radiological expertise in tertiary referral centers. Treatment decisions should follow an interdisciplinary approach, and treatment options (endoscopic vs. surgical) should be discussed with the patient, including efficacy and complication risk but also the risk of recurrence.

Competing interests

The authors declare that they have no conflicts of interest.

References

[1] Jepsen JM, Persson M, Jakobsen NO et al. Prospective study of prevalence and endoscopic and histopathologic characteristics of duodenal polyps in patients submitted to upper endoscopy. Scand J Gastroenterol 1994; 29: 483–487

[2] Alkhatib AA. Sporadic nonampullary tubular adenoma of the duodenum: Prevalence and patients' characteristics. Turk J Gastroenterol 2019; 30: 112–113

[3] Okada K, Fujisaki J, Kasuga A et al. Sporadic nonampullary duodenal adenoma in the natural history of duodenal cancer: a study of follow-up surveillance. Am J Gastroenterol 2011; 106: 357–364

[4] Chathadi KV, Khashab MA, Acosta RD et al. ASGE Standards of Practice Committee. The role of endoscopy in ampullary and duodenal neoplasms. Gastrointest Endosc 2015; 82: 773–781

[5] Lepilliez V, Chemaly M, Ponchon T et al. Endoscopic resection of sporadic duodenal adenomas: an efficient technique with a substantial risk of delayed bleeding. Endoscopy 2008; 40: 806–810

[6] Klein A, Nayyar D, Bahin FF et al. Endoscopic mucosal resection of large and giant lateral spreading lesions of the duodenum: success, adverse events, and long-term-outcomes. Gastrointest Endosc 2016; 84: 688–696

[7] Napoleon B, Gincul R, Ponchon T et al. Endoscopic papillectomy for early ampullary tumors: long-term-results from a large multicenter prospective study. Endoscopy 2014; 46: 127–134

[8] Klein A, Qi Z, Bahin FF et al. Outcomes after endoscopic resection of large laterally spreading lesions of the papilla and conventional ampullary adenomas are equivalent. Endoscopy 2018; 50: 972–983

[9] Tomizawa Y, Ginsberg GG. Clinical outcome of EMR of sporadic, non-ampullary, duodenal adenomas: a 10-year retrospective. Gastrointest Endosc 2018; 87: 1270–1278

[10] Hara Y, Goda K, Dobashi A et al. Short and long-term outcomes of endoscopically treated superficial non-ampullary duodenal epithelial tumors. World J Gastroenterol 2019; 25: 707–718

[11] Endoscopic Classification Review Group. Update on the Paris classification of superficial neoplastic lesions in the digestive tract. Endoscopy 2005; 37: 570–578

[12] Veitch AM, Vanbiervliet B, Gershlick AH et al. Endoscopy in patients on antiplatelet or anticoagulant therapy, including direct oral anticoagulants: British Society of Gastroenterology (BSG) and European Society of Gastrointestinal Endoscopy (ESGE) guidelines. Endoscopy 2016; 48: 1–18

[13] Cotton PB, Eisen GM, Aabakken L et al. A lexicon for endoscopic adverse events: report of an ASGE workshop. Gastrointest Endosc 2010; 71: 446–454

[14] Kandler J, Neuhaus H. How to approach a patient with ampullary lesion. Gastroenterology 2018; 155: 1670–1678

[15] Eswaran SL, Sanders M, Bernadino KP et al. Success and complications of endoscopic removal of giant duodenal and ampullary polyps: a comparative series. Gastrointest Endosc 2006; 64: 925–932

[16] Fanning SB, Bourke MJ, Williams SJ et al. Giant laterally spreading tumors of the duodenum: endoscopic resection outcomes, limitations and caveats. Gastrointest Endosc 2012; 75: 805–812

[17] Aschmoneit-Messer I, Richl J, Pohl J et al. Prospective study of acute complication rates and associated risk factors in endoscopic therapy for duodenal adenomas. Surg Endosc 2015; 29: 1823–1830

[18] Yahagi N, Kato M, Ochiai Y et al. Outcomes of endoscopic resection for superficial duodenal epithelial neoplasia. Gastrointest Endosc 2018; 88: 676–682

[19] Inoue T, Uedo N, Yamashina T et al. Delayed perforation: a hazardous complication of endoscopic resection for non-ampullary duodenal neoplasm. Dig Endosc 2014; 26: 220–227

[20] Von Wulffen M, Huelsen A, O'Rourke T et al. Delayed perforation caused by an endoscopic clip following uncomplicated endoscopic resection of a large sporadic nonampullary duodenal adenoma. Endoscopy 2016; 48: E211–E212

[21] Basford PJ, George R, Nixon E et al. Endoscopic resection of sporadic duodenal adenomas: comparison of endoscopic mucosal resection (EMR) with hybrid endoscopic submucosal dissection (ESD) techniques and the risks of late delayed bleeding. Surg Endosc 2014; 28: 1594–1600

[22] Bartel MJ, Puri R, Brahmbhatt B et al. Endoscopic and surgical management of nonampullary duodenal neoplasms. Surg Endosc 2018; 32: 2859–2869

[23] Jung JH, Choi KD, Ahn JY et al. Endoscopic submucosal dissection for sessile, nonampullary duodenal adenomas. Endoscopy 2013; 45: 133–135

[24] Hoteya S, Yahagi N, Iizuka T et al. Endoscopic submucosal dissection for nonampullary large superficial adenocarcinoma/adenoma of the duodenum: feasibility and long-term outcomes. Endosc Int Open 2013; 1: E2–E7

[25] Doyama H, Tominaga K, Yoshida N et al. Endoscopic tissue shielding with polyglycolic acid sheets, fibrin glue and clips to prevent delayed perforation after duodenal endoscopic resection. Dig Endosc 2014; 26: (Suppl. 02): 41–45

[26] Hoteya S, Kasie M, Iizuka T et al. Delayed bleeding after endsocopic submucosal dissection for non-ampullary superficial duodenal neoplasias might be prevented by prophylactic endoscopic closure: analysis of risk factors. Dig Endosc 2015; 27: 323–330

[27] Kato M, Ochiai Y, Fukuhara S et al. Clinical impact of closure of the mucosal defect after duodenal endoscopic submucosal dissection. Gastrointest Endosc 2019; 89: 87–93

[28] Tashima T, Ohata K, Sakai E et al. Efficacy of an over-the-scope clip for preventing adverse events after duodenal endoscopic submucosal dissection: a prospective interventional study. Endoscopy 2018; 50: 487–496

[29] Yamasaki Y, Uedo N, Takeuchi Y et al. Underwater endoscopic mucosal resection for superficial nonampullary duodenal adenomas. Endosocpy 2018; 50: 154–158

[30] Irino T, Nunobe S, Hiki N et al. Laparoscopic-endoscopic cooperative surgery for duodenal tumors: a unique procedure that helps ensure the safety of endoscopic submucosal dissection. Endoscopy 2015; 47: 349–351

[31] Nakahira H, Takeuchi Y, Kanesaka T et al. Wide-field underwater EMR followed by line-assisted complete closure for a large duodenal adenoma. Video GIE 2019; 4: 479–481

[32] Klein A, Ahlenstiel G, Tate DJ et al. Endoscopic resection of large duodenal and papillary lateral spreading lesions is clinically and economically advantageous compared with surgery. Endoscopy 2017; 49: 659–667

[33] Asbun HJ. Management of duodenal polyps in the era of maximal interventional endoscopy and minimally invasive surgery. Gastrointest Endosc 2016; 84: 697–699