

## CT morphology of COVID-19: Case report and review of literature

### Introduction

In December 2019 a clustering of pneumonia was reported for the first time in Wuhan, Hubei, China [1]. A coronavirus was identified as the pathogen, which has since been given the name Severe Acute Respiratory Syndrome Coronavirus 2 (SARS-CoV-2). The disease caused by SARS-CoV-2 is called COVID-19 which has since spread worldwide. In Germany the numbers continue to increase, and the level of COVID-19 lethality in Europe cannot yet be accurately estimated. However, lethality appears to be particularly higher in older patients compared to seasonal influenza [2, 3]. Based on experience in China, computed tomography (CT) is very helpful in COVID-19 in that it can produce an image that is suggestive for diagnosis, and the sensitivity of CT is in some cases higher than that of the current gold standard, real-time polymerase chain reaction (RT-PCR) [4, 5].

The aim of this article is to present a case with COVID-19 pneumonia and to provide an overview of the existing radiological literature on COVID-19.

### Case Report

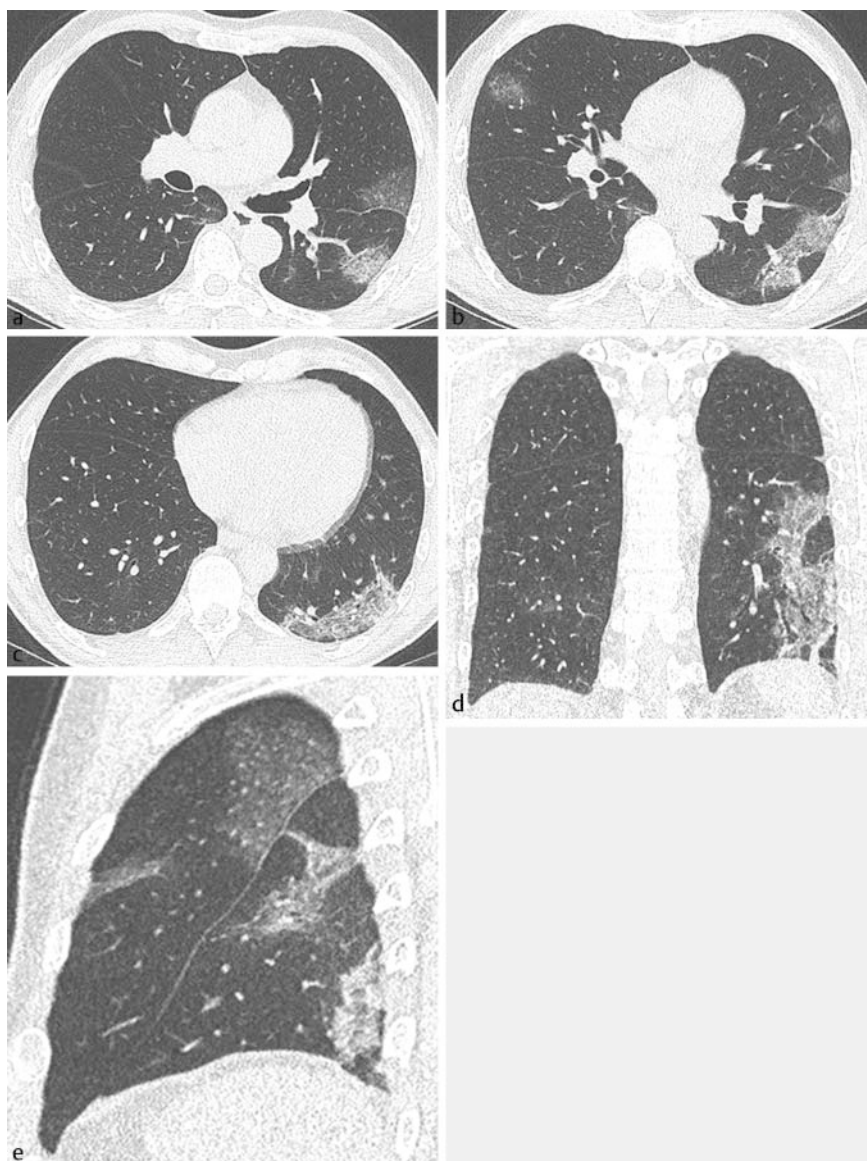
The inpatient admission of a 59-year-old male was carried out with outpatient-confirmed SARS-CoV-2 infection with positive RT-PCR from a throat swab and relevant clinical symptoms. The patient had previously visited South Tirol. Six days prior to hospital admission, the patient exhibited initial symptoms in the form of chills and fever. He had no pre-existing conditions.

At the time of admission there was a high fever of 40.0 °C and conspicuous tachypnea with a respiratory rate of 28/min with sufficient oxygenation (ambient air saturation 95 %). Clinically, there was also a severe general feeling of malaise with obvious fatigue. Laboratory results showed leukopenia with  $3.8 \times 10^9/l$ , lymphopenia with  $0.96 \times 10^9/l$  (25 %), an only slightly increased CRP with 14.7 mg/l and a low procalcitonin of 0.11 ng/ml. D-dimer as risk factor for instability was

not increased at 370 µg. Interleukin-6 as inflammatory parameter was slightly elevated at 36.4 pg/ml, LDH was 330 U/l and creatinine kinase was 412 U/l. Albumin was initially within the normal range at 4.0 g/dl.

The native thin-slice volume CT of the thorax performed on the day of admission (► Fig. 1) showed multifocal, bilateral ground glass opacities, partly with over-

lapping reticulations appearing as crazy paving. Consolidation was present, but much less pronounced than the ground glass opacities, which were somewhat round and geographically arranged. It was noticeable that they were sometimes sharply delineated from the neighboring healthy lung parenchyma. A positive air bronchogram was evident within the changes. All changes were in the periphery



► **Fig. 1** Non-contrast enhanced thin slice Volume-CT at day of admission: MPRs in axial **a–c**, coronal **d** and sagittal **e** orientation. Bilaterally multiple patchy ground glass opacities and crazy paving are seen. Some of the opacities are round and some geographic shaped. Partially, the lesions are sharply demarcated against the surrounding healthy lung. The left lower lobe and the periphery of the lungs are predominantly involved. Images courtesy PD Dr. med W. Kurre.

of the lungs, in the craniocaudal plane the base of the lungs, and here the left lower lobe, were most affected.

Due to the presence of a risk constellation with clinically significant compromise, high fever, respiratory impairment and CT-morphologically pronounced parenchymal alterations, a decision was quickly made in favor of a therapy including antivirals (Lopinavir-Ritonavir) and a broadly-calculated antibiotic therapy. With persistent fever up to 39.6 °C and respiratory deterioration with increasing oxygen demand, a follow-up CT of the thorax was performed on day 6 after admission (► Fig. 2). The images showed significantly increasing densities, whereby in contrast to the initial CT, consolidations now dominated the image. Still, the periphery and the base of the lungs were most affected. On day 7 a nasal high flow therapy was initiated for severe respiratory insufficiency. By day 16 the patient had improved clinically and was ready for discharge. No more follow-up CT examination was performed.

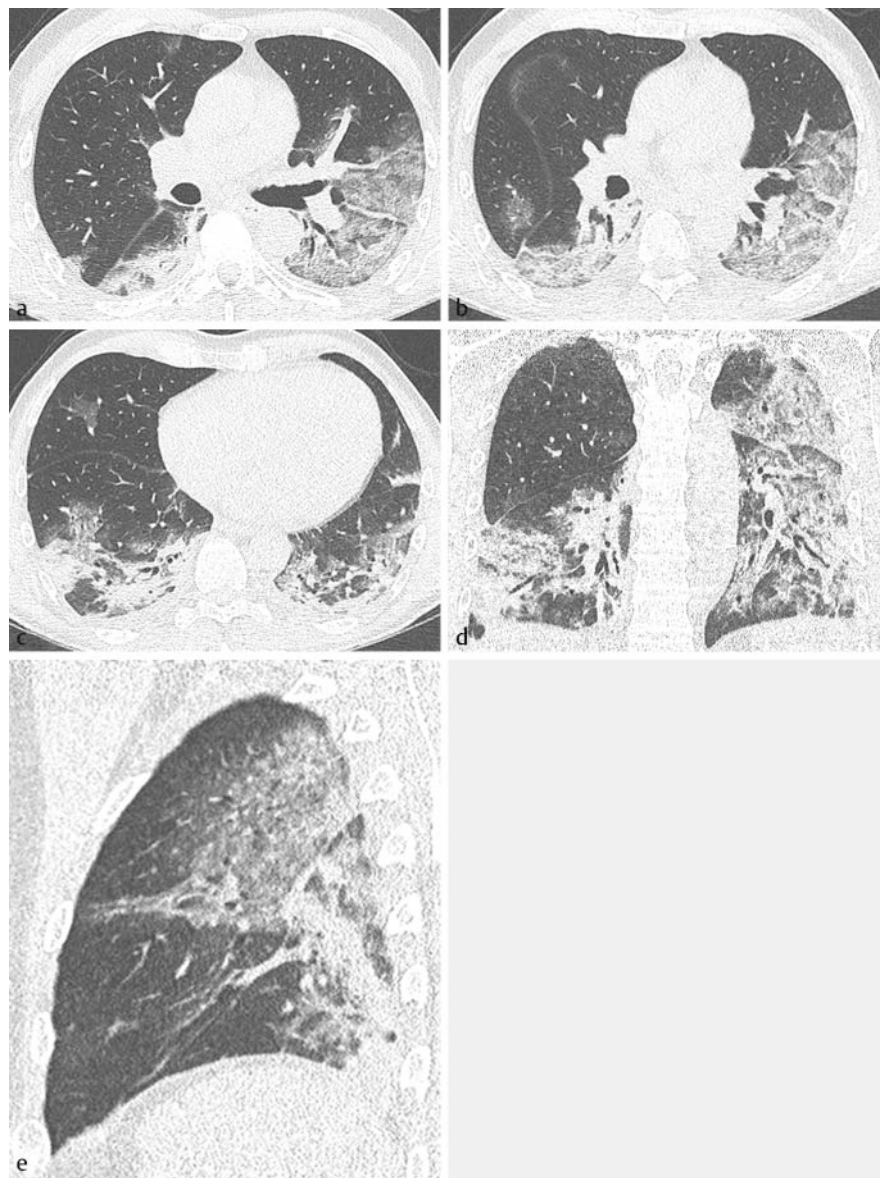
## Materials and Methods

A literature search was conducted in the “pubmed” database with the keywords “COVID-19 OR SARS-CoV 2”. As of March 10, 2020, 637 articles were identified. Based on these articles, all studies were identified that included at least 10 patients with proven COVID-19 who had received a chest CT and whose characteristics had been systematically evaluated. Fourteen studies met the inclusion criteria [5–18], describing a total of 1966 patients. In addition to the data, images of all studies were reviewed.

## Results

### HRCT signs of SARS CoV-2 pneumonia

The most common manifestation of pneumonia caused by SARS-CoV-2 is ground glass opacities, followed by a mixed picture of ground glass opacities and consolidation, followed by consolidation alone (► Table 1). Nodules are rare, tree-in-bud was not mentioned in any study. Crazy paving was seen, but was present in highly variable fre-



► Fig. 2 Non-contrast enhanced thin slice Volume-CT 5 days later: MPRs in axial a–c), coronal d and sagittal e orientation. The opacities have markedly increased in size. Now, consolidation is the predominant feature. Still mainly the lower lobes and the periphery of the lungs are involved. Images courtesy PD Dr. med W. Kurre.

quency. However, the phrasing in some studies suggested that crazy paving may have been present (“reticulations”), but this was not explicitly described as such. These cases were not included in the overview table. Two studies reported that the lesions were round (in 33 % and 54 % of cases, respectively). Three studies investigated vessel width and reported dilatation of vessels within the opacifications (82 %, 71 % and 59 % of cases). Reversed halo was observed in approx. 5 % of patients. Pleural effusions or lymphadenopathy occurred in only a limited number of patients. cavit-

tions were not observed. In most of the studies, lesion boundary was not an evaluation criterion, therefore the published image material was reviewed by an author (OWH). Ground glass opacities (with or without crazy paving) and consolidation were often at least partially sharply delineated and geographically configured.

### Distribution of parenchymal changes

The above described CT signs were found in the axial plane predominantly in the

► **Table 1** Overview of CT-morphology of SARS-CoV 2 pneumonia (according to all studies including more than 10 patients, as of March 10<sup>th</sup> 2020).

	Bernheim [6]	Pan (early stage: day 0–4) [7]	Chung [8]	Ng [9]	Song [10]	Ai [5]	Shi [11]	Li [13]	Li [12]	Chen [14]	Huang [15]	Zhao [16]	Bai [17]	Xiong [18]
<b>epidemiology</b>														
number of patients	121	21	21	21	51	1014	81	83	51	99	41	101	219	42
male	61	6	13	13	25	467	42	44	28	67	30	56	119	25
middle age	45	40	51	56	49	51	50	46	58	56	49	44	45	50
<b>CT signs</b>														
CT normal [%]	22	17		10		12	0		4		0			
milk glass [%]	34	75	57	86	77	46	65	98	35			86	91	
consolidation [%]	2	42	0	62	55	50	17	64	6			44	69	55
milk glass and consolidation [%]	41		29		59				55			64		
crazy paving [%]	5	25	19		75		10	36	71				5	
vasodilation in solidifications [%]	54		33						82			71	59	
round configuration [%]	2								4					
reversed halo [%]	1		0	0	8		5	8	2			14	4	12
pleural effusion [%]	0		0	0	6		6	8	0				3	29
lymphadenopathy [%]														
<b>distribution of CT signs</b>														
emphasized periphery [%]	52	54	33	86	86		54					87	80	29
right upper lobe [%]	44		67	67	84		19	65				6		
left upper lobe [%]	48		67	76			20	86						
middle lobe [%]	41		57	48	59		10	74						
right lower lobe [%]	65		76	76	90		27	94				55		
left lower lobe [%]	63	0	67	81			24	96						
unilateral [%]		42			14		21	5		25	2	10	19	
bilateral [%]	60	42	76		86		79	95		75	98	82	75	

periphery of the lung. The lower lobes were mainly affected in the craniocaudal plane. The vast majority of patients showed bilateral changes.

### Temporal changes of CT morphology

Follow-up CTs were performed in some studies, allowing an assessment of the course of parenchymal changes [6, 7, 9–11, 18]. The authors unanimously reported an increasing expansion of the lesions with, in particular, increased consolidation and crazy paving. The maximum finding was seen approximately on day 10 after the onset of symptoms. Afterwards there was a decrease of the parenchymal changes, but they were not completely regressive in one work describing up to day 26 after the onset of symptoms.

### Correlation between CT findings and clinical symptoms

The extent of parenchymal changes correlated with the severity of the clinical symptoms [7, 13, 15, 16].

### Thoracic CT versus RT-PCR

Four studies compared the sensitivities of CT and RT-PCR [4–6, 19].

Fang et al. report an initial RT-PCR sensitivity of 71% (36/51) and sensitivity of initial CT (“CT compatible with viral pneumonia”) of 98% (50/51); the interval between RT-PCR and CT was  $\leq 3$  days. Of patients with abnormal CT, 72% (36/50) exhibited “typical” CT morphology (lung periphery predominantly involved, ground glass, consolidation) [4]. Bernheim et al. report on 121 patients, 120 of whom had a positive RT-PCR, the interval between RT-PCR and CT is not mentioned in the study [6]. On day 0–2 after onset of symptoms, 56% of patients exhibited inconspicuous CT findings, 9% on day 3–5 and 4% on day 6–12. Ai et al. report that 60–93% of patients had an abnormal CT before the initial positive PCR; the median time between RT-PCR and CT was 1 day (0–7 days) [5]. Xie et al. report that in 3% (5/167) of patients the RT-PCR was initially negative, but the CT showed signs of viral pneumonia. A follow-up PCR 2–8 days after a positive CT confirmed SARS-CoV2 infection. In 4% (7/167) of patients the CT was initially negative, but the PCR was positive.

### Differentiation of SARS CoV-2 pneumonia and other viral pneumonias

A study by Bai et al. evaluated whether pneumonia caused by SARS-CoV2 (n = 219) can be differentiated from viral pneumonia of a different etiology (n = 205) on the basis of CT findings [17]. The sensitivity of 7 radiologists was between 67% and 97%, the specificity for 6 radiologists lay between 93 and 100%; one radiologist, who had received no training regarding the CT morphology of COVID-19 pneumonia, showed a specificity of 7%. Findings indicative of COVID-19 pneumonia were findings predominantly in the periphery of the lung (80% versus 57%), the presence of ground glass opacities (91% versus 68%), reticulations (56% versus 22%), and vasodilation (59% versus 22%).

### Discussion

In December 2019, cases of patients with acute pneumonia, the cause of which was initially unclear, increased in Wuhan Province, China. Within a short time, a novel coronavirus could be isolated as a trigger [1], which WHO officially named “SARS-CoV-2”. The disease itself has been designated “COVID-19”.

The primary transmission route of SARS-CoV-2 is droplet infection. Smear infections do not seem to play a role, but according to publications of the Robert Koch Institute this cannot be ruled out at this point in time.

The clinical pattern initially shows the symptoms of an infection of the respiratory tract, although the severity can be variable with unspecific, mild symptoms up to severe disease manifestations. The most common symptoms are cough, fever, myalgia and headaches [20]. According to the evaluation of 72 314 patients suffering from SARS-CoV-2 by the Chinese Center for Disease Control and Prevention, 81% of patients showed a mild and 14% a severe course. Five percent of patients were critically ill with severe respiratory insufficiency [3].

To date, no proven specific antiviral therapy for COVID-19 is known, although a number of trials with different substances (Camostat, Remdesivir, Lopinavir-Ribonavir or hydroxychloroquine) have

been conducted [21]. The primary therapy is therefore symptomatic; in the case of serious illnesses, intensive medical treatment including respiration and ECMO therapy may be necessary [22]. Depending on the country, the mortality rate of the disease is between 0.5 and 3.5% (updated figures can be found under <https://www.who.int>).

Diagnostic measures depend on the symptoms and the current risk profile (visit to a risk area, contact with an infected person). With the increasing spread of COVID-19, however, symptomatology alone will decide whether further clarification is necessary. Detection of SARS-CoV-2 is performed by RT-PCR from a throat wash or deep throat swab.

Despite the fact that COVID-19 has only been known since December 2019, numerous reports on CT morphology are already available; in most cases these are case reports. We identified 14 studies in which the CT characteristics of at least 10 patients each had been systematically evaluated. A limiting factor here is that the CT technique was not standardized among the various studies and the radiological terminology was not uniformly employed. Nevertheless, the picture emerges that, unlike most other pathogen-induced pneumonia, pneumonia caused by SARS-CoV-2 in many patients seems to provide a CT image, especially initially, that is suggestive for diagnosis. The cardinal signs are ground glass opacities, consolidation and crazy paving. The opacification are typically round or geographically configured and at least partially show a sharply delineated border to the surrounding healthy lung. The vast majority of cases show multifocal, bilateral involvement. The periphery of the lung and the lower lobes are predominantly affected. Pleural effusions or lymphadenopathy are usually not present. Overall, the CT image initially resembles a cryptogenic organizing pneumonia pattern [23]. As the disease progresses, the lesions, especially the consolidation and crazy paving increase, and the picture changes into that of lobar pneumonia/bronchopneumonia or even acute respiratory distress syndrome (ARDS). Keeping in mind the CT findings described above, it seems possible, according to a recent study, to distinguish SARS-CoV-2 pneumonia radiologically from other viral pneu-

monia with moderate sensitivity but high specificity [17]. Parameters that argued for COVID-19 pneumonia were a predominant involvement of the lunge periphery, the presence of ground glass opacity, reticulation and vasodilation. Despite these data, there is naturally a large overlap in CT morphology with other viral pneumonias, so that RT-PCR is still the gold standard in diagnostics.

## Summary

The number of patients with COVID-19 is rapidly increasing in Europe. The lethality of the disease appears to be higher than that of seasonal flu, for example, especially in older patients. RT-PCR is the gold standard for establishing a diagnosis. In many patients, chest CT seems to provide an image that is suggestive for diagnosis. The cardinal signs are ground glass opacities, consolidation and crazy paving, predominantly located in the periphery of the lower lobes. This CT morphology can support the diagnosis and differentiation from other viral pneumonia. This is particularly important because RT-PCR can initially provide a false negative result.

## Conflict of Interest

The authors declare that they have no conflict of interest.

## Authors

Okka Wilkea Hamer<sup>1,4</sup>, Bernd Salzberger<sup>2</sup>, Johannes Gebauer<sup>3</sup>, Christian Stroszczyński<sup>4</sup>, Michael Pfeifer<sup>1,4,5</sup>

<sup>1</sup> Department of Radiology, Klinik Donaustauf, Germany

<sup>2</sup> Infectious Diseases, University Hospital Regensburg, Germany

<sup>3</sup> Pneumology, Klinikum Passau, Germany

<sup>4</sup> Institut für Röntgendiagnostik, Universitätsklinikum Regensburg, Germany

<sup>5</sup> Pneumology, Barmherzige Brüder gemeinnützige Krankenhaus GmbH, Regensburg, Germany

## Correspondence

Prof. Okka Wilkea Hamer

Institut für Röntgendiagnostik, Klinikum der Universität Regensburg  
Franz-Josef-Strauß-Allee 11  
93042 Regensburg  
Germany  
Tel.: ++49/941/944 74 01  
Fax: ++49/941/944 74 02  
okka.hamer@ukr.de

## References

- [1] Zhu N, Zhang D, Wang W et al. A Novel Coronavirus from Patients with Pneumonia in China, 2019. *The New England journal of medicine* 2020; 382: 727–733
- [2] Iuliano AD, Roguski KM, Chang HH et al. Estimates of global seasonal influenza-associated respiratory mortality: a modelling study. *Lancet (London, England)* 2018; 391: 1285–1300
- [3] Wu Z, McGoogan JM. Characteristics of and Important Lessons From the Coronavirus Disease 2019 (COVID-19) Outbreak in China: Summary of a Report of 72314 Cases From the Chinese Center for Disease Control and Prevention. *JAMA* 2020
- [4] Fang Y, Zhang H, Xie J et al. Sensitivity of Chest CT for COVID-19: Comparison to RT-PCR. *Radiology* 2020: 200432
- [5] Ai T, Yang Z, Hou H et al. Correlation of Chest CT and RT-PCR Testing in Coronavirus Disease 2019 (COVID-19) in China: A Report of 1014 Cases. *Radiology* 2020: 200642
- [6] Bernheim A, Mei X, Huang M et al. Chest CT Findings in Coronavirus Disease-19 (COVID-19): Relationship to Duration of Infection. *Radiology* 2020: 200463
- [7] Pan F, Ye T, Sun P et al. Time Course of Lung Changes On Chest CT During Recovery From 2019 Novel Coronavirus (COVID-19) Pneumonia. *Radiology* 2020: 200370
- [8] Chung M, Bernheim A, Mei X et al. CT Imaging Features of 2019 Novel Coronavirus (2019-nCoV). *Radiology* 2020: 200230
- [9] Ng MY, Lee EYP, Yang J et al. Imaging Profile of the COVID-19 Infection: Radiologic Findings and Literature Review. *Radiology: Cardiothoracic Imaging* 2020; 2: e200034
- [10] Song F, Shi N, Shan F et al. Emerging Coronavirus 2019-nCoV Pneumonia. *Radiology* 2020: 200274
- [11] Shi H, Han X, Jiang N et al. Radiological findings from 81 patients with COVID-19 pneumonia in Wuhan, China: a descriptive study. *The Lancet Infectious diseases* 2020
- [12] Li Y, Xia L. Coronavirus Disease 2019 (COVID-19): Role of Chest CT in Diagnosis and Management. *Am J Roentgenol American journal of roentgenology* 2020: 1–7
- [13] Li K, Wu J, Wu F et al. The Clinical and Chest CT Features Associated with Severe and Critical COVID-19 Pneumonia. *Investigative radiology* 2020
- [14] Chen N, Zhou M, Dong X et al. Epidemiological and clinical characteristics of 99 cases of 2019 novel coronavirus pneumonia in Wuhan, China: a descriptive study. *Lancet (London, England)* 2020; 395: 507–513
- [15] Huang C, Wang Y, Li X et al. Clinical features of patients infected with 2019 novel coronavirus in Wuhan, China. *Lancet (London, England)* 2020; 395: 497–506
- [16] Zhao W, Zhong Z, Xie X et al. Relation Between Chest CT Findings and Clinical Conditions of Coronavirus Disease (COVID-19) Pneumonia: A Multicenter Study. *Am J Roentgenol American journal of roentgenology* 2020: 1–6
- [17] Bai HX, Hsieh B, Xiong Z et al. Performance of radiologists in differentiating COVID-19 from viral pneumonia on chest CT. *Radiology* 2020: 200823
- [18] Xiong Y, Sun D, Liu Y et al. Clinical and High-Resolution CT Features of the COVID-19 Infection: Comparison of the Initial and Follow-up Changes. *Investigative radiology* 2020
- [19] Xie X, Zhong Z, Zhao W et al. Chest CT for Typical 2019-nCoV Pneumonia: Relationship to Negative RT-PCR Testing. *Radiology* 2020: 200343
- [20] Guan WJ, Ni ZY, Hu Y et al. Clinical Characteristics of Coronavirus Disease 2019 in China. *The New England journal of medicine* 2020
- [21] Zhang L, Liu Y. Potential interventions for novel coronavirus in China: A systematic review. *Journal of medical virology* 2020
- [22] Jin YH, Cai L, Cheng ZS et al. A rapid advice guideline for the diagnosis and treatment of 2019 novel coronavirus (2019-nCoV) infected pneumonia (standard version). *Military Medical Research* 2020; 7: 4
- [23] Kanne JP, Little BP, Chung JH et al. Essentials for Radiologists on COVID-19: An Update-Radiology Scientific Expert Panel. *Radiology* 2020: 200527

## Bibliography

DOI <https://doi.org/10.1055/a-1142-4094>

Published online: 26.3.2020

Fortschr Röntgenstr 2020; 192: 386–390

© Georg Thieme Verlag KG, Stuttgart · New York  
ISSN 1438-9029